Med Oncol (2011) 28:682–688
DOI 10.1007/s12032-010-9515-2

ORIGINAL PAPER

High expression of PD-L1 in lung cancer may contribute to poor prognosis and tumor cells immune escape through suppressing tumor infiltrating dendritic cells maturation

Chuan-Yong Mu · Jian-An Huang · Ying Chen · Cheng Chen · Xue-Guang Zhang

Received: 12 February 2010 / Accepted: 22 March 2010 / Published online: 6 April 2010
© Springer Science+Business Media, LLC 2010

Abstract The immunohistochemical analysis was used to evaluate the expression of PD-L1 in 109 non-small cell lung cancer (NSCLC) tissues and para-tumor tissues. Associations between expressed PD-L1 and tumor histological types, degree of differentiation, and lymph node metastasis were calculated, and overall survival was assessed. Meanwhile, immunohistochemistry and immunofluorescence double labeling technique were performed to detect the expressions of PD-L1, CD1α, and CD83 on TIDC of 20 lung cancer tissues, and the expression of PD-L1 in CD1α^+DCs and CD83$^+$DCs and their significances were also explored. We found that the expression rate of PD-L1 in NSCLC was associated with histological types and overall survival. Patients with either adenocarcinoma or survival time after surgery less than 3 years showed higher expression rate of PD-L1. Furthermore, Cox model analysis indicated that PD-L1 might be regarded as a poor prognostic factor. PD-L1 could be also detected in CD1α^+ immature DC in NSCLC, indicating that as a class of key anti-tumor immunocyte in tumor microenvironment, DC expressing PD-L1 itself might play an important role in keeping its immature status and contributing to tumor cells immune escape and disease progression.

Keywords NSCLC · Dendritic cells (DC) · Programmed-death receptor ligands 1 (PD-L1) · CD83 · CD1α

C.-Y. Mu · J.-A. Huang (✉) · C. Chen
Respiratory Department, The First Affiliated Hospital of Soochow University, 188 Shizi Street, 215006 Suzhou, China
e-mail: huang_jian_an@163.com

C.-Y. Mu · J.-A. Huang · C. Chen
Clinical Immunology Laboratory of Jiangsu Province, The First Affiliated Hospital of Soochow University, 188 Shizi Street, 215006 Suzhou, China

Y. Chen
Respiratory Department, Suzhou Municipal Hospital, 26 Daoqian Street, 215002 Suzhou, China

X.-G. Zhang
Biotechnology Research Institute, Soochow University, 48 Renmin Road, 215007 Suzhou, China

Introduction

Lung cancer is one of the most common fatal malignant tumors, and chemotherapy and radiotherapy have low efficacy against it. Studies of new therapeutic strategies including immunotherapy are in progress [1]. However, researches demonstrate that tumor cells could evade host immune surveillance by several strategies. These include down-regulation of cell surface major histocompatibility complex class I molecules, secretion of immunosuppressive factors, lack of T-cell costimulation, and expression of death ligands or negative ligands [2–4].

Recently, programmed-death receptor ligand 1 (PD-L1) has been shown to be involved in negative regulation of immune responses through PD-1 receptor on activated T and B cells and has been thought to be an important strategy by which cancer cells evade host immune surveillance. Cancer cells expressing PD-L1 have been shown to increase apoptosis of antigen-specific human T-cell clones and to inhibit CD4 and CD8 T-cell activation in vitro [5–7]. However, tumor cells may suppress immune response by several other strategies. Data have revealed that antigen presentation by immature dendritic cells (imDCs) plays a role in establishing and maintaining T-cell tolerance, and PD-L1, acted as a negative regulator, also could inhibit

Dana-Farber EX1023
Dana-Farber v. BMS, IPR2023-00252
Page 1 of 7

antigen-specific dendritic cells (DC) activation and immune function [8]. Many studies focus on the relationship between PD-L1 and immune escape of lung cancer, and our previous study manifested blockade of PD-L1 on murine imDCs could promote T-cell proliferation and IL-2 production, but no pathological data of PD-L1 expression and relationship with tumor infiltrating DCs (TIDC) is presented in microenvironment of human lung cancer tissue sites at present. Here, we want to explore the association between TIDC subset expression, especially PD-L1, and tumor immunity in non-small cell lung cancer (NSCLC).

Materials and methods

Subjects

Formalin-fixed, paraffin-embedded tissue samples were obtained from a randomly selected group of 109 patients with lung cancer, who underwent lobectomy surgery in the first affiliated hospital of Soochow University from January 2002 to March 2006. The surgically resected specimens included 46 adenocarcinomas and 63 squamous cell carcinomas. Tumors were classified as stage I ($n = 36$), stage II ($n = 35$), and stage III ($n = 38$), The American Joint Committee on Cancer staging was used for staging of the patients [9]. Resected lymph nodes had been histologically verified (N0 = 39, N1 = 32, N2 = 36, N3 = 2). No patient underwent radiation or chemotherapy before surgery. Thirty-two patients survived above 3 years, 77 patients survived less than 3 years, and all patients who were analyzed for overall survival must meet the following criteria: (a) survived for 3 months after surgery and (b) did not die of any cause other than lung cancer after surgery. Twenty tissue samples obtained at surgery were immediately embedded in OCT and then frozen and stored at −80°C for immunofluorescence staining. All tumors were evaluated according to H&E staining.

Immunohistochemical stain (IHC) and immunofluorescence

Sections were deparaffinized in xylene and rehydrated in graded alcohols and water. For antigen retrieval, specimens were exposed to 10 mM buffer (pH 6.0) and heated for 15 min in a water bath (120°C). Endogenous peroxidase activity was blocked by treatment with 3% hydrogen peroxide for 10 min. After washing in PBS, the slides were incubated overnight at 4°C with primary monoclonal antibodies directed against PD-L1 and CD1α. After several rinses in phosphate-buffered saline, the sections were incubated in the biotinylated secondary antibodies. Bound antibodies were detected by the streptavidin–biotin method. Slides were rinsed in phosphate-buffered saline, exposed to diaminobenzidine, and counterstained with Mayer's hematoxylin. The negative controls for these proteins were made by the omission of the primary antibody during the process of immunohistochemical staining.

For immunofluorescence, frozen samples were cut into serial 5-μm-thick sections, and after fixing with acetone, they were incubated with primary antibody of PD-L1, then followed by CD1α or CD83. In a subsequent secondary step, FITC-conjugated goat anti-rabbit and RhodamineB200-conjugated goat anti-mouse IgG were used. Confocal laser scanning microscopy was performed with a confocal laser scanning microscope equipped with 10, 20, and 40 objectives.

Microscopic evaluation of tumor sections

Diagnoses were histologically verified at the department of pathology, the slides were examined independently by two observers blinded to both clinical and pathologic data. PD-L1 positive tumor cells displayed membranous and cytoplasmic staining. CD1α-positive DC were identified by their brown membranous staining patterns and cytoplasmic flame-like extensions. PD-L1 and CD1α proteins were quantified using a visual grading system based on the extent of staining (by percentage of positive tumor cells graded on a scale of 0–3: 0 = none, 1 = 1–10%, 2 = 11–50%, 3 = 51–100%) and the intensity of staining (graded on a scale of 0–3: 0 = no staining, 1 = weak staining, 2 = moderate staining, 3 = strong staining). A semi-quantitative H-score was obtained by multiplying the grades of extent and intensity of staining. The median value of all the H-scores was chosen as the cutoff value for dividing the expression of proteins into high and low [10].

Statistical analysis

A comparison of clinic-pathologic characteristics of patients was evaluated with the Fisher's exact test. Overall survival (OS) was calculated using the Kaplan–Meier method. OS was defined as the time from start of treatment to death. The differences between the survival curves were tested by using the log-rank test. The Cox proportional hazards regression model was used to determine the joint effects of several variables on survival. All P values were performed two-tailed, with SPSS 12.0 software.

Dana-Farber EX1023
Dana-Farber v. BMS, IPR2023-00252
Page 2 of 7

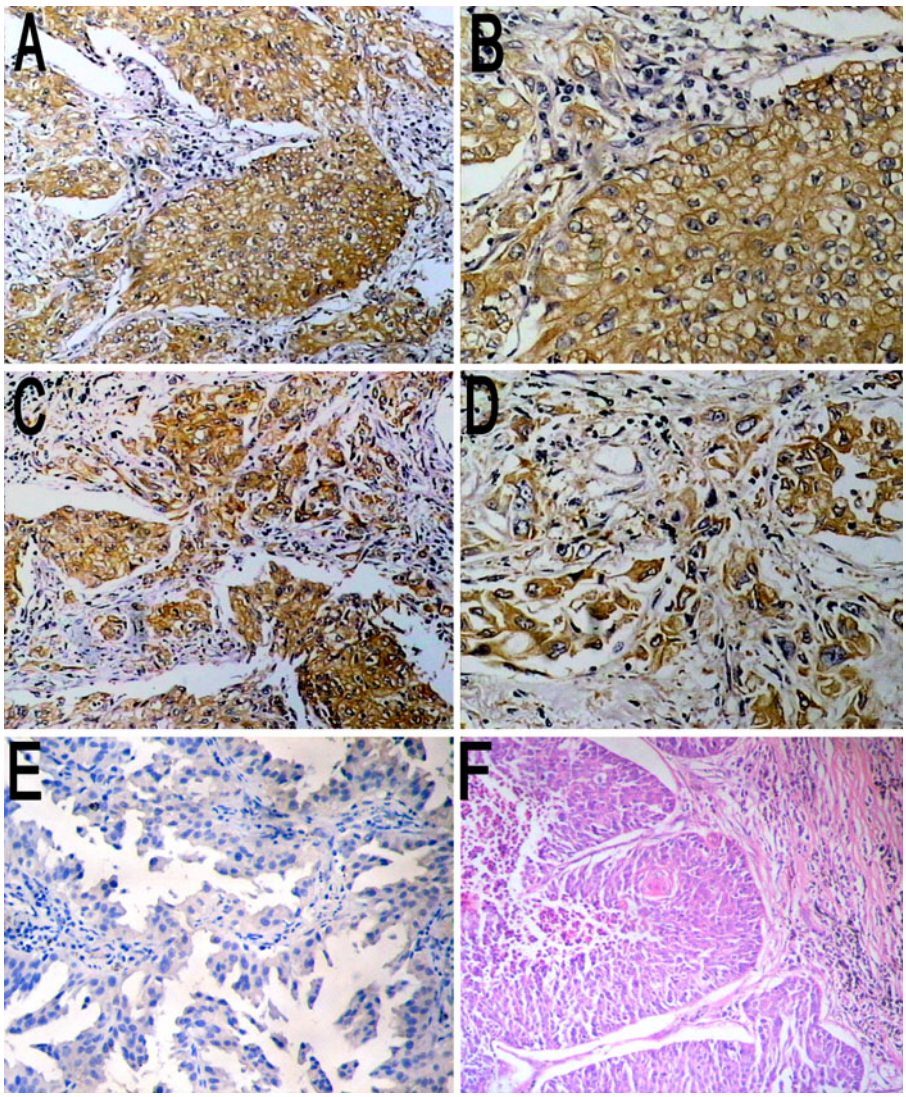

Fig. 1 Representative immunohistochemical staining in non-small cell lung cancer. PD-L1 positive case of non-small cell lung cancer in a cluster pattern (**a** and **b**) and a scattered pattern (**c** and **d**), PD-L1-negative control (**e**), H&E staining (**f**) (Original magnifications **a**, **c**, **e** and **f** 200×, **b** and **d** 400×)

Results

Association between PD-L1 expression and the clinicopathological variables

The expression of PD-L1 was demonstrated in the cell membrane and cytoplasm (Fig. 1). The percentage of PD-L1-positive cells in non-small cell lung cancer was 53.2% (58/109), whereas only 4.8% (5/109) expressed in the lung parenchyma adjacent to tumor ($P = 0.004$). The percentage of PD-L1-positive cells in adenocarcinoma was higher than that in squamous cell carcinoma (65.2% vs. 44.4%, $P = 0.032$).

Prognostic significance of PD-L1-positive tumor cells

Correlation of survival with clinicopathologic factors in patients with lung cancer. The clinicopathologic features affecting patient survival are summarized in Table 1. In multivariate analysis, PD-L1-positive lung cancer cells were significantly related to a poor prognosis (Fig. 2).

Changed infiltration of TIDC with changed PD-L1 expression in tumor tissues

Cells stained with CD1α antibody were found in 59 (54%) of 109 lung cancer samples. Positively stained cells indicated immature DC, characterized by the expression of CD1α, and showed a typical dendritic morphology, resided in the tumor margins in a cluster pattern and a scattered pattern (Fig. 3). To evaluate whether PD-L1 expression on non-small cell lung cancers limited immune effector cell infiltration within tumors, we also analyzed the correlation between expression of PD-L1 on tumor cells and CD1α-positive TIDC. The result indicated that CD1α-positive TIDC were increased in PD-L1-positive sections.

Dana-Farber EX1023
Dana-Farber v. BMS, IPR2023-00252
Page 3 of 7

Table 1 Characteristics of patients, PD-L1 expression, and clinicopathologic parameters

Characteristics	PD-L1 expression		*P*	CD1α expression		*P*
	Positive	Negative		Positive	Negative	
Histology						
Squamous cell carcinoma	28	35	0.032*	29	34	0.395
Adenocarcinoma	30	16		20	26	
Differentiation						
Well	12	17	0.136	10	19	0.248
Moderate/poor	46	34		39	41	
pN classifications						
N0	20	19	0.566	17	22	0.652
N1	16	16		13	19	
N2	20	16		18	18	
N3	2	0		1	1	
Stage classifications						
I	18	18	0.768	14	22	0.712
II	18	17		15	20	
III	22	16		20	18	
Survival years after surgery						
<3 year	46	31	0.034*	39	38	0.063
≧3 year	12	20		10	22	

* $P < 0.05$

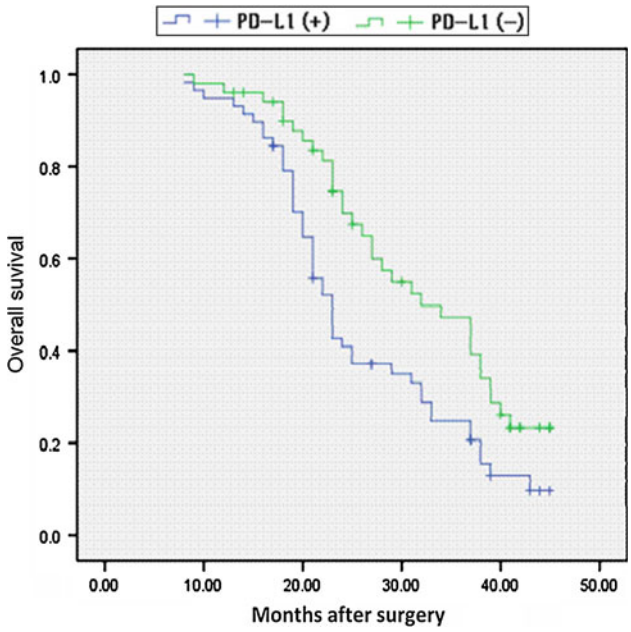

Fig. 2 Kaplan–Meier survival curves of patients with lung cancer according to the presence of PD-L1-positive lung cancer cells

Expression of PD-L1 on CD1α$^+$DCs is higher than that on CD83$^+$DCs

Immunofluorescence staining on frozen sections of lung cancer tissues were evaluated by confocal microscopy (Fig. 4), expression of PD-L1 on CD1α$^+$DCs and CD83$^+$DCs is (65.68 ± 12.50)% and (37.16 ± 9.52)%, respectively (Table 2), which presents a negative correlation between ratio of CD83/CD1α and PD-L1/CD1α (rs = −0.532, $P = 0.016$), while presents a positive correlation between ratio of PD-L1/CD1α and PD-L1/CD83 (rs = 0.537, $P = 0.015$).

Discussion

PD-L1 is one member of the B7 superfamily and more broadly expressed than the other B7 superfamily members [11, 12]. PD-L1 expressing on cancer cells could increase apoptosis of human T-cell clones. We and others have found while blockade PD-L1 has been shown to increase antitumoral T-cell responses directed against PD-L1-positive tumors in vitro and in vivo [13–15]. Thus, PD-L1 may function as a negative regulator of effector T-cell-mediated antitumoral immunity [16–18]. Consistent with above observations, we have demonstrated the expression of PD-L1 in surgically resected specimens of non-small cell lung cancer, and expression of these molecules is found in both the plasma membrane and cytoplasm of cancer cells. In contrast, paratumor tissues failed to express PD-L1. In the present study, there was a statistically significant correlation between the percentage of PD-L1-positive cells and histological type. Otherwise, the higher percentage of

Dana-Farber EX1023
Dana-Farber v. BMS, IPR2023-00252
Page 4 of 7

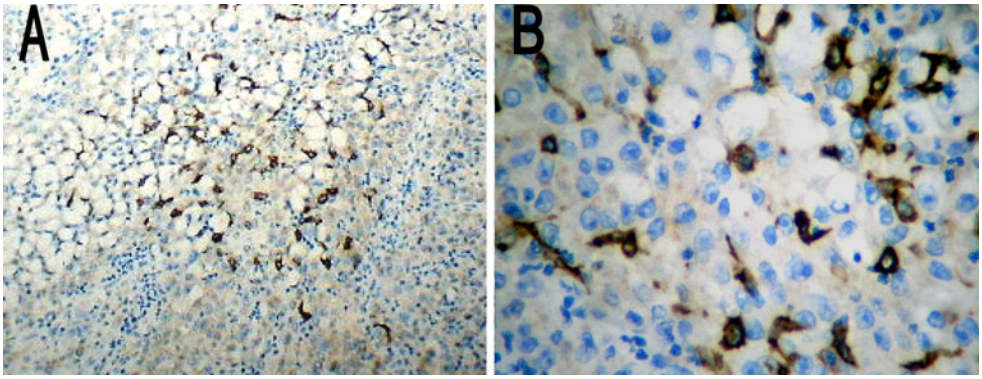

Fig. 3 In lung cancer tissues, CD1α^+DCs were found to infiltrate the tumor beds with brown stain and dendritic morphology, they are selectively adhere to tumor cells. (Original magnifications **a** 200×, **b** 400×)

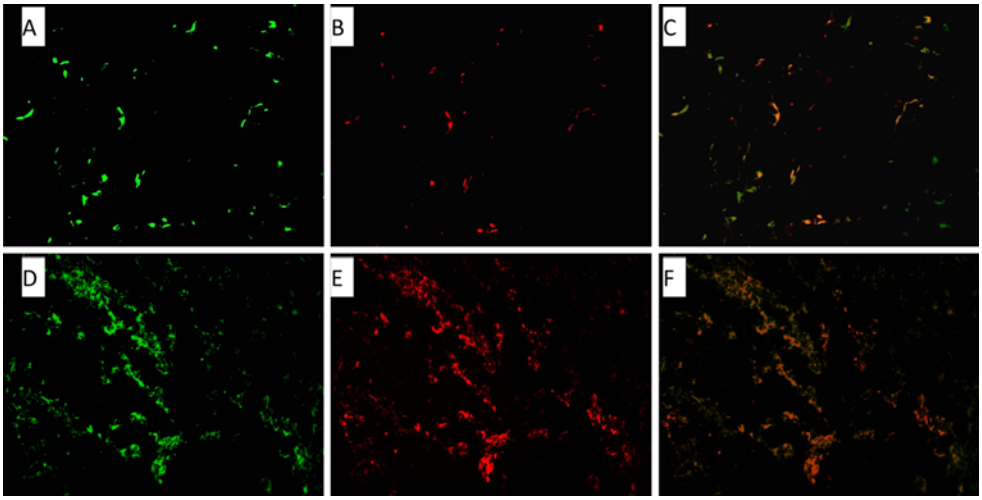

Fig. 4 Immunofluorescence staining on lung cancer tissue frozen sections evaluated by confocal microscopy. **a** and **d**, dendritic cells are stained with PD-L1 antibody (*green*). **b** and **e**, dendritic cells are stained with CD83 and CD1α antibodies, respectively (*red*) **c** and **f**, PD-L1$^+$CD83$^+$ and PD-L1$^+$CD1α^+ dendritic cells are identified (*deep yellow*). (Original magnifications, 200×)

PD-L1 positive lung cancer cells was significantly related to a poor prognosis. No correlation was observed between PD-L1 expression and other clinicopathological parameters. So, we can draw a conclusion that PD-L1 plays a role in disease progression and detecting PD-L1 molecule on lung cancer tissues will help estimate the prognosis of patients.

The result also manifests that CD1α-positive DC could infiltrate in the tumor, and high percentage infiltration of CD1α-positive DC in tumor was significantly correlated with the expression of PD-L1-positive lung cancer. So, we presume that, besides T cells, the other immune cells, include DC, in the local tumor area are all affected by PD-L1 expression in tumor microenvironment.

DC in general play a key role in the development and maintenance of an immune response and present an important role in a cellular antitumor immune response [19, 20].They perform antitumor process by infiltrating, capturing, and processing tumor antigens and subsequent presentation, activation, and recruitment of lymphocytes. Several previous studies have already showed a correlation between the quantity of TIDC and clinical outcome in different tumor types and clinical outcome. DC can be identified with series different markers (CD1α, CD83, HLA class II, and PD-L1, etc.). CD83 is a highly specific marker for mature DC. CD1α is another antigen-presenting molecule expressed on dendritic cell subtypes and often being regarded as a marker for immature DC [21–24]. Although IL-10, TGF-β, and VEGF are considered as potent inhibitory mediators of DC maturation and function and have been associated with various extents with a defective antitumor immune response, but in some previous studies, these three factors were detected, regardless of the subsets of DC present in the tumor, and no correlation was observed with the number of CD1α-positive cells [25–27]. Therefore,

Dana-Farber EX1023
Dana-Farber v. BMS, IPR2023-00252
Page 5 of 7

Table 2 The percentage of PD-L1 on CD1α- and CD83-positive TIDC in tumor regions

Tumor specimen	CD83/CD1α%	PD-L1/CD1α%	PD-L1/CD83%
1	40.0	62.2	27.8
2	51.2	56.1	42.9
3	69.2	69.2	40.7
4	47.5	77.5	47.4
5	37.1	74.3	30.8
6	52.4	61.9	54.5
7	68.9	57.8	51.6
8	34.0	74.0	41.2
9	51.4	70.3	42.1
10	54.2	41.7	15.4
11	116.7	50.0	28.6
12	66.1	58.9	40.5
13	35.3	55.9	25.0
14	28.3	87.0	30.8
15	45.9	78.4	35.3
16	31.6	81.6	33.3
17	51.2	65.9	42.9
18	66.7	70.6	44.1
19	76.7	76.7	30.4
20	126.1	43.5	37.9
Mean ± SD	58.23 ± 26.14	65.68 ± 12.50	37.16 ± 9.52
rs		−0.532	0.537
P		0.016*	0.015*

* $P < 0.05$

whether or not there is relationship between PD-L1 expression in tumor microenvironment and DC maturation disability needs to be reconsidered and further studied.

It is still unclear how TIDC interact with tumor cells and other immune cells in the local tumor area. In this study, a distinct infiltration pattern was found according to the maturation and activation status of the DC. We presume that antigen-capturing and antigen-processing DC on their way to the tumor cells are hindered in their function due to inhibiting factors in the tumor environment and maybe PD-L1 is one of important inhibiting factors expression by lung cancer cells.

Our data also manifest that expression of PD-L1 on $CD1\alpha^{+}$DCs is higher than on $CD83^{+}$DCs, indicating there is a positive correlation between PD-L1 expression and DC mature status. So, maturing DC in the tumor cells might be hindered in their ways to migrate out to secondary lymphoid tissue after antigen captured possibly by expression of PD-L1 on lung cancer cells.

Expression of PD-L1 on lung cancer cells has ever been confirmed as an activator of antigen-specific T cell [28]. In this study, we just to demonstrate that correlation between PD-L1 expression and TIDC mature status, furthermore, PD-L1 may contribute to tumor cells immune escape and poor prognosis through suppress TIDC maturation as another way. Thus, we could perform a further research based on this result.

Conclusion

All that we have found above indicate PD-L1 expression had contributed to DC maturation within tumor cell area and correlated with the survival of patients with lung cancer. So, further studies will be required to establish the specific role of the PD-L1 in tumor immunity and to draw conclusions for the design of therapeutic strategies.

Acknowledgments We would like to thank Haidong Xu (Department of Microbiology and Immunology, University of Rochester Medical Center, Rochester, NY, USA) for critical reading of the manuscript, Prof. Yongquan Xue (The first affiliated hospital of Soochow University, China) for his fluorescence microscope technique support, and Dr. Jinfang Shen (Soochow University, China) for pathological support. This work was supported by the ''Key Project of National Natural Science Foundation of China'' (30770947), "135 Projects focus on Talent Foundation of Health Department of Jiangsu Province (RC2007075)" and "Medical Development Foundation of Jiangsu Province (H200712)".

References

1. Yasumoto K, Hanagiri T, Takenoyama M. Lung cancer-associated tumor antigens and the present status of immunotherapy against non-small-cell lung cancer. Gen Thorac Cardiovasc Surg. 2009;57:449–57.
2. Blank C, Gajewski TF, Mackensen A. Interaction of PD-L1 on tumor cells with PD-1 on tumor-specific T cells as a mechanism of immune evasion: implications for tumor immunotherapy. Cancer Immunol Immunother. 2005;54:307–14.
3. XU X, et al. Clinicopathological significance of major histocompatibility complex class I-related chain A and B expression in thyroid cancer. Clin Endocrinol. 2006;91:2704–12.
4. Kaklamanis L, et al. Loss of major histocompatibility complex-encoded transporter associated with antigen presentation (TAP) in colorectal cancer. Am J Pathol. 1994;145:505–9.
5. Blank C, Brown I, Peterson AC. PD-L1/B7–H1 inhibits the effector phase of tumor rejection by T cell receptor (TCR) transgenic CD8+T cells. Cancer Res. 2004;64:1140–5.
6. Mary E, et al. Tissue expression of PD-L1 mediates peripheral T cell tolerance. Exp Med. 2006;203:883–95.
7. Fabienne H, et al. Peripheral deletional tolerance of alloreactive CD8 but not CD4 T cells is dependent on the PD-1/PD-L1 pathway. Blood. 2008;112:2149–55.
8. Gabrilovich D. Mechanisms and functional significance of tumor-induced dendritic cell defects. Nat Rev Immunol. 2004;4:941–52.
9. Mountain CF. Revisions in the international system for staging lung cancer. Chest. 1997;111:1710–7.
10. Olaussen KA, et al. DNA repair by ERCC1 in non-small-cell lung cancer and cisplatin-based adjuvant chemotherapy. N Engl J Med. 2006;355:983–91.

Dana-Farber EX1023
Dana-Farber v. BMS, IPR2023-00252
Page 6 of 7

11. Dong H, Zhu G, Tamada K, Chen L. B7-H1, a third member of the B7 family, co-stimulates T-cell proliferation and interleukin-10 secretion. Nat Med. 1999;5:1365–9.
12. Sharpe AH, Freeman GJ. The B7-CD28 superfamily. Nat Rev Immunol. 2002;2:116–26.
13. Chen C, et al. Expression of programmed-death receptor ligands 1 and 2 may contribute to the poor stimulatory potential of murine immature dendritic cells. Immunol. 2007;212:159–65.
14. Wong RM, et al. Programmed death-1 blockade enhances expansion and functional capacity of human melanoma antigen-specific CTLs. Int Immunol. 2007;19:1223–34.
15. Tsushima F, et al. Interaction between B7-H1 and PD-1 determines initiation and reversal of T cell anergy. Blood. 2007; 110:180–5.
16. Blank C, et al. Blockade of PD-L1 (B7–H1) augments human tumor-specific T cell responses in vitro. Int J Cancer. 2006; 119:317–27.
17. Brown JA, et al. Blockade of programmed death 1 ligands on dendritic cells enhances T cell activation and cytokine production. J Immunol. 2003;170:1257–66.
18. Dong H, et al. Tumor-associated B7-H1 promotes T-cell apoptosis: a potential mechanism of immune evasion. Nat Med. 2002;8:793–800.
19. Matthias S. Immunesurveillance by dendritic cells: potential implication for immunotherapy of endocrine cancers. Endocr Relat Cancer. 2006;13:779–95.
20. Mary F, Barbara J. Dendritic cells: immune regulators in health and disease. Physiol Rev. 2002;82:97–130.
21. Zhou LJ, Thomas F. CD14+ blood monocytes can differentiate into functionally mature CD83+ dendritic cells. PNAS. 1996; 93:2588–92.
22. Vakkila J, et al. A basis for distinguishing cultured dendritic cells and macrophages in cytospins and fixed sections. Pediatr Dev Pathol. 2005;8:43–51.
23. Ivan P, Dominique B, Nathalie F. Dendritic cells infiltrating human non-small cell lung cancer are blocked at immature stage. Immunol. 2007;178:2763–9.
24. Kim R, Emi M, Tanabe K. Functional roles of immature dendritic cells in impaired immunity of solid tumor and their targeted strategies for provoking tumor immunity. Clin Exp Immunol. 2006;146:189–96.
25. Hyun K, et al. Down-regulation of cellular vascular endothelial growth factor (VEGF) levels induces differentiation of leukemic cells into leukemic-dendritic cells in patients with acute myeloid leukemia. Blood ASH (Annual Meeting Abstracts). 2005;106: 2226.
26. Boorjian SA, et al. T-cell coregulatory molecule expression in urothelial cell carcinoma: clinicopathologic correlations and association with survival. Clin Cancer Res. 2008;14:4800–8.
27. Sergey V, et al. Adenosine receptors in regulation of dendritic cell differentiation and function. Blood. 2008;112:1822–31.
28. Konishi J, et al. B7-H1 expression on non-small cell lung cancer cells and its relationship with tumor—infiltrating lymphocytes and their PD-1 expression. Clin Cancer Res. 2004;10:5094–100.

Dana-Farber EX1023
Dana-Farber v. BMS, IPR2023-00252
Page 7 of 7