ANNALS of Clinical and Translational Neurology
Open Access
American Neurological Association since 1875

BRIEF COMMUNICATION

Cladribine to treat disease exacerbation after fingolimod discontinuation in progressive multiple sclerosis

Cesar Alvarez-Gonzalez[1,2], Ashok Adams[3], Joela Mathews[4], Benjamin P. Turner[1,2], Gavin Giovannoni[1,2], David Baker[1] & Klaus Schmierer[1,2]

[1]BartsMS, Blizard Institute (Neuroscience), Queen Mary University of London, London, United Kingdom
[2]Emergency Care & Acute Medicine Neuroscience Clinical Academic Group, Barts Health NHS Trust, London, United Kingdom
[3]Department of Neuroradiology, St Bartholomew's Hospital, Barts Health NHS Trust, London, United Kingdom
[4]Pharmacy, Barts Health NHS Trust, London, United Kingdom

Correspondence
Klaus Schmierer, BartsMS, Blizard Institute, Queen Mary University of London, 4 Newark Street, London E1 2AT, United Kingdom.
Tel: +44 20 7882 6246;
Fax: +44 20 7882 6913;
E-mail: k.schmierer@qmul.ac.uk

Funding Information
No funding information provided.

Received: 1 February 2017; Revised: 16 March 2017; Accepted: 17 March 2017

***Annals of Clinical and Translational Neurology* 2017; 4(7): 506–511**

doi: 10.1002/acn3.410

Abstract

Rebound disease following cessation of disease modifying treatment (DMT) has been reported in people with both relapsing and progressive multiple sclerosis (pwRMS, pwPMS) questioning strict separation between these two phenotypes. While licensed DMT is available for pwRMS to counter rebound disease, no such option exists for pwPMS. We report on a pwPMS who developed rebound disease, with 45 Gadolinium-enhancing lesions on T_1 weighted MRI brain, within 6 months after fingolimod 0.5 mg/day was stopped. Treatment with a short course of subcutaneous cladribine 60 mg led to effective suppression of inflammatory activity and partial recovery with no short-term safety issues or adverse events.

Introduction

Fingolimod is an effective disease-modifying treatment (DMT) for people with relapsing multiple sclerosis (pwRMS). It has also undergone a phase III trial in people with progressive MS (pwPMS) failing to show efficacy on the primary endpoint.[1] A key mechanism of action of fingolimod is believed to be sequestering of pathogenic lymphocytes in lymph nodes[2] thereby preventing entry into the central nervous system (CNS). When treatment is stopped lymphocyte levels usually return to normal within 4–8 weeks. The resulting release of lymphocytes back into the blood circulation may cause "rebound" disease, defined as a degree of disease activity significantly exceeding pre-DMT activity.[3,4] We report a case of rebound disease after fingolimod cessation in a pwPMS, who was successfully treated with Cladribine as an off-label "rescue" therapy.

Case report

Written informed consent was obtained from the patient for her clinical information and MRI to be published.

At the age of 28, a woman of Afro-Caribbean origin first noticed weakness of her right leg. Neurological signs on examination were indicative of an upper motor neuron syndrome, which steadily deteriorated henceforth. Thorough diagnostic work-up including MRI head and spinal cord, and assessment of her cerebro-spinal fluid, revealed her lower limb paresis to be the first manifestation of primary progressive MS (PPMS).

Five years after disease onset she was enrolled in the phase III trial of fingolimod 0.5 mg/day in PPMS (INFORMS).[1] She had never been treated with a DMT before.

Examination at baseline of the trial revealed bilateral internuclear ophthalmoplegia and right-sided hemiparesis limiting her walking range to 100–200 m. Her expanded disability status scale (EDSS) score was 5.5. MRI brain at screening showed 57 demyelinating lesions on T_2 weighted scans. In the cervical spinal cord two lesions were detected (Figure). Two of the brain lesions showed Gadolinium-enhancement (Gd^+) (Fig. 1A). Subsequent annual MRI head and cervical spine studies during INFORMS did not reveal any significant change in the

© 2017 The Authors. *Annals of Clinical and Translational Neurology* published by Wiley Periodicals, Inc on behalf of American Neurological Association. This is an open access article under the terms of the Creative Commons Attribution-NonCommercial-NoDerivs License, which permits use and distribution in any medium, provided the original work is properly cited, the use is non-commercial and no modifications or adaptations are made.

Hopewell EX1009

23289503, 2017, 7, Downloaded from https://onlinelibrary.wiley.com/doi/10.1002/acn3.410, Wiley Online Library on [29/11/2022]. See the Terms and Conditions (https://onlinelibrary.wiley.com/terms-and-conditions) on Wiley Online Library for rules of use; OA articles are governed by the applicable Creative Commons License

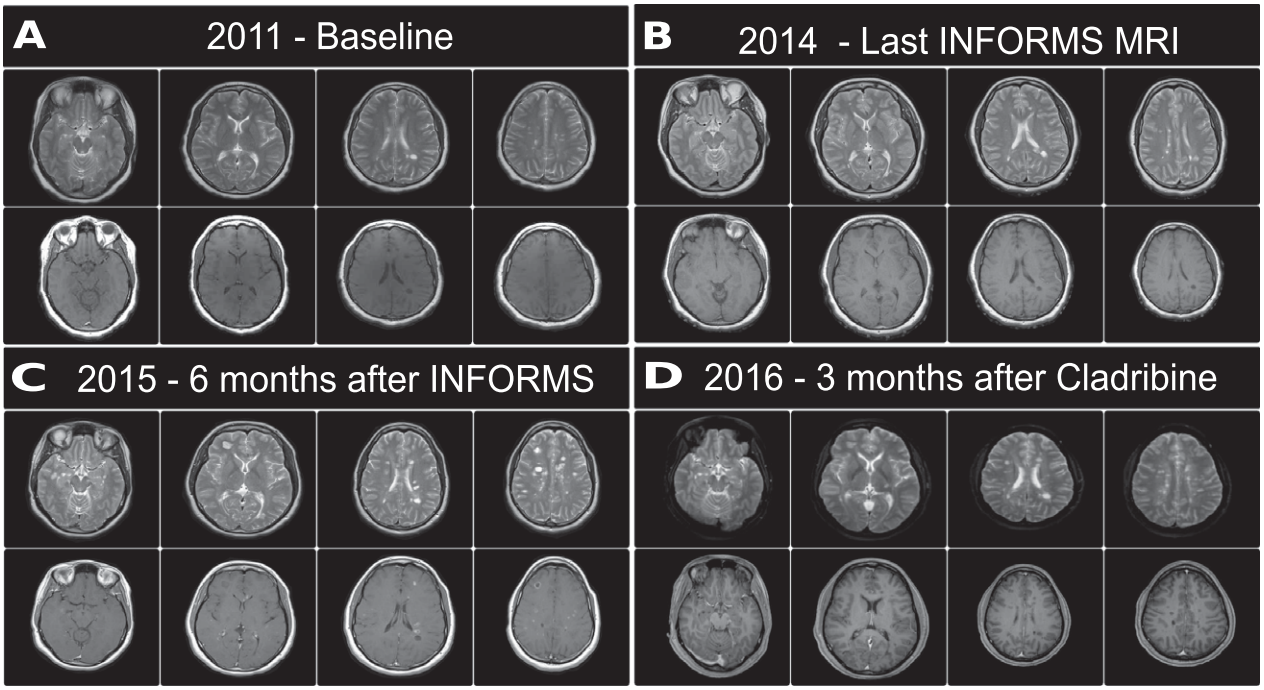

Figure 1. (A) Baseline MRI taken before entrance to INFORMS study. (B) Last MRI taken at the end of INFORMS study. (C) MRI taken 6 months after suspending Fingolimod and during the clinical relapse. (D) MRI taken 3 months after receiving treatment with Cladribine.

number or volume of lesions, and no Gd^+ lesions. Mild brain atrophy was noted (Fig. 1A and B). Unblinding after completion of INFORMS confirmed the patient had been randomized to fingolimod, of which she took the last dose during the open-label extension phase in December 2014. Over the course of INFORMS, a total duration of 3 years and 7 months including the extension phase, her EDSS deteriorated from 5.5 to 6.5 (Fig. 2A–E).

Six months after taking the last capsule of fingolimod, she presented to our clinic with significant exacerbation over the course of 1 week of her right-sided hemiparesis. She was unable to walk and had a new thoracic sensory level. On examination power of hip flexion on the left was MRC grade 2-3/5, on the right 1/5. Knee flexion was MRC 3/5 on the left and 0/5 on the right. Upper limb weakness had deteriorated on the right with MRC grades 2/5 distally and 4^-/5 proximally. There was a new sensory level for touch and pain from T_6 downwards bilaterally. Her EDSS was 8 (Fig. 2A). MRI head acquired within 1 week of deterioration showed 48 new T_2 lesions, of which 45 were Gd^+ on T_1 (Fig. 1C; Figure S1).

Given the significant clinical and MRI-detected disease activity, we offered treatment using Cladribine 60 mg s.c. over 5 weeks.[5] On follow-up 3 months after treatment initiation her EDSS had improved to 7, and MRI head at this time did not show any evidence of new T_2 lesions and no Gd^+ lesions (Fig. 1D).

Discussion

Irrespective of the disease course, withdrawal of DMT in MS poses the risk of resuming disease activity including rebound.[3,6,7] Whilst progressive MS, particularly PPMS is often characterized by a relative quiescence in terms of lesion activity detected on MRI,[8] there are many exceptions from this rule, and PPMS should therefore be considered as one end of the spectrum of MS presentations (the other being relapsing MS with a high relapse rate), rather than an altogether distinct subtype.[8] This view is supported by the revised classification of MS into active and non-active (1) relapsing and (2) progressive disease, and a lesser emphasis on "primary" versus "secondary" progression.[9] Against this backdrop, it makes evident sense to include clinical semiology as well as MRI appearance when deciding about the likelihood of response to DMT, be it licensed or off-label.

Two previously reported patients[6] share similarities with our case. They both had PPMS, participated in INFORMS, and developed relapses and MRI-documented disease activity 3–6 months after treatment cessation. Our case was characterized by steady deterioration, without any clinical relapses and two Gd^+ lesions at entry into the INFORMS trial. Significant clinical deterioration resembling a severe relapse after stopping fingolimod, and associated MRI activity, suggested two things, (1) that

© 2017 The Authors. *Annals of Clinical and Translational Neurology* published by Wiley Periodicals, Inc on behalf of American Neurological Association.

23289503, 2017, 7, Downloaded from https://onlinelibrary.wiley.com/doi/10.1002/acn3.410, Wiley Online Library on [29/11/2022]. See the Terms and Conditions (https://onlinelibrary.wiley.com/terms-and-conditions) on Wiley Online Library for rules of use; OA articles are governed by the applicable Creative Commons License

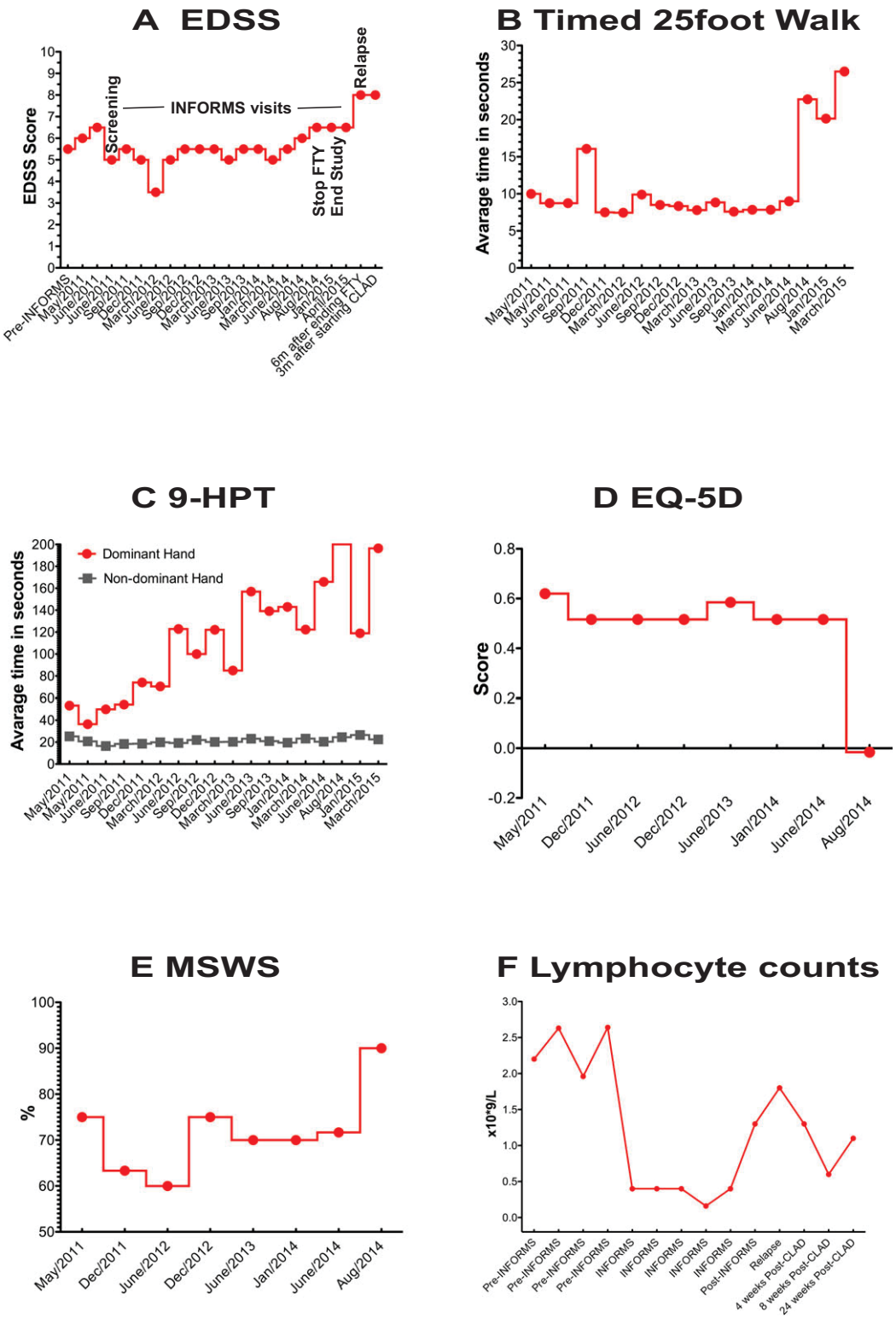

Figure 2. Neurological status during and after the INFORMS study and lymphocyte counts. (A) Expanded disability status scale (EDSS) pre- and post-INFORMS, and after relapse. (B) Timed 25-Foot walk (T25-FW) during INFORMS study. (C) Hand function during INFORMS assessed with 9-Hole Peg Test (9-HPT). (D) EQ-5D score during INFORMS study. (E) MS walking scale during INFORMS study. (F) Lymphocyte counts during INFORMS, pre- and post-Cladribine.

 © 2017 The Authors. *Annals of Clinical and Translational Neurology* published by Wiley Periodicals, Inc on behalf of American Neurological Association.

23289503, 2017, 7, Downloaded from https://onlinelibrary.wiley.com/doi/10.1002/acn3.410, Wiley Online Library on [29/11/2022]. See the Terms and Conditions (https://onlinelibrary.wiley.com/terms-and-conditions) on Wiley Online Library for rules of use; OA articles are governed by the applicable Creative Commons License

fingolimod effectively suppressed disease activity over the course of the study, and (2) that DMT, despite the lack of any licensed options, would have a reasonable likelihood of success.

Given the lack of licensed DMT we offered Cladribine, a purine analogue and effective B and T lymphocyte depleting drug for pwRMS,[10] as a convenient and safe option. In support of this decision we considered the evidence for Cladribine being effective in pwMS from previous phase III trials,[10,11] and our recent work demonstrating there is no short-term increase in the risk of cancer with Cladribine compared to licensed DMT.[12] Moreover, earlier phase II trials providing evidence of efficacy in pwPMS[13–15] the convenience of an induction treatment, and the availability of Cladribine as an off-label drug for people with hairy cell leukemia all played a role in this decision. Finally, Cladribine penetrates into the CNS,[16] which may be advantageous in pwPMS through treatment effect on meningeal B and T lymphocyte clusters described in *post mortem* samples of pwPMS.[17]

Evidence suggests Rituximab is effective in young pwPMS with active MRI scans. In the OLYMPUS trial of PPMS, Rituximab slowed disease deterioration in patients less than 51 years of age, and with Gd^+ lesions, suggesting a subgroup of pwPMS may well benefit from B cell depletion.[18] Rituximab has also been offered recently as an off-label rescue therapy in pwRRMS following rebound activity after cessation of fingolimod.[3] Moreover, the humanised anti-CD20 antibody Ocrelizumab has been successfully tested in a phase III trial of patients with PPMS.[19] However, Rituximab remains relatively expensive, and in our healthcare environment (NHS) would have required an individual funding application with (1) potential for delay and (2) likely rejection, based on recent experience. Further alternative DMTs, such as Mitoxantrone and Cyclophosphamide (both off-label in the UK), carry evidently more significant risks including malignancy and cardiotoxicity.[20,21]

We selected Cladribine for the following reasons: (1) class I evidence of efficacy of the active compound in people with relapsing MS[10,15,22]; (2) selective lymphocyte mechanism of action not requiring cell-proliferation and notably B cell targeting potential that appears to be associated with effective control of active MS[23,24]; (3) CNS penetration for peripheral and CNS immune cell inactivation and modulation[16,23]; (4) safety comparable or better than similarly effective, current treatments[12]; (5) known relative safety in people with advanced MS[15]; (6) induction therapy potential requiring only short courses of treatment[10] with rapid elimination from the body potentially allowing additional use of neuroprotection and symptomatic treatments without complications due to drug-drug interactions[23]; and importantly, (7) convenience for the patient with easy and rapid administration during brief hospital visits to our day case unit, and few monitoring needs compared to some of the current DMT. This will limit travel requirements for someone restricted to a wheelchair. We felt this list of advantages outweighs the use of alternatives, such as cyclophosphamide, that lack the weight of evidence of efficacy in phase III studies whilst evidently having significantly more side-effects.[25] Indeed based on the above issues, parenteral cladribine may have some practical and clinical advantages over currently licensed DMT and offers additional value via cost-effectiveness, due to its availability as a generic product (for hairy cell leukemia). The low price is an important factor for pwPMS to gaining access to DMT. In our healthcare system (NHS) it is not worth even considering treatment with licensed DMT a patient who does not fulfill the NHS criteria for treatment.

Our dosing scheme for Cladribine took into account comments by the European Medicines Agency in their withdrawal assessment of Cladribine tablets in 2010/11 regarding the risk of severe lymphopenia (http://www.ema.europa.eu/docs/en_GB/document_library/Application_withdrawal_assessment_report/2011/03/WC500104393.pdf). Based on 100% bioavailability of Cladribine s.c. (versus 42% or the oral prodrug) 60 mg Cladribine/year in an individual weighing less than 90 kg resembles bio-equivalence with the oral 3.5 mg/kg dose used in the pivotal CLARITY MS study.[10] Cladribine 10 mg s.c. was given on days 1, 2 and 3 in week one.[11] We then checked the total lymphocyte count in week 4 (Fig. 2F). After confirming the total lymphocyte count remained within normal limits we administered further doses Cladribine of 10 mg s.c. on days 1, 2 and 3 in week 5. No adverse effects were observed. Clinically, the patient improved to EDSS 7, with no disease activity detected on follow-up MRI. A second treatment cycle is planned 11 months after the first.

In conclusion, we report the case of a pwPMS who developed rebound disease after fingolimod cessation and partially recovered following Cladribine administration. Successful treatment in this case should encourage studies to more definitely investigate the effectiveness of immunosuppressive DMT in pwPMS. Based on its safety, convenience, and unique pharmacokinetics including CNS penetration Cladribine is a promising candidate DMT for pwPM.

Conflict of Interests

None considered to be relevant. **CAG:** Has nothing to declare. **AA** Has nothing to declare. **JM** Has nothing to declare. **BPT** has received compensations from various pharmaceutical companies including Roche, Teva,

© 2017 The Authors. *Annals of Clinical and Translational Neurology* published by Wiley Periodicals, Inc on behalf of American Neurological Association.

23289503, 2017, 7, Downloaded from https://onlinelibrary.wiley.com/doi/10.1002/acn3.410, Wiley Online Library on [29/11/2022]. See the Terms and Conditions (https://onlinelibrary.wiley.com/terms-and-conditions) on Wiley Online Library for rules of use; OA articles are governed by the applicable Creative Commons License

Novartis, Merck-Serono, Sanofi-Genzyme, and Biogen. **GG** has received fees for participation in advisory board for AbbVie Biotherapeutics, Biogen, Canbex, Ironwood, Novartis, Merck, Merck Serono, Roche, Sanofi Genzyme, Synthon, Teva and Vertex; speaker fees from AbbVie, Biogen, Bayer HealthCare, Genzyme, Merck Serono, Sanofi-Aventis and Teva. Research support from Biogen, Genzyme, Ironwood, Merck, Merck Serono and Novartis. **DB** is a founder and consultant to Canbex therapeutics and has received research funds from Canbex therapeutics, Sanofi-Genzyme and Takeda in the past 3 years. **KS:** PI of trials sponsored by Novartis, Roche, Teva, Medday. Involved in trials sponsored by Biogen, Genzyme, BIAL, Cytokinetics, Canbex. Speaking honoraria from, and/or served in an advisory role for, Biogen, Merck, Novartis, Roche, Teva. Supported for attendance of meetings by Genzyme, Merck and Novartis. Research grant support from Novartis, Biogen.

References

1. Lublin F, Miller DH, Freedman MS, et al. Oral fingolimod in primary progressive multiple sclerosis (INFORMS): a phase 3, randomised, double-blind, placebo-controlled trial. Lancet 2016;387:1075–1084.
2. Kim W, Zandoná M, Kim S-H, Kim H. Oral Disease-Modifying Therapies for Multiple Sclerosis [Internet]. Oral Disease-Modifying Therapies for Multiple Sclerosis 2015;11(1):9.Available from: https://doi.org/10.3988/jcn.2015.11.1.9
3. Hatcher SE, Waubant E, Nourbakhsh B, et al. Rebound Syndrome in Patients With Multiple Sclerosis After Cessation of Fingolimod Treatment. JAMA Neurol 2016;73:790–794.
4. Gündüz T, Kürtüncü M, Eraksoy M. Severe rebound after withdrawal of fingolimod treatment in patients with multiple sclerosis. Mult Scler Relat Disord 2017;11:1–3.
5. Alvarez-Gonzalez C, Allen-Philbey K, Mathews J, et al. Treating multiple sclerosis with cladribine. J Neurol Neurosurg Psychiatry 2016;87:e1.
6. Davion J-BB, Cambron M, Duhin E, et al. Two cases of relapses in primary progressive multiple sclerosis after fingolimod withdrawal. J Neurol 2016;263:1361–1363.
7. De Masi R, Accoto S, Orlando S, et al. Dramatic recovery of steroid-refractory relapsed multiple sclerosis following Fingolimod discontinuation using selective immune adsorption. BMC Neurol 2015;15:125.
8. Lassmann H, Brück W, Lucchinetti CF. The immunopathology of multiple sclerosis: an overview. Brain Pathol 2007;17:210–218.
9. Lublin FD. New multiple sclerosis phenotypic classification. Eur Neurol 2014;72(Suppl 1):1–5.
10. Giovannoni G, Comi G, Cook S, et al. CLARITY Study Group. A placebo-controlled trial of oral_cladribine_for relapsing multiple sclerosis. N Engl J Med 2010;362:416–426.
11. Leist TP, Comi G, Cree BA, et al. Effect of oral cladribine on time to conversion to clinically definite multiple sclerosis in patients with a first demyelinating event (ORACLE MS): a phase 3 randomised trial. Lancet Neurol 2014;13:257.
12. Pakpoor J, Disanto G, Altmann DR, et al. No evidence for higher risk of cancer in patients with multiple sclerosis taking cladribine. Neurol Neuroimmunol Neuroinflamm 2015;2:e158.
13. Sipe JC, Romine JS, Koziol JA, et al. Cladribine in treatment of chronic progressive multiple sclerosis. Lancet 1994;344:9–13.
14. Beutler E, Sipe JC, Romine JS, et al. The treatment of chronic progressive multiple sclerosis with cladribine. Proc Natl Acad Sci USA 1996;93:1716–1720.
15. Rice GP, Filippi M, Comi G. Cladribine and progressive MS: clinical and MRI outcomes of a multicenter controlled trial. Cladribine MRI Study Group. Neurology 2000;54:1145–1155.
16. Santana VM, Hurwitz CA, Blakley RL, et al. Complete hematologic remissions induced by 2-chlorodeoxyadenosine in children with newly diagnosed acute myeloid leukemia. Blood 1994;84:1237–1242.
17. Magliozzi R, Howell O, Vora A, et al. Meningeal B-cell follicles in secondary progressive multiple sclerosis associate with early onset of disease and severe cortical pathology. Brain 2007;130(Pt 4):1089–1104.
18. Hawker K, O'Connor P, Freedman MS, et al. Rituximab in patients with primary progressive multiple sclerosis: results of a randomized double-blind placebo-controlled multicenter trial. Ann Neurol 2009;66:460–471.
19. Fernandez O, Rodriguez-Antiguedad A, Olascoaga J, et al. Review of the novelties from the 31st ECTRIMS Congress, 2015, presented at the 8th Post-ECTRIMS meeting. Rev Neurol 2016;62:559–569.
20. Neuhaus O, Kieseier BC. Hartung H-PP immunosuppressive agents in multiple sclerosis. Neurotherapeutics 2007;4:654–660.
21. Buttmann M, Seuffert L, Mäder U, Toyka KV. Malignancies after mitoxantrone for multiple sclerosis: a retrospective cohort study. Neurology 2016;86:2203–2207.
22. Rotstein DL, Healy BC, Malik MT, et al. Evaluation of no evidence of disease activity in a 7-year longitudinal multiple sclerosis cohort. JAMA Neurol 2015;72:152–158.
23. Liliemark J. The clinical pharmacokinetics of cladribine. Clin Pharmacokinet 1997;32:120–131.
24. Baker D, Marta M, Pryce G, et al. Memory B Cells are Major Targets for Effective Immunotherapy in Relapsing Multiple Sclerosis. EBioMedicine 2017;16:41–50.
25. La Mantia L, Milanese C, Mascoli N, et al. Cyclophosphamide_for_multiple sclerosis. Cochrane Database Syst Rev 2007; 1:CD002819.

 © 2017 The Authors. *Annals of Clinical and Translational Neurology* published by Wiley Periodicals, Inc on behalf of American Neurological Association.

23289503, 2017, 7, Downloaded from https://onlinelibrary.wiley.com/doi/10.1002/acn3.410, Wiley Online Library on [29/11/2022]. See the Terms and Conditions (https://onlinelibrary.wiley.com/terms-and-conditions) on Wiley Online Library for rules of use; OA articles are governed by the applicable Creative Commons License

Supporting Information

Additional Supporting Information may be found online in the supporting information tab for this article:

Figure S1. (**A**) Baseline MRI of spinal cord showed T_2 lesions before entrance to INFORMS study; no gadolinium-enhancement study was performed. (**B**) Spinal cord MRI acquired within 1 week of deterioration showing T_2 lesions and Gd^+ on T_1.

© 2017 The Authors. *Annals of Clinical and Translational Neurology* published by Wiley Periodicals, Inc on behalf of American Neurological Association.

23289503, 2017, 7, Downloaded from https://onlinelibrary.wiley.com/doi/10.1002/acn3.410, Wiley Online Library on [29/11/2022]. See the Terms and Conditions (https://onlinelibrary.wiley.com/terms-and-conditions) on Wiley Online Library for rules of use; OA articles are governed by the applicable Creative Commons License