THE GASTROINTESTINAL EPITHELIUM AND ITS AUTOCHTHONOUS BACTERIAL FLORA*

By DWAYNE C. SAVAGE, Ph.D., RENÉ DUBOS, Ph.D., and RUSSELL W. SCHAEDLER, M.D.

(*From The Rockefeller University, New York 10021*)

Plates 9–11

(Received for publication 17 July 1967)

Downloaded from http://rupress.org/jem/article-pdf/127/1/67/1392320/67.pdf by guest on 02 May 2023

Comparative studies of the gastrointestinal microflora in various mouse colonies have been carried out for several years in our laboratory. Some of the findings, presented in earlier publications (1–5), can be summarized as follows:

(*a*) A few bacterial species reach high population levels in all mouse colonies tested, irrespective of the condition of husbandry, except in severe pathological states and of course in the germfree state. These bacterial species are anaerobic and persist throughout the whole life-span of the animal. In view of the general occurrence of these bacterial species, we have suggested that they evolve with their mouse host and constitute, therefore, its autochthonous flora (1).

(*b*) Whatever the genetic constitution of the animals, the composition of their so-called "normal flora" (i.e., the flora characteristic of the mouse colony) differs qualitatively from one colony to the other. It has been found, in particular, that the NCS and NCS-D mouse colonies, produced and maintained under protected conditions in our laboratory, have a much simpler microflora than that of the Standard Swiss (SS) colony from which they were derived. The bacterial flora of the gastrointestinal tract of the NCS and NCS-D colonies consists chiefly of the autochthonous species, in the sense described above (1–3).

(*c*) The various bacterial species, especially those of the autochthonous flora, do not occur randomly in the gastrointestinal tract, but rather exhibit marked selectivity in their anatomical localization. For example, autochthonous lactobacilli are extremely numerous in the stomach, where they exist as a well-organized layer on the mucosal epithelium. In contrast, the species of Bacteroides and fusiform bacteria do not occur in the stomach, but are extremely numerous in the large intestine (1, 3, 4).

(*d*) Under normal conditions, the various bacterial species colonize the gastrointestinal tract at different periods after birth, according to a sequence characteristic of each particular part of the tract (3, 5).

The conclusions outlined above were chiefly derived from the results of quantitative bacteriological analysis. In the present study, an effort was made to correlate these and other bacteriological findings with histological phenomena

* The studies were supported (in part) by Public Health Service Grant No. AI-05676.

CELGENE 2047
APOTEX v. CELGENE
IPR2023-00512

that occur in the various areas of the gastrointestinal tract at each stage of their colonization by the various bacterial species of the bacterial flora.

Materials and Methods

Mice.—The origin and characteristics of the NCS and NCS-D mouse colonies have been described in references 3 and 6. Other mice used were from the ordinary CFW colony of Carworth Farms (New City, N.Y.) and the specified pathogen-free, Caesarean-Originated, Barrier-Sustained (COBS) colony of the Charles River Farms Breeding Laboratories (Wilmington, Mass.).

In all experiments, the mice were given acidified water and commercial pellets essentially free of living microorganisms (see reference 6). Gravid females from the various colonies were maintained in individual cages containing wood shavings for bedding. The date of birth of the young was carefully recorded so that the experiments could be conducted with animals of precisely known age.

Preparation of Specimens for Bacteriological Examination.—Animals were sacrificed under chloroform anesthesia; the organs, always with their contents intact, were weighed and then homogenized in Teflon grinders in 5 ml of sterile charcoal water (2). Studies were carried out with the entire digestive canal from the esophagus to the rectum, or the whole stomachs, or segments of the small and large intestines.

Bacteriological Culture Techniques.—The homogenates described above were diluted in charcoal water in 10-fold steps. Calibrated loopfuls of each dilution were then spread on the surface of various selective agar media. The selective media and conditions of incubation used for the recovery and enumeration of lactobacilli, coliforms, enterococci, and anaerobes have been described elsewhere (2, 5).

Histological Techniques.—Segments of the intestines or the whole stomach with contents intact were frozen in a 2% solution of methyl cellulose (15 centipoise) in 0.15 M saline on the freezing shelf of a microtome-cryostat (International Equipment Co., Needham Heights, Mass.). Sections of the frozen tissues, cut at either 4 or 8 μ, were fixed for 60 sec in absolute methyl alcohol, and stained with hematoxylin and eosin, periodic acid–Schiff, or with a modified tissue Gram stain (7).

RESULTS

The Esophagus and Stomach.—As demonstrated previously, the bacterial flora that can be cultured with present techniques from the stomachs of NCS and NCS-D mice consists almost exclusively of lactobacilli and Group N streptococci (1, 3). These bacteria colonize the stomachs of infant NCS and NCS-D mice on the very first day after birth, and within 7 or 8 days reach high population levels that persist throughout normal life. In the present study, it was found that the stomachs of CFW and COBS mice also harbor populations of lactobacilli and Group N streptococci. These populations exist at the same levels and develop in infants in the same manner as that reported for the NCS mice. In addition, it was found that lactobacilli could also be consistently cultured in significant numbers from the esophagi of both infant and adult mice from the four colonies (Table I).

These findings were extended and their significance made apparent by histological studies. In histological sections, as early as the 2nd or 3rd day after birth, Gram-positive rods and streptococci could be seen in layers on the strati-

Downloaded from http://rupress.org/jem/article-pdf/127/1/67/1392320/67.pdf by guest on 02 May 2023

fied squamous epithelium of the nonglandular mucosa of the stomachs (Fig. 1) and the distal one-third of the esophagi of mice from the four colonies. In the stomach, the bacterial layer was confined to the keratinized epithelium and ended abruptly at the cardiac antrum. By the 7th to 10th day after birth, the layer was almost as well-developed as in the adult stomach (Fig. 2).

TABLE I

*Bacterial Flora of the Stomach and Esophagus of Infant and Adult NCS, NCS-D, CFW, and COBS Mice**

	Mice	Lactobacilli and Gr. N streptococci	Coliforms‡	Enterococci	Anaerobes§
Esophagus	NCS	10^7	±	±	±
	NCS-D	10^7	±	±	±
	CFW	10^7	±	±	±
	COBS	10^7	±	±	±
Stomach	NCS	10^9	±	±	±
	NCS-D	10^9	±	±	±
	CFW	10^9	±	±	±
	COBS	10^9	±	±	±

* The data are recorded as the average of the number of bacteria per gram of fresh tissue; 15 to 20 animals per group. The sign ± indicates occasional culture of very low numbers of bacteria that are probably not resident in the stomach or esophagus, but are passing through after being ingested during coprophagy. In infant mice, the lactobacilli and Group N streptococci become established in the gut within the first day after birth and increase to the levels shown by the end of the first week of life.

‡ The coliforms are predominantly slow fermenters of lactose (SLF) in NCS-D and NCS mice, but the latter also contain substantial numbers of lactose fermenters. Lactose fermenting coliforms are the predominant coliform flora in CFW and COBS mice.

§ The anaerobes include bacteroides and clostridia which can be cultured on agar media and also fusiform-shaped bacteria which have not yet been quantitatively cultured. On the proper anaerobic agar media, bacteroides constitute the most numerous organisms recovered from the mice of the various colonies tested; clostridia are recovered occasionally from the NCS and frequently from the CFW and COBS mice. From the 12th or 13th day after birth, fusiform bacteria outnumber all other bacteria, by a factor of 100–1000, as seen in the special histological sections of the cecums and colons of mice of the four colonies.

In a previous study, it was found, with NCS mice, that just as many lactobacilli and streptococci could be cultured from homogenates of the stomach mucosa washed three times with saline, as from the luminal contents and the washings of the mucosa (1). In the present histological study, few bacteria were seen free in the lumen, whereas the mucosal layers contained large numbers of Gram-positive rods and cocci (Fig. 3). These facts strongly indicated that the bacteria in the layers were lactobacilli and anaerobic streptococci.

The Small Intestine.—The types of bacteria that could be cultured from the

Downloaded from http://rupress.org/jem/article-pdf/127/1/67/1392320/67.pdf by guest on 02 May 2023

small intestines of the mice from the four colonies were essentially the same as were found in the stomach (Table II and reference 1). Again, lactobacilli and anaerobic streptococci appeared early and predominated throughout the lives of the animals. Histological views of an infant duodenum (Fig. 4) and an infant ileum (Fig. 5) are shown to illustrate the location and nature of the bacteria. As in the stomach, the bacteria that could be observed in the sections were Gram-positive rods and streptococci. In the small intestine, however, these bacteria were confined to the lumen; no layering on the epithelium was seen. In adults, the ileum had a more extensive bacterial population than any other area of the small intestine; but that population was composed only of Gram-positive bacteria.

TABLE II

*Bacterial Flora of the Small Intestines of Infant and Adult NCS, NCS-D, CFW, and COBS Mice**

Segment of intestine‡	Lactobacilli and Group N streptococci	Coliforms§	Enterococci	Anaerobes§
Duodenum	10^7	±	±	±
Jejunum	10^8	±	±	±
Ileum	10^9	±	±	±

* See the first footnote in Table I for the method of recording the data.

‡ The small intestine was arbitrarily divided into three segments. The duodenum was taken as a 1.5–3 cm piece just distal to the stomach; the jejunum and ileum were taken as the proximal and distal halves respectively of the remainder.

§ See the footnotes (‡, §) in Table I for a discussion of the various types of coliforms and anaerobes recovered.

The Cecum and the Colon.—It was reported in references 1 and 5 that the cecum and the colon of adult NCS mice contain a rich and varied bacterial flora, and that the various types of bacteria in this mixed population become established according to a certain time sequence in infants. These findings were confirmed in the present study for the NCS and NCS-D mice, and were extended to the CFW and COBS mice. During this sequential colonization, the period from about the 10th to the 18th day after birth was a time of profound rearrangement of the bacterial populations, as can be observed in Table III. The histological examination of the cecum and the colon made during that period provided further evidence of such readjustments.

As illustrated in Figs. 6–9, histological studies of the colon showed that the contents of the lumen contained mostly Gram-positive rods and streptococci until the infant mice were about 10 days old; the results were similar for the cecum. Around that time, microcolonies of tiny Gram-negative rods with rounded ends, and Gram-positive cocci, usually in pairs, appeared in the mucus

Downloaded from http://rupress.org/jem/article-pdf/127/1/67/1392320/67.pdf by guest on 02 May 2023

TABLE III

*Development of the Bacterial Flora in the Cecums and Large Intestines of NCS, NCS-D, CFW, and COBS Mice**

		Age of mice in days										
		2	4	6	8	10	12	14	16	18	20	60
Cecum	Lactobacilli and streptococci (Gr. N)	N	N	4	9	9	9	9	9	9	9	9
	Coliforms‡	N	N	N	N	±	6	5	5	5	4	4
	Enterococci	N	N	N	N	3	10	7	6	6	4	4
	Anaerobes‡	N(−)	N(−)	N(−)	N(−)	N(−)	6(1+)	8(2+)	9(3+)	10(3+)	10(3+)	10(3+)
Large intestine	Lactobacilli and streptococci (Gr. N)	±	4	8	9	9	9	9	9	9	9	9
	Coliforms‡	N	N	N	4	9	10	9	9	9	3	4
	Enterococci	N	N	N	6	9	9	9	8	8	±	4
	Anaerobes‡	N(−)	N(−)	N(−)	N(−)	±(−)	9(1+)	10(2+)	10(3+)	10(3+)	10(3+)	10(3+)

* The data are recorded as the average of the $\log_{10}$ of the numbers of the bacteria per gram of fresh tissue; 15–20 animals per group. The sign ± indicates bacteria infrequently cultured in low numbers; N, no bacteria recovered. The parentheses indicate the results of determinations from histological sections of the amounts of fusiform bacteria present; (1+) to (3+), small to enormous numbers; (±), infrequently observed in small numbers; (−), not observed.

‡ See the footnotes (‡, §) in Table I for a discussion of the various types of coliforms and anaerobes recovered.

Downloaded from http://rupress.org/jem/article-pdf/127/1/67/1392320/67.pdf by guest on 02 May 2023

near the mucosa. By the 12th day after birth, however, long, thin Gram-variable rods with tapering ends appeared in the mucous layer among the Gram-positive cocci and small Gram-negative rods. In the next few days, the numbers of the fusiform rods increased, and by the 15th day after birth they were so numerous that the other bacteria had either been replaced or were no longer detectable among the dense fusiform population. In the colon of the adult, these tapered rods formed a densely packed layer in the mucus on the epithelium, as can be seen in Figs. 10–15. Similar but thinner layers were observed in the cecum of the adult. These bacterial layers effectively separated the epithelium from the mass of mixed bacterial types and digesta in the center of the lumen.

Although both bacteroides and clostridia could be cultured as early as 12 days after birth from the cecums and colons of mice of the four colonies, these culturable organisms could not be identified as the fusiform bacteria in the mucous layers. Since the latter microorganisms do not grow readily in vitro, meaningful viable counts of them have not yet been obtained. On the basis of histological observations, however, fusiform bacteria clearly outnumber by a factor of as much as 1000 all other bacteria visible in the sections; quantitatively, therefore, they appear to predominate in the bacterial population of the cecum and large bowel in normal healthy mice.

DISCUSSION

Histological techniques have rarely been applied to the study of the normal flora in situ in the gastrointestinal tract. More importantly, perhaps, the usual techniques are not suited to the recognition of the intimate kind of associations that become established between particular strains of microorganisms and certain histological structures. In the present study, we were particularly anxious not to dislodge the bacteria from the mucous layer in which some of them appeared to be embedded. The technical modifications described in this paper were designed to meet this desideratum.

Initially, the techniques were employed to examine the development and characteristics of a layer of lactobacilli and streptococci on the mucosa of the stomachs of mice (1). It was found that this bacterial layer developed early in life, indeed, within one or two days after birth, and was confined to the nonglandular epithelium of the stomach. In addition, a similar bacterial layer was also seen on the distal esophageal epithelium.

In the mouse, both the nonglandular epithelium of the stomach and the esophageal epithelium are of the stratified squamous type. It is well known that such epithelium lines the esophageal mucosae of animals, but it is less widely known that it is present in certain portions of the stomachs of a wide variety of mammals. This is the case for mice, rats, guinea pigs, rabbits, and hamsters (personal observations), solipeds such as horses, camels, and swine, and all ruminants (8).

Downloaded from http://rupress.org/jem/article-pdf/127/1/67/1392320/67.pdf by guest on 02 May 2023

The widespread existence of squamous epithelium in stomachs makes it very likely that bacterial layers similar to that described in mice exist in many types of animals; and indeed, such layers have already been seen in histological sections of the stomachs of rats (personal observations and reference 9) and guinea pigs (personal observations). Moreover, lactobacilli have been cultured from the stomachs of swine (1) and horses (10). It can be anticipated, therefore, that such layers will be found in the stomachs of many animal types when the proper techniques are employed. Moreover, since the esophageal mucosa of all types of mammals including humans is lined with squamous epithelium, bacterial layers may also be found in those areas in many types of animals and possibly in humans as well.

Histological techniques also revealed the presence of fusiform bacteria embedded in the mucous layers on the epithelia of the cecums and colons of mice over the age of 12 days. Approximately 3 days before the appearance of the fusiform rods, however, microcolonies of Gram-positive cocci in pairs and small Gram-negative rods could be observed in the same location. Since the populations of enterococci and coliforms increased markedly on the 9th or 10th day after birth (Table III and reference 5), it is possible that the microcolonies in the mucous layer consisted of these bacteria. It is of interest that the coliforms and enterococci persisted at high levels until the layers of fusiform bacteria were completely established. An investigation is under way to test the hypothesis that their disappearance is related to the multiplication of the fusiform bacteria.

It must be emphasized again that the various types of fusiform rods seen embedded in the mucus in dense layers are difficult to culture in vitro. They appear to be strict anaerobes and to have exacting nutritional requirements. Some strains have been cultured in this laboratory by using anaerobic liquid media (unpublished observations). These bacteriological difficulties have made it impossible, so far, to obtain meaningful viable counts of these tapered rods. Nevertheless, so many of them were seen in the histological sections that it appears legitimate to conclude that they outnumber all other bacteria in the cecum and the colon by a factor of 100–1000. Moreover, the unique location of these bacteria in the mucous layer suggests that they are important ecological components of the gut microflora of the mouse. For this reason, all studies of the digestive microflora should include a detailed examination for these fusiform bacterial populations.

CONCLUSIONS AND SUMMARY

Colonization of the gastrointestinal tract by bacteria of the normal flora was followed by bacteriological and special histological techniques in mice from several colonies. These histological techniques were designed to preserve the intimate associations that become established between particular strains of microorganisms and the epithelium of the mucosa of certain areas of the gut.

Downloaded from http://rupress.org/jem/article-pdf/127/1/67/1392320/67.pdf by guest on 02 May 2023

The findings were as follows:

1. The various strains of bacteria of the normal flora became established in the different areas of the guts of infant mice according to a definite time sequence.

2. The first types of bacteria that could be cultured from the gut were lactobacilli and Group N streptococci. Within the first day after birth, these bacteria colonized the entire digestive tract and formed layers on the stratified squamous epithelium of the nonsecreting portion of the stomach and of the distal esophagus.

3. The bacterial types that appeared next were coliforms and enterococci. From about the 9th to the 18th day after birth, these bacteria could be cultured in extremely high numbers from the cecum and the colon. Histological sections of those organs taken during the first 2 or 3 days of that interval revealed microcolonies of Gram-positive cocci in pairs and tiny Gram-negative rods embedded in the mucous layer of the epithelium. The microcolonies were well separated from the mixture of digesta and bacteria that occupied the center of the lumen; they may have consisted of the coliforms and enterococci mentioned above; but this possibility remains to be proved.

4. Histological sections also revealed that, at about the 12th day after birth, long, thin Gram-variable rods with tapering ends were present, side by side, with the small Gram-negative rods and Gram-positive cocci in the mucous layer. By the 15th day after birth, the fusiform bacteria formed thick layers in the mucus, and seemed to be the only bacteria remaining in that location. It has not yet been possible to enumerate these tapered rods by culture methods, but as judged by visual appearances in the histological sections, they seemed to outnumber all other bacteria in the cecum and the colon by a factor of as much as 1000.

It must be stressed that these bacterial layers are readily disrupted and even washed away by conventional histological techniques; their discovery was largely due to the use of the special histological techniques described in the text.

The bacteriological and histological findings described here constitute further evidence for the hypothesis that symbiotic associations exist between microorganisms and animals, and that a very large percentage of the bacteria in the gastrointestinal tract constitutes a true autochthonous flora.

The constant occurrence of several distinct associations of bacteria with the special histological structures of the animal host renders obsolete the notion that the intestine constitutes a chemostat in which the bacterial populations are randomly mixed. For a full understanding of the ecology of the normal microflora, it is necessary to think of body surfaces as distinct microenvironments in which virtually pure cultures of a few species of microorganisms interact with their host and the adjacent microbial populations. Experiments based on this hypothesis are admittedly difficult to design, but on the other

Downloaded from http://rupress.org/jem/article-pdf/127/1/67/1392320/67.pdf by guest on 02 May 2023

hand studies based on the assumption that microorganisms exist as mixtures in the gastrointestinal tract will be only of limited value and may often be misleading.

The excellent technical assistance of Mrs. Katherine Toula Davis is gratefully acknowledged.

BIBLIOGRAPHY

1. Dubos, R., R. W. Schaedler, R. Costello, and P. Hoet. 1965. Indigenous, normal, and autochthonous flora of the gastrointestinal tract. *J. Exptl. Med.* **122**:67.
2. Schaedler, R. W., and R. J. Dubos. 1962. The fecal flora of various strains of mice. Its bearing on their susceptibility to endotoxin. *J. Exptl. Med.* **115**:1149.
3. Mushin, R., and R. Dubos. 1965. Colonization of the mouse intestine with *Escherichia coli*. *J. Exptl. Med.* **122**:745.
4. Schaedler, R. W., R. Dubos, and R. Costello. 1965. Association of germfree mice with bacteria isolated from normal mice, *J. Exptl. Med.* **122**:77.
5. Schaedler, R. W., R. Dubos, and R. Costello. 1965. The development of the bacterial flora in the gastrointestinal tract of mice. *J. Exptl. Med.* **122**:59.
6. Dubos, R. J., and R. W. Schaedler. 1960. The effect of the intestinal flora on the growth rate of mice, and on their susceptibility to experimental infections. *J. Exptl. Med.* **111**:407.
7. Brown, J. H., and L. Brenn. 1931. A method for the differential staining of Gram-positive and Gram-negative bacteria in tissue sections. *Bull. Johns Hopkins Hosp.* **48**:69.
8. Trautmann, A., and J. Fiebiger. 1957. Fundamentals of the Histology of Domestic Animals. Comstock Publishing Associates, Ithaca. 180.
9. Brownlee, A., and W. Moss. 1961. The influence of diet on lactobacilli in the stomach of the rat. *J. Pathol. Bacteriol.* **82**:513.
10. Alexander, F., and M. E. Davies. 1963. Production and fermentation of lactate by the bacteria in the alimentary canal of the horse and pig. *J. Comp. Pathol. Therap.* **73**:1.

Downloaded from http://rupress.org/jem/article-pdf/127/1/67/1392320/67.pdf by guest on 02 May 2023

EXPLANATION OF PLATES

PLATE 9

FIGS. 1–5. Gram-stained tissue sections showing Gram-positive bacteria in the stomachs and small intestines of mice. In the stomachs, the bacteria form layers on the stratified squamous epithelium of the nonglandular mucosa. These layers of bacteria stop abruptly at the cardiac antrum of the stomachs. In the small intestine, the bacteria lie free in the lumen.

FIG. 1. Stomach, infant mouse, the bacteria are the most darkly stained material to the upper left, glandular mucosa is to the right. × 400.

FIG. 2. Stomach, adult mouse, the bacteria are the most darkly stained material to the right, the glandular mucosa is to the left, the cardiac antrum is the large fold of tissue in the center. × 40.

FIG. 3. Stomach, adult mouse, the bacteria are the darkly stained rods lying in close association with the keratinized epithelium. × 600.

FIG. 4. Duodenum, infant mouse, the bacteria are the darkly stained rods and cocci to the right. × 860.

FIG. 5. Ileum, infant mouse, the bacteria are the darkly stained rods to the right × 860.

Downloaded from http://rupress.org/jem/article-pdf/127/1/67/1392320/67.pdf by guest on 02 May 2023

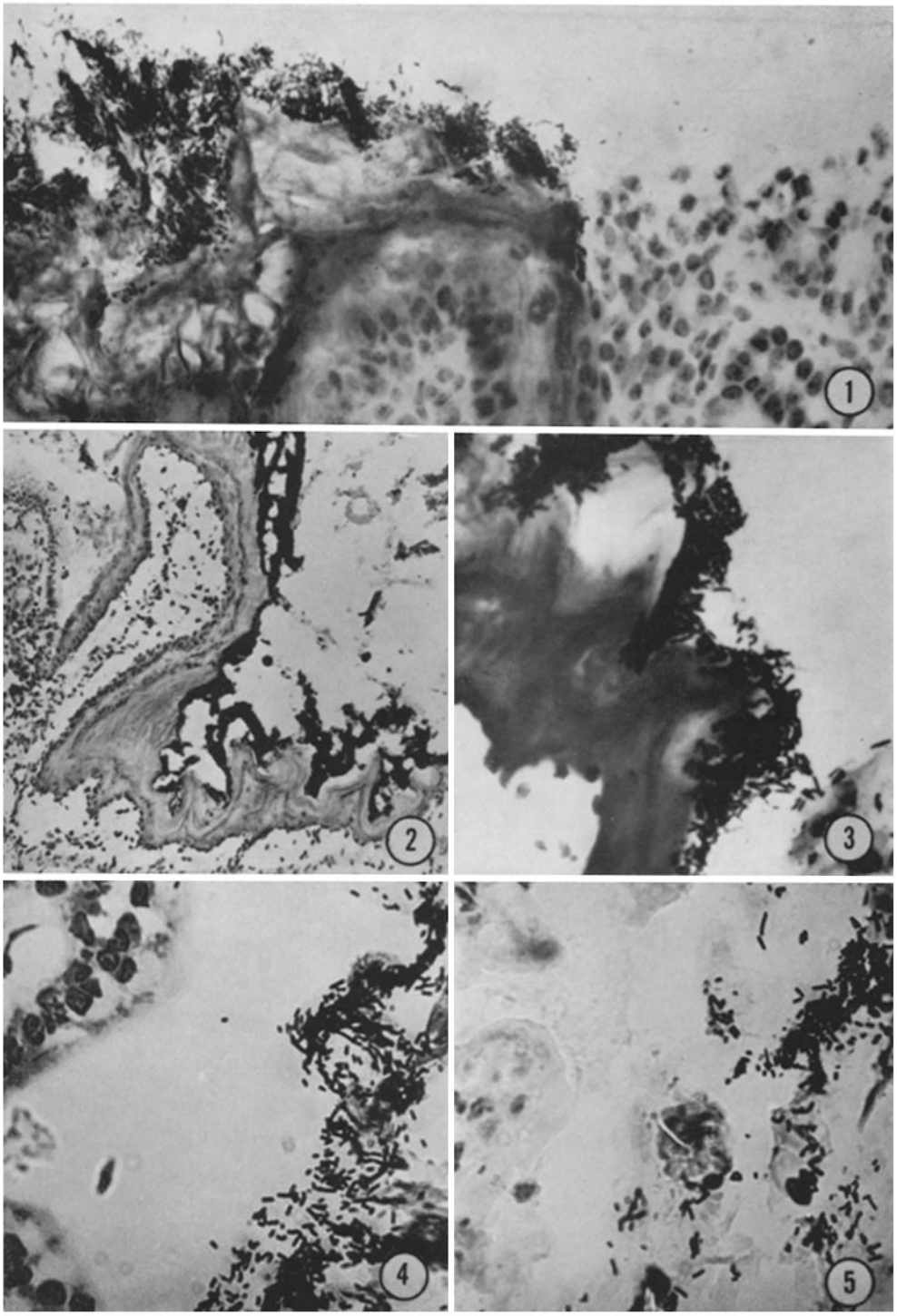

(Savage et al.: Gastrointestinal epithelium and autochthonous flora)

Downloaded from http://rupress.org/jem/article-pdf/127/1/67/1392320/67.pdf by guest on 02 May 2023

PLATE 10

FIGS. 6–9. Gram-stained tissue sections showing bacterial colonization of the colon of infant mice.

FIG. 6. 4 day old; the bacteria are almost all Gram-positive and appear as a darkly stained mass in the center of the lumen (upper right) well separated from the mucosa (lower left) by mucus. × 400.

FIG. 7. 10 day old; the bacteria, mostly Gram-positive, are seen again as a darkly stained mass in the center of the lumen (upper right), but the mucus between the bacterial mass and the mucosa (lower right) now contains microcolonies of small Gram-negative rods and Gram-positive cocci in pairs. × 400.

FIG. 8. 12 day old; again a mass of Gram-positive (and at this time also Gram-negative) bacteria is seen in the center of the lumen (upper right), but now the mucus near the mucosa contains long, tapered Gram-variable rods in addition to the Gram-negative rods and Gram-positive cocci shown in Fig. 7. × 400.

FIG. 9. 15 day old; a thick layer of Gram-variable fusiform rods separates the mucosa from the mass of Gram-positive and Gram-negative bacteria and digesta in the center of the lumen (upper right). × 400.

Downloaded from http://rupress.org/jem/article-pdf/127/1/67/1392320/67.pdf by guest on 02 May 2023

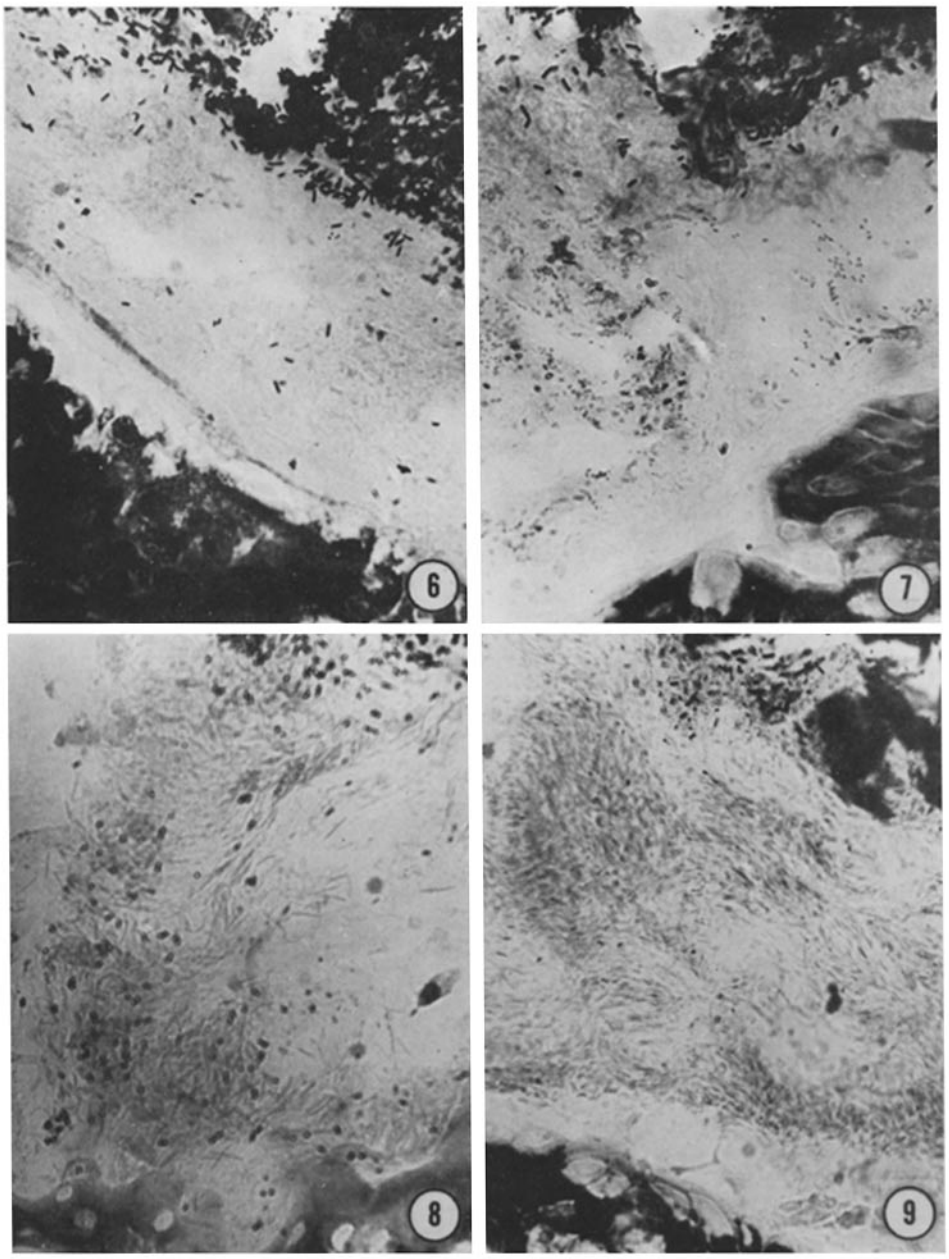

(Savage et al.: Gastrointestinal epithelium and autochthonous flora)

Downloaded from http://rupress.org/jem/article-pdf/127/1/67/1392320/67.pdf by guest on 02 May 2023

PLATE 11

FIGS. 10–15. Histological sections showing appearance of layers of Gram-variable fusiform bacteria in the colons of adult mice. Several views are shown to illustrate that the layers of bacteria occur in slightly different forms, probably due to drying of the tissue sections during preparation.

FIG. 10. Layer of fusiform bacteria is seen as a diffuse, predominantly Gram-negative (pink) layer between the epithelium and a mass of Gram-positive (black) and Gram-negative bacteria and debris in the center of the lumen at the top right of the photo. Gram strain; original magnification × 160, present magnification × 611.

FIG. 11. A preparation similar to that illustrated in Fig. 10 but in which the layer of fusiform bacteria takes a somewhat different appearance. Gram stain; original magnification × 160, present magnification × 611.

FIG. 12. Another preparation similar to those illustrated in Figs. 10 and 11 showing another appearance of the fusiform layer. Gram stain; original magnification × 160, present magnification × 611.

FIG. 13. Same preparation as Fig. 12, higher magnification. Gram stain; original magnification × 400, present magnification × 1528.

FIG. 14. Characteristic appearance of fusiform rods embedded in mucus on epithelium in layers such as are illustrated in Figs. 10–13. Periodic acid–Schiff; original magnification × 1000, present magnification × 3820.

FIG. 15. Another view similar to that shown in Fig. 14, showing the density of packing of the fusiform bacteria in the mucus on the epithelium. Periodic acid–Schiff; original magnification × 1000, present magnification × 3820.

Downloaded from http://rupress.org/jem/article-pdf/127/1/67/1392320/67.pdf by guest on 02 May 2023

10

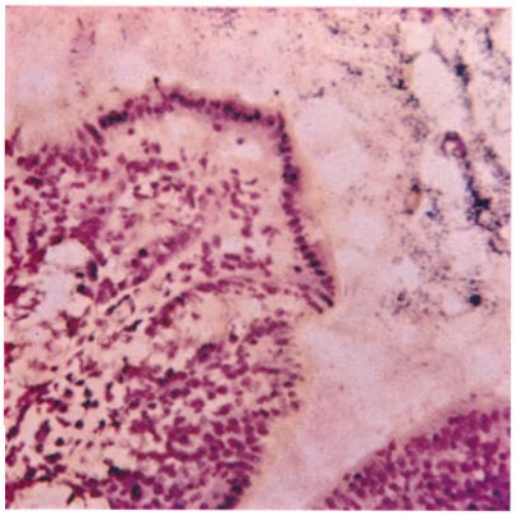

11

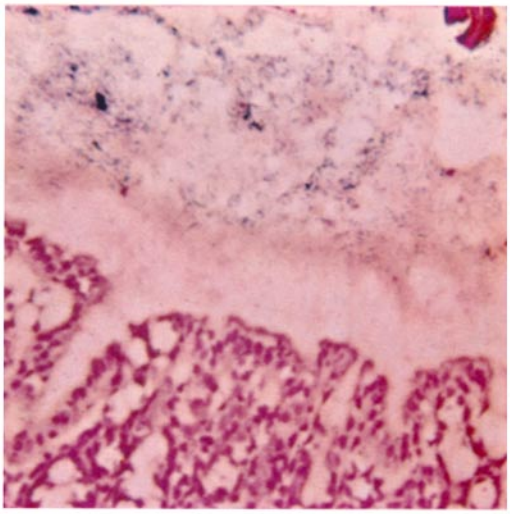

12

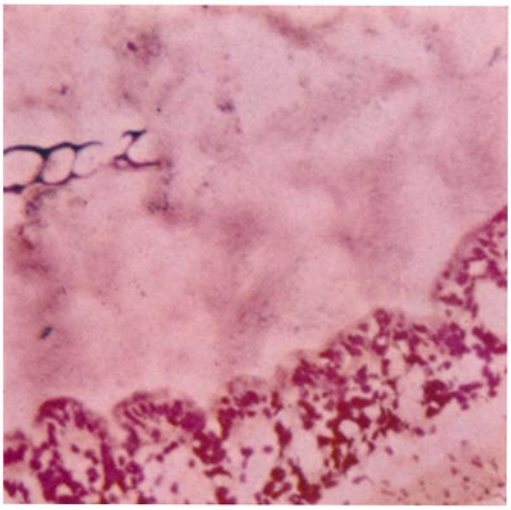

13

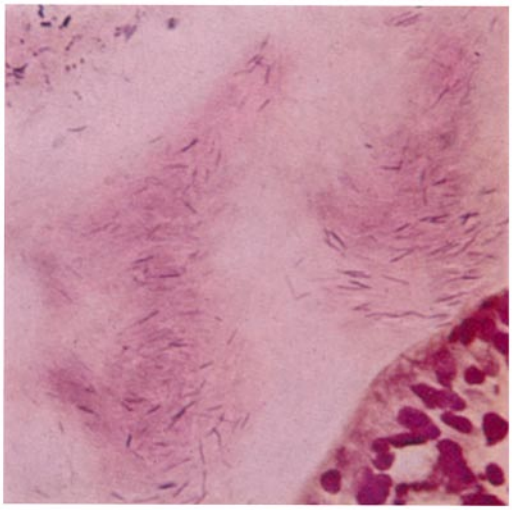

14

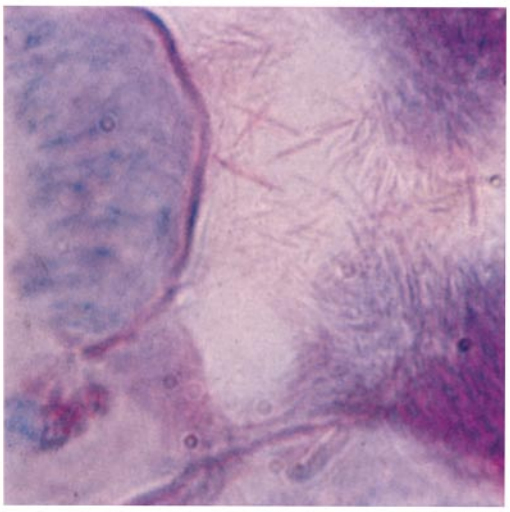

15

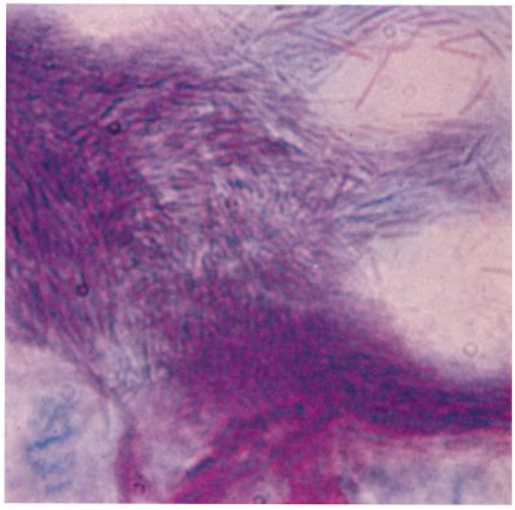

(Savage et al.: Gastrointestinal epithelium and autochthonous flora)

Downloaded from http://rupress.org/jem/article-pdf/127/1/67/1392320/67.pdf by guest on 02 May 2023