British Journal of Haematology, 1989, 72, 467–474

Case Reports

5-AZACYTIDINE TREATMENT IN A β^{o}-THALASSAEMIC PATIENT UNABLE TO BE TRANSFUSED DUE TO MULTIPLE ALLOANTIBODIES

We report here on a patient with homozygous beta°-thalassaemia of known molecular genotype who survived without need for transfusion until age 11. Red cells were then given because of severe anaemia, pneumonia and congestive heart failure. Splenectomy was performed and he did well until age 14, when he began an elective hypertransfusion regimen. He experienced a catastrophic haemolytic transfusion reaction and was found to have anti-E, c, Jk^{b}, Fy^{b}, s and Kell antibodies, as well as a panagglutinin with H and I reactivity (Giblett *et al.* 1965). No compatible blood could be found thereafter, but the patient remained relatively well with a haemoglobin concentration ranging from 6·0 to 9·0 g/dl.

At age 29 he was evaluated for iron overload due primarily to hyperabsorption. Remarkable marrow hyperexpansion was evident, especially in the ribs as revealed by chest X-ray (Fig 1A). He had evidence of mild end organ damage, and iron was chelated with desferrioxamine over the next several years; liver iron, as measured non-invasively, fell to 255 μg/g wet liver, within the normal range.

At age 36 the patient developed exercise intolerance and was found to have right-sided heart failure and hypoxaemia. Cardiac catheterization revealed normal wall motion, a cardiac output of 18 l/min, and a mean pulmonary artery pressure of 55 mm. No intracardiac or intrapulmonary shunts were present, but massive peripheral shunting in his abnormally expanded marrow space (Fig 1A) was postulated to account for his high cardiac output and pulmonary hypertension. Pulmonary function tests revealed a profound restrictive defect also contributing to his hypoxaemia.

By age 38 the patient was severely incapacitated despite optimal supportive care. On physical examination he had severe cachexia, signs of right-sided heart failure, and hepatomegaly. The haemoglobin concentration was 6·2 g/dl and the reticulocyte count 3·2%. A trial of 5-azacytidine was begun. Four separate courses were given (Fig 1C): after the first two intravenous courses of 2 mg/kg/d for 5 d, his haemoglobin recorded a maximum of 9·2 g/dl; his weight increased 1·5 kg, his oxygen requirements decreased, and he reported increased exercise tolerance. No significant decreases in white blood cell or platelet counts occurred. An oral course of 5-azacytidine 2 mg p.o. three times a day given with tetrahydrouridine was ineffective and his haemoglobin fell. He experienced a spontaneous rib fracture while stretching. His cardiopulmonary function continued to deteriorate, despite improvement of his Hb concentration after a third i.v. course of 5-azacytidine. He became progressively more hypoxaemic and died of respiratory failure.

This patient illustrates the complexity of classification of the severe beta thalassaemia syndromes. Genetically he was homozygous for two beta° alleles, and ultimately he experienced major complications characteristic of the untransfused thalassaemia major syndrome. However, he survived for over two decades without transfusion, and indeed often had a Hb concentration consistent with the classification of thalassaemia intermedia. Ultimately severe anaemia and progressive lung disease due to marrow expansion (Fig 1A) led to symptomatic deterioration and prompted a trial of 5-azacytidine.

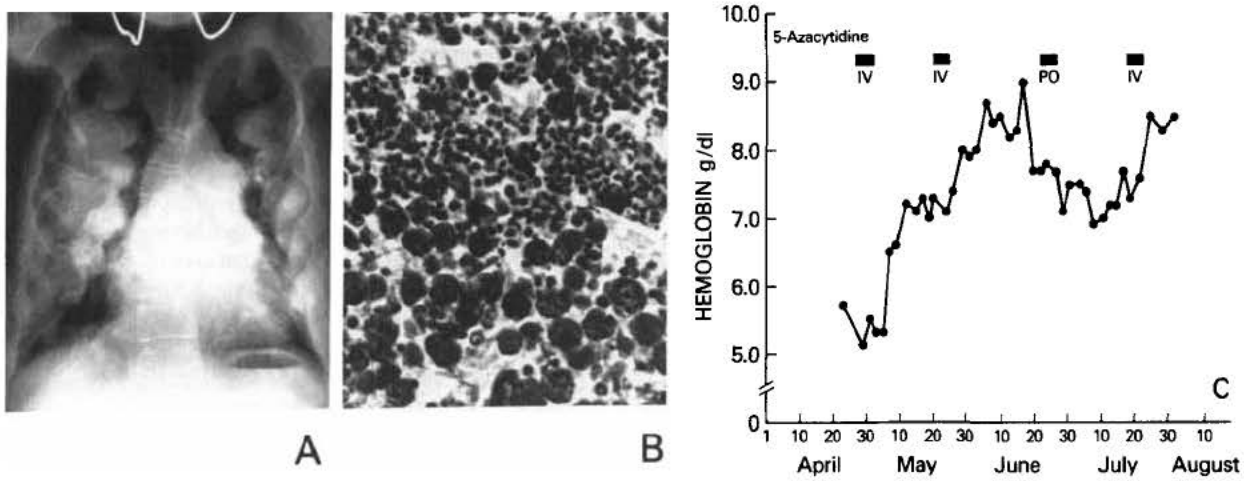

Fig 1. (A) Chest roentgenogram obtained at age 29. (B) 500 × magnification of rib bone marrow obtained at autopsy, stained with Periodic-acid Schiff. (C) Haemoglobin levels during the 4-month period described. Solid bars above the graph denote administration of 5-azacytidine.

CELGENE 2079
APOTEX v. CELGENE
IPR2023-00512

5-Azacytidine has been shown to increase HbF synthesis and partially correct anaemia in thalassaemic individuals, while hydroxyurea, another agent that increases HbF synthesis, has been less effective (Ley *et al.* 1982, 1983). The potential carcinogenicity of 5-azacytidine has prohibited its use in patients for whom other therapy is feasible. In this patient we hoped that 5-azacytidine would increase the percentage of erythroblasts making significant amounts of gamma chains and thereby diminish ineffective erythropoiesis. The regimen chosen was that shown to be most effective in earlier studies, namely continuous intravenous infusion over 5 d (Nienhuis *et al.* 1985). Dramatic increases in Hb concentration occurred at times consistent with effects of 5-azacytidine (Fig 1C). Our experience with this patient suggests that 5-azacytidine may be useful in severely anaemic thalassaemic individuals in whom transfusions are contraindicated.

Unfortunately, by the time this patient received 5-azacytidine his cardiopulmonary deterioration proved irreversible, despite his promising haematologic response. Autopsy revealed massive expansion of the marrow space, with marked thickening of the ribs and resultant contracted lung volumes. Histologically there was profuse erythroid hyperplasia. Numerous histiocytes containing abundant Periodic-acid-Schiff positive cytoplasmic material took up greater than 50% of the marrow space (Fig 1B). These cells have previously been reported to occur in untransfused patients with thalassaemia major and resemble the foamy histiocytes found in primary phospholipid storage disorders (Sen Gupta *et al.* 1960). They are presumed to result from phagocytosis and incomplete digestion of the huge load of phospholipids derived from cell membranes of mature and immature erythrocytes. This degree of extramedullary haematopoiesis and erythrophagocytosis has rarely been seen since the advent of aggressive transfusional therapy.

Clinical Haematology Branch,
National Heart, Lung and Blood Institute,
Bethesda, Maryland 20892, U.S.A.

CYNTHIA DUNBAR
WILLIAM TRAVIS
Y. W. KAN
ARTHUR NIENHUIS

REFERENCES

Giblett, E.R., Hillman, R.S. & Brooks, L.E. (1965) Transfusion reaction during marrow suppression in a thalassemic patient with a blood group anomaly and an unusual cold agglutinin. *Vox Sanguinis*, **10**, 448–459.

Ley, T.J., DeSimone, J., Anagnou, N.P., Keller, G.H., Humphries, R.K., Turner, P.H., Young, N.S., Heller, P. & Nienhuis A.W. (1982) 5-Azacytidine selectively increases γ-globin synthesis in a patient with β^+ thalassemia. *New England Journal of Medicine*, **307**, 1469–1475.

Ley, T.J., DeSimone, J., Noguchi, C.T., Turner, P.H., Schecter, A.N., Heller, P. & Nienhuis, A.W. (1983) 5-Azacytidine increases γ-globin synthesis and reduces the proportion of dense cells in patients with sickle cell anemia. *Blood*, **62**, 370–380.

Neinhuis, A.W., Ley, T.J., Humphries, R.K., Young, N.S. & Dover, G. (1985) Pharmacological manipulation of fetal hemoglobin synthesis in patients with severe β-thalassemia. *Annals of the New York Academy of Sciences*, **445**, 198–211.

Sen Gupta, P.C., Chatterji, J.B., Mukherjee, A.M. & Chatterji, A. (1960) Observations on the foam cell in thalassemia, *Blood*, **16**, 1039–1044.

TREATMENT OF CHRONIC MYELOMONOCYTIC LEUKAEMIA WITH LOW DOSE ETOPOSIDE

The optimal management of chronic myelomonocytic leukaemia (CMML) is unknown. It is agreed that those patients who are asymptomatic with a slight monocytosis should be kept under observation only. For those in whom the disease follows an aggressive course with increasing leucocytosis, anaemia and/or thrombocytopenia, or who develop extramedullary effects such as hepatosplenomegaly, serous effusions (Mufti *et al.* 1984) or skin infiltrations (Copplestone *et al.* 1986) and for the 30% that transform to AML (Worsley *et al.* 1988) treatment remains controversial. Hydroxyurea, 6-mercaptopurine, 6-thioguanine, razoxane and low-dose subcutaneous cytosine arabinoside have all been used with some success but there is no evidence to suggest which agent is most effective or even whether survival is improved.

Between 1983 and 1987 we treated 10 consecutive patients with CMML with oral etoposide. Details are given in Table I. We have found empirically that a dose of 100 mg a day for 3 d is sufficient to achieve a rapid fall in WBC and resolution of serous effusions and that 50 mg twice weekly is effective both as a maintentance dose and as initial treatment when there is less need for a rapid response.

Sustained clinical benefit was obtained in seven of the 10 patients treated. The most dramatic response was seen in two patients who presented with life-threatening pericardial and pleural effusions, which resolved after 1 week of treatement. Similarly good results were obtained in those patients with monocytic skin infiltrates. Approximately 50% of the patients with anaemia or thrombocytopenia responded, especially when there was concomitant spenomegaly. Less benefit was obtained in those patients with increased blasts in the blood or marrow.

This regimen was extremely well tolerated with only two patients developing minor degrees of hair loss and one patient experiencing mild gastrointestinal side effects. Whether etoposide has any advantage over other oral cytotoxic agents or over low dose cytosine arabinoside is uncertain. We have treated a further 10 patients with hydroxyurea. In nine there was control of the leucocytosis but five developed a transfusion requirement during maintenance therapy; a problem we did not encounter with etoposide. A further eight patients received razoxone in doses ranging from 125 mg twice weekly to 250 mg daily. Seven achieved good control of the leucocytosis and in four there was an improvement in the platelet count. One patient had rapid resolution of a pleural effusion. Only one patient (patient 1) sequentially received all three drugs in an attempt to control a rapidly rising white cell count and pleural and pericardial effusions. There was no response to hydroxyurea 2 g daily for 3 d but transient benefit