ResearchGate

See discussions, stats, and author profiles for this publication at: https://www.researchgate.net/publication/40020970

Intravitreal bevacizumab for myopic choroidal neovascularization: short-term and 1-year results

Article *in* Bulletin de la Société belge d'ophtalmologie · January 2009

Source: PubMed

CITATIONS
6

READS
86

2 authors, including:

Leigh Spielberg
AZ Sint-Jan Brugge-Oostende

24 PUBLICATIONS **226** CITATIONS

SEE PROFILE

All content following this page was uploaded by Leigh Spielberg on 26 May 2014.

The user has requested enhancement of the downloaded file.

Celltrion Exhibit - 1049
Celltrion, Inc. v. Regeneron Pharmaceuticals, Inc.

INTRAVITREAL BEVACIZUMAB FOR MYOPIC CHOROIDAL NEOVASCULARIZATION: SHORT-TERM AND 1-YEAR RESULTS

SPIELBERG L., MD, LEYS A., MD, PHD**

ABSTRACT

Purpose: To report three-month and one-year safety and efficacy results of intravitreal bevacizumab injection (IVB) for active choroidal neovascularization associated with pathological myopia (mCNV).

Methods
This retrospective interventional case series of 23 patients (23 eyes) was conducted at the medical retina center in the Leuven University Hospital Department of Ophthalmology, a referral center for macular diseases in Belgium. Charts were reviewed of all patients who received 1.25 mg IVB for active mCNV. If patients had two treated eyes, the eye with the longest follow-up was selected as the study eye. Injections were repeated as needed based on a decrease in visual acuity, an increase in central macular thickness (CMT) of $>100\mu$ mm on optical coherence tomography (OCT), the recurrence of macular edema on OCT and/or leakage on fluorescein angiography (FA). For statistical analysis, patients were divided into two groups based on length of follow up: patients in Group 1 had a follow-up of $\geqslant$12 months, while those in Group 2 had <12 months of follow-up. Changes in visual acuity (VA), as measured by the Early Treatment of Diabetic Retinopathy Study (ETDRS) protocol, and CMT were analyzed, as were safety considerations such as intraocular inflammation and endophthalmitis.
Results: Twenty-three eyes of 23 patients with ages ranging from 20 to 84 years (mean 57.7 years) were included. Mean best-corrected visual acuity (BCVA) at baseline for all patients (n=23) was 45 letters (Snellen equivalent: 20/120; 8 lines). At 3 months after initial treatment, the mean BCVA improved significantly ($P < 0.05$) to 58 letters ($20/60^{2-}$; 10.5 lines). Eight patients had $\geqslant$12 months of follow-up (Group 1); 15 patients had $\geqslant$3 months of follow-up (Group 2). The mean BCVA for Group 1 improved significantly ($P < 0.05$) from 45 letters (20/120; 8 lines) to 60 letters (20/60; 11 lines), having received an average of 2.75 injections (range: 1-5) during this period and an average of one injection thereafter (mean follow-up after 12 months: 8 months). The mean BCVA for Group 2 improved significantly ($P < 0.05$) from 47 letters ($20/120^{2+}$; 8 lines) to 61 letters ($20/60^{1+}$; 11 lines), having received an average of 1.3 injections. CMT for all patients decreased from a mean of 266 mm at baseline to 201 mm at 1 month, 181 μmm at 3 months and 192 at 12 months (Group 1). Greater patient age was correlated with the need for more frequent injections. The oldest half of Group 1 (mean age 68.5 years) required an average of 3.75 injections, while the youngest half (mean age 39.5 years) required only 1.75. In Group 2, an inverse correlation between age and time between injections was observed. A total of 42 injections were administered. No peri- or post-injection ocular or systemic side effects were noted in either group.
Conclusion: Short-term and twelve-month results indicate that IVB is a safe and effective method to improve visual, reduce CMT and inhibit progression of mCNV.

KEYWORDS

anti-VEGF: Avastin: bevacizumab; choroidal neovascularization; myopia

.....

* *Medical Retina Department, Department of Ophthalmology, University Hospitals Leuven, Belgium*

Submitted: 14-05-09
Accepted: 18-07-09

INTRODUCTION

Pathological myopia, defined as myopia with complications in the posterior segment, is a leading cause of legal blindness in many developed countries (1), affecting approximately 2% of the general population (2). Myopic choroidal neovascularization (mCNV) is a sight-threatening complication of pathological myopia and the second-leading cause of secondary neovascular maculopathy, after age-related macular degeneration (AMD). Myopic CNV develops in approximately 5% to 10% of highly myopic eyes (3), making this the most common vision-threatening complication of high myopia. Because of the subsequent atrophic changes, the disease has a poor prognosis, and mCNV thus leads to significant vision loss in patients who are often young and otherwise healthy. (4,5,6)

Different therapeutic approaches, including thermal laser photocoagulation (7), radiotherapy (8), surgery (9,10) and verteporfin photodynamic therapy (PDT), (11) with or without triamcinolone acetonide, have been reported, without significant success. This has prompted the search for more effective treatment modalities for mCNV. The current study used bevacizumab to treat mCNV. The goal of the study was to determine whether 1.25 mg IVB on an as-needed basis would be efficacious and safe in the treatment of myopic CNV. The primary endpoints were BCVA at 1, 3, 6, 9 and 12 months. Secondary endpoints were CMT at the same time points, and safety during the entire follow-up period.

METHODS

A retrospective chart review was performed of 23 eyes of 23 consecutive patients treated with 1.25 mg IVB for mCNV. Only eyes with confirmed presence of CNV on FA and pathologic myopia, defined as a refractive error (spherical equivalent) of -6.00 diopters (D) or more, and treated with 1.25 mg IVB, were included. Exclusion criteria were laser photocoagulation in the study eye; a history of triamcinolone acetonide sub-Tenon injection during the previous six months before the initial IVB; cataract surgery during follow-up; the presence of a serious posterior segment complication, such as retinal detachment or foveoschisis; and the presence of severe cataract in the study eye. Of the 23 eyes included in the review, 8 eyes had been followed up for 12 months or longer after the first injection (designated as Group 1) and 15 eyes with at least 3 months of follow-up (Group 2). Patients had been informed about the benefits, risks, off-label nature, and alternatives to treatment before treatment was initiated, as is standard in our department.

Examinations

Each patient underwent complete ocular examination, including BCVA (Early Treatment of Diabetic Retinopathy protocol, ETDRS), OCT (Cirrus HD-OCT, Carl Zeiss Meditec, Jena, Germany) and FA at baseline. Each follow-up examination consisted of a complete dilated ocular examination, BCVA and OCT. The same examiner performed the BCVA and OCT examinations at each patient visit. Color fundus photographs were obtained and FA was performed using a conventional digitalized fundus camera (Topcon TRC-50DX Fundus Camera, Topcon, Itabashi, Tokyo, Japan) before the initial IVB and later based on a decrease in visual acuity, an increase in CMT of $>100\,\mu$mm on OCT, the recurrence of macular edema on OCT and/or leakage on FA.

Intravitreal bevacizumab

Patients received 1.25 mg / 0.05 ml intravitreal bevacizumab injections (Avastin®, Roche, Basel, Switzerland) using the standard protocol of the medical retina department of the Department of Ophthalmology at Leuven University Hospital, following the instillation of topical anesthetic drops under sterile conditions. Povidone-iodine 10% solution (Braunol®, B. Braun Medical, Diegem, Belgium) was applied to the periocular area; povidone-iodine 5% (Iso-Betadine Ophta®, Meda Pharma, Solna, Sweden) solution was applied topically. Bevacizumab was injected into the vitreous cavity using a 30-gauge needle inserted through the inferotemporal pars plana 3.0 mm (pseudophakic) or 3.5 mm (phakic) posterior to the limbus. Patients were instructed to instill one drop of ofloxacine eye drops (Trafloxal®, Dr. Mann Phar-

ma, Berlin, Germany) into the injected eye three times daily for three days after the intravitreal injection.

All patients had undergone FA before the first IVB treatment. An "evaluate-and-extend" regimen was followed, in which patients were initially followed up at 4-week intervals after the first injection. This interval was gradually extended to a maximum of three months between visits. Retreatment was based on a decrease in visual acuity, an increase in CMT of >100 μmm on OCT, the recurrence of macular edema on OCT and/or leakage on FA. Further, patients were advised to return to the clinic in between scheduled appointments for evaluation if they experienced a loss of vision or increased metamorphopsia.

For the purpose of analysis, ETDRS visual acuity data were converted into equivalent logarithms of the minimum angle of resolution (log MAR) values. Data were analyzed using the paired two-sample t-test for means. A *p*-value of less than 0.05 was considered to be statistically significant.

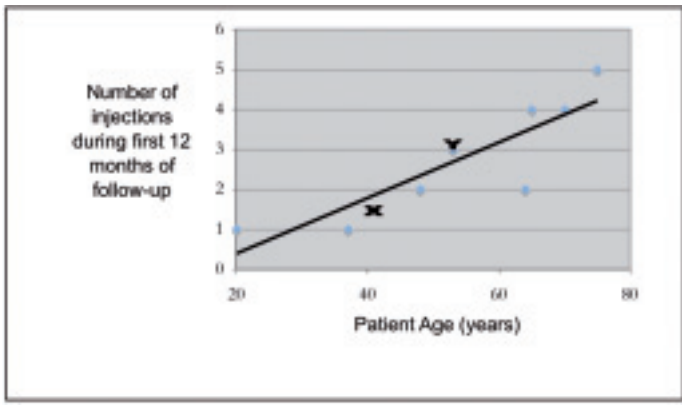

Fig. 1: Correlation between patient age and injection frequency in patients with 12-month follow-up (Group 1). X = data from Wu *et al.* (mean patient age = 41.5 years; mean injection frequency = 1.4); Y = data from Rhéaume *et al.* (mean patient age = 53.5 years; mean injection frequency = 3.1)

RESULTS

Fifteen women (65%) and eight men (35%) with a mean age of 57.7 years (range 20-84) were included in this study. Prior ocular treatment included photodynamic therapy in 10 patients (5 in Group 1 and 5 in Group 2) and intravitreal triamcinolone in 1 patient (Group 2). All treatments were performed at least 6 months prior to IVB. Three patients were pseudophakic. One patient had suffered a retinal detach-

Table 1: *Mean visual acuity measurements at baseline each of the main time points after initial intravitreal bevacizumab treatment for myopic choroidal neovascularization*

	BCVA					
Patient group	*Baseline*	*1m*	*3m*	*6m*	*9m*	*12m*
Group 1 (n = 8)	20 / 120	20 / 80^{-}	20 / 80^{+}	20 / 80	20 / 60^{+}	20 / 60
Group 2 (n = 15)	20 / 120^{++}	20 / 80^{+}	20 / 60$^{=}$	/	/	/
All patients (n = 23)	20 / 120^{+}	20 / 80	20 / 80^{++}	/	/	/

BCVA = best-corrected visual acuity; VA = visual acuity

Table 2: *Central macular thickness at baseline, 1 and 3 months (all patients) and at 6, 9 and 12 months (Group 1).*

	Central Macular Thickness (mm)					
Group	*Baseline*	*1m*	*3m*	*6m*	*9m*	*12m*
Group 1 (n=8)	361	307	276	261	270	262
Group 2 (n=15)	367	318	284	/	/	/
All patients (n=23)	365	314	281	/	/	/

μm = micrometers; m = months

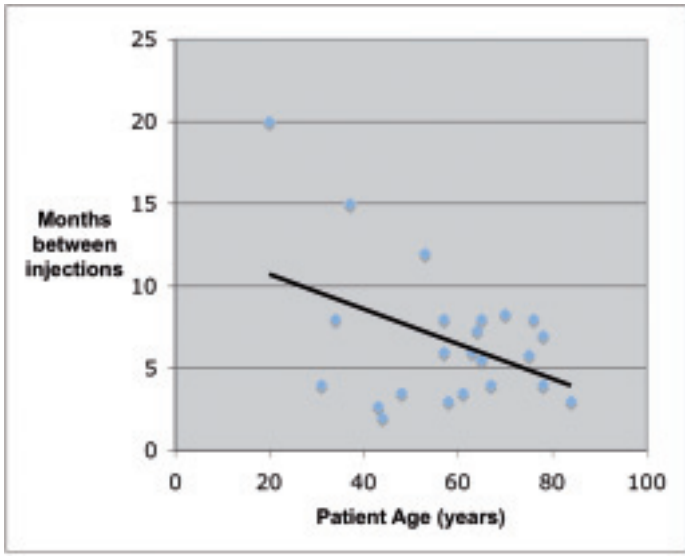

Fig. 2: Correlation between injection frequency (months between injections) and patient age for all patients (n=23).

ment in the study eye, which was treated with a scleral buckle 7 years prior to the first bevacizumab injection. All patients in Group 1 had at least 12 months of follow-up. An OCT scan was performed at each patient visit to the clinic. No ocular or systemic side effects were noted.

The mean log MAR BCVA for all patients (n=23) was 0.77 (Snellen equivalent: 20/120^{+}; 8 ETDRS lines) at baseline, 0.60 (20/80; 10 lines) at 1 month and 0.55 (20/60^{2-}; 10.5 lines) at three months. In Group 1 (n=8), the mean BCVA was log MAR 0.80 (20/120; 8 lines) at baseline, 0.63 (20/80^{2-}; 9.5 lines) at 1 month, 0.58 (20/80^{+}; 10 lines) at 3 months, 0.61 (20/80; 10 lines) at 6 months, 0.48 (20/60^{+}; 11 lines) at 9 and 0.50 (20/60; 11 lines) at 12 months (Table 1). In Group 2 (n=15), the mean BCVA was log MAR 0.75 (20/120^{2+}; 8 lines) at baseline, 0.59 (20/80^{2-}; 9.5 lines) at 1 month and 0.54 (20/80^{+}; 10 lines) at 3 months (Table 1). The mean differences in log MAR VA between baseline and each of the follow-up points for all patients and for both groups were statistically significant ($P < 0.05$).

Increased patient age was associated with the need for more frequent injections (Figures 1 and 2). Of the 8 patients with 12-month follow-up (Group 1), the oldest half (mean age: 68.5 years) required an average of 3.75 injections, while the youngest half (mean age: 39.5 years) required 1.75 (Table 3). In those patients with shorter follow up (Group 2), there was an inverse relationship between age and time between injections; older patients required more frequent injections (Figure 2). However, the mean visual acuity improvement was almost identical between older and younger patients, improving a mean of 3 lines in both the older and younger patients (Table 3). The mean CMT for all patients was 365 mm at baseline, 314 mm at 1 month and 281 mm at 3 months (Table 2; Figure 3). For Group 1, the mean CMT was 261 mm at 6 months; 270 mm at 9 months and 262 at 12 months (Table 2). The mean differences in CMT between baseline and each of the follow-up points were statistically significant ($P < 0.05$).

Table 3: *Age, visual acuity and injection frequency in patients with 12-month follow-up (Group 1)*

BCVA	*Mean Age (years)*	*Baseline VA*	*Final VA*	*ETDRS lines gained*	*Injections*
Older patients (n=4)	68.5	20 160^{+}	20 / 80^{+}	3	3.75
Younger patients (n=4)	39.5	20 / 100^{-}	20 / 50^{-}	3	1.75
All patients in current study (n=8)	54.0	20 / 120	20 / 60	3	2.75

BCVA = best corrected visual acuity; VA = visual acuity; * pro-rated from 2.6 injections over 10 months

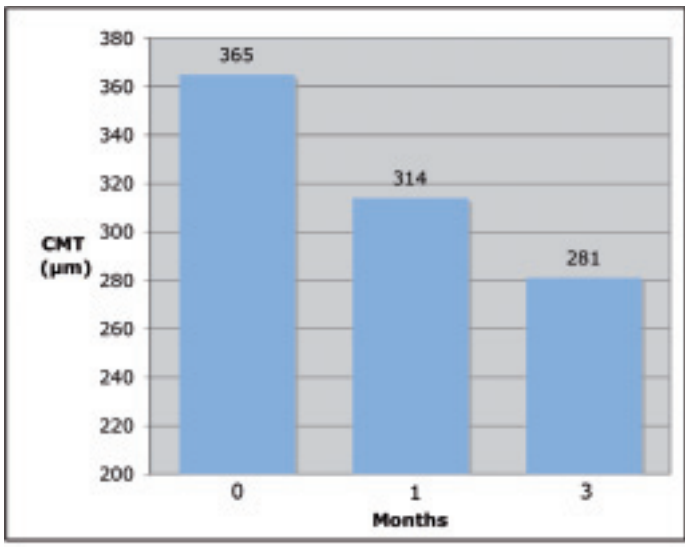

Fig. 3: Central macular thickness (CMT) in micrometers (µm) for all patients (n= 23) at baseline, 1 and 3 months.

DISCUSSION

The results of this study suggest that intravitreal bevacizumab is a safe and effective treatment modality for choroidal neovascularization caused by pathological myopia. This supports the conclusions of previously published studies in other populations. To our knowledge, this is the first study of this kind to be conducted within the Belgian population.

The visual outcome of myopic choroidal neovascularization is extremely poor if left untreated. Studies of the long-term outcome of untreated choroidal neovascularization due to pathological myopia have shown that between 60 and 73% of patients with subfoveal or juxtafoveal lesions end up with a final VA of ⩽ 20/200T(4,13,14). This visual loss is largely due to the development of chorioretinal atrophy around the regressed CNV. (15) Only a small percentage of patients retain good vision over the long term without treatment.

Factors associated with a better prognosis (defined in these studies as a final VA better than 20/40) have been shown by Hayashi *et al.* to be younger age, better initial VA, smaller CNV lesion and juxtafoveal lesion location. (16) However, the vast majority of patients does not present with these favorable factors. Most are of middle or advanced age (in Hayashi's study: mean 49 years), have a VA worse than 20/40 (81%), have large CNV lesions (mean = 0.85 disc areas) and have subfoveal lesions (81%) at presentation. (16) Yoshida *et al.* reported that the angiographic features of the CNV in patients over the age of 40 had more profuse angiographic leakage and that patients <40 years of age had significantly better visual outcome. (5) Kojima *et al* found that the BCVA at 5 years after onset was significantly associated with patient age ($P < 0.05$, Spearman correlation). (17) The correlation between age and greater VA loss was supported by Axer-Siegel *et al*., who found that 50% of the older age group and 20% of the younger age group had visual loss of 15 letters or more. Further, even young age does not protect against disease progression. Axer-Siegel reported that 8% of the younger patients lost ⩾15 letters despite treatment with PDT. (18)

With regards to lesion location, although juxtafoveal lesions have a better prognosis, most non-subfoveal lesions rapidly progress to the subfoveal area. Secretan *et al.* recorded the progression of patients with extra- and juxtafoveal lesions and found that all juxtafoveal lesions in Secretan's study became subfoveal within five years, with a mean final visual acuity of 20/160. (6) During this time patients were either treated with laser photocoagulation or left untreated.

The only multicenter, randomized, controlled trial of PDT for mCNV conducted to date reported that treatment with PDT improves the visual outcome of myopic CNV (19). However, the effect of PDT was not sustained by the end of the second year. Indeed, some authors have reported that treatment of highly myopic eyes with PDT accelerates thrombosis of choroidal vessels and induces lacquer crack formation. (20,21) Thus, PDT might have a negative effect on the chorioretinal atrophy in mCNV, which is a key factor in the long-term prognosis of the disease. (22) In fact, treatment with

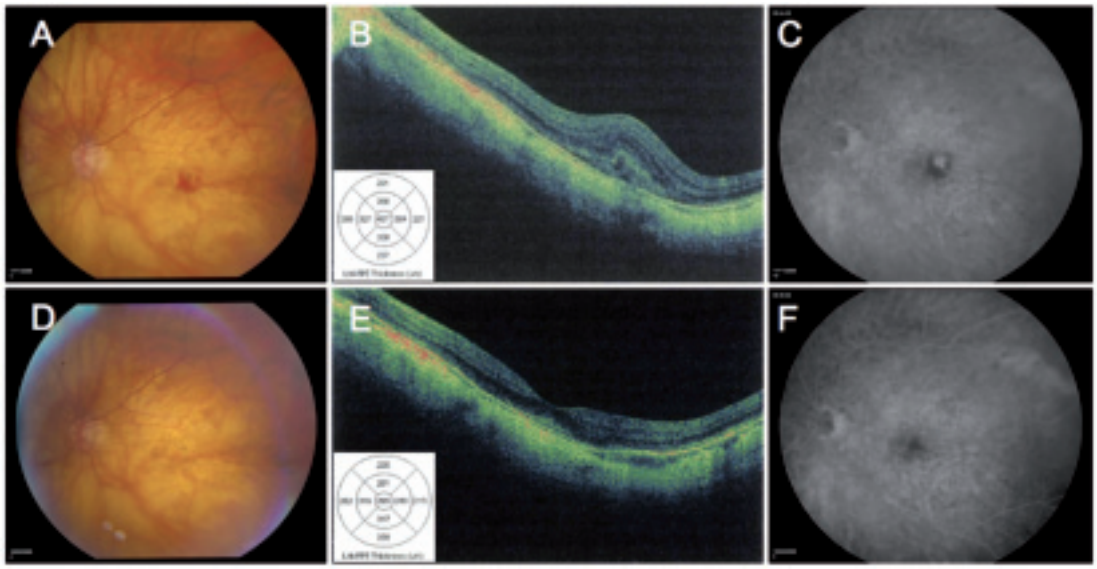

Fig. 4: Female (78 yrs; -12 D) with metamorphopsia for 1 week prior to presentation. VA = 20/50. **A,B,C:** Fundus exam, OCT and FA (at 45 sec) show a bleeding subretinal membrane. CMT was 437 μm. Avastin was administered the same day. **D,E,F:** Three months after injection, the metamorphopsia has disappeared and the VA has improved to 20/32. Fundus exam, OCT and FA (at 36 sec) show a subretinal neovascular membrane without leakage. CMT = 295 μm.

PDT results in only a slightly better visual outcome than would have been expected from the natural history of the disease. A large, retrospective study by Costagliola *et al* reported a slight decrease in BCVA with standard PDT treatment over a 12-month follow-up period. (23) Ruiz-Moreno *et al* reported a slightly better outcome in a prospective study, with a small BCVA improvement at 12 months (1.4 lines) and 48 months (0.6 lines). (24) However, PDT has not achieved truly satisfactory results, which has lead to the investigation of other treatment modalities.

The recent discovery of the complex pathogenic mechanisms responsible for choroidal neovascularization has lead to the development of treatment focused on interrupting this process. This pathogenesis consists of a cascade of retinal changes in which hypoxia or ischemia leads to atrophy of the choroidal vasculature and the upregulation of angiogenic factors such as VEGF. (25-27) This leads to inflammation, angiogenesis and subsequently neovascularization. (28) Higher intraocular concentrations of VEGF have been shown to be significantly related to disease activity in neovascular AMD. (29) The discovery of the role of VEGF in the pathogenesis of neovascularization led to the development of a new class of pharmacological agents that could block its action. These anti-VEGF antibodies, or anti-angiogenics, include pegaptanib, bevacizumab and ranibizumab, and have been used to treat CNV of other etiologies, primarily AMD, (30,31) but also idiopathic CNV and myopic CNV.

Because of the successful antiangiogenic treatment of CNV due to other etiologies, anti-VEGF treatment of mCNV has gained speed. The results have been encouraging and similar to those obtained in the treatment of neovascular AMD. (32) However, very few trials have follow-up periods longer than 6 months, and none are large-scale, randomized studies. Thus, the optimal dosage and time intervals of re-injection for long-term efficacy are largely unknown, as are the medium- and long-term effects of the treatment.

A review of the available literature (up to October, 2007), conducted by the American Academy of Ophthalmology, suggests that anti-VEGF

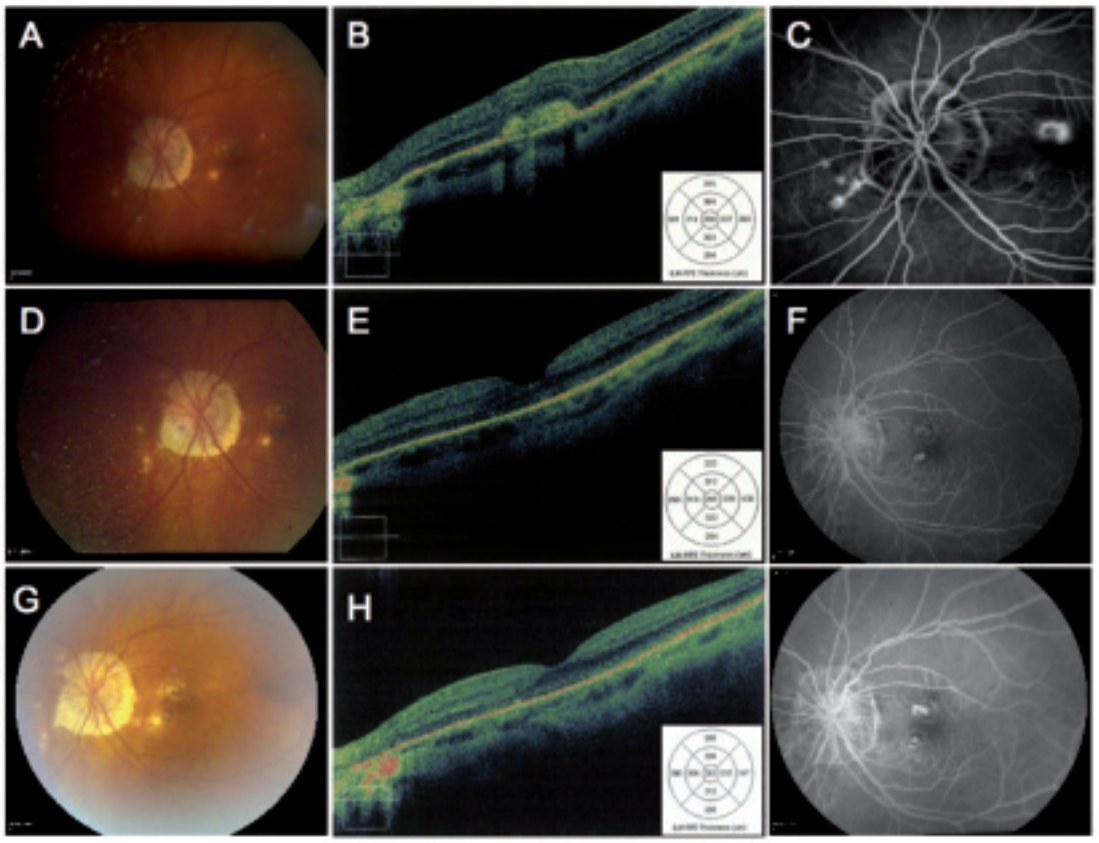

Fig. 5: Female (64y; -10 D) severely reduced vision for 2 weeks. VA = 20/126 OS. **A,B,C:** Fundus photo, FA (Heidelberg, 3m14s) and OCT show myopic degeneration, retinal and peripapillar atrophy and an active, 100% classic subretinal membrane with a small hemorrhage on the inferior border of fixation. CMT = 298 μm. Avastin was administered the same day. **D,E,F:** Four months later. VA = 20/40. Minimally active lesion without macular edema. CMT = 265 μm. **G,H,I:** 13 months after first injection, 9 months after the second, VA = 20/25. Atrophic retinal lesions and peripapillar atrophy with an inactive lesion. CMT stable at 262 μm.

pharmacotherapy, delivered by intravitreal injection, is a safe and effective treatment for neovascular AMD for up to 2 years. (33) Level I evidence exists to support this conclusion for the antiangiogenics pegaptanib and ranibizumab, but none for bevacizumab at this time. To our knowledge, no comparable study has been conducted for the treatment of myopic CNV. However, there have been several reports of the safety and efficacy of off-label bevacizumab for mCNV. (34-37)

In these studies, visual acuity improved by 2 or more lines in ⩾75% of cases after a mean follow up of 5.0 and 4.4 months, respectively. Yamamoto *et al* reported a mean improvement of 2 or more lines in 91% of patients after a mean follow-up of 5.0 months. (35) Sakaguchi *et al* reported an improvement of 2 or more lines in 75% of patients, after a mean follow-up of 4.4 months. (34) Wu *et al* followed 8 patients up for 12 months and reported an improvement of at least 3 ETDRS lines in all eyes, (36) while Rhéaume *et al* reported a 10-month follow-up of 10 eyes in which vision improved by a mean of 3.9 lines on the Snellen VA chart. There were no associated side effects or complications reported in any of these 4 studies. Studies by Konstantinidis) *et al* (38) and Silva *et al* (39) have shown similar results with ranibizumab, also without complications or drug-related side effects during the follow-up period.

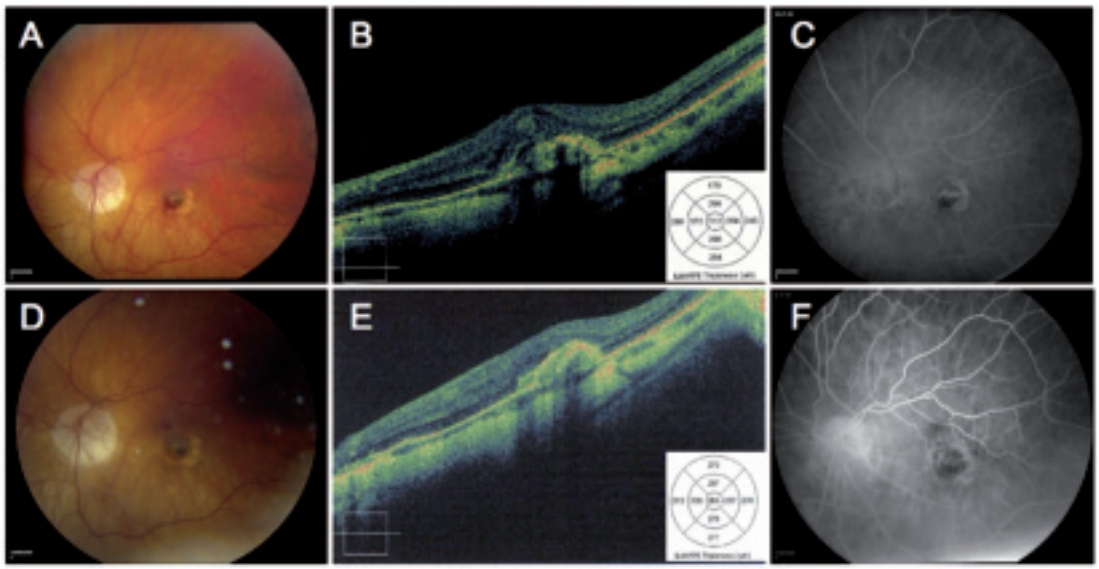

Fig. 6: Male (53 years; -10 D), with a history of an inferotemporal, peripheral, self-sealed retinal detachment and 4 previous PDT sessions. VA = 20/80. **A,B,C:** Fundus exam, OCT and FA (28 sec) show an active membrane with recent hemorrhage and macular edema. CMT = 312 μm. Avastin was administered the following week. **D,E,F:** 5 months later: VA = 20/64^{-}. Fundus exam, OCT and FA (at 26 sec) show an inactive membrane and an absence of hemorrhage, lipoid exudates and macular edema. CMT = 265 μm. No further Avastin was required during the 12-month follow-up.

Our "evaluate-and-extend" regimen is a modified "treat-and-extend" strategy. In the "treat-and-extend" approach, originally developed for neovascular age-related macular degeneration, treatment is administered at each patient visit, even in the absence of macular edema. If the macula remains free of edema, and the vision is stable, the interval between visits is extended to a maximum of 10-11 weeks. The goal of "treat-and-extend" is to safely maintain the benefits of therapy while minimizing the number of visits and injections needed. Our modified ''evaluate-and-extend'' approach utilized the same evaluation strategy, allowing for frequent evaluation of the fundus, but only treated as-needed, in case of recurrence. Extension of the time between visits was based on the degree of stability between the previous visit and the current one, up to a maximum of three months. This allowed for a lower reinjection rate.

In our series of 8 patients followed up for at least 12 months, the mean time between injections was 4.4 months (based on a mean of 2.75 injections in 12 months). This is similar to the reinjection frequency reported by Rhéaume et al (2.6 in 10 months, mean age 53), (37) but substantially more than the mean reported by Wu (1.4 in 12 months, mean age 41.5). (36) However, when analyzed in relation to patient age, the injection frequency of our study closely mirrors those of Rhéaume and Wu (Figure 1).

Taken together, these three studies suggest that the reinjection frequency is highly correlated with patient age. Of the 8 patients with 12-months of follow-up, the youngest four (mean 39.5 years) required an average of 1.75 injections, while the oldest four (mean 68.5 years) required 3.75. This suggests that younger patients respond more efficiently to the effects of bevacizumab than those of more advanced age. Regarding VA, what we observed is that both baseline (20/160^{+} *vs.* 20/100^{-}) and final (20/80^{+} *vs.* 20/50^{-}) BCVA are better in younger patients, but that overall improvement (3 lines) is similar between the two groups (Table 3). That younger age is correlated with superior VA at presentation, as well as a less damaging natural progression, is well known. However, what has not yet been described is a correlation be-

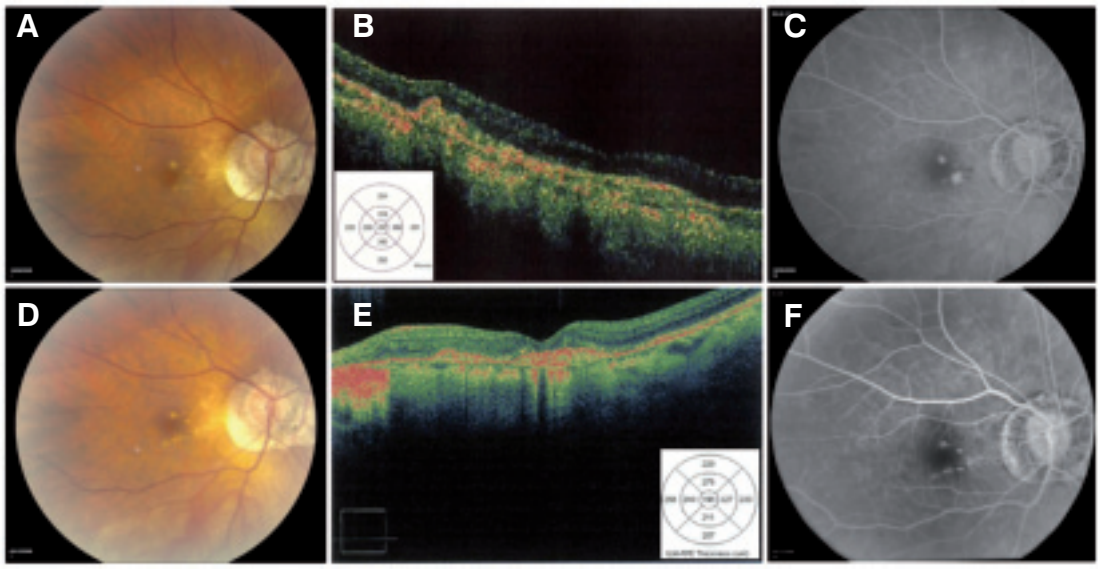

Fig. 7: Female (63 years, -8.5 D) Presented at the emergency department with sudden onset of metamorphopsia OD, despite VA = 20/20. History of 7 previous PDT treatments OS. **A,B,C:** Fundus exam, OCT (Stratus) and FA (at 42 sec) showed 2 recent hemorrhages and 2 active subretinal neovascular membranes (superior and nasal of fovea). Avastin was administered the same day. CMT = 297 μm. **D,E,F:** Four months later, the patient reported stable vision. VA = 20/20. Fundus exam, OCT (Cirrus) and FA (at 45 sec) show an inactive neovascular membrane. CMT = 193 μm.

tween age and reinjection frequency. This is likely because few studies have exceeded 6 months follow-up, and have treated on an individualized, as-needed basis. Other studies conducted to date have had much shorter follow-up times and pre-determined injection schedules, making comparison difficult.

The administration of multiple injections in an individualized regimen suggests that one-time treatment is not sufficient, and that frequent patient visits and complete ophthalmic examinations are necessary to determine when injections are needed. This is in line with the use of anti-angiogenics in the treatment of neovascular AMD, in which individualized, OCT-guided treatment regimens, as outlined in the PrONTO study, (40) are becoming more common now that the efficacy of the drugs has been established when given on a monthly basis.

In the absence of evidence derived from randomized controlled trials supporting the use of bevacizumab for myopic CNV, many clinicians may feel obliged to use PDT as the first-line treatment. However, we do not feel that this is supported by the results of the studies conducted. Despite the short follow-up times of the studies to date, and despite the fact that it is not yet known whether anti-VEGF treatment will favorably alter the long-term natural history of the disease, it is clear that there is significant improvement in the short- to medium-term, and that without treatment, there is an inevitable and irreparable decline in visual function.

In conclusion, this short-term study shows that IVB effectively improves visual acuity and decreases central CMT in patients with mCNV secondary to pathological myopia. A majority of eyes will require multiple injections for persistent or recurrent macular edema. Adverse events did not occur in our study and are likely to be rare.

Advantages of this study are its 12-month follow-up time and the individualized, as-needed treatment regimen, which made it possible to differentiate injection frequency between different age groups. However, this is a retrospective study without controls, which makes it difficult to evaluate the efficacy of IVB for mCNV. However, we observed a statistically significant mean improvement compared with the

natural history of the disease, which almost invariably leads to a clinically significant loss of VA. In addition, the use of IVB is still off-label in many countries. A future multi-center, randomized, controlled clinical trial with even longer follow-up may more clearly reveal the efficacy and safety of IVB for mCNV.

Acknowledgements

Carol Heughebaert provided excellent scientific writing and editorial assistance. The authors would also like to thank Adrian Loehwing for her help with the statistical analysis.

REFERENCES

(1) HOTCHKISS M.L., FINE S.L. – Pathologic myopia and choroidal neovascularization. *Am J Ophthalmol 1981; 91: 177-83.*

(2) CURTIN B. – The myopias: basic science and clinical management. Philadelphia: Harper & Row, 1985.

(3) SOUBRANE G., COSCAS, G.J. – Choroidal neovascular membrane in degenerative myopia. Philadelphia: Elsevier Mosby, 2006.

(4) AVILA M.P., WEITER J.J., JALKH A.E., TREMPE C.L., PRUETT R.C., SCHEPENS C.L. – Natural history of choroidal neovascularization in degenerative myopia. *Ophthalmology 1984; 91: 1573-81.*

(5) YOSHIDA T., OHNO-MATSUI K., OHTAKE Y., et al. – Long-term visual prognosis of choroidal neovascularization in high myopia: a comparison between age groups. *Ophthalmology 2002; 109: 712-9.*

(6) SECRETAN M., KUHN D., SOUBRANE G., COSCAS G. – Long-term visual outcome of choroidal neovascularization in pathologic myopia: natural history and laser treatment. *Eur J Ophthalmol 1997;7:307-16.*

(7) RUIZ-MORENO J.M., MONTERO J.A. – Long-term visual acuity after argon green laser photocoagulation of juxtafoveal choroidal neovascularization in highly myopic eyes. *Eur J Ophthalmol 2002; 12: 117-22.*

(8) KOBAYASHI H., KOBAYASHI K. – Radiotherapy for subfoveal neovascularisation associated with pathological myopia: a pilot study. *Br J Ophthalmol 2000; 84: 761-6.*

(9) FUJIKADO T., OHJI M., SAITO Y., HAYASHI A., TANO Y. – Visual function after foveal translocation with scleral shortening in patients with myopic neovascular maculopathy. *Am J Ophthalmol 1998; 125: 647-56.*

(10) RUIZ-MORENO J.M., AMAT-PERAL P., LUGO F.L., MONTERO JA. – Surgical removal of peripapillary choroidal neovascularization in young patients. *Arch Soc Esp Oftalmol 2009; 84: 39-42.*

(11) MONTERO J.A., RUIZ-MORENO J.M. – Verteporfin photodynamic therapy in highly myopic subfoveal choroidal neovascularisation. *Br J Ophthalmol 2003; 87: 173-6.*

(12) HEIER J. (MOD) F.K., FREUND K.B., HOLEKAMP N.M., BRESSLER N.M., BROWN DM. – Evaluating dosing strategies to maximize outcomes, minimize risks in neovascular age-related macular degeneration: roundtable discussion. *Retinal Physician 2008 (April).*

(13) HAMPTON G.R., KOHEN D., BIRD A.C. – Visual prognosis of disciform degeneration in myopia. *Ophthalmology 1983; 90: 923-6.*

(14) TABANDEH H., FLYNN H.W., JR., SCOTT I.U., et al. – Visual acuity outcomes of patients 50 years of age and older with high myopia and untreated choroidal neovascularization. *Ophthalmology 1999; 106: 2063-7.*

(15) YOSHIDA T., OHNO-MATSUI K., YASUZUMI K., et al. – Myopic choroidal neovascularization: a 10-year follow-up. *Ophthalmology 2003; 110: 1297-305.*

(16) HAYASHI K., OHNO-MATSUI K., YOSHIDA T., et al. – Characteristics of patients with a favorable natural course of myopic choroidal neovascularization. *Graefes Arch Clin Exp Ophthalmol 2005; 243: 13-9.*

(17) KOJIMA A., OHNO-MATSUI K., TERAMUKAI S., et al. – Estimation of visual outcome without treatment in patients with subfoveal choroidal neovascularization in pathologic myopia. *Graefes Arch Clin Exp Ophthalmol 2006; 244: 1474-9.*

(18) AXER-SIEGEL R., EHRLICH R., WEINBERGER D., et al. – Photodynamic therapy of subfoveal choroidal neovascularization in high myopia in a clinical setting: visual outcome in relation to age at treatment. *Am J Ophthalmol 2004; 138: 602-7.*

(19) Photodynamic therapy of subfoveal choroidal neovascularization in pathologic myopia with verteporfin. 1-year results of a randomized clinical trial--VIP report no. 1. *Ophthalmology 2001; 108: 841-52.*

(20) LADAS I.D., MOSCHOS M.M., ROUVAS A.A., KARAGIANNIS D.A., KOKOLAKIS SN. – Lacquer crack formation after photodynamic therapy. *Eur J Ophthalmol 2003; 13: 729-33.*

(21) OHNO-MATSUI K., MORIYAMA M., HAYASHI K., MOCHIZUKI M. – Choroidal vein and artery occlusion following photodynamic therapy in eyes with pathologic myopia. *Graefes*

Arch Clin Exp Ophthalmol 2006; 244: 1363-6.
(22) IKUNO Y., SAYANAGI K., SOGA K., et al. – Intravitreal bevacizumab for choroidal neovascularization attributable to pathological myopia: one-year results. *Am J Ophthalmol 2009; 147: 94-100 e1.*
(23) COSTAGLIOLA C., CAMPA C., INCORVAIA C., et al. – Verteporfin photodynamic therapy for subfoveal choroidal neovascularization in pathologic myopia: a 12-month retrospective review. *Eur J Ophthalmol 2008; 18: 955-9.*
(24) RUIZ-MORENO J.M., AMAT P., MONTERO J.A., LUGO F. – Photodynamic therapy to treat choroidal neovascularisation in highly myopic patients: 4 years' outcome. *Br J Ophthalmol 2008; 92: 792-4.*
(25) CASEY R., LI W.W. – Factors controlling ocular angiogenesis. *Am J Ophthalmol 1997; 124: 521-9.*
(26) DAS A., MCGUIRE P.G. – Retinal and choroidal angiogenesis: pathophysiology and strategies for inhibition. *Prog Retin Eye Res 2003; 22: 721-48.*
(27) D'AMORE PA. – Mechanisms of retinal and choroidal neovascularization. *Invest Ophthalmol Vis Sci 1994; 35: 3974-9.*
(28) AUGUSTIN A.J., OFFERMANN I. – Combination therapy for choroidal neovascularisation. *Drugs Aging 2007; 24: 979-90.*
(29) ROH M.I., KIM H.S., SONG J.H., LIM J.B., KOH H.J., KWON O.W. – Concentration of cytokines in the aqueous humor of patients with naive, recurrent and regressed CNV associated with AMD after bevacizumab treatment. *Retina 2009; 29: 523-9.*
(30) BROWN D.M., KAISER P.K., MICHELS M., et al; ANCHOR Study Group. – Ranibizumab versus verteporfin for neovascular age-related macular degeneration. *N Engl J Med 2006; 355: 1432-44.*
(31) ROSENFELD P.J., BROWN D.M., HEIER J.S., et al; MARINA Study Group. – Ranibizumab for neovascular age-related macular degeneration. *N Engl J Med 2006; 355: 1419-31.*
(32) CHANG L.K., SPAIDE R.F., BRUE C., FREUND K.B., KLANCNIK J.M. JR, SLAKTER J.S. – Bevacizumab treatment for subfoveal choroidal neovascularization from causes other than age-related macular degeneration. *Arch Ophthalmol 2008; 126: 941-5.*
(33) IP M.S., SCOTT I.U., BROWN G.C., et al; American Academy of Ophthalmology. – Antivascular endothelial growth factor pharmacotherapy for age-related macular degeneration: a report by the American Academy of Ophthalmology. *Ophthalmology 2008; 115: 1837-46.*
(34) SAKAGUCHI H., IKUNO Y., GOMI F., et al. – Intravitreal injection of bevacizumab for choroidal neovascularisation associated with pathological myopia. *Br J Ophthalmol 2007; 91: 161-5.*
(35) YAMAMOTO I., ROGERS A.H., REICHEL E., YATES P.A., DUKER J.S. – Intravitreal bevacizumab (Avastin) as treatment for subfoveal choroidal neovascularisation secondary to pathological myopia. *Br J Ophthalmol 2007; 91: 157-60.*
(36) WU P.C., CHEN Y.J. – Intravitreal injection of bevacizumab for myopic choroidal neovascularization: 1-year follow-up. *Eye 2009 Jan 16* [Epub ahead of print].
(37) RHEAUME M.A., SEBAG M. – Intravitreal bevacizumab for the treatment of choroidal neovascularization associated with pathological myopia. *Can J Ophthalmol 2008; 4: 576-80.*
(38) KONSTANTINIDIS L., MANTEL I., POURNARAS J.A, ZOGRAFOS L., AMBRESIN A. – Intravitreal ranibizumab (Lucentis) for the treatment of myopic choroidal neovascularization. *Graefes Arch Clin Exp Ophthalmol 2009; 247: 311-8.*
(39) SILVA R.M., RUIZ-MORENO J.M., NASCIMENTO J., et al. – Short-term efficacy and safety of intravitreal ranibizumab for myopic choroidal neovascularization. *Retina 2008; 29: 1117-23.*
(40) FUNG A.E., LALWANI G.A., ROSENFELD P.J., et al. – An optical coherence tomography-guided, variable dosing regimen with intravitreal ranibizumab (Lucentis) for neovascular age-related macular degeneration. *Am J Ophthalmol 2007; 143: 566-83.*

.....

Adress for correspondence:
Dr Leigh Spielberg, MD
University Hospitals Leuven

View publication stats