January 2010 Volume 94 Issue 1

94/1

Shawnee Mission Medical Center Medical Library
Library Date Received FEB 0 1 2010

British Journal of Ophthalmology

bjo.bmj.com

BMJ | Journals

Celltrion Exhibit - 1030
Celltrion, Inc. v. Regeneron Pharmaceuticals, Inc.

Cover image: Undine and drop bottles. *Courtesy of Mr Richard Keeler, Curator, Museum of the Royal College of Ophthalmologists.* See p 26.

Editors-in-Chief
Harminder S Dua (UK)
Arun D Singh (USA)

Website Editor
Robert Bhisitkul (USA)

Translation Editors
Evelyn Fu (USA)
José Gomes (Brazil)
Alvin Kwok (Hong Kong)
Merce Morral Palau (Spain)
David Pelayes (Argentina)
Daniel de Souza Pereira (Brazil)

Editorial Office
BMJ Publishing Group Ltd,
BMA House, Tavistock Square,
London WC1H 9JR, UK
T: **+44 (0)20 7383 6170**
F: **+44 (0)20 7383 6668**
E: **bjo@bmjgroup.com**

ISSN: 0007-1161 (print)
ISSN: 1468-2079 (online)

Impact factor: 2.859

Disclaimer: British Journal of Ophthalmology is owned and published by BMJ Publishing Group Ltd, a wholly owned subsidiary of the British Medical Association. The owner grants editorial freedom to the Editor of British Journal of Ophthalmology.

British Journal of Ophthalmology follows guidelines on editorial independence produced by the World Association of Medical Editors and the code on good publication practice of the Committee on Publication Ethics.

British Journal of Ophthalmology is intended for medical professionals and is provided without warranty, express or implied. Statements in the journal are the responsibility of their authors and advertisers and not authors' institutions, the BMJ Publishing Group Ltd or the BMA unless otherwise specified or determined by law. Acceptance of advertising does not imply endorsement.

To the fullest extent permitted by law, the BMJ Publishing Group Ltd shall not be liable for any loss, injury or damage resulting from the use of British Journal of Ophthalmology or any information in it whether based on contract, tort or otherwise. Readers are advised to verify any information they choose to rely on.

Copyright: © 2010 BMJ Publishing Group Ltd. All rights reserved; no part of this publication may be reproduced, stored in a retrieval system or transmitted in any form or by any means, electronic, mechanical, photocopying, recording or otherwise without the prior permission of British Journal of Ophthalmology.

British Journal of Ophthalmology is published by BMJ Publishing Group Ltd, typeset by The Charlesworth Group and printed in the UK on acid-free paper by Latimer Trend & Co Ltd, Plymouth.

British Journal of Ophthalmology (ISSN 0007-1161) is published monthly by BMJ Publishing Group and distributed in the US by Mercury International Ltd. Periodicals postage paid at Rahway, NJ. POSTMASTER: Send address changes to BJO, Mercury International Ltd, 365 Blair Road, Avenel, NJ 07001, USA

Contents

Editorial

1 Ocular anaesthesia and the never-ending story
P Athanasiov, T Henderson

Review

2 Ranibizumab (Lucentis) in neovascular age-related macular degeneration: evidence from clinical trials
P Mitchell, J-F Korobelnik, P Lanzetta, F G Holz, C Prünte, U Schmidt-Erfurth, Y Tano, S Wolf

Global issues

14 Mapping trachoma in Nasarawa and Plateau States, central Nigeria
J D King, N Jip, Y S Jugu, A Othman, A F Rodgers, D Y Dajom, E Miri, P M Emerson

20 Increased hyperopia with ageing based on cycloplegic refractions in adults: the Tehran Eye Study
H Hashemi, R Iribarren, I G Morgan, M KhabazKhoob, K Mohammad, A Fotouhi

Innovations

24 Computer simulation-assisted rotational autokeratoplasty with pupillary enlargement for management of cases with partial corneal opacification
T Agarwal, N Sharma, V Jhanji, R B Vajpayee

Cover illustration

26 All for a drop: Undines and drop bottles
R Keeler, A D Singh, H S Dua

Original articles

Clinical science

28 A novel Ocular Anaesthetic Scoring System, OASS, tool to measure both motor and sensory function following local anaesthesia
J Cehajic-Kapetanovic, P N Bishop, S Liyanage, T King, M Muldoon, I M Wearne

33 Intraocular pressures after ketamine and sevoflurane in children with glaucoma undergoing examination under anaesthesia
L Jones, V Sung, G Lascaratos, H Nagi, R Holder

36 A pilot randomised controlled trial comparing the post-operative pain experience following vitrectomy with a 20-gauge system and the 25-gauge transconjunctival system
L Wickham, C Bunce, A S Kwan, J Bainbridge, G W Aylward

41 Macular morphology and visual acuity after macular hole surgery with or without internal limiting membrane peeling
U C Christensen, K Krøyer, B Sander, T M Jorgensen, M Larsen, M la Cour

48 Subretinal coapplication of recombinant tissue plasminogen activator and bevacizumab for neovascular age-related macular degeneration with submacular haemorrhage
F Treumer, C Klatt, J Roider, J Hillenkamp

54 New patterns of retinal collateral circulation are exposed by a retinal functional imager (RFI)
G Landa, R B Rosen

59 Relationship between different fluorescein and indocyanine green angiography features in multiple evanescent white dot syndrome
R dell'Omo, R Wong, M Marino, K Konstantopoulou, C Pavesio

64 A comparison between microperimetry and standard achromatic perimetry of the central visual field in eyes with glaucomatous paracentral visual-field defects
V C Lima, T S Prata, C G V De Moraes, J Kim, W Seiple, R B Rosen, J M Liebmann, R Ritch

68 The sensitivity and specificity of Heidelberg Retina Tomograph parameters to glaucomatous progression in disc photographs
V Saarela, A Falck, P J Airaksinen, A Tuulonen

74 Efficacy and tolerability of bimatoprost versus travoprost in patients previously on latanoprost: a 3-month, randomised, masked-evaluator, multicentre study
J A Kammer, B Katzman, S L Ackerman, D A Hollander

80 Using diurnal intraocular pressure fluctuation to assess the efficacy of fixed-combination latanoprost/timolol versus latanoprost or timolol monotherapy
R Varma, L-J Hwang, J W Grunden, G W Bean

MORE CONTENTS ►

EDITOR'S CHOICE

This article has been chosen by the Editor to be of special interest or importance and is freely available online.

Articles carrying the Unlocked Logo are freely available online under the BMJ Journals unlocked scheme. See **http://bjo.bmj.com/info/unlocked.dtl**

COPE COMMITTEE ON PUBLICATION ETHICS

This journal is a member of and subscribes to the principles of the Committee on Publication Ethics

www.publicationethics.org.uk

equator network

recycle
When you have finished with this magazine please recycle it.

85 The effect of socio-economic deprivation on severity of glaucoma at presentation
W S Ng, P K Agarwal, S Sidiki, L McKay, J Townend, A Azuara-Blanco

88 Visual training of cerebral blindness patients gradually enlarges the visual field
D P Bergsma, G van der Wildt

97 Scope of super-resolution in central vision
L Frisén

101 Evaluation of the impact of intracorneal ring segments implantation on the quality of life of patients with keratoconus using the NEI-RQL (National Eye Institute Refractive Error Quality of life) instrument
J de Freitas Santos Paranhos, M P Ávila, A Paranhos Jr, P Schor

106 Evaluation of the Lenstar LS 900 non-contact biometer
L P J Cruysberg, M Doors, F Verbakel, T T J M Berendschot, J De Brabander, R M M A Nuijts

111 Endophthalmitis following open globe injury
Y Zhang, M N Zhang, C H Jiang, Y Yao, K Zhang

115 Peripapillary retinal nerve fibre layer thickness profile in subjects with myopia measured using the Stratus optical coherence tomography
M J Kim, E J Lee, T-W Kim

121 Ophthalmological findings in children and young adults with genetically verified mitochondrial disease
M A Grönlund, A K Seyedi Honarvar, S Andersson, A R Moslemi, A Oldfors, E Holme, M Tulinius, N Darin

128 A prospective comparison of fine-needle aspiration cytopathology and histopathology in the diagnosis of orbital mass lesions
Z A Karcioglu, J C Fleming, B G Haik

Education

131 Papilloedema and vision loss with elevated cerebrospinal fluid protein in a patient with systemic lupus erythematosus: diagnosis and management challenges
E K Deschler, N R Miller, P S Subramanian

PostScript

133 Letters

139 Mailbox

Take a closer look at the latest research

The British Journal of Ophthalmology keeps you right up to date with the clinical investigations and observations related to ophthalmology, so you'll want the guarantee of reading it every month.

Why not recommend the journal to your librarian or better still, obtain your own personal subscription? You will receive a paper copy every month as well as online access for just £169 a year (€228, $330). Too much paper on your desk already? An online subscription is just £106 (€143, $207).

Visit **group.bmj.com/group/subs-sales** - your subscription to this first class journal is just a few clicks away.

bjo.bmj.com BMJ|Journals

Ranibizumab (Lucentis) in neovascular age-related macular degeneration: evidence from clinical trials

P Mitchell,[1] J-F Korobelnik,[2] P Lanzetta,[3] F G Holz,[4] C Prünte,[5] U Schmidt-Erfurth,[5] Y Tano,[6] S Wolf[7]

[1] Department of Ophthalmology, University of Sydney, Sydney, Australia; [2] Department of Ophthalmology, Centre Hospitalier Universitaire de Bordeaux, Bordeaux, France; [3] Department of Ophthalmology, University of Udine, Udine, Italy; [4] Department of Ophthalmology, University of Bonn, Bonn, Germany; [5] Department of Ophthalmology and Optometry, Medical University of Vienna, Vienna, Austria; [6] Department of Ophthalmology, Osaka University Medical School, Osaka, Japan; [7] Department of Ophthalmology, Inselspital, University of Bern, Bern, Switzerland

Correspondence to: Professor P Mitchell, Eye Clinic (B4A), Westmead Hospital, Hawkesbury Road, Westmead, NSW, 2145, Australia; paul_mitchell@wmi.usyd.edu.au

Accepted 29 April 2009
Published Online First 20 May 2009

ABSTRACT

Background: Neovascular age-related macular degeneration (AMD) has a poor prognosis if left untreated, frequently resulting in legal blindness. Ranibizumab is approved for treating neovascular AMD. However, further guidance is needed to assist ophthalmologists in clinical practice to optimise treatment outcomes.

Methods: An international retina expert panel assessed evidence available from prospective, multicentre studies evaluating different ranibizumab treatment schedules (ANCHOR, MARINA, PIER, SAILOR, SUSTAIN and EXCITE) and a literature search to generate evidence-based and consensus recommendations for treatment indication and assessment, retreatment and monitoring.

Results: Ranibizumab is indicated for choroidal neovascular lesions with active disease, the clinical parameters of which are outlined. Treatment initiation with three consecutive monthly injections, followed by continued monthly injections, has provided the best visual-acuity outcomes in pivotal clinical trials. If continued monthly injections are not feasible after initiation, a flexible strategy appears viable, with monthly monitoring of lesion activity recommended. Initiation regimens of fewer than three injections have not been assessed. Continuous careful monitoring with flexible retreatment may help avoid vision loss recurring. Standardised biomarkers need to be determined.

Conclusion: Evidence-based guidelines will help to optimise treatment outcomes with ranibizumab in neovascular AMD.

Neovascular age-related macular degeneration (AMD) causes severe and irreversible vision loss, and frequently results in legal blindness, with resulting considerable economic burden.[1–5]

Pharmacotherapies against vascular endothelial growth factor-A (VEGF-A), a key factor in the pathogenesis of choroidal neovascularisation (CNV), have been introduced to treat neovascular AMD.[6–10] Pegaptanib sodium (Macugen, EyeTech, New York), a selective antagonist of the 165 isoform of VEGF-A,[11] was approved by the Food and Drug Administration (FDA) in December 2004. Ranibizumab (Lucentis, Novartis Pharma AG, Basel, Switzerland and Genentech, South San Francisco, California), a recombinant, humanised, monoclonal antibody Fab fragment that inhibits all biologically active VEGF-A isoforms, was approved by the FDA in June 2006 (monthly 0.5 mg intravitreal injection).[12–14] Bevacizumab (Avastin, Genentech), a full-length monoclonal antibody against all VEGF-A isoforms, was approved by the FDA for colorectal cancer in 2004 and later used intravitreally off-label in neovascular AMD.[15 16] Head-to-head ranibizumab and bevacizumab trials are under way but are not scheduled to report until 2010 (CATT (NCT00593450), VIBERA (NCT00559715), IVAN and GEFAL trials).

Although preliminary guidelines for anti-VEGF therapies exist,[16–22] more comprehensive clinical practice guidelines on applying ranibizumab are needed to optimise patient outcomes. Ranibizumab Phase III clinical trials in neovascular AMD have studied different treatment schedules, doses and populations, and this review applies the trial evidence to ranibizumab use in clinical practice. We evaluated the licensed 0.5 mg of ranibizumab dose, shown to be more effective than 0.3 mg in pivotal trials,[12 13 23] and focused solely on ranibizumab because: pegaptanib showed less visual-acuity (VA) decline than sham injection, although on average treated patients continued to experience vision loss;[11] bevacizumab use in neovascular AMD currently remains off-label with relatively few reported clinical trial data and, to date, no completed large, prospective, randomised clinical trials.[16]

RANKING AND SOURCES OF EVIDENCE

Level I indicates strong evidence (eg, well-designed, randomised, controlled clinical trials that address the issue in question); level II indicates substantial evidence that lacks some qualities (eg, derived from randomised clinical trials but with flaws, such as absent control group or sufficiently long follow-up); level III indicates relatively weak evidence (eg, derived from non-comparative studies without controls, descriptive studies, panel consensus or expert opinion).

A PubMed literature search on 31 October 2008 (restricted to English literature; no date restriction) using the MeSH term macular degeneration (multi) and the words vascular endothelial growth factor, ranibizumab or Lucentis yielded 187 papers. The Cochrane Register of Controlled Trials and the Cochrane Database of Systematic Reviews were also searched, yielding 16 and four references, respectively. A total of 129 relevant articles were selected, from which 74 were selected for detailed assessment. Additional data from abstracts considered relevant to this manuscript were included in the analysis. From this detailed literature search, the primary sources of data were all level I evidence: the Phase III trials MARINA[13] and ANCHOR,[12 24] including quality-of-life and subgroup analyses,[25–28] and the Phase IIIb trials PIER,[23] SAILOR Cohort 1,[29] SUSTAIN (assigned level II evidence as only interim data currently available),[30] and EXCITE[31]. A small, open-label study

Br J Ophthalmol 2010;94:2–13. doi:10.1136/bjo.2009.159160

Table 1 Recommendations for treatment indication with ranibizumab

Parameters for recommended indication	Evidence	Level of evidence
Predominantly classic, minimally classic and occult (with no classic component) CNV*	All CNV types included in PIER, EXCITE, SUSTAIN, SAILOR and PrONTO; predominantly classic CNV in ANCHOR and minimally classic and occult (with no classic component) CNV in MARINA	Level I evidence (MARINA, ANCHOR, PIER, EXCITE and SAILOR), supported by level II (SUSTAIN) and III evidence (PrONTO)
Subfoveal (including juxtafoveal) lesions	Subfoveal CNV (defined as including the foveal centre within the boundaries of the CNV) was an inclusion criteria in all studies	Level I evidence (MARINA, ANCHOR, PIER, EXCITE and SAILOR), supported by level II (SUSTAIN) and III evidence (PrONTO)
Active disease	Active disease was an inclusion criteria in the MARINA and PIER studies†	Level I evidence (MARINA and PIER) and level III evidence
Abnormal retinal thickness with evidence of intraretinal or subretinal fluid by OCT		
Intraretinal or subretinal haemorrhage		
Enlargement of CNV size on FA unless solely due to dry, fibrotic staining		
New/persistent leakage on FA		
Any baseline VA	Baseline VA 20/40 to 20/320 was an inclusion criterion in all studies‡	Level I evidence (MARINA, ANCHOR, PIER and SAILOR), supported by level II evidence (SUSTAIN)
Efficacy was seen over the whole VA range studied in trials, so it is expected that benefit would occur independently of VA whenever progressive vision loss is expected due to an active lesion	Baseline VA better than 20/40 or worse than 20/320: no clinical data available, expert opinion based on extrapolation of clinical evidence	Level III evidence
Serous PED, RAP or PCV can be considered for ranibizumab treatment but might not respond as well as expected from average trial outcomes	No detailed clinical trial evidence currently available	Level III evidence

*In the MARINA and PIER studies, evidence of recent disease progression was required for eyes with minimally classic or occult (with no classic) CNV.
†Active disease was defined as meeting any of the following criteria: (1) ⩾10% increase in lesion size by comparing a fluorescein angiogram performed within 1 month preceding day 0, inclusive, compared with a fluorescein angiogram performed within 6 months preceding day 0, inclusive; (2) resulting in VA loss of >1 Snellen line (or equivalent) and occurring at any time within the prior 6 months; (3) subretinal haemorrhage associated with CNV within 1 month preceding day 0; or (4) (not included in MARINA criteria) classic CNV comprised ⩾50% of the CNV lesion area.
‡Snellen equivalent assessed by Early Treatment Diabetic Retinopathy Study charts; the PrONTO study included patients with baseline VA from 20/40 to 20/400.
CNV, choroidal neovascularisation; FA, fluorescein angiography; OCT, optical coherence tomography; PCV, polypoidal choroidal vasculopathy; PED, pigment epithelial detachment; RAP, retinal angiomatous proliferation; VA, visual acuity.

(PrONTO; level III evidence) also provided relevant information,[32] and appropriate abstracts covering recent Phase III trial findings (unpublished) were included.

NATURAL HISTORY AND ASSESSMENT OF NEOVASCULAR AMD

What is the natural history or prognosis of untreated neovascular AMD?

A systematic review covering the period 1980 to 2005 assessed studies reporting disease progression outcomes for untreated patients with neovascular age-related macular degeneration (AMD), by using random effects meta-analyses.[4] Of 53 studies included, there were 28 randomised clinical trials (RCTs), totalling 4362 patients with untreated neovascular AMD. The most recent RCTs of antivascular endothelial growth factor therapy (VISION,[11] MARINA[13] and PIER[23]) were not included. The systematic review found that, on average, one logarithm of the maximum angle of resolution (logMAR) line of visual acuity (VA) was lost by 3 months, three lines by 1 year and four lines by 2 years. This prognosis is relatively similar to that in MARINA, in which sham-treated eyes lost an average of two lines by 1 year and three lines by 2 years and in PIER, in which sham-treated eyes lost an average of three lines by 1 year. In this review, a doubling of the visual angle was found in the first year. At baseline, 20% of eyes already had a VA <20/200, but this proportion rose to 76% by 3 years.[4]

How should neovascular AMD be diagnosed?

Accurate diagnosis and classification of neovascular AMD using recommended criteria is critical. Assessment should include: history (duration and characteristics of visual symptoms); VA; stereoscopic biomicroscopic slit-lamp fundus examination (78 D or similar lens); fluorescein angiography (FA); and, where possible, optical coherence tomography (OCT).

Logarithm of the minimum angle of resolution (logMAR) VA is preferable to Snellen VA due to its greater sensitivity, ordered progression of letter size (five equally readable letters per line), reproducibility and ability to compare with published trial data.[33] The Snellen chart has several limitations such as visual crowding and variable legibility of the letters. Non-geometric letter size progression and a variable number of letters per line also prevent Snellen outcomes from being easily equated to letters or lines of VA change.[34 35]

For initial diagnosis, FA is deemed mandatory to detect CNV, exclude non-AMD causes (eg, neovascularisation due to myopia, pseudo-xanthoma elasticum, birdshot choroidopathy, etc, which could respond differently to AMD neovascularisation) and determine CNV extent, type, size, location, degree of leakage and proportion of various lesion components.[18 36] OCT is also strongly recommended initially to define the extent of retinal thickening and both the localisation and qualitative pattern of extracellular fluid accumulation.[37 38] Indocyanine Green (ICG) angiography may also be useful in selected cases, eg, when polypoidal choroidal vasculopathy (PCV)[4 39 40] or retinal angiomatous proliferation (RAP)[41–43] is suspected, or the extent of CNV in occult lesions is unclear.

RANIBIZUMAB THERAPY FOR NEOVASCULAR AMD: INDICATIONS AND CONTRAINDICATIONS

Which neovascular AMD lesions should be considered for ranibizumab treatment?

All three major CNV subtypes (predominantly classic, occult (with no classic component) and minimally classic) respond to ranibizumab[12 13] (table 1). Ranibizumab is primarily indicated

for subfoveal (which could also be defined to include juxtafoveal[44]) lesions with "active disease."

The concept of active neovascular AMD is central to these guidelines (level III evidence). A similar concept was proposed in developing guidelines for verteporfin photodynamic therapy (PDT) for AMD and retreatment using specific clinical parameters.[45 46] Anti-VEGF therapy specifically targets angiogenesis and vascular permeability,[6 47 48] and the active disease concept has evolved to encompass the hallmarks of neovascular disease such as persistent or recurrent extracellular fluid.

The following "starting criteria" (level III evidence) to define active disease may assist in identifying suitable patients for ranibizumab treatment:

- abnormal retinal thickness, particularly with evidence of intraretinal, subretinal or subpigment epithelial fluid accumulation, optimally confirmed by OCT;
- presence (or recurrence) of intraretinal or subretinal haemorrhage;
- new or persistent leakage shown on FA;
- CNV enlargement on FA unless solely due to dry, fibrotic staining;
- VA deterioration, considered likely to represent CNV activity.

In retrospective analyses of 24-month MARINA study data, ranibizumab was superior to sham across all subgroups based on patient age, gender, CNV lesion type, lesion size, baseline VA and AMD duration.[26] VA outcomes were predicted by baseline VA, then CNV lesion size and age (level I evidence). Importantly, for CNV lesion size, smaller lesions had a better prognosis than larger lesions. A subgroup analysis of 12-month ANCHOR study data showed similar results.[28]

Although clinical data are only available for baseline VA levels of 20/40 (6/12) to 20/320 (6/48), the initial baseline VA was not a limiting factor for response to ranibizumab: all baseline VA subgroups gained with treatment.[26 28] For example, cases with active subfoveal/juxtafoveal CNV and VA better than 20/40 should always be considered for treatment, as these have the potential to retain the best possible vision outcomes, particularly for tasks such as reading and driving.

Although the trials did not include cases with the following criteria, no evidence suggests that ranibizumab should be withheld in these populations (level III evidence):[17 18]

- haemorrhage or serous pigment epithelial detachment (PED) involving an area >50% of the entire CNV lesion, particularly if any CNV can be documented before treatment (eg, using ICG);
- glaucoma or elevated intraocular pressure;
- advanced cataract—cataract surgery should generally follow ranibizumab therapy.

Lesion characteristics such as isolated serous PED without documented CNV,[49] RAP or PCV have not been investigated sufficiently in ranibizumab trials. These cases may be considered for ranibizumab therapy, but they might not respond as well, or may respond more slowly,[50] than would be expected from the average trial outcomes of other occult lesions. Current trials are investigating some of these subtypes (eg, ranibizumab Phase IV EVEREST PCV trial; clinical trials' identifier NCT00674323).

What characteristics suggest that ranibizumab would likely be futile?

Based on expert opinion (level III evidence),[17 18] and some clinical trial evidence, patients with active disease, but for whom treatment is not generally recommended, were defined by the following criteria:

- Structural foveal damage: advanced subretinal fibrosis or significant geographic atrophy involving the foveal centre (both particularly important if longstanding, as any functional benefit from treatment would be unlikely).
- Confounding severe ocular disease: vitreous or preretinal haemorrhage obscuring the central macula, or presence of rhegmatogenous retinal detachment (other forms of immediate therapy, eg, vitrectomy, may be indicated before reconsidering ranibizumab).

Retinal pigment epithelial (RPE) tears with subfoveal involvement have been reported to occur occasionally following intravitreal ranibizumab,[49 51–55] and may therefore be a relative contraindication. However, to date, no data indicate that continuing ranibizumab in such cases would be deleterious (level III evidence).

COMMENCING AND CONTINUING RANIBIZUMAB THERAPY FOR NEOVASCULAR AMD

What are appropriate intervals for the initiation of ranibizumab treatment?

Evidence

Ranibizumab initiation with three consecutive monthly injections appears optimal as this is when the majority of patients experienced most VA gain in all studies (fig 1A–F, tables 2, 3). Improvements occurred rapidly, and the largest VA gain occurred after the first injection. Several studies indicate that untreated subfoveal CNV may grow quickly, on average around 10 μm per day.[56] Furthermore, after the first month in the PIER trial, VA deteriorated in the untreated control group by a mean of five letters (one line).[23] A recent study reported that delayed initiation of treatment in patients with newly diagnosed AMD was associated with substantial VA loss.[57]

MARINA, ANCHOR[12 13 24] and the EXCITE ranibizumab active control arm[31] were the only Phase III studies with monthly injections throughout the whole treatment period. Most VA improvement was seen during the initial 3-month phase with subsequent injections appearing to maintain the achieved benefit (fig 2). Prospective clinical trials would be valuable for investigating fewer injections in the initiation phase.

Clinical recommendation (level I evidence)

- 0.5 mg of ranibizumab should be initiated with at least three consecutive monthly intravitreal injections, using an aseptic procedure.[58]
- Treatment should be commenced as soon as possible after diagnosis. As an indication of this time interval, the screening periods permitted before treatment initiation in the clinical studies were ⩽14 or ⩽28 days. Clearly, treatment as early as possible, and at a maximum of within 2 weeks of diagnosis, is ideal. Durations longer than 1 month risk increasing visual loss.[23 56]
- Before administering ranibizumab at months 1 and 2, follow-up examination is recommended: history, VA assessment and slit-lamp fundus examination to identify any ocular side effects or major criteria for treatment failure or discontinuation.
  - FA is generally recommended only for patients with significant or unexplained vision loss, at the ophthalmologist's discretion.

OCT detects, localises, classifies and quantifies intraretinal, subretinal and sub-RPE fluid, and is therefore recommended to

Br J Ophthalmol 2010;94:2–13. doi:10.1136/bjo.2009.159160

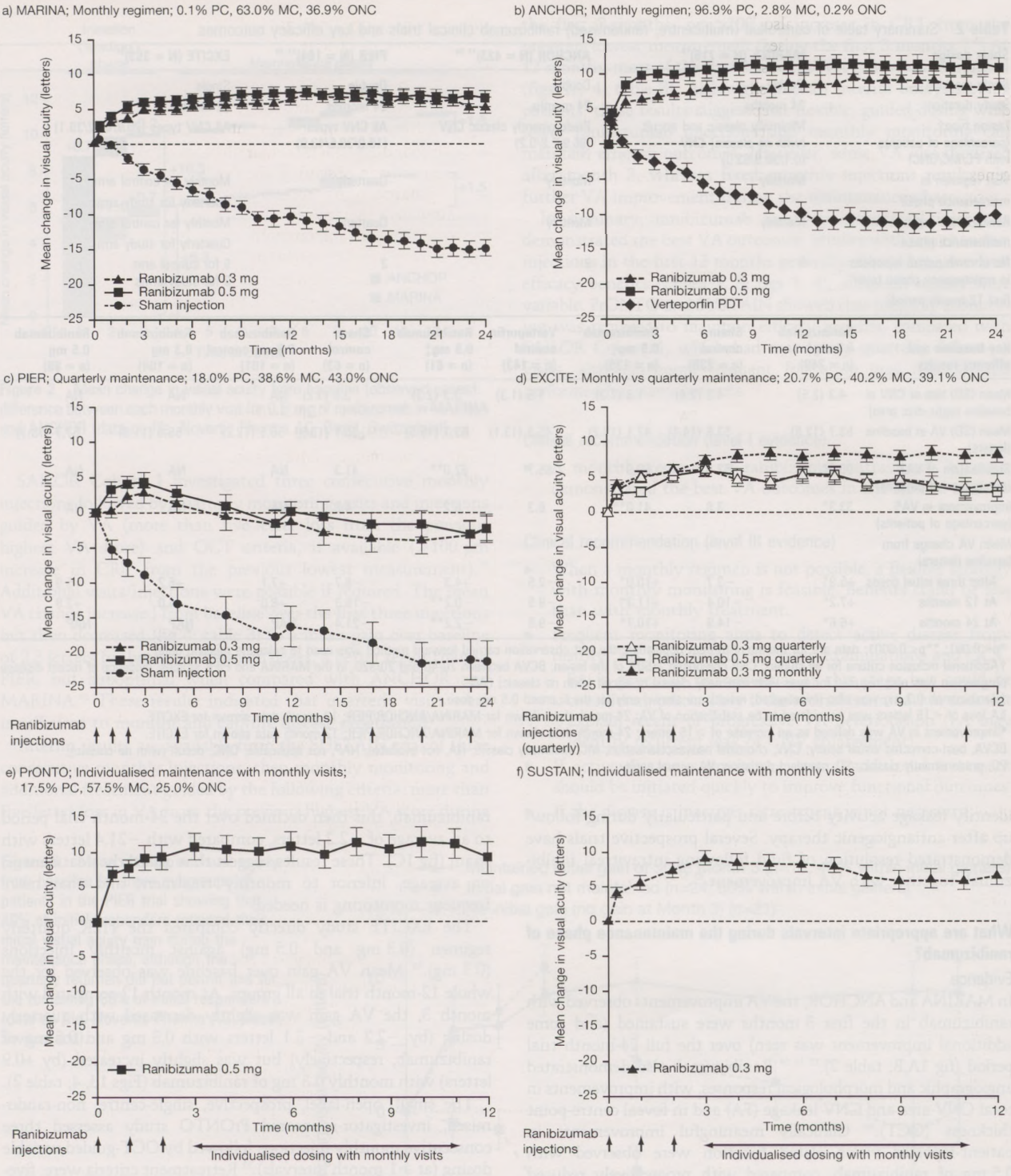

The LOCF method was used to impute missing data.
Vertical bars are ±1 standard error of the mean.
LOCF=last observation carried forward; PC=predominantly classic; PDT=photodynamic therapy; MC=minimally classic; ONC=occult (with no classic)

Figure 1 Mean change from baseline in best-corrected visual acuity by month for (A) MARINA, (B) ANCHOR, (C) PIER, (D) EXCITE, (E) PrONTO, (F) SUSTAIN ((A) Copyright© 2006 Massachusetts Medical Society. All rights reserved; (B) reprinted from *Ophthalmology* 2009, 116, Brown *et al*, Ranibizumab versus verteporfin photodynamic therapy for neovascular age-related macular degeneration: 2-year results of ANCHOR Study, 57–65, Copyright 2009, with permission from Elsevier; (C) reprinted from Regillo *et al*, Ranibizumab (Lucentis) in treatment of neovascular age-related macular degeneration (AMD): 2-year results of PIER study, poster PO459 presented at the AAO 2007; (E) reprinted from *Am J Ophthalmol* 2007, 143, Fung *et al*, An optical coherence tomography-guided, variable dosing regimen with intravitreal ranibizumab (Lucentis) for neovascular age-related macular degeneration, 566–83, Copyright 2007, with permission from Elsevier).

Table 2 Summary table of controlled (multicentre, randomised) ranibizumab clinical trials and key efficacy outcomes

Study design	MARINA (N = 716)[13]	ANCHOR (N = 423)[12 24]	PIER (N = 184)[23 59]	EXCITE (N = 353)[31]
Study masking	Double	Double	Double	Single
Study duration	24 months	24 months	24 months	12 months
Lesion type† (percentage of patients with PC/MC/ONC)	Minimally classic and occult (with no classic) CNV (0.1/36.9/63.0)	Predominantly classic CNV (96.9/2.8/0.2)	All CNV types (18.0/38.6/43.0)	All CNV types (20.7/40.2/39.1)
Visit regimen in maintenance phase	Monthly	Monthly	Quarterly	Monthly for control arm Quarterly for study arms
Ranibizumab regimen in maintenance phase	Monthly	Monthly	Quarterly	Monthly for control arm Quarterly for study arms
No of ranibizumab injections in maintenance phase (over first 12-month period)	9	9	3	9 for control arm 3 for study arms

Key baseline and efficacy results	Ranibizumab 0.5 mg‡ (n = 240)	Sham control (n = 238)	Ranibizumab 0.5 mg‡ (n = 139)	Verteporfin control (n = 143)	Ranibizumab 0.5 mg‡ (n = 61)	Sham control (n = 63)	Ranibizumab 0.3 mg control (n = 101)	Ranibizumab 0.3 mg (n = 104)	Ranibizumab 0.5 mg (n = 88)
Mean (SD) size of CNV at baseline (optic-disc area)	4.3 (2.5)	4.3 (2.4)	1.3 (1.2)	1.5 (1.3)	3.3 (2.3)	3.6 (3.2)	NA	NA	NA
Mean (SD) VA at baseline (letters)	53.7 (12.8)	53.6 (14.1)	47.1 (13.2)	45.5 (13.1)	53.7 (15.5)	55.1 (13.9)	56.5 (12.2)	55.8 (11.8)	57.7 (13.1)
Stabilisation of VA§ (percentage of patients)	90.0*	52.9	89.9**	65.7	82.0**	41.3	NA	NA	NA
Improvement in VA¶ (percentage of patients)	33.3*	3.8	41.0**	6.3	8.2	4.8	NA	NA	NA
Mean VA change from baseline (letters)									
After three initial doses	+5.9*	−3.7	+10.0*	−2.5	+4.3	−8.7	+7.1	+6.2	+5.9
At 12 months	+7.2*	−10.4	+11.3*	−9.5	−0.2**	−16.3	+8.0	+4.0	+2.8
At 24 months	+6.6*	−14.9	+10.7*	−9.8	−2.2**	−21.4	NAP	NAP	NAP

*p<0.001; **p<0.0001; data are for the intent-to-treat population; the last observation carried forward method was used to calculate missing data;
†Additional inclusion criteria for all studies: CNV comprised ⩾50% of the lesion; BCVA between 20/40 and 20/320. In the MARINA and PIER studies, evidence of recent disease progression was also required for eyes with minimally classic or occult (with no classic) CNV.
‡Ranibizumab 0.3 mg was also investigated; results are shown only for the licensed 0.5 mg dose.
§A loss of <15 letters was considered to be stabilisation of VA; 24-month data shown for MARINA/ANCHOR/PIER; 12-month data shown for EXCITE.
¶Improvement in VA was defined as an increase of ⩾15 letters; 24-month data shown for MARINA/ANCHOR/PIER; 12-month data shown for EXCITE.
BCVA, best-corrected visual acuity; CNV, choroidal neovascularisation; MC, minimally classic; NA, not available; NAP, not applicable; ONC, occult (with no classic); PC, predominantly classic; SD, standard deviation; VA, visual acuity.

identify leakage activity before and particularly during follow-up after antiangiogenic therapy. Several prospective trials have demonstrated resolution of fluid following intravitreal ranibizumab together with VA improvement.[32 37 38]

What are appropriate intervals during the maintenance phase of ranibizumab?

Evidence

In MARINA and ANCHOR, the VA improvements observed with ranibizumab in the first 3 months were sustained (and some additional improvement was seen) over the full 24-month trial period (fig 1A,B; table 2).[12 13 24] Ranibizumab also demonstrated angiographic and morphological responses, with improvements in total CNV area and CNV leakage (FA) and in foveal centre-point thickness (OCT).[60] Clinically meaningful improvements in patient-reported vision-related function were observed with 0.5 mg of ranibizumab, compared with progressively reduced function with sham (MARINA)[25] and verteporfin PDT (ANCHOR).[27] These improvements were maintained over the 24-month study period, paralleling the objective VA improvements and, importantly, occurred with treatment of only one eye.

In the PIER study of three consecutive monthly injections followed by fixed quarterly injections,[23] ranibizumab demonstrated a clinically meaningful (three lines or more) benefit in mean VA change from baseline compared with sham at 12 and 24 months (figs 1C, 3; table 2). However, although the mean VA improved from baseline in the first 3 months with ranibizumab, this then declined over the 24-month trial period to an average of −2.2 letters, compared with −21.4 letters with sham (fig 1C). These results suggest that quarterly treatment is, on average, inferior to monthly treatment and that more frequent monitoring is needed.

The EXCITE study directly compared the PIER quarterly regimen (0.3 mg and 0.5 mg) against monthly injections (0.3 mg).[31] Mean VA gain over baseline was observed for the whole 12-month trial in all groups. At month 12 compared with month 3, the VA gain was slightly decreased with quarterly dosing (by −2.2 and −3.1 letters with 0.3 mg and 0.5 mg of ranibizumab, respectively) but was slightly increased (by +0.9 letters) with monthly 0.3 mg of ranibizumab (Figs 1d, 4; table 2).

The small, open-label, prospective, single-centre, non-randomised, investigator-sponsored PrONTO study assessed three consecutive monthly injections followed by OCT-guided variable dosing (at ⩾1 month intervals).[32] Retreatment criteria were: five-letter loss in the presence of fluid at the macula detected by optical coherence tomography (OCT); ⩾100 μm increase in central retinal thickness (CRT); new-onset classic choroidal neovascularisation (CNV); new macular haemorrhage; or persistent macular fluid detected by OCT. While similar VA outcomes to the MARINA and ANCHOR trials were demonstrated but with fewer intravitreal injections (figs 1E, 4; tables 2, 3), substantial trial design differences limit comparisons. Although small and open label, this study suggests that flexible OCT-guided retreatment could sustain visual gain with fewer injections.

Br J Ophthalmol 2010;**94**:2–13. doi:10.1136/bjo.2009.159160

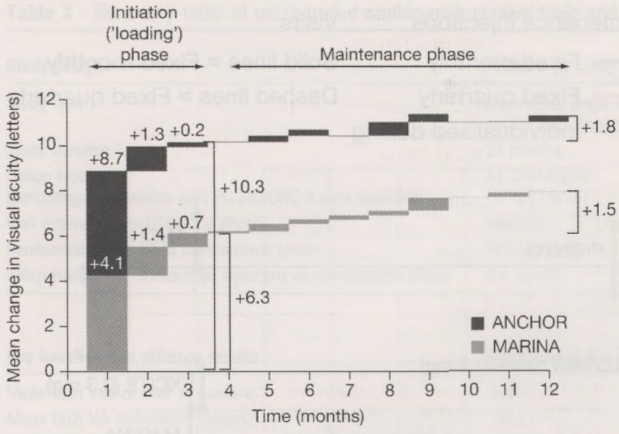

Figure 2 Mean change in visual acuity from baseline (observed cases): difference between each monthly visit for 0.5 mg of ranibizumab in MARINA and ANCHOR (data on file, Novartis Pharma AG, Basel, Switzerland).

SAILOR Cohort 1 investigated three consecutive monthly injections followed by quarterly monitoring visits and injections guided by VA (more than five-letter loss from the previous highest VA score) and OCT criteria, if available (>100 μm increase in CRT from the previous lowest measurement).[29] Additional visits/injections were possible if required. The mean VA change increased from baseline over the first three injections but then decreased (fig 4; table 3) to a mean gain over baseline of 2.3 letters for both ranibizumab doses, a better result than in PIER, but suboptimal when compared with ANCHOR and MARINA.[61] These results indicated that quarterly visits were insufficient to monitor and capture disease progression.

Interim results are available from the SUSTAIN trial of three consecutive monthly injections, then monthly monitoring and additional treatment guided by the following criteria: more than five-letter loss in VA from the previous highest VA score during the first 3 months; or >100 μm increase in CRT from the previous lowest measurement during the first 3 months.[30 62] At 12 months, most of the first 3 months' VA gain was maintained (figs 1F, 4; table 3). Although only an interim analysis of 69 patients, these results suggest that flexible, guided dosing with fewer ranibizumab injections and monthly monitoring can maintain efficacy outcomes. However, some VA loss occurred after month 3, whereas fixed monthly injections resulted in further VA improvement during the maintenance phase.

In summary, ranibizumab monthly intravitreal injections demonstrated the best VA outcomes. Studies with less than five injections in the first 12 months generally showed the weakest efficacy benefits (tables 2, 3; figs 1, 4), although results were variable. PrONTO and SUSTAIN showed that monthly monitoring was required to maintain efficacy benefits, compared with SAILOR Cohort 1, which had mandatory quarterly follow-up visits, although more frequent follow-up was possible and performed for many patients.

Clinical recommendation (level I evidence)

- A monthly regimen of ranibizumab intravitreal injection demonstrated the best VA outcomes in the clinical trials.

Clinical recommendation (level III evidence)

- When a monthly regimen is not possible, a flexible strategy with monthly monitoring is feasible. Benefits could be less than with monthly treatment.
- Frequent monitoring aims to detect active disease from: history, VA assessments, slit-lamp examinations and OCT.
  - FA is generally not essential at this stage but could be considered, particularly if the retinal examination does not explain recent or progressive VA deterioration (FA may identify recurrent leak or CNV enlargement).
- If active disease is present or recurs, additional treatment should be initiated quickly to improve functional outcomes.
- If the disease is inactive, retreatment is not necessary.

Figure 3 Mean change in visual acuity from baseline for three subgroups of patients in the PIER trial showing that 40% of initial responders retained their initial visual acuity gain during the maintenance phase, although the quarterly regimen did not permit this for the remaining 60% of initial responders (data on file, Novartis Pharma AG, Basel, Switzerland).

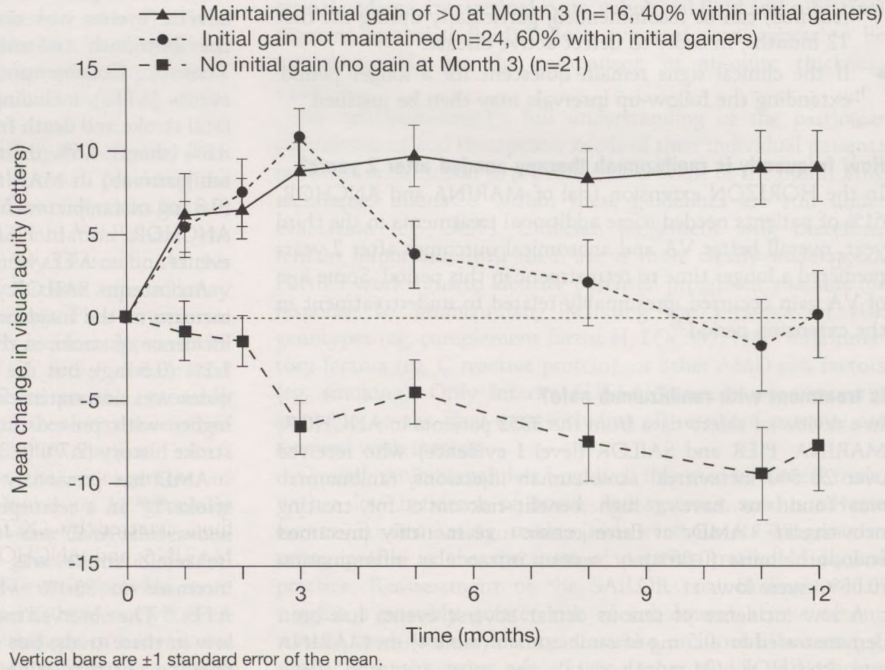

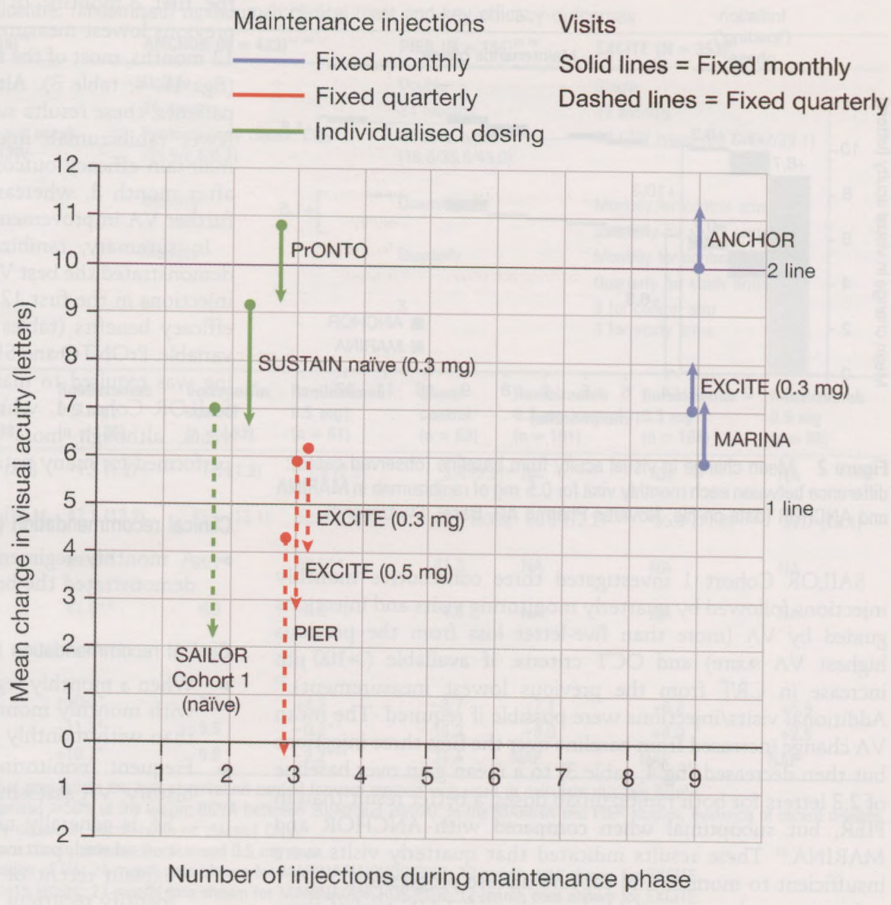

Figure 4 Mean change in visual acuity from baseline at the end of the loading phase (●) and at 12 months (arrowhead) against the number of injections during 9 months of the maintenance phase (ranibizumab 0.5 mg data unless indicated).

- In both cases, patients should be reviewed at each following month using the same assessments, with treatment administered only if active disease is present.
- Continued monthly follow-up (with an injection if required) can be recommended, particularly during the first 12 months, in order to detect active disease.
- If the clinical signs remain quiescent for a longer period, extending the follow-up intervals may then be justified.

How frequently is ranibizumab therapy needed after 2 years?

In the HORIZON extension trial of MARINA and ANCHOR, 61% of patients needed some additional treatments in the third year; overall better VA and anatomical outcomes after 2 years predicted a longer time to retreatment in this period. Some loss of VA gain occurred, presumably related to undertreatment in the extension period.[63]

Is treatment with ranibizumab safe?

In a review of safety data from the 3252 patients in ANCHOR, MARINA, PIER and SAILOR (level I evidence) who received over 28 500 intravitreal ranibizumab injections, ranibizumab was found to have a high benefit–risk ratio for treating neovascular AMD.[64] Per-injection rates of presumed endophthalmitis (0.05%) or serious intraocular inflammation (0.03%) were low.

A low incidence of serious ocular adverse events has been demonstrated for 0.5 mg of ranibizumab (table 4). In MARINA and ANCHOR (24-month data), the most common were: presumed endophthalmitis (1.3% in MARINA; 1.4% in ANCHOR) and uveitis (1.3% in MARINA; 0.7% in ANCHOR).[12 13 24]

In MARINA and ANCHOR, the incidence of systemic adverse events was similar across treatment groups. During the 24-month treatment period, the rates of Antiplatelet Trialists' Collaboration (APTC)[65] arterial thromboembolic events (ATEs), including non-fatal myocardial infarction, non-fatal stroke and death from a vascular or unknown cause, were: 3.8% (sham), 4.6% (0.3 mg of ranibizumab) and 4.6% (0.5 mg of ranibizumab) in MARINA; and 4.2% (verteporfin PDT), 4.4% (0.3 mg of ranibizumab) and 5.0% (0.5 mg of ranibizumab) in ANCHOR.[12 13 24] In PIER, a low rate of serious ocular adverse events and no ATEs were observed with ranibizumab (table 4).[23]

An interim SAILOR safety analysis showed a trend for an increase in the incidence of stroke in the 0.5 mg group. The incidence of stroke in the final analysis was 0.7% (0.3 mg) and 1.2% (0.5 mg), but the numerical difference between the two doses was not statistically significant. Incidence of stroke was higher with pre-existing risk factors, particularly a previous stroke history (2.7% (0.3 mg) and 9.6% (0.5 mg)) or arrhythmia.

AMD has previously been associated with a higher risk of stroke.[66–68] In a retrospective analysis of 15 771 patients with neovascular AMD and 46 408 matched controls, the incidence of ischaemic stroke was 3.5% and 3.6%, respectively, which increased to 35.1% when there was a history of previous ATEs.[66] The observed incidence of stroke with ranibizumab was low in these trials, but needs to be continuously monitored in ongoing postmarketing studies. Nevertheless, the benefit–risk

Br J Ophthalmol 2010;**94**:2–13. doi:10.1136/bjo.2009.159160

Table 3 Summary table of uncontrolled ranibizumab clinical trials and key efficacy outcomes

Study design	PrONTO (N = 40)[32]	SUSTAIN (N = 531; interim data available for n = 69)[30]	SAILOR Cohort 1 (N = 2378)[29]
Study type	Open-label, single-centre, non-randomised, investigator-sponsored	Open-label, multicentre, non-randomised	Single-masked, multicentre, randomised
Study duration	24 months	12 months	12 months
Lesion type (percentage of patients with PC/MC/ONC if data available)	All CNV types* (17.5/57.5/25)	All CNV types†	All CNV types
Visit regimen in maintenance phase	Monthly	Monthly	Quarterly
Ranibizumab regimen in maintenance phase	Individualised	Individualised	Individualised
Mean (range) no ranibizumab injections in maintenance phase	2.6 (0–10)	2.3 (0–7)	1.6 (range NA)
Key baseline and efficacy results	**Ranibizumab 0.5 mg (n = 40)**	**Ranibizumab 0.3 mg (n = 69; interim data)**	**Ranibizumab 0.5 mg‡ (n = 1209; 490 treatment-naïve; 719 previously treated)**
Mean (SD) size of CNV at baseline	NA	NA	NA
Mean (SD) VA at baseline (letters)	56.2	54.7 (11.0)	NA
Stabilisation of VA at 12 months§ (percentage of patients)	95.0	NA	NA
Improvement in VA at 12 months¶ (percentage of patients)	35.0	NA	19.3 (treatment-naïve) 16.5 (previously treated)
Mean VA change from baseline (letters)			
After three initial doses	+10.8	+9.2	+7.0 (treatment-naïve) +6.0 (previously treated)
At 12 months	+9.3	+6.7	+2.3 (both groups)
At 24 months	+10.7	NAP	NAP

SUSTAIN data are for the intent-to-treat population; the last observation carried forward method was used to calculate missing data.
*Additional PrONTO inclusion criteria: BCVA between 20/40 and 20/400 (Snellen equivalent, assessed using Early Treatment Diabetic Retinopathy Study charts); optical coherence tomography central retinal thickness ⩾300 μm; evidence of progression.
†Additional SUSTAIN inclusion criteria: CNV comprised ⩾50% of the lesion; BCVA between 20/40 and 20/320.
‡Ranibizumab 0.3 mg was also investigated; results are only shown for the licensed 0.5 mg dose.
§A loss of <15 letters was defined to be stabilisation of VA.
¶Improvement in VA was defined as an increase of ⩾15 letters.
BCVA, best-corrected visual acuity; CNV, choroidal neovascularisation; MC, minimally classic; NA, not available; NAP, not applicable; ONC, occult (with no classic); PC, predominantly classic; SD, standard deviation; VA, visual acuity.

profile should be discussed with individual patients, particularly those with a history of, or risk factors for, stroke.

DISCUSSION

Detailed and focused analysis of Phase III clinical trial evidence has generated evidence-based guidelines for using ranibizumab to manage neovascular AMD (summarised in table 5). These guidelines aim to assist ophthalmologists in clinical practice, improve the quality of medical care and optimise the treatment outcomes and quality of life for patients, and are based on the highest level of evidence available.

Clinical evidence indicates that ranibizumab initiation with three consecutive monthly injections is optimal, providing the greatest VA gain, although three versus fewer injections has not been prospectively evaluated. After the initiation phase, the strongest evidence is for continued monthly treatment. As this is frequently not feasible, a flexible individualised approach may achieve similar outcomes to monthly therapy. This, however, is yet to be verified. The flexible approach requires approximate monthly monitoring to capture signs of active disease and reinitiate treatment without delay. Where possible, monthly evaluation should include OCT, as this may be the most sensitive means of detecting VEGF-induced permeability changes.

OCT is strongly recommended for the management of neovascular AMD[20 21] and has been found to be generally reproducible, although recent studies have identified some measurement variability.[69 70] The new generation of spectral domain and other high-resolution OCTs may provide more accurate assessments, but these instruments have not yet been validated in the context of anti-VEGF therapy in neovascular AMD.[71–73] Both quantitative OCT (measurements of increased centre-point thickness using "fast" scanning protocols) and qualitative OCT (anatomical evidence of CNV leakage using "regular" scanning protocols) should be used to define VEGF-induced permeability changes in neovascular AMD. Qualitative OCT signs may be the most useful, as these can help to define specific structural changes resulting from CNV leakage (diffuse retinal oedema, intraretinal cysts, subretinal fluid and subretinal pigment epithelial fluid).[21] Both types of scan appear to be interchangeable for the comparison of absolute thickness values.[74]

An ophthalmologist's full understanding of the particular circumstances and therapeutic needs of their individual patients remains fundamental to providing care. Some of the monitoring techniques discussed within these guidelines are still under evaluation (eg, OCT). Clinician judgement will, therefore, remain important until their use is more clearly understood. Further work aims to identify potential prognostic markers for response to ranibizumab, including the presence of risk genotypes (eg, complement factor H, *LOC387715*),[63] inflammatory factors (eg, C-reactive protein), or other AMD risk factors (eg, smoking). Only interim SUSTAIN results are currently available, so the final data including all recruited patients are awaited with interest.

Overall, ranibizumab has been well tolerated in clinical trials, with a low incidence of ocular and systemic serious adverse events. Postmarketing studies will evaluate its longer-term safety profile in the spectrum of patients treated in clinical practice. Reassessment of the SAILOR trial findings which suggest a possibly greater risk of subsequent stroke among treated cases with a history of stroke or its risk factors (eg, cardiac arrhythmias) is needed using other studies and cohorts.

Table 4 Summary of key ocular and non-ocular adverse events (AEs) in ranibizumab clinical trials

	MARINA (24-month data)			ANCHOR (12-month data)			PIER (12-month data)			EXCITE (12-month data)			SUSTAIN (12-month data)
	Ranibizumab 0.3 mg (n = 238)	Ranibizumab 0.5 mg (n = 240)	Sham control (n = 238)	Ranibizumab 0.3 mg (n = 137)	Ranibizumab 0.5 mg (n = 140)	Verteporfin control (n = 143)	Ranibizumab 0.3 mg (n = 59)	Ranibizumab 0.5 mg (n = 61)	Sham control (n = 63)	Ranibizumab 0.3 mg control (n = 101)	Ranibizumab 0.3 mg (n = 104)	Ranibizumab 0.5 mg (n = 88)	Ranibizumab 0.3 mg (n = 69; interim data)
Key serious ocular AEs													
Presumed endophthalmitis	2 (0.8)	3 (1.3)	0	0	2 (1.4)	0	0	0	0	0	0	0	0
Culture positive	0	0	0	0	1 (0.7)	0	0	0	0	0	0	0	0
Culture negative	1 (0.4)	3 (1.3)	0	0	0	0	0	0	0	0	0	0	0
Culture not done	1 (0.4)	0	0	0	1 (0.7)	0	0	0	0	0	0	0	0
Uveitis	3 (1.3)	3 (1.3)	0	0	1 (0.7)	0	0	0	0	0	0	0	0
Retinal detachments	0	0	1 (0.4)	1 (0.7)	0	1 (0.7)	0	0	0	0	1 (0.8)	0	0
Retinal tear	1 (0.4)	1 (0.4)	0	0	0	0	0	0	0	0	0	2 (1.7)	0
Retinal haemorrhage	NA	NA	NA	NA	NA	NA	1 (1.7)	0	2 (3.2)	0	0	1 (0.8)	1 (1.4)
Detachment of RPE	NA	NA	NA	NA	NA	NA	NA	NA	NA	0	0	0	1 (1.4)
Vitreous haemorrhage	1 (0.4)	1 (0.4)	2 (0.8)	1 (0.7)	0	0	0	0	0	0	0	0	0
Key non-ocular AEs													
Hypertension	41 (17.2)	39 (16.3)	38 (16.1)	3 (2.2)	9 (6.4)	12 (8.4)	4 (6.8)	6 (9.8)	5 (8.1)	8 (7.0)	10 (8.3)	6 (5.1)	3 (4.3)
Key ATEs (non-fatal)													
Myocardial infarction	6 (2.5)*	3 (1.3)†	4 (1.7)	1 (0.7)	3 (2.1)	1 (0.7)	0	0	0	1 (0.9)	1 (0.8)	0	0
Stroke	3 (1.3)‡	6 (2.5)†§	2 (0.8)¶,**	0	1 (0.7)	1 (0.7)	0	0	0	1 (0.9)	0	0	0
Cerebral infarction	NA	NA	NA	1 (0.7)	0	0	NA	NA	NA	0	0	1 (0.8)	0
Death													
Vascular cause	3 (1.3)‡,††	3 (1.3)‡‡	4 (1.7)§§	1 (0.7)¶¶	2 (1.4)***	1 (0.7)¶¶	0	0	0	1 (0.9)†††	0	1 (0.8)‡‡‡	0
Non-vascular cause	2 (0.8)	3 (1.3)	2 (0.8)	2 (1.5)	0	1 (0.7)	0	0	0	0	0	1 (0.8)	(1.4)
Non-ocular haemorrhage	22 (9.2)	21 (8.8)	13 (5.5)	7 (5.1)	9 (6.4)	3 (2.1)	2 (3.4)	4 (6.6)	3 (4.8)	NA	NA	NA	NA

*One patient had two episodes.
†One patient had a myocardial infarction and a haemorrhagic stroke, both non-fatal.
‡One patient had a non-fatal ischaemic stroke and died of an unknown cause.
§One patient had a cerebral ischaemic incident that was categorised as an ischaemic stroke.
¶One patient in the sham group received a single ranibizumab 0.5 mg dose in error approximately 8 months before the onset of stroke.
**One patient had a second episode of stroke, which resulted in death.
††Two patients died from myocardial infarction and one from an unknown cause.
‡‡One patient died from a small-bowel infarct and two from stroke.
§§Two patients died from stroke, one from congestive heart failure and one from an unknown cause.
¶¶One patient died from cardiac arrest.
***One patient died from cardiac failure and one from worsening of chronic heart failure.
†††One patient died from cerebral haemorrhage.
‡‡‡One patient died from cardiorespiratory arrest.
ATE, arterial thromboembolic event; NA, not available; RPE, retinal pigment epithelial.

Table 5 Summary of clinical recommendations for ranibizumab treatment of neovascular AMD

How should neovascular AMD be diagnosed?
History (duration and characteristic visual symptoms—distortion, dark patch)
VA (logMAR preferable to Snellen)
Stereoscopic biomicroscopic slit-lamp fundus examination (78 D or similar lens)
FA
OCT where possible
Which neovascular AMD lesions should be considered for ranibizumab treatment?
Predominantly classic, minimally classic and occult (with no classic) CNV
Subfoveal (including juxtafoveal) lesions
Active disease (see table 1)
Any baseline VA
Serous PED, RAP or PCV can be considered but might not respond as well as expected from average trial outcomes
What characteristics suggest that ranibizumab would likely be futile?
Structural foveal damage: advanced subretinal fibrosis or significant geographic atrophy involving the foveal centre
Confounding severe ocular disease: vitreous or preretinal haemorrhage obscuring the central macula, or presence of rhegmatogenous retinal detachment
What are appropriate intervals for the initiation of ranibizumab treatment?
Initiate 0.5 mg of ranibizumab with ⩾3 consecutive monthly intravitreal injections
Commence treatment as soon as possible after diagnosis; as a guide, ⩽14 or ⩽28 days
Follow-up examination recommended before readministering ranibizumab at months 1 and 2: history, VA assessment, slit-lamp fundus examination and OCT; repeat FA generally only recommended for patients with significant or unexplained vision loss
What are appropriate intervals during the maintenance phase of ranibizumab treatment?
Level I evidence: monthly ranibizumab intravitreal injection demonstrated the best VA outcomes in the clinical trials
Level III evidence: when a monthly regimen is not possible, a flexible strategy with monthly monitoring is feasible; benefits could be lower than with monthly treatment
Monthly follow-up (particularly during the first 12 months) aims to detect active disease from: history, VA assessments, slit-lamp examinations and OCT; FA is mostly not needed at this stage
If active disease is present or recurs, additional treatment should be initiated quickly to improve functional outcomes
If the disease is inactive, retreatment can be deferred
In both cases, patients should be reviewed at each following month using the same assessments, with treatment readministered only if active disease is present
If the clinical signs remain quiescent for longer than the first 12 months, extending the follow-up intervals may then be justified

AMD, age-related macular degeneration; CNV, choroidal neovascularisation; FA, fluorescein angiography; OCT, optical coherence tomography; PCV, polypoidal choroidal vasculopathy; PED, pigment epithelial detachment; RAP, retinal angiomatous proliferation; VA, visual acuity.

There are still many unanswered questions to be resolved by future research. For example, are these guidelines applicable to CNV from myopia and PCV; is ICG needed for Asian patients; and what is the role of combination treatment? How many patients need treatment into the second then the third year after initiation? Do any situations alter the pharmacogenetics of ranibizunab (eg, vitrectomy surgery, glaucoma medications)?

Different studies are under way in these areas, such as the ranibizumab Phase IV EVEREST PCV trial (clinical trials' identifier NCT00674323) and the Phase II MONT BLANC (NCT00433017) and Phase IIIb DENALI (NCT00436553) trials investigating ranibizumab in combination with verteporfin PDT. The HORIZON Extension Study (NCT00379795) has examined the need for treatment into the third year. Insights from the National Eye Institute-sponsored large randomised controlled trial comparing ranibizumab and bevacizumab (Comparison of AMD Treatment Trials (CATT); clinical trials' identifier NCT00593450) and other similar trials will also contribute substantially to improved understanding of the clinical use of these agents.

Additional evidence should also be collected on patient preferences relating to AMD treatment, as these are important to incorporate within treatment guidelines. To date, patient views have been studied relating to the deleterious impact AMD has on patients' quality of life, which is often markedly underestimated by ophthalmologists.[75] An improved public awareness of the debilitating natural history of AMD and of the benefits from preventive therapies for early stage disease is needed.

These evidence-based guidelines may evolve with better understanding of ranibizumab clinical use from new trial data and increasing clinical practice experience, and should be updated each year. The impact of these guidelines on quality of care and patient well-being should be monitored in clinical practice. Primary efficacy outcomes from the clinical studies, such as the proportion of patients losing ⩽15 letters, gaining ⩾15 letters or maintaining ⩾20/40 vision, could also be used in clinical practice as key audit indicators. Another key outcome for patients is the maintenance of functional vision to enable continued independence, which could, for example, be monitored based on being able to see well enough to read, to drive or to go out shopping.

Acknowledgements: The authors acknowledge medical writing assistance from E Boning from Complete Medical Communications.

Funding: Medical writing assistance was provided under the direction of the authors and was funded unconditionally by Novartis Pharma AG, Basel, Switzerland.

Competing interests: PM has received a consultancy fee from Novartis Pharma AG, Pfizer, Solvay and Allergan. He has also been paid lecture fees/honoraria by Novartis Pharma AG, Pfizer, Solvay and Allergan. J-FK has received a consultancy fee from Novartis Pharma AG, Bayer Schering, Alcon, Pfizer and Thea. PL has received a consultancy fee from NeoVista, Allergan, Novartis Pharma AG and QLT. He has also been paid lecture fees/honoraria by Allergan, Novartis Pharma AG, QLT and Optimedica. He has patents with and/or royalties from Iridex Co. FGH has received a consultancy fee from Alcon, Acucela, Bayer Schering and Novartis Pharma AG. He has also been paid lecture fees/honoraria by Alcon and Novartis Pharma AG. CP has received a consultancy fee and lecture fee/honoraria from Novartis Pharma AG. US-E has received a consultancy fee from Novartis Pharma AG, Alcon and Bayer Healthcare. She has also been paid lecture fees/honoraria by Novartis Pharma AG, Alcon, Bayer

Healthcare and Carl Zeiss Meditec. YT has received a consultancy fee from Novartis Pharma AG, Alcon Japan, Bausch & Lomb Japan, Pfizer Japan and Santen. He has also been paid lecture fees/honoraria by Novartis Pharma AG, Alcon Japan, Pfizer Japan and Santen. SW has received a consultancy fee from Novartis Pharma AG. He has also been paid lecture fees/honoraria by Novartis Pharma AG, Pfizer and Allergan.

Provenance and peer review: Not commissioned; externally peer reviewed.

REFERENCES

1. **Bressler NM.** Age-related macular degeneration is the leading cause of blindness. *JAMA* 2004;**291**:1900–1.
2. **Friedman DS,** O'Colmain BJ, Munoz B, *et al*. Prevalence of age-related macular degeneration in the United States. *Arch Ophthalmol* 2004;**122**:564–72.
3. **Resnikoff S,** Pascolini D, Etya'ale D, *et al*. Global data on visual impairment in the year 2002. *Bull World Health Organ* 2004;**82**:844–51.
4. **Wong T,** Chakravarthy U, Klein R, *et al*. The natural history and prognosis of neovascular age-related macular degeneration: a systematic review of the literature and meta-analysis. *Ophthalmology* 2008;**115**:116–26.
5. **Brown MM,** Brown GC, Stein JD, *et al*. Age-related macular degeneration: economic burden and value-based medicine analysis. *Can J Ophthalmol* 2005;**40**:277–87.
6. **Ferrara N,** Damico L, Shams N, *et al*. Development of ranibizumab, an anti-vascular endothelial growth factor antigen binding fragment, as therapy for neovascular age-related macular degeneration. *Retina* 2006;**26**:859–70.
7. **Lowe J,** Araujo J, Yang J, *et al*. Ranibizumab inhibits multiple forms of biologically active vascular endothelial growth factor in vitro and in vivo. *Exp Eye Res* 2007;**85**:425–30.
8. **Grisanti S,** Tatar O. The role of vascular endothelial growth factor and other endogenous interplayers in age-related macular degeneration. *Prog Retin Eye Res* 2008;**27**:372–90.
9. **Penn JS,** Madan A, Caldwell RB, *et al*. Vascular endothelial growth factor in eye disease. *Prog Retin Eye Res* 2008;**27**:331–71.
10. **Oester A,** Baffi J, Ambati BK. Pharmacotherapy targeting ocular neovascularization. *Focal Points* 2008;**XXVI**:1–10.
11. **Gragoudas ES,** Adamis AP, Cunningham ET Jr, *et al*. Pegaptanib for neovascular age-related macular degeneration. *New Engl J Med* 2004;**351**:2805–16.
12. **Brown DM,** Kaiser PK, Michels M, *et al*. Ranibizumab versus verteporfin for neovascular age-related macular degeneration. *New Engl J Med* 2006;**355**:1432–44.
13. **Rosenfeld PJ,** Brown DM, Heier JS, *et al*. Ranibizumab for neovascular age-related macular degeneration. *New Engl J Med* 2006;**355**:1419–31.
14. **Blick SK,** Keating GM, Wagstaff AJ. Ranibizumab. *Drugs* 2007;**67**:1199–206.
15. **Rosenfeld PJ,** Moshfeghi AA, Puliafito CA. Optical coherence tomography findings after an intravitreal injection of bevacizumab (avastin) for neovascular age-related macular degeneration. *Ophthalmic Surg Lasers Imaging* 2005;**36**:331–5.
16. **Ip MS,** Scott IU, Brown GC, *et al*. Anti-vascular endothelial growth factor pharmacotherapy for age-related macular degeneration: a report by the American Academy of Ophthalmology. *Ophthalmology* 2008;**115**:1837–46.
17. **Amoaku W.** Ranibizumab: The clinician's guide to commencing, continuing, and discontinuing treatment. *Eye*. In press.
18. **Amoaku WM.** The Royal College of Ophthalmologists interim recommendations for the management of patients with age-related macular degeneration. *Eye* 2008;**22**:864–8.
19. **Chakravarthy U,** Soubrane G, Bandello F, *et al*. Evolving European guidance on the medical management of neovascular age related macular degeneration. *Br J Ophthalmol* 2006;**90**:1188–96.
20. **Schmidt-Erfurth UM,** Richard G, Augustin A, *et al*. Guidance for the treatment of neovascular age-related macular degeneration. *Acta Ophthalmol Scand* 2007;**85**:486–94.
21. **Brown DM,** Regillo CD. Anti-VEGF agents in the treatment of neovascular age-related macular degeneration: applying clinical trial results to the treatment of everyday patients. *Am J Ophthalmol* 2007;**144**:627–37.
22. **Dadgostar H,** Waheed N. The evolving role of vascular endothelial growth factor inhibitors in the treatment of neovascular age-related macular degeneration. *Eye* 2008;**22**:761–7.
23. **Regillo CD,** Brown DM, Abraham P, *et al*. Randomized, double-masked, sham-controlled trial of ranibizumab for neovascular age-related macular degeneration: PIER Study year 1. *Am J Ophthalmol* 2008;**145**:239–48.
24. **Brown DM,** Michels M, Kaiser PK, *et al*. Ranibizumab versus verteporfin photodynamic therapy for neovascular age-related macular degeneration: Two-year results of the ANCHOR study. *Ophthalmology* 2009;**116**:57–65.
25. **Chang TS,** Bressler NM, Fine JT, *et al*. Improved vision-related function after ranibizumab treatment of neovascular age-related macular degeneration: results of a randomized clinical trial. *Arch Ophthalmol* 2007;**125**:1460–9.
26. **Boyer DS,** Antoszyk AN, Awh CC, *et al*. Subgroup analysis of the MARINA study of ranibizumab in neovascular age-related macular degeneration. *Ophthalmology* 2007;**114**:246–52.
27. **Bressler NM,** Chang TS, Fine JT, *et al*. Improved vision-related function after ranibizumab vs photodynamic therapy: a randomized clinical trial. *Arch Ophthalmol* 2009;**127**:13–21.
28. **Kaiser PK,** Brown DM, Zhang K, *et al*. Ranibizumab for predominantly classic neovascular age-related macular degeneration: subgroup analysis of first-year ANCHOR results. *Am J Ophthalmol* 2007;**144**:850–7.
29. **Eyeworld.org.** Lucentis at one year. http://www.eyeworld.org/printarticle.php?id=4390 (accessed 21 Nov 2008).
30. **Meyer CH,** Eter N, Holz FG, *et al*. Ranibizumab in patients with subfoveal choroidal neovascularization secondary to age-related macular degeneration. Interim results from the SUSTAIN trial [abstract]. *Invest Ophthalmol Vis Sci* 2008;**49**:E-abstract 273.
31. **Bolz M,** Schmidt-Erfurth U. Ranibizumab EXCITE study: Exploring the value of optical coherence tomography for the management of ranibizumab therapy in age-related macular degeneration. 2008. *8th EURETINA Congress*, 22–25 May 2008, Vienna.
32. **Fung AE,** Lalwani GA, Rosenfeld PJ, *et al*. An optical coherence tomography-guided, variable dosing regimen with intravitreal ranibizumab (Lucentis) for neovascular age-related macular degeneration. *Am J Ophthalmol* 2007;**143**:566–83.
33. **Ferris FL III,** Kassoff A, Bresnick GH, *et al*. New visual acuity charts for clinical research. *Am J Ophthalmol* 1982;**94**:91–6.
34. **Rosser DA,** Laidlaw DA, Murdoch IE. The development of a "reduced logMAR" visual acuity chart for use in routine clinical practice. *Br J Ophthalmol* 2001;**85**:432–6.
35. **Falkenstein IA,** Cochran DE, Azen SP, *et al*. Comparison of visual acuity in macular degeneration patients measured with Snellen and early treatment diabetic retinopathy study charts. *Ophthalmology* 2008;**115**:319–23.
36. **Barbazetto I,** Burdan A, Bressler NM, *et al*. Photodynamic therapy of subfoveal choroidal neovascularization with verteporfin: fluorescein angiographic guidelines for evaluation and treatment—TAP and VIP report No. 2. *Arch Ophthalmol* 2003;**121**:1253–68.
37. **Ahlers C,** Golbaz I, Stock G, *et al*. Time course of morphologic effects on different retinal compartments after ranibizumab therapy in age-related macular degeneration. *Ophthalmology* 2008;**115**:e39–46.
38. **Liakopoulos S,** Ongchin S, Bansal A, *et al*. Quantitative optical coherence tomography findings in various subtypes of neovascular age-related macular degeneration. *Invest Ophthalmol Vis Sci* 2008;**49**:5048–54.
39. **Yannuzzi LA,** Sorenson J, Spaide RF, *et al*. Idiopathic polypoidal choroidal vasculopathy (IPCV). *Retina* 1990;**10**:1–8.
40. **Spaide RF,** Yannuzzi LA, Slakter JS, *et al*. Indocyanine green videoangiography of idiopathic polypoidal choroidal vasculopathy. *Retina* 1995;**15**:100–10.
41. **Yannuzzi LA,** Negrao S, Iida T, *et al*. Retinal angiomatous proliferation in age-related macular degeneration. *Retina* 2001;**21**:416–34.
42. **Gross NE,** Aizman A, Brucker A, *et al*. Nature and risk of neovascularization in the fellow eye of patients with unilateral retinal angiomatous proliferation. *Retina* 2005;**25**:713–18.
43. **Freund KB,** Ho IV, Barbazetto IA, *et al*. Type 3 neovascularization: the expanded spectrum of retinal angiomatous proliferation. *Retina* 2008;**28**:201–11.
44. **Position of the Retinological Society,** the German Ophthalmological Society and the Professional Association of Ophthalmologists in Germany on the current therapeutic possibilities for neovascular age-related macular degeneration. *Klin Monatsbl Augenheilkd* 2007;**224**:559–66.
45. **Verteporfin Roundtable 2000 and 2001 Participants,** Treatment of age-related macular degeneration with photodynamic therapy (TAP) study group principal investigators, Verteporfin in photodynamic therapy (VIP) study group principal investigators. Guidelines for using verteporfin (visudyne) in photodynamic therapy to treat choroidal neovascularization due to age-related macular degeneration and other causes. *Retina* 2002;**22**:6–18.
46. **Verteporfin Roundtable Participants**. Guidelines for using verteporfin (Visudyne) in photodynamic therapy for choroidal neovascularization due to age-related macular degeneration and other causes: update. *Retina* 2005;**25**:119–34.
47. **Deissler H,** Deissler H, Lang S, *et al*. VEGF-induced effects on proliferation, migration and tight junctions are restored by ranibizumab (Lucentis) in microvascular retinal endothelial cells. *Br J Ophthalmol* 2008;**92**:839–43.
48. **Kourlas H,** Abrams P. Ranibizumab for the treatment of neovascular age-related macular degeneration: a review. *Clin Ther* 2007;**29**:1850–61.
49. **Elman MJ,** Fine SL, Murphy RP, *et al*. The natural history of serous retinal pigment epithelium detachment in patients with age-related macular degeneration. *Ophthalmology* 1986;**93**:224–30.
50. **Dadgostar H,** Ventura AA, Sharma S, *et al*. OCT lesion morphology and the response of exudative AMD to Ranibizumab. Abstract PO552. *AAO/SOE Joint Annual Meeting*, 8–11 November 2008, Atlanta. http://www.aao.org/aao/customcf/onlineprogram2008/tnt_getevtlongaao02.cfm?subsystem=MTG&primary_id=AM08&secondary_id=PO552 (accessed 22 May 2009).
51. **Carvounis PE,** Kopel AC, Benz MS. Retinal pigment epithelium tears following ranibizumab for exudative age-related macular degeneration. *Am J Ophthalmol* 2007;**143**:504–5.
52. **Bakri SJ,** Kitzmann AS. Retinal pigment epithelial tear after intravitreal ranibizumab. *Am J Ophthalmol* 2007;**143**:505–7.
53. **Chan CK,** Lin SG. Retinal pigment epithelial tear after ranibizumab therapy for subfoveal fibrovascular pigment epithelial detachment. *Eur J Ophthalmol* 2007;**17**:674–6.
54. **Chang LK,** Sarraf D. Tears of the retinal pigment epithelium: an old problem in a new era. *Retina* 2007;**27**:523–34.
55. **Schmidt-Erfurth U,** Wolf S, Study Group. Same-day administration of verteporfin and ranibizumab 0.5 mg in patients with choroidal neovascularization due to age-related macular degeneration. *Br J Ophthalmol* 2008;**92**:1628–35.
56. **Klein ML,** Jorizzo PA, Watzke RC. Growth features of choroidal neovascular membranes in age-related macular degeneration. *Ophthalmology* 1989;**96**:1416–19.
57. **Arias L,** Armada F, Donate J, *et al*. Delay in treating age-related macular degeneration in Spain is associated with progressive vision loss. *Eye* 2009;**23**:326–33.
58. **US Food and Drug Administration**. Labeling Instructions for Ranibizumab, (BLA) 125156. 2006. http://www.fda.gov/cder/foi/label/2006/125156lbl.pdf (accessed 21 Nov 2008).

59. **Regillo CD,** Yue H, Shams N. Ranibizumab (Lucentis) in treatment of neovascular age-related macular degeneration (AMD): 2-year results of PIER study. Poster PO459. AAO 2007.
60. **Kaiser PK,** Blodi BA, Shapiro H, *et al*. Angiographic and optical coherence tomographic results of the MARINA study of ranibizumab in neovascular age-related macular degeneration. *Ophthalmology* 2007;**114**:1868–75.
61. **Kaiser PK,** Chung CY, Tuomi L. Overview of Ranibizumab efficacy for wet AMD: ANCHOR, MARINA, PIER, and SAILOR studies. Abstract PO255 presented at the AAO/SOE Joint Annual Meeting, 8–11 November 2008, Atlanta. http://www.aao.org/aao/customcf/onlineprogram2008/tnt_getevtlongaao02.cfm?subsystem=MTG&primary_id=AM08&secondary_id=PO255.
62. **Holz FG.** SOE: flexibly dosed ranibizumab in patients with neovascular AMD: twelve-month interim results of the SUSTAIN Trial. Abstract PA078 presented at the AAO/SOE Joint Annual Meeting, 8–11 November 2008, Atlanta. http://www.aao.org/aao/customcf/onlineprogram2008/tnt_getevtlongaao02.cfm?subsystem=MTG&primary_id=AM08&secondary_id=PA078.
63. **Brown DM,** Wang P-W, Scott LC. HORIZON extension trial of Ranibizumab for wet AMD: subanalysis of year 1 results. Abstract PO248 presented at the AAO/SOE Joint Annual Meeting, 8–11 November 2008, Atlanta. http://www.aao.org/aao/customcf/onlineprogram2008/tnt_getevtlongaao02.cfm?subsystem=MTG&primary_id=AM08&secondary_id=PO248.
64. **Boyer DS,** Chung CY, Tuomi L. A Safety Overview of Ranibizumab in Patients With Wet AMD: ANCHOR, MARINA, PIER, and SAILOR Studies. Abstract PO247 presented at the AAO/SOE Joint Annual Meeting, 8–11 November 2008, Atlanta. http://www.aao.org/aao/customcf/onlineprogram2008/tnt_getevtlongaao02.cfm?subsystem=MTG&primary_id=AM08&secondary_id=PO247.
65. **Antiplatelet Trialists' Collaboration**. Collaborative overview of randomised trials of antiplatelet therapy—I: Prevention of death, myocardial infarction, and stroke by prolonged antiplatelet therapy in various categories of patients. *BMJ* 1994;**308**:81–106.
66. **Alexander SL,** Linde-Zwirble WT, Werther W, *et al*. Annual rates of arterial thromboembolic events in medicare neovascular age-related macular degeneration patients. *Ophthalmology* 2007;**114**:2174–8.
67. **Wong TY,** Klein R, Sun C, *et al*. Age-related macular degeneration and risk for stroke. *Ann Intern Med* 2006;**145**:98–106.
68. **Tan JS,** Wang JJ, Liew G, *et al*. Age-related macular degeneration and mortality from cardiovascular disease or stroke. *Br J Ophthalmol* 2008;**92**:509–12.
69. **Joeres S,** Tsong JW, Updike PG, *et al*. Reproducibility of quantitative optical coherence tomography subanalysis in neovascular age-related macular degeneration. *Invest Ophthalmol Vis Sci* 2007;**48**:4300–7.
70. **Patel PJ,** Chen FK, Ikeji F, *et al*. Repeatability of stratus optical coherence tomography measures in neovascular age-related macular degeneration. *Invest Ophthalmol Vis Sci* 2008;**49**:1084–8.
71. **Fleckenstein M,** Charbel IP, Helb HM, *et al*. High-resolution spectral domain-OCT imaging in geographic atrophy associated with age-related macular degeneration. *Invest Ophthalmol Vis Sci* 2008;**49**:4137–44.
72. **de Bruin DM,** Burnes DL, Loewenstein J, *et al*. In vivo three-dimensional imaging of neovascular age-related macular degeneration using optical frequency domain imaging at 1050 nm. *Invest Ophthalmol Vis Sci* 2008;**49**:4545–52.
73. **Wolf-Schnurrbusch UE,** Ceklic L, Brinkmann CK, *et al*. Macular thickness measurements in healthy eyes using six different optical coherence tomography instruments. *Invest Ophthalmol Vis Sci*. In press.
74. **Ceklic L,** Maar N, Neubauer AS. Optical coherence tomography fast versus regular macular thickness mapping in diabetic retinopathy. *Ophthalmic Res* 2008;**40**:235–40.
75. **Davanger M,** Ringvold A, Blika S, *et al*. Frequency distribution of IOP. Analysis of a material using the gamma distribution. *Acta Ophthalmol (Copenh)* 1991;**69**:561–4.