theclinics.com

EMERGENCY MEDICINE CLINICS OF NORTH AMERICA

Ophthalmologic Emergencies

GUEST EDITORS
Joseph H. Kahn, MD and
Brendan Magauran, MD

CONSULTING EDITOR
Amal Mattu, MD

February 2008 • Volume 26 • Number 1

SAUNDERS
An Imprint of Elsevier, Inc.
PHILADELPHIA LONDON TORONTO MONTREAL SYDNEY TOKYO

Celltrion Exhibit - 1059
Celltrion, Inc. v. Regeneron Pharmaceuticals, Inc.

W.B. SAUNDERS COMPANY
A Division of Elsevier Inc.

1600 John F. Kennedy Boulevard, Suite 1800 • Philadelphia, Pennsylvania 19103-2899

http://www.theclinics.com

EMERGENCY MEDICINE CLINICS OF NORTH AMERICA
February 2008
Editor: Patrick Manley

Volume 26, Number 1
ISSN 0733-8627
ISBN-13: 978-1-4160-5852-6
ISBN-10: 1-4160-5852-4

Copyright © 2008 by Elsevier Inc. All rights reserved. No part of this publication may be reproduced or transmitted in any form or by any means, electronic or mechanical, including photocopy, recording, or any information retrieval system, without written permission from the Publisher.

Single photocopies of single articles may be made for personal use as allowed by national copyright laws. Permission of the publisher and payment of a fee is required for all other photocopying, including multiple or systematic copying, copying for advertising or promotional purposes, resale, and all forms of document delivery. Special rates are available for educational institutions that wish to make photocopies for non-profit educational classroom use. Permission may be sought directly from Elsevier's Global Rights Department in Oxford, UK; phone: 215-239-3804, or +44 (0) 1865 843830, fax +44 (0)1865 853333, e-mail: healthpermissions@elsevier.com. Requests may also be completed online via the Elsevier homepage (http://www.elsevier.com/permissions). In the USA, users may clear permissions and make payments through the Copyright Clearance Center, Inc., 222 Rosewood Drive, Danvers, MA 01923, USA; phone: (978) 750-8400, fax: (978) 750-4744, and in the UK through the Copyright Licensing Agency Rapid Clearance Service (CLARCS), 90 Tottenham Court Road, London WIP 0LP, UK; phone: (+44) 171 436 5931; fax: (+44) 171 436 3986. Other countries may have a local reprographic rights agency for payments.

Reprints. For copies of 100 or more, of articles in this publication, please contact the Commercial Reprints Department, Elsevier Inc., 360 Park Avenue South, New York, New York 10010-1710. Tel. (212) 633-3813; Fax: (212) 462-1935; e-mail: reprints@elsevier.com.

The ideas and opinions expressed in *Emergency Medicine Clinics of North America* do not necessarily reflect those of the Publisher. The Publisher does not assume any responsibility for any injury and/or damage to persons or property arising out of or related to any use of the material contained in this periodical. The reader is advised to check the appropriate medical literature and the product information currently provided by the manufacturer of each drug to be administered to verify the dosage, the method and duration of administration, or contraindications. It is the responsibility of the treating physician or other health care professional, relying on independent experience and knowledge of the patient, to determine drug dosages and the best treatment for the patient. Mention of any product in this issue should not be construed as endorsement by the contributors, editors, or the Publisher of the product or manufacturers' claims.

Emergency Medicine Clinics of North America (ISSN 0733-8627) is published quarterly by Elsevier Inc., 360 Park Avenue South, New York, NY, 10010-1710. Months of issue are February, May, August, and November. Business and Editorial Offices: 1600 John F. Kennedy Boulevard, Suite 1800, Philadelphia, PA 19103-2899. Customer Service Office: 6277 Sea Harbor Drive, Orlando, FL 32887-4800. Periodicals postage paid at New York, NY, and additional mailing offices. Subscription prices are $109.00 per year (US students), $212.00 per year (US individuals), $339.00 per year (US institutions), $145.00 per year (international students), $285.00 per year (international individuals), $400.00 per year (international institutions), $145.00 per year (Canadian students), $261.00 per year (Canadian individuals), and $400.00 per year (Canadian institutions). International air speed delivery is included in all *Clinics'* subscription prices. All prices are subject to change without notice. POSTMASTER: Send address changes to *Emergency Medicine Clinics of North America*, Elsevier Periodicals Customer Service, 6277 Sea Harbor Drive, Orlando, FL 32887-4800. Customer Service: 1-800-654-2452 (US). From outside the United States, call 1-407-563-6020. Fax: 1-407-363-9661. E-mail: JournalsCustomerService-usa@elsevier.com.

Emergency Medicine Clinics of North America is covered in *Index Medicus, Current Contents/Clinical Medicine, EMBASE/Excerpta Medica, BIOSIS, SciSearch, CINAHL, ISI/BIOMED,* and *Research Alert.*

Printed in the United States of America.

ELSEVIER
SAUNDERS

Emerg Med Clin N Am
26 (2008) 57–72

EMERGENCY
MEDICINE
CLINICS OF
NORTH AMERICA

Ocular Infection and Inflammation

Jorma B. Mueller, MD[a],
Christopher M. McStay, MD[b,*]

[a]*Emergency Medicine Residency, New York University/Bellevue Hospital Center, 462 First Avenue, New York, NY 10016, USA*
[b]*Department of Emergency Medicine, New York University/Bellevue Hospital Center, 462 First Avenue, New York, NY 10016, USA*

Managing the inflamed or infected eye in the emergency setting presents a diagnostic and therapeutic challenge to the emergency physician; the causes and prognoses range from benign, self-limited illness to organ-threatening pathology. A careful history, with attention to comorbid illnesses and time course, is paramount, as is knowledge of the complete ophthalmologic examination. Much of the organ morbidity is ameliorated with prompt therapy in the emergency department (ED) and by initiating ophthalmologic consultation.

Conjunctivitis

Inflammation of the bulbar (covering the globe of the eye) and tarsal (lining the orbit) conjunctiva can be caused by viral or bacterial infections, trauma, toxic exposure, or autoimmune disease. Patients will complain of redness, pruritis, and a foreign body sensation that is often associated with discharge. Awakening in the morning with eye crusting is a common complaint. Photophobia and visual loss should not be present. Physical examination will reveal injection of the conjunctiva associated with lid edema. Discharge may be scant or may range from stringy and fibrinous to copious and purulent. If bacterial conjunctivitis is expected, gram stain and culture of the discharge is often revealing and can guide initiation of therapy. Most conjunctivitis seen in the ED is of viral origin and is self limited. However, the emergency practitioner should be familiar with all causes because the clinical course of conjunctivitis can lead to significant morbidity, depending on the cause.

* Corresponding author.
E-mail address: chris.mcstay@med.nyu.edu (C.M. McStay).

0733-8627/08/$ - see front matter © 2008 Elsevier Inc. All rights reserved.
doi:10.1016/j.emc.2007.10.004 *emed.theclinics.com*

Viral conjunctivitis

Most cases of viral conjunctivitis are caused by adenoviridae, but enteroviruses and coxsackievirus may also be implicated. Conjunctivitis of viral origin is associated with significant redness and pruritis but should have less discharge than bacterial conjunctivitis. Chemosis and soft tissue swelling may be dramatic. The presence of preauricular lymphadenopathy, conjunctivitis, and a viral prodrome are classic and frequently present. Disease often becomes bilateral in the first 24 to 48 hours [1,2].

Viral conjunctivitis is contagious for almost 2 weeks; patients, family, and caretakers should be educated in appropriate infection-preventing measures, including hand washing. Treatment is symptomatic, with artificial tears, cold compresses, and vasoconstrictor-antihistamine combinations for severe pruritis.

Fever, lymphadenopathy, and conjunctivitis with concomitant pharyngitis constitute pharyngoconjunctival fever, caused by certain strains of adenoviridae. It can have a prolonged course (up to 2 weeks) and resolves spontaneously. Preceding upper respiratory infection supports this diagnosis.

Epidemic keratoconjunctivitis is also caused by strains of adenoviridae (usually adenovirus type 8). It generally presents with thicker discharge and punctuate keratitis (corneal inflammation seen on fluorescein staining), and may result in conjunctival membrane formation with scarring. It has an even longer clinical course (up to 3 weeks) and corneal opacities may persist for months afterwards, affecting vision but ultimately resolving [1,2]. Consultation with an ophthalmologist is recommended to decide whether steroids are indicated based on the presence and extent of the corneal involvement (Fig. 1).

Bacterial conjunctivitis

The pathogens most commonly associated with bacterial conjunctivitis include staphylococci, streptococci, *N gonorrohae*, and *C trachomatis*. In

Fig. 1. Conjunctivitis in Kawasaki disease. (*Courtesy of* Christopher McStay, MD, New York, NY.)

contrast to viral conjunctivitis, discharge may be purulent, and crusting marked, typically with less pruritis. Patients who have bacterial pathogens may be more likely to report eye crusting that impedes opening each morning [3]. The process is more likely to be unilateral, but bilateral involvement does not rule out a bacterial cause. Acuity should be preserved and photophobia absent; presence of either photophobia or decreased visual acuity should raise concern for corneal involvement. In this setting, the practitioner should look for signs of keratoconjunctivitis on slit lamp examination. Corneal involvement portends a worse clinical course and is an indication for ophthalmologic consultation within the ED. Corneal opacification or hypopyon may indicate a keratitis, which could be vision threatening.

If a bacterial pathogen is suspected, treatment with topical drops (eg, quinolone, trimethoprim-polymyxin) should be initiated for 7 to 10 days. Erythromycin ointment may also be used and is preferred in pediatrics for easier compliance. In contact lens wearers, pseudomonal coverage is essential and a quinolone is first line. Most cases of bacterial conjunctivitis resolve spontaneously in a week to 10 days, but antibiotics limit the duration and severity of disease [4]. Delaying antibiotic therapy (by 1–3 days) while awaiting gram stain and culture results appears to cause little harm and may reduce inappropriate antibiotic usage [5]. Ophthalmologic or ED follow-up can be given, with antibiotic choice tailored to culture results. Supportive care, including warm compresses and eye irrigation, are also indicated and are of equal importance. Eye patching should be avoided.

A fulminant course of conjunctivitis in a young, sexually active patient or a neonate (24–48 hours postpartum) should raise the possibility of *N gonorrohae* as the causative organism (Fig. 2). Discharge is often thick, yellowish green, and associated with significant underlying chemosis. Concomitant and symptomatic genitourinary symptoms may be present, but their absence does not rule out the diagnosis. Untreated, corneal involvement leading to rupture and endophthalmitis can ultimately occur. The decision as to

Fig. 2. Fulminant gonococcal conjunctivitis. (*From* Goldman L, Ausiello D, editors. Cecil textbook of medicine. 22nd edition. Philadelphia: Saunders (an imprint of Elsevier); 2004; with permission.)

whether to treat for gonococcal conjunctivitis is based on the history, fulminant course, and gram stain (chocolate agar cultures should also be sent). The practitioner should ask about sexual practices, partners, and symptoms [6]. Treatment is typically more aggressive, and hospital admission for intravenous and topical antibiotics may be warranted. For milder cases, one gram of ceftriaxone intramuscularly and appropriate coverage for concomitant Chlamydia infections (doxycycline or azithromycin) is indicated, in addition to ophthalmic antibiotics (bacitracin, erythromycin ointment). The high risk of corneal involvement warrants daily ophthalmologic follow-up. Sexual partners should seek appropriate medical care.

Neonatal conjunctivitis

In the neonatal period, conjunctivitis can occur and the causes are closely linked with postpartum age at presentation. Conjunctivitis in the first 36 hours postpartum is often chemically induced, caused by silver nitrate used to prevent maternal transmission of gonococcus, Chlamydia, and other bacteria. Almost all infants treated with silver nitrate will develop a transient conjunctivitis that resolves in 1 to 2 days. Silver nitrate drops have largely been replaced by topical erythromycin in the United States. Neonatal symptoms occurring 24 to 48 hours postpartum are often due to *N gonorrhoeae* and should be treated with intravenous penicillin, or intramuscular ceftriaxone or cefotaxime, in addition to saline washes. Topical antibiotics are also indicated; penicillin or erythromycin ointment should be used every 2 hours while discharge persists. Blood cultures and cerebrospinal fluid gram stain and culture are also recommended but are controversial. These patients should also be treated for concomitant Chlamydia infection [7]. Other bacterial causes often occur on days 2 through 5 postpartum and treatment should be guided by gram stain (erythromycin ointment for gram-positive organisms, gentamicin or tobramycin drops for gram-negative organisms). Chlamydial conjunctivitis often occurs on days 5 through 12 postpartum and should be treated with oral erythromycin for 2 weeks.

Episcleritis

Inflammation of the episclera and sclera may be difficult to distinguish. Because their causes and prognoses differ considerably, it is important to differentiate between the two. Both have significant association with systemic disease, so primary care or ophthalmologic follow-up is indicated, based on patient comorbidities and severity of symptoms.

Inflammation of the episclera, generally a benign, self-limited condition, presents as acute redness, tearing, pruritis, and foreign body sensation ("grittiness"), with minimal-to-moderate pain in one or both eyes. It typically occurs in young adults and may be recurrent. Examination will reveal dilated episcleral vessels and an overall injected appearance. The differential

diagnosis also includes conjunctivitis, scleritis, keratitis, and glaucoma. A slit lamp examination should also be performed to rule out other common causes of ocular inflammation. A true change in acuity should prompt the clinician to consider other causes.

To differentiate episcleritis from conjunctivitis, topical anesthetic should be applied and, under slit lamp, the ocular surface probed with a cotton-tipped applicator. Conjunctival vessels will be highly mobile, whereas episcleral vessels should remain relatively fixed. In contrast to conjunctivitis, the findings are generally limited to one segment of the bulbar surface. Conjunctival involvement may also occur in episcleritis but should be focal [8,9]. The episcleral vessels should also blanch with application of a topical vasoconstrictor, which will help the clinician differentiate between episcleritis and scleritis.

Distribution of the findings may be simple or nodular. In simple disease, sectoral involvement of the episclera is generally seen, with only part of the episclera involved. Nodular densities with surrounding injection of the sclera vessels appear in nodular episcleritis.

Episcleritis is of idiopathic origin in two thirds of cases and generally improves after a week or so. Supportive treatment includes the use of artificial tears. The use of topical corticosteroids and nonsteroidal anti-inflammatory drugs has been suggested but both are controversial. A recent study found the duration and severity of symptoms the same with topical ketorolac and artificial tears. Patients treated with ketorolac were more likely to complain of stinging [10]. If treatment has failed by 2 weeks, ophthalmologic referral is indicated. In one third of cases, systemic disease is present. Evaluation for connective tissue, autoimmune vascular, or rheumatoid (more common in nodular subtypes) disease may be indicated. Rosacea and atopy are also commonly associated with episcleritis.

Inflammation of the sclera itself has a more insidious onset, more pronounced pain, and a greater number of complications and systemic associations (Fig. 3). It is most often idiopathic in origin, but patients may

Fig. 3. Scleritis. (*From* Sen HN, Suhler EB, Al-Khatib SQ, et al. Mycophenolate mofetil for the treatment of scleritis. Ophthalmol 2003;110(9):1750–5; with permission.)

give a history of recent eye surgery, infection, new malignancy, or new drug therapy. Patients may describe the onset of progressive pain and visual deterioration over the course of days to weeks. Pain may radiate from the eye to the face and may be intense and boring in nature. Photophobia, tearing, and pain with ocular motion may be present. Patients may notice marked scleral swelling and globe tenderness if the anterior sclera is involved. On examination, swelling may be focal and limited to one part of the globe or may involve the entire visible sclera. The overlying episcleral and conjunctival vessels may be dilated and inflamed, making the diagnosis difficult. Engorgement of vessels with a surrounding violaceous hue is indicative of scleritis. Topical vasoconstrictors will blanch the conjunctival and episcleral vessels, but the sclera itself should remain swollen and inflamed. Findings adjacent to the cornea may also show a keratitis. Areas of necrosis should raise the possibility of an infectious cause of scleritis, including tuberculosis. Necrotizing scleritis will also reveal areas of capillary nonperfusion and represents an immediate threat to globeintegrity [8,9].

In patients who do not have involvement of the anterior sclera, posterior scleritis is easily missed. Patients may have similar presenting symptoms and may also have proptosis. Alternatively, patients may present with minimal pain, complaining only of visual loss in a rare variant of necrotizing posterior scleritis. Concomitant, secondary uveitis, either anterior or posterior, is not uncommon and the ED practitioner can easily be fooled into thinking this is the primary diagnosis. Retinal detachment or other retinal pathology may also accompany posterior scleritis, but the painful nature of the condition should initiate a more thorough workup. Diagnosis by ultrasound is preferred. CT with intravenous contrast may be helpful in these cases and can show a thickened scleral component. MRI is also useful but is not routinely available in the ED [8,9,11].

One half of all cases of scleritis are associated with systemic disease. The most commonly associated disease is rheumatoid arthritis. Other associations include Wegener's granulomatosis, relapsing polychondritis, systemic lupus erythematosus, and polyarteritis nodosa. Workup for these conditions can begin in the ED or with the patient's primary care provider. All patients should have screening tests for syphilis. Tuberculosis and Hansen's disease can also cause a granulomatous scleritis.

Complications of scleritis include necrosis, scleral thinning, and visual loss. Treatment with oral indomethacin is the standard of care in patients who have active anterior scleritis. Necrotizing or posterior scleritis should be treated in concert with ophthalmologic consultation; treatment should include systemic and intraocular steroid injection. If disease is mild, with no tenting of the sclera, and with no secondary iritis or uveitis, treatment can be deferred, with close ophthalmologic follow-up. If an infectious cause is suspected (postsurgical patients, necrosis, immunocompromised hosts), treatment decisions should be made with an ophthalmologic consultant.

Antibiotic penetration into the sclera is generally poor, owing to its avascular nature [8,9].

Keratitis

Inflammation of the cornea with or without violation of its epithelium constitutes keratitis. Patients will present with an acutely red, painful eye and often complain of foreign body sensation, photophobia, tearing, and vision change. Infectious causes may be associated with secondary lid edema, conjunctival reaction, hypopyon, and anterior chamber reaction. Photophobia is due to ciliary spasm. Keratitis is most often viral or bacterial in origin, but exposure to intense ultraviolet light, chemicals, and contact lenses may be implicated. Contact lens use itself imparts a 10-fold risk of developing an infectious keratitis. Corneal abrasions may accompany (or mimic) a keratitis because of excessive rubbing or scratching of the affected eye. Prompt diagnosis, treatment, and identification of cause are paramount to prevent vision loss due to ulceration, necrosis, and scarring [12,13].

Patients should receive a full ophthalmologic examination. The presence of corneal opacification, ulceration, hypopyon, or other irregularities strengthen the diagnosis. Fluorescein staining is essential to evaluate for epithelial disruption, and its pattern can also help reveal the cause.

Viral keratitis

The herpesviridae (herpes simplex virus [HSV]-1, HSV-2, varicella zoster virus [VZV], Epstein-Barr virus [EBV], cytomegalovirus [CMV]) are the viral agents most commonly associated with keratitis. Their clinical presentations and treatments have considerable overlap.

HSV can present with ocular involvement in primary or recurrent infections. Primary infections often occur in neonates (by way of maternal delivery with active lesions) or at 6 months of age (by way of saliva), when maternal antibodies no longer protect the infant from HSV transmission. A follicular conjunctivitis with the presence of lid or periorbital vesicles should alert the clinician to HSV infection. Slit lamp examination may show staining of the cornea in a dendritic pattern. Ophthalmologic antivirals and systemic antivirals (acyclovir) should be initiated promptly. Corneal involvement may lag behind and persist after conjunctival and dermatologic involvement.

Most HSV pathology is caused by recurrent disease and may present without dermatologic findings. Patients may complain simply of eye pain, redness, and change in vision. Slit lamp examination should reveal a corneal ulcer with fluorescein uptake in a characteristic dendritic branching pattern that extends outward. Sometimes, the ulcer alone may stain with fluorescein, without staining of the advancing dendritic cells. In these cases, ophthalmologic consultation for rose bengal or other dye staining will reveal the

pattern. Advanced or recurrent disease may lead to stromal (subepithelial corneal matrix) involvement with opacification, thinning, and edema present on slit lamp examination [14].

The cornea should be debrided of infected cells using a cotton applicator, starting with the ulcer. This procedure can be done by the ED practitioner or, preferably, by the ophthalmologic consultant. Pharmacologic treatment of HSV keratitis consists of ophthalmic antiviral drops (acyclovir or idoxuridine) or systemic antiviral medication (oral acyclovir). ED ophthalmologic consultation is indicated and close follow-up or admission is appropriate. Topical drops may be associated with corneal toxicity and could prolong healing, so some clinicians prefer oral agents. Some research suggests that topical ganciclovir gel may also be effective. Daily ophthalmologic follow-up or admission is indicated (Fig. 4) [14,15].

Reactivation of herpes zoster virus in the trigeminal distribution can cause significant ocular disease, including a keratitis. Zoster is often preceded by a viral prodrome of malaise, fever, headache, and neuralgia. Ocular and periorbital disease can then follow, with the conjunctiva, lid, and periorbital skin showing crops of vesicular lesions. The rash is typically unilateral, does not cross the midline, and involves only the upper portion of the lid. The presence of vesicular lesions on the tip of the nose (nasociliary branch of the ophthalmic division of trigeminal V1), or Hutchinson's sign, should prompt the clinician to evaluate the cornea for involvement. Disease can be marked and conjunctival vesicles with scarring can occur [16].

Corneal involvement usually occurs after other manifestations and may present after other symptoms have resolved, or separately from them. Fluorescein staining will reveal dendritic branching that is thicker and more rope-like than the lace-like pattern of HSV keratitis. Terminal bulbs, present in HSV keratitis, should be absent in VZV. Fluorescein uptake is much less pronounced on the VZV dendrites, so inspection under slit lamp must be

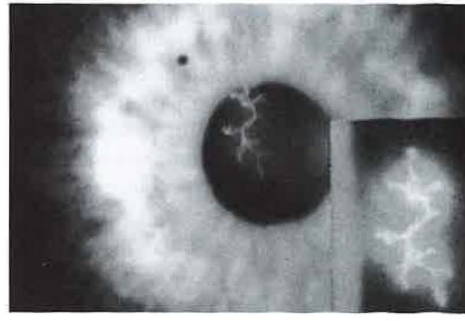

Fig. 4. HSV keratitis with characteristic dendritic pattern of staining. (*From* Goldman L, Ausiello D, editors. Cecil textbook of medicine. 22nd edition. Philadelphia: Saunders (an imprint of Elsevier); 2004; with permission.)

careful so as to avoid missing the lesions. Complications include uveitis and keratitis (even bacterial coinfection). Ophthalmologic consultation is indicated to start oral versus topical antivirals. Steroids are controversial and should not be started by the emergency practitioner [15,16].

EBV and CMV can also cause a keratitis, but this is much more likely in the immunocompromised host. A dendritic corneal branching pattern is often seen with EBV and the conjunctiva and soft tissue may be affected as in HSV infection. Diagnosis is made by way of polymerase chain reaction of infected cells. Supportive care is indicated; the use of systemic antivirals is controversial. In the ED, where it will be difficult to distinguish cause, starting the patient on oral acyclovir may be appropriate. CMV keratitis has been reported but is uncommon. Its corneal findings are almost identical to VZV [17].

Bacterial keratitis

The propensity to cause visual loss makes bacterial keratitis an ophthalmologic emergency. Its incidence is increasing in the setting of contact lens use. Most cases are caused by staphylococcal species, but in contact lens wearers, pseudomonas species may predominate. Both organisms have increased because of contact lens use; in the non–contact lens wearer, streptococcal species are common. In immunocompromised patients, *Moraxella catarrhalis* should be considered. Patients will complain of pain, tearing, and decreased vision. *N gonorrohae* and *C trachomatis* should be considered in the sexually active patient, particularly if conjunctivitis is present. Depending on the causative organism and the condition of the underlying cornea, physical examination may reveal a corneal ulcer, with or without surrounding stromal involvement. The overlying epithelium may be absent. The cornea will often be opacified and edematous, and hypopyon may be present. The surrounding conjunctiva may show injection with vessel dilatation [18].

Topical aminoglycosides, quinolones, or cephalosporins should be used, based on history and gram stain. If gram stain is unavailable or the causative organism is unlikely to be discovered in the ED, broad-spectrum coverage using two antibiotics should be initiated with rapid alternating of agent (eg, two drops aminoglycoside followed by two drops of cephalosporin every 5 minutes for the first hour followed by applications every 15 minutes to 1 hour around the clock). Alternatively, quinolone monotherapy may be effective. ED ophthalmologic consultation should be obtained and the patient admitted [18].

Keratitis due to light exposure

Prolonged exposure to ultraviolet light, or brief exposure to intense ultraviolet flashes, can produce a photokeratitis or photokeratoconjunctivitis of noninfectious origin. Patients may complain of eye pain, change in vision,

and redness. The staining pattern is generally punctuated with some degree of corneal opacification. Ancillary signs of infection (purulent discharge, cellulitic changes) are generally absent. In punctuate keratitis due to welding exposure, symptoms begin hours after exposure. In patients who have had prolonged ultraviolet exposure (ie, snow blindness), time to onset may be variable [19]. Topical antibiotics are indicated to prevent bacterial superinfection.

Uveitis

Understanding the anatomy of the uvea is essential in diagnosing and treating the different forms of uveitis. The uvea is the middle eye. Anteriorly, this includes the iris and ciliary body, with the posterior reflection of these structures known as the choroid. Inflammation of the anterior structures presents with anterior chamber reaction and is easily seen and diagnosed in the ED. Inflammation of the anterior chamber (anterior uveitis) is a much more common presentation in the ED than middle or posterior involvement. Posterior involvement is synonymous with retinitis. Inflammation of the uveal structures can be a primary, idiopathic process, or can occur secondary to other ophthalmologic infections or inflammatory conditions.

Anterior uveitis

Patients who have anterior uveitis (commonly called iritis) can present with a remarkable range of complaints, from mild visual disturbance to severe pain and loss of vision. Approximately 50% of cases are considered idiopathic and the next most common cause is thought to be HLA-B27 associated. Patients typically present with eye pain, redness, decreased vision, photophobia, and headache. The symptoms may mimic glaucoma, which must be ruled out first by measuring intraocular pressure. When present, scleral injection and anterior chamber cells and flare make the diagnosis clear. The limbus is characteristically injected (known as ciliary flush) and the pupil is often constricted. In idiopathic anterior uveitis, small keratic precipitates may be present in the anterior chamber. Larger, granulomatous or clumpy precipitates should lead the physician to consider specific causes, including syphilis, toxoplasmosis, and tuberculosis. Hypopyon, when present, should prompt the clinician to think of HLA-B27–associated disease, and referral to a rheumatologist is appropriate [20].

In patients who have HIV, the antibiotic rifabutin and the antiviral cidofovir should be considered as possible causes. Both have been associated with anterior uveitis, and withdrawal of the drug, or reduction of the dose, is often enough to stop or reduce symptoms [21]. Anterior chamber reaction can also be secondary to many of the other conditions discussed in this article, including scleritis, episcleritis, and posterior segment disease. Autoimmune diseases, such as sarcoidosis, are also associated with anterior chamber reactions (Fig. 5).

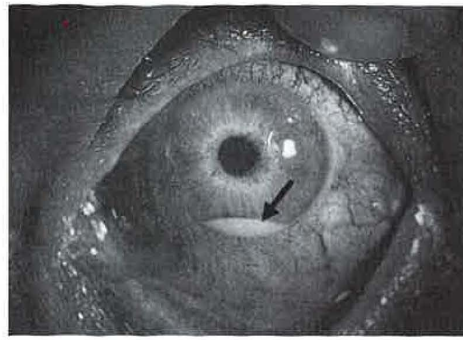

Fig. 5. Acute anterior uveitis with hypopyon (*arrow*). (*From* Munoz-Fernandez S, Martin-Mola E. Uveitis. Best Pract Res Cl Rh 2006;20(3):487–505; with permission.)

The ED workup will be dictated by the patient presentation. Individuals with only mild complaints without visual disturbance could be referred for ophthalmology follow-up. Those who have acute onset and severe symptoms may require more thorough testing in the ED, including chest radiography, angiotensin-converting enzyme, and syphilis and tuberculosis testing.

The common treatment for uncomplicated anterior uveitis is topical corticosteroid drops, which could potentially be started from the ED in conjunction with ophthalmology consultation. The addition of scopolamine or cyclopentolate drops may help decrease the pain associated with ciliary spasm. Disease that does not improve, or worsens, in the setting of steroid treatment should alert the practitioner to an infectious cause, particularly tuberculosis.

Intermediate uveitis

Patients who have blurry vision or floaters, mild pain, and redness but without elevated intraocular pressure or anterior chamber findings may have intermediate uveitis. Intermediate uveitis comprises inflammation of the anterior vitreous humor, the peripheral retina, or the pars plana ciliaris (the posterior aspect of the ciliary body). Examination will reveal anterior vitreous floaters and inflammatory cells, absence of anterior chamber cells, and snowbank-like exudates heaped at the inferior pars plana (in patients who have pars planitis). The diagnosis of pars planitis may be difficult to make because most ED practitioners are not familiar with scleral depression, which may be required to see the heaped exudates. Concomitant macular edema, cataract formation, or retinal detachment are the most common complications, in descending frequency. Disease is often bilateral and presents in patients in the first half of life; presentation in the elderly should raise the specter of human T-cell lymphoma virus–associated disease.

The association of uveitis with systemic disease should prompt investigation based on patient age and comorbidities. All patients who have not been evaluated for sarcoidosis should receive a chest radiograph as a screening test. Screening for syphilis is recommended. Its association with multiple sclerosis and Lyme disease has been documented. Still, most cases are idiopathic in origin.

Treatment should be initiated in concert with ophthalmologic consultation, and includes intraocular and systemic corticosteroids. Further ophthalmologic treatment is beyond the scope of the emergency physician.

Posterior uveitis and retinitis

Posterior uveitis and retinitis can be thought of interchangeably. The ED practitioner should be aware of the causes of acute retinitis. For the purposes of this article, retinitis pigmentosa and other slowly progressive causes of retinal deterioration are not discussed.

In the immunocompromised host (eg, patients who have AIDS, or who are on chemotherapy or receiving immunosuppressive treatment), progressive, painless vision loss should alert the practitioner to the possibility of CMV-induced retinitis. Patients may also complain of floaters and light flashes. CMV retinitis is a marker of profound immune suppression and rarely presents in AIDS patients unless the CD4 count is very low, but occasionally is the presenting symptoms of undiagnosed HIV infection [22]. Examination will generally reveal a necrotic retinitis with whitening. Hemorrhages may be present at the advancing edge of the lesion. Other causative organisms should be considered in the immunocompromised patient, including tuberculosis, toxoplasmosis, syphilis, and other herpesviridae. In the immunocompromised patient who has suspected CMV retinitis, acute or subacute visual loss does not preclude the diagnosis because retinal detachment is a well-described complication. Diagnosis of CMV retinitis warrants hospital admission and initiation of treatment with ganciclovir.

HSV and VZV can also cause a retinitis. Their pattern of retinal involvement and clinical presentation vary, depending on the host's immune status. In the immunocompromised host, HSV and VZV cause a rapidly progressive retinal necrosis without evidence of vasculitis and with minimal vitreous inflammatory changes. The pattern of retinal necrosis may be patchy and it may begin at the periphery, making diagnosis difficult for the ED practitioner. These viruses can also cause an acute retinal necrosis in the immunocompetent patient, with a marked vitritis and with a retinal vasculitic appearance. Eventually, retinal detachment occurs. Treatment for both is with intravenous acyclovir [23].

Hordeolum and chalazion

Patients who present complaining of acute onset of pain, focal swelling, and lid edema should be evaluated for hordeolum. A hordeolum represents

purulent infection of a cilium and adjacent gland with local abscess formation. They can be either present at the lid margin or contained in the lid itself. The resulting abscess can point toward either the mucosa (internal) or the skin (external surface). They will generally swell and then ultimately resolve on their own within a week. Staphylococcal species are the most common causative organism. Cellulitis may accompany the hordeolum. Treatment is conservative, with warm compresses several times a day for 10 minutes. If this fails, an incision and drainage may be performed. Some sources cite the need for topical antibiotics to prevent local complications, but their use is controversial.

Chalazions are granulomatous inflammatory lesions present on the lid that occur from obstruction of a sebaceous gland (Fig. 6) [24]. They may arise acutely or persist and recur after initial formation. Clinically, they are often indistinguishable from hordeolum and there is little reason to separate them. Indeed, a hordeolum may occur acutely in the setting of a chalazion. They may resolve spontaneously, similar to a hordeolum, with a more sebaceous, waxy drainage. Recurrent chalazions need ophthalmologic referral for biopsy and evaluation for malignant origin [24].

Dacryocystitis

Acute infection of the lacrimal sac will present as pain, swelling, and erythema overlying the sac. Dacryocystitis is the result of obstruction of the nasolacrimal duct and resultant purulent infection. Staphylococcal species are the most common causative organisms. It is managed conservatively initially with warm compresses and massage of the infected sac to encourage drainage of purulent material through the puncta. Oral and topical antistaphylococcal antibiotics are also indicated. Prompt ophthalmologic

Fig. 6. Bilateral chalazion. (*From* Goldman L, Ausiello D, editors. Cecil textbook of medicine. 22nd edition. Philadelphia: Saunders (an imprint of Elsevier); 2004; with permission.)

follow-up is indicated to evaluate for response to therapy. Patients who have signs of systemic illness should be hospitalized (Fig. 7).

In cases of impending rupture, incision and drainage are indicated, which, in the ED, should be done by an ophthalmologist, if possible. Aspiration with a high-gauge needle before incision and drainage should be performed and sent for culture. Incision and drainage is then performed in a vertical fashion, and purulent contents curetted. Prompt ophthalmologic referral is then indicated for follow-up and potential surgical intervention [24]. Acute dacryocystitis may progress to periorbital or orbital cellulites, depending on direction of spread and host factors. These patients should be managed as outlined in the next section.

Periorbital and orbital cellulitis

Infection of the periorbital and orbital soft tissues may represent extension of a primary infection, or may accompany other ocular pathology. Superficial anterior infection, with involvement limited by the ocular fascia, presents as upper or lower lid edema, pain, and warmth. Patients may have systemic symptoms (eg, fever), but change in vision should be absent and the pupil examination and intraocular pressures normal. Ocular range of motion should be essentially intact, with little pain. Treatment is with antistaphylococcal antibiotics, and selected cases may be managed in the outpatient setting. Amoxicillin-clavulanate or a suitable cephalosporin may be used (eg, cefpodoxime) [24,25].

Involvement of the orbital soft tissues is much more serious, with significant chance of permanent ocular damage and potentially fatal infectious consequences. Patients will present with marked swelling, pain, and edema,

Fig. 7. Acute dacryocystitis. (*From* Goldman L, Ausiello D, editors. Cecil textbook of medicine. 22nd edition. Philadelphia: Saunders (an imprint of Elsevier); 2004; with permission.)

but symptoms will be more pronounced. Proptosis may be present, and the eye may exhibit an afferent papillary defect. Extraocular motion may be either limited or associated with pain. Intraocular pressure may be elevated because of external compression. CT is indicated to aid in diagnosis and to evaluate for abscess or soft tissue extension. Periorbital swelling should be evident on CT, and contrast enhancement may aid in abscess identification.

Most cases of orbital cellulitis represent an extension of sinusitis. Staphylococcal species are the most common pathogen, but other gram-positive organisms should be considered when starting antibiotics. Pseudomonas should also be considered in recently hospitalized, instrumented, or immunocompromised patients. The remaining cases are caused by primary infection of the lid or face, or by a foreign body. A recent case series in the pediatric population showed increasing presence of methicillin-resistant *Staphylococcus aureus* in orbital cellulitis, so vancomycin should be considered [24–26].

Ophthalmologic consultation and admission is indicated for cases of orbital cellulitis. The presence of proptosis, a dilated pupil, or vision loss portends a worse clinical course. Sinus drainage is often performed. Other complications, including cavernous sinus thrombosis and meningitis, have been described.

References

[1] Rubenstein JB, Jick SL. Cornea and external disease. In: Yanoff M, Duker JS, editors. Yanoff opthalmology. 2nd edition. Philadelphia: Mosby; 2004. p. 398–404.
[2] Kaufman HE. Treatment of viral diseases of the cornea and external eye. Prog Retin Eye Res 2000;19(1):69–85.
[3] Rietveld RP, ter Riet G, Bindels PJ, et al. Predicting bacterial cause in infectious conjunctivitis: cohort study on informativeness of combinations of signs and symptoms. BMJ 2004; 329:206–10.
[4] Sheikh A, Hurwitz B. Antibiotics versus placebo for acute bacterial conjunctivitis. Cochrane Database Syst Rev; 2006.
[5] Everitt HA, Little PS, Smith PW. A randomised controlled trial of management strategies for acute infective conjunctivitis in general practice. BMJ 2006;333:321–4.
[6] Wan WL, Farkas GC, May WN, et al. The clinical characteristics and course of adult gonococcal conjunctivitis. Am J Ophthalmol 1986;102:575–83.
[7] Woods CR. Gonococcal infections in neonates and young children. Semin Pediatr Infect Dis 2005;16(4):258–70.
[8] Jabs DA, Mudun A, Dunn JP, et al. Episcleritis and scleritis: clinical features and treatment results. Am J Ophthalmol 2000;130:469–76.
[9] Okhravi N, Odufuwa B, McCluskey P, et al. Scleritis. Surv Ophthalmol 2005;50:351–63.
[10] Williams CP, Browning AC, Sleep TJ, et al. A randomised, double-blind trial of topical ketorolac vs artificial tears for the treatment of episcleritis. Eye 2005;19:739–42.
[11] McCluskey PJ, Watson PG, Lightman S, et al. Posterior scleritis: clinical features, systemic associations, and outcome in a large series of patients. Ophthalmology 1999;106:2380–6.
[12] Keay L, Edwards K, Naduvilath T, et al. Microbial keratitis: predisposing factors and morbidity. Ophthalmology 2006;113:109–16.
[13] Titiyal JS, Negi S, Anand A, et al. Risk factors for perforation in microbial corneal ulcers in north India. Br J Ophthalmol 2006;90:686–9.

[14] Kaye S, Choudhary A. Herpes simplex keratitis. Prog Retin Eye Res 2006;25:355–80.
[15] Tabbara KF. Treatment of herpetic keratitis. Ophthalmology 2005;112:1640–1.
[16] Shaikh S, Ta CN. Evaluation and management of herpes zoster ophthalmicus. Am Fam Physician 2002;66(9):1723–30.
[17] McLeod SD. Infectious keratitis. In: Yanoff M, Duker JS, editors. Yanoff ophthalmology. 2nd edition. Philadelphia: Mosby; 2004. p. 466–91.
[18] Thomas PA, Geraldine P. Infectious keratitis. Curr Opin Infec Dis 2007;20(2):129–41.
[19] Cullen AP. Photokeratitis and other phototoxic effects on the cornea and conjunctiva. Int J Toxicol 2002;21(6):455–64.
[20] Gutteridge IF, Hall AJ. Acute anterior uveitis in primary care. Clinical Exp Optom 2007;90(2), 70–82.
[21] Bhagat N, Read RW, Rao NA, et al. Rifabutin-associated hypopyon uveitis in human immunodeficiency virus–negative immunocompetent individuals. Ophthalmology 2001; 108:750–2.
[22] Pertel P, Hirschtick R, Phair J, et al. Risk of developing cytomegalovirus retinitis in persons infected with the human immunodeficiency virus. J Acquir Immune Defic Syndr 1992;5: 1069–74.
[23] Ganatra JB, Chandler D, Santos C, et al. Viral causes of acute retinal necrosis syndrome. Am J Ophthalmol 2000;129:166–72.
[24] Wald ER. Periorbital and orbital infections. Pediatr Rev 2004;25(9):312–20.
[25] Starkey CR, Steele RW. Medical management of orbital cellulitis. Pediatr Infect Dis J 2001; 20:1002–5.
[26] McKinley SH, Yen MT, Miller AM, et al. Microbiology of pediatric orbital cellulitis. Am J Ophthalmol; 2007;144(4):497–501.