Correlation of Primary Tumor Prostate-Specific Membrane Antigen Expression with Disease Recurrence in Prostate Cancer

Jeffrey S. Ross,[1,4] Christine E. Sheehan,[1] Hugh A. G. Fisher,[2] Ronald P. Kaufman, Jr.,[2] Prabhjot Kaur,[1] Karen Gray,[4] Iain Webb,[4] Gary S. Gray,[4] Rebecca Mosher,[4] and Bhaskar V. S. Kallakury[1,3]

Departments of [1]Pathology and Laboratory Medicine and [2]Surgery, Albany Medical College, Albany, New York; [3]Department of Pathology, Georgetown University Hospital, Washington, DC; and [4]Millennium Pharmaceuticals, Inc., Cambridge, Massachusetts

ABSTRACT

Purpose: **The restricted expression of the surface glycoprotein prostrate-specific membrane antigen (PSMA) to normal prostate tissue, primary and metastatic prostate cancer (PCa), and the neovasculature of various nonprostatic epithelial malignancies has enabled targeting strategies for PCa treatment using anti-PSMA antibodies.**

Experimental Design: **Using prostatectomy specimens, immunohistochemical staining for PSMA (7E11 antibody) was performed on formalin-fixed paraffin-embedded sections of 136 cases of PCa. Cytoplasmic immunoreactivity was scored for intensity and distribution, and results were correlated with tumor grade, pathological stage, DNA ploidy status (Feulgen spectroscopy), and disease recurrence. PSMA mRNA expression in selected primary tumors and metastatic lesions was also detected using *in situ* hybridization and autoradiography.**

Results: **Generally, PCa cells expressed relatively increased levels of PSMA as compared with benign elements. Among the PCa cases, increased (high) PSMA expression correlated with tumor grade ($P = 0.030$), pathological stage ($P = 0.029$), aneuploidy ($P = 0.010$), and biochemical recurrence ($P = 0.001$). The mean serum prostate-specific antigen level of 18.28 ng/ml at the time of diagnosis for the PSMA-overexpressing tumors was significantly greater than the mean serum prostate-specific antigen of 9.10 ng/ml for the non-PMSA-overexpressing group ($P = 0.006$). On multivariate analysis, pathological stage ($P = 0.018$) and PSMA expression ($P = 0.002$) were independent predictors of biochemical recurrence. PSMA protein overexpression in high-grade primary PCa tumors and metastatic lesions also correlated with increased PSMA mRNA expression levels using *in situ* hybridization and autoradiography.**

Conclusions: **This study demonstrates for the first time that overexpression of PSMA in primary PCa correlates with other adverse traditional prognostic factors and independently predicts disease outcome.**

INTRODUCTION

Prostate-specific membrane antigen (PSMA) is a transmembrane folate hydrolase consisting of 750 amino acids and having a molecular weight of M_r 110,000 (1–3). PSMA expression has been consistently demonstrated by immunohistochemistry (IHC) and other techniques in normal and hyperplastic prostate tissues, in prostatic intraepithelial neoplasia, and in invasive carcinomas (4–6). PSMA expression and PSMA enzymatic activity are greater in prostate cancer (PCa) specimens than in benign prostate tissues (6, 7). The first descriptions of increased PSMA expression in PCa associated this finding with high tumor grade and the presence of metastases (6, 8, 9), suggesting that PSMA expression could be an adverse prognostic factor for the disease. The finding that PSMA was intensely expressed in metastatic PCa (8, 9) led initially to the development of diagnostic imaging strategies using anti-PSMA antibodies (10, 11) and subsequently to clinical testing of radioconjugated anti-PSMA antibodies for the treatment of metastatic disease (12–14). Further evidence that PSMA expression was up-regulated by androgen deprivation has fueled interest in anti-PSMA therapies for hormone-refractory PCa (15). The identification of PSMA expression in the neovasculature of patients with non-PCa has also encouraged the potential use of anti-PSMA antibody therapies for patients with carcinomas of the kidney, lung, colon, breast, and other organs (16–18). Despite the current interest in PSMA as a target of therapy for patients with hormone-refractory PCa and clinical use of PSMA-directed tumor imaging (ProstaScint), PSMA expression in primary PCa has not been evaluated previously as a standalone prognostic marker. The following study is the first evaluation of PSMA expression status as a predictor of PCa disease outcome.

MATERIALS AND METHODS

Specimen Collection, Tumor Grading, and Pathological Staging. One hundred and thirty-six patients who underwent radical prostatectomy for biopsy-proven prostate adenocarcinoma between 1987 and 1997 at the Albany Medical Center Hospital were randomly selected from a group of 1440 cases. Patients who had received adjuvant therapy were excluded from this study. H&E-stained slides from each radical prostatectomy specimen were reviewed, and a Gleason grade (19) and patho-

Received 2/25/03; revised 8/25/03; accepted 8/25/03.

Grant support: Funded in part by Millennium Pharmaceuticals, Inc.

The costs of publication of this article were defrayed in part by the payment of page charges. This article must therefore be hereby marked *advertisement* in accordance with 18 U.S.C. Section 1734 solely to indicate this fact.

Note: Presented in part at the 92nd Annual Meeting of the United States and Canadian Academy of Pathology, March 2003, Washington, DC.

Requests for reprints: Jeffrey S. Ross, Department of Pathology and Laboratory Medicine, Albany Medical College, Mail Code 81, 47 New Scotland Avenue, Albany, New York 12208. Phone: (518) 262-5461; Fax: (518) 262-8092; E-mail: rossj@mail.amc.edu.

Downloaded from http://aacrjournals.org/clincancerres/article-pdf/9/17/6357/2085645/zdf01703006357.pdf by guest on 27 July 2022

Fusion Pharmaceuticals, Inc.
Exhibit 1021.001

logical stage (20) were assigned. During review, multiple blocks were identified based on the presence of adequate tumor and the representative nature of the overall tumor grade. Tumors were classified as high grade when the combined Gleason score was ≥7 and as low grade when the combined score was ≤6. Tumor grading was performed without knowledge of the PSMA and DNA ploidy results. Serum prostate-specific antigen (PSA) levels were obtained from the patient's medical records in every case. Serum PSA was measured by the Hybritech tandem method (Beckman Coulter, Inc., Brea, CA). A postsurgical elevation of the PSA level from a baseline level of 0 to >0.4 ng/ml on two consecutive occasions was considered as biochemical evidence of disease recurrence. Follow-up information was obtained from review of the patient's medical records.

IHC. Immunohistochemical staining for PSMA was performed by an automated method on the Ventana ES IHC instrument (Ventana Medical Systems, Inc., Tucson, AZ) using contiguous formalin-fixed paraffin-embedded 4-μm sections from a representative block in each case. After deparaffinization to water, the antigenic determinant sites were unmasked in citrate buffer with steam for 60 min. The samples were then reacted with the primary antibody, a mouse antihuman PSMA monoclonal antibody (clone 7E11; American Type Culture Collection, Manassas, VA) of the IgG1 isotype directed against the internal domain of the PSMA protein. The secondary antibody was biotinylated goat antimouse immunoglobulins (DAKO, Carpinteria, CA) at a dilution of 1:250. The tissue section-bound antibody complex was detected using a biotin avidin diaminobenzidine detection system (Ventana Medical Systems). After the development of the color with diaminobenzidine, the slides were counterstained with hematoxylin. Benign elements in all cases served as internal positive controls, and a PCa specimen known to be positive for intense PSMA expression served as an external positive control. To confirm the specificity of the primary antibody, slides were processed with every batch using a matched immunoglobulin (Sigma, St. Louis, MO) of the same isotype at the same concentration as that of the primary antibody.

IHC Staining Interpretation. Immunoreactivity for PSMA was interpreted without prior knowledge of any of the clinicopathological parameters or DNA ploidy. The intensity of staining and the distribution of cytoplasmic positivity were considered in the semiquantitative assessment of the immunohistochemical results for the 7E11 antibody. The distribution of staining in the tumor cells was graded as focal (≤10% of all PCa tumor cells on the selected slide), regional (11–50% of PCa cells), or diffuse (>50% of PCa cells). The intensity of cytoplasmic staining was subjectively graded as weak, moderate, or intense. Cases in which the staining patterns were categorized as intense diffuse, intense regional, or moderate diffuse were considered as overexpressing (or "high") PSMA protein.

***In Situ* Hybridization.** *In situ* hybridization was performed using formalin-fixed, acetylated, dehydrated, and delipidated frozen tissue sections with ^{35}S-labeled riboprobes. Gene-specific T3 sense and T7 antisense *in situ* hybridization probes were generated by PCR to the domain that is found in all variants of PSMA reported to date. Probes were labeled by reverse transcription (Promega) following the manufacturer's instructions in the presence of ^{35}S-UTP; unlabeled ATP, GTP, and CTP; and 200–500 ng of DNA template with purification on MicroSpin G-25 columns (Amersham Biosciences). Slides were hybridized with 50% formamide, 10 mM Tris-HCl, 0.2 mg/ml yeast tRNA, 1× Denhardt's solution, 10% dextran sulfate, 600 mM NaCl, 0.25% SDS, and 2×10^6 cpm/μl riboprobe. Hybridization was done at 55°C overnight, followed with washing of slides sequentially at low and high stringency with 2× SSC and 0.2× SSC at 60°C, and then with 20 μg/ml RNase A at 37°C. The washed hybridized slides were dehydrated, dipped in the NTB2 photographic emulsion (VWR International), incubated for 10–14 days at 4°C, developed with Kodak Dektol developer and fixer, and counterstained with hematoxylin. The results were quantitated as a range of hybridization intensities estimated by the number of silver grains over the epithelial cells and on the approximate percentage of cells found positive.

Quantitative DNA Analysis. Five-μm formalin-fixed paraffin-embedded sections were stained by the Feulgen method and analyzed for DNA content with the CAS 200 Image Analyzer (Cell Analysis Systems, Lombard, IL; Ref. 21). After the instrument was calibrated against similarly stained tetraploid rat hepatocytes, the DNA content of the cases with PCa was measured in a minimum of 100 tumor cells, and the tumor DNA index was determined by comparison with the control diploid cells of the benign prostatic epithelium. All of the tumor cell histograms were reviewed without knowledge of the tumor grade, pathological stage, recurrence status, or immunohistochemical results. A DNA index of 0.77–1.22 was considered to be diploid. Peaks in the tetraploid region containing <15% of the total cell population were considered to be the G_2-M components of diploid cell populations. Tumors with tetraploid peaks >15% and hyperdiploid, nontetraploid peaks were considered to be nondiploid (aneuploid; Ref. 21).

Statistical Analysis. Statistical comparisons were carried out with the STATA software (Stata Corp., College Station, TX). The χ^2 test was used to determine the significance of the associations between PSMA expression and pathological variables. The *t* test was used to test the equality of the means between PSMA-overexpressing and non-PSMA-overexpressing groups. Disease recurrence analysis was performed with univariate models and by the Kaplan-Meier method. Multivariate analysis including clinicopathological parameters and PSMA expression was performed using the Cox proportional hazards model. The level of significance was set at $P < 0.05$.

RESULTS

Clinicopathological Data. The mean age of the patients was 66 years (range, 49–94 years), and the mean preoperative PSA level was 12.4 ng/ml (range, 1.6–87.8 ng/ml). Of the 136 cases of PCa, there were 76 (56%) low-grade tumors (Gleason score ≤ 6) and 60 (44%) high-grade tumors (Gleason score > 7). At prostatectomy, there were 83 (61%) organ-confined tumors (pathological stages I and II) and 53 (39%) advanced-stage (III and IV) tumors. Of the 96 cases analyzed previously for total DNA content, 68 (71%) were diploid, and 28 (29%) were nondiploid. Follow-up information was available for all patients, 57 (42%) of whom had biochemical postsurgical disease recurrence.

Downloaded from http://aacrjournals.org/clincancerres/article-pdf/9/17/6357/2085645/zdf01703006357.pdf by guest on 27 July 2022

Fusion Pharmaceuticals, Inc.
Exhibit 1021.002

Table 1 Correlation of PSMA[a] expression status with clinical parameters and disease outcome in 136 cases of prostate cancer treated by radical prostatectomy

Clinical parameter/disease outcome	PSMA expression status (no. of patients)		Significance (*P*)
	Nonoverexpressing[b] (71)	Overexpressing[c] (65)	
Mean preoperative PSA (ng/ml)	9.10 ± 5.91	18.28 ± 17.70	0.006
Mean tumor Gleason score	5.92 ± 1.20	6.33 ± 1.21	0.04
Mean DNA index (diploid = 1.00)	1.03 ± 0.33	1.32 ± 0.50	0.002
Advanced tumor stage (III/IV)	23/71 (32%)	33/65 (51%)	0.029
Recurrent disease	20/71 (28%)	37/65 (57%)	0.001
Mean time to recurrence (mo)	43.75	34.78	0.001

[a] PSMA, prostate-specific membrane antigen; PSA, prostate-specific antigen.
[b] Low staining intensity.
[c] High staining intensity.

PSMA Protein Expression by IHC. The immunostaining pattern for PSMA was cytoplasmic with tumor cells in all cases of PCa showing variably increased staining as compared with the weak expression in benign elements (Table 1). Sixty-five of 136 (48%) patients with PCa featured intense or "highly" overexpressed PSMA (Fig. 1*A*) staining compared with 71 (52%) patients with PCa who showed increased but not intense overexpression of the protein as compared with benign prostatic tissues (Fig. 1*B*). Overexpression of PSMA correlated with high tumor grade ($P = 0.04$). The mean Gleason score of tumors with background PSMA expression was 5.92, and the mean Gleason score of the tumors with PSMA overexpression was 6.33. PSMA overexpression was also associated with the presence of nondiploid tumors ($P = 0.01$). The mean DNA

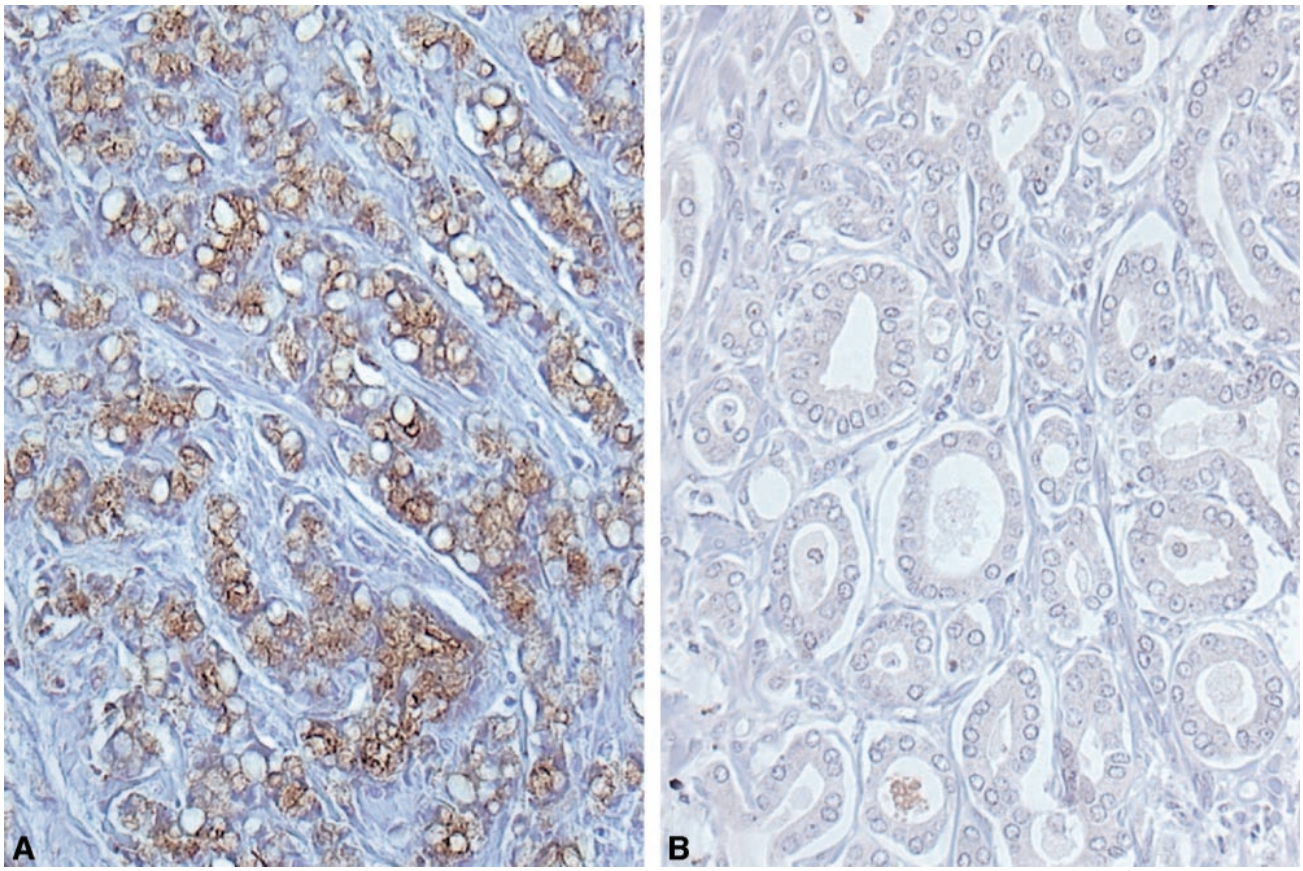

Fig. 1 *A,* intense prostate-specific membrane antigen (PSMA) overexpression detected by immunohistochemistry in a 61-year-old Caucasian man with an extracapsular stage III Gleason 7 tumor that recurred at 44 months and progressed to hormone-refractory metastatic disease (anti-PSMA with 7E11 antibody, immunoperoxidase with hematoxylin counterstain, ×200). *B,* relatively weaker PSMA immunostaining in a 64-year-old Caucasian man with a stage II organ-confined Gleason 6 prostate cancer tumor that has not recurred at 68 months of follow-up (anti-PSMA with 7E11 antibody, immunoperoxidase with hematoxylin counterstain, ×200).

Downloaded from http://aacrjournals.org/clincancerres/article-pdf/9/17/6357/2085645/zdf01703006357.pdf by guest on 27 July 2022

Fusion Pharmaceuticals, Inc.
Exhibit 1021.003

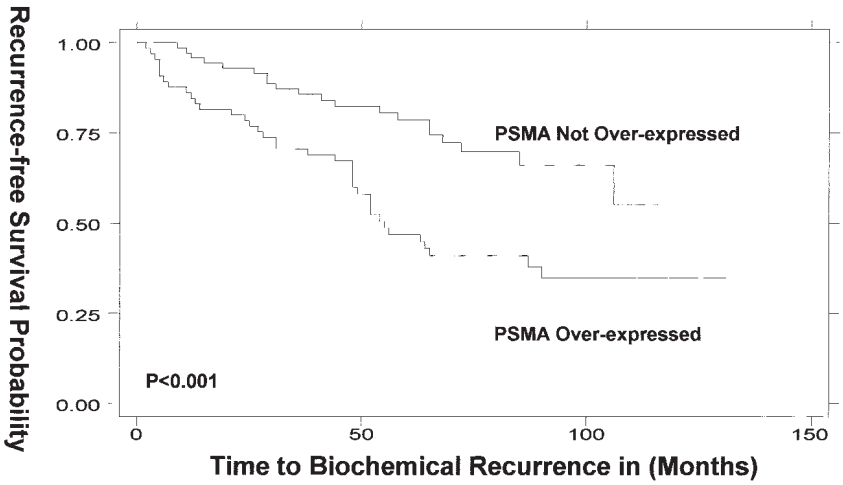

Fig. 2 Kaplan-Meier survival curves for prostate-specific membrane antigen (PSMA) expression in prostate cancer patients. Patients with tumors with high PSMA expression suffered a significantly increased rate of recurrent disease ($P = 0.001$) as compared with those whose tumors featured a relatively lower PSMA expression.

index for the PSMA-overexpressing tumors was 1.32 compared with a mean DNA index of 1.03 for the non-PSMA-overexpressing tumors ($P = 0.002$). PSMA expression status was also associated with advanced pathological stage with 33 of 65 (51%) pathological stage III or IV tumors overexpressing PSMA as compared with 23 of 71 (32%) of pathological stage I and II tumors overexpressing PSMA ($P = 0.029$). The mean serum PSA level of 18.28 ng/ml at the time of diagnosis for the PSMA-overexpressing tumors was significantly greater than the mean serum PSA level of 9.10 ng/ml for the non-PSMA-overexpressing group ($P = 0.006$).

Univariate and Multivariate Analysis for Disease Relapse. On univariate analysis, PSMA expression status correlated with biochemical disease recurrence ($P = 0.001$; Fig. 2). Tumor Gleason score ($P = 0.04$), aneuploid DNA content ($P = 0.04$), and pathological stage ($P = 0.03$) also predicted disease recurrence. On multivariate analysis, advanced tumor stage ($P = 0.018$) and PSMA overexpression ($P = 0.002$) were independent predictors of biochemical recurrence.

***In Situ* Hybridization.** *In situ* hybridization was performed on a limited number of frozen sections from normal prostate tissues, prostatic intraepithelial neoplasia, PCa tumors, and metastatic lesions (Fig. 3, *A–D*). PSMA mRNA was preferentially expressed in the epithelium of normal, benign, and malignant prostate tissues. The majority of the prostatic intraepithelial neoplasias and primary tumors examined demonstrated increased PSMA mRNA expression compared with sections of normal prostate and benign prostatic hypertrophic tissues. Strong PSMA mRNA expression was also found in most bone metastases and all lymph node and liver metastases. In the small subset of frozen sections from primary PCa tumors, increased PSMA mRNA expression tended to correlate with increased Gleason score (data not shown).

DISCUSSION

A wide variety of morphology-driven and molecular markers have been studied for their ability to predict disease outcome in PCa (22–25). Traditional morphology-driven measures have included tumor grade, volume, and pathological stage. Numerous molecular markers have been proposed for their potential clinical utility including the determination of p21, p27, cyclin D1, p53, bcl-2, E-cadherin, HER-2/neu, matrix metalloproteases, telomerase, and glutathione *S*-transferase π (22–27). However, expanded use of these markers for the individualization of therapy has been hampered by a lack of universal acceptance of their prognostic significance, problems concerning the specificity and sensitivity of the available testing platforms for each marker, limited available tissue, and the concern that the inherent heterogeneity of PCa could cause false negative results, especially for patients for whom a narrow-bore needle biopsy is the only sample available for testing (23).

PCa Gleason score has typically correlated with other markers of disease aggressiveness, including increased cell proliferation, aneuploid DNA content, oncogene activation, and tumor suppressor gene mutation (23–27). The Gleason score has been highly predictive of rapid PSA progression (24). In the present study, tumor grade was not an independent prognostic factor when PSMA expression status was known. Thus, although the Gleason score of prostatic adenocarcinoma is clearly one of the strongest predictors of biological behavior and metastatic potential, in most studies it is not capable of predicting disease outcome when used alone (26–28). Similarly, the majority of retrospective studies have shown that aneuploid DNA content in PCa independently predicts poor prognosis for the disease (29–31). Similar to the findings for the tumor Gleason score, in the present study DNA ploidy status did not independently predict biochemical disease relapse.

In the present study, the increased expression of PSMA determined by IHC on the primary prostatectomy specimens correlated significantly with higher preoperative serum PSA levels, high tumor grade, nondiploid DNA content, and advanced tumor stage, and increased expression also independently predicted biochemical disease relapse. PSMA protein overexpression in high-grade primary PCa tumors and metastatic lesions also correlated with increased PSMA mRNA expression levels using *in situ* hybridization and autoradiography. This appears to be the first attempt to link PSMA levels measured on primary prostatectomy specimens with PCa outcome,

Downloaded from http://aacrjournals.org/clincancerres/article-pdf/9/17/6357/2085645/zdf01703006357.pdf by guest on 27 July 2022

Fusion Pharmaceuticals, Inc.
Exhibit 1021.004

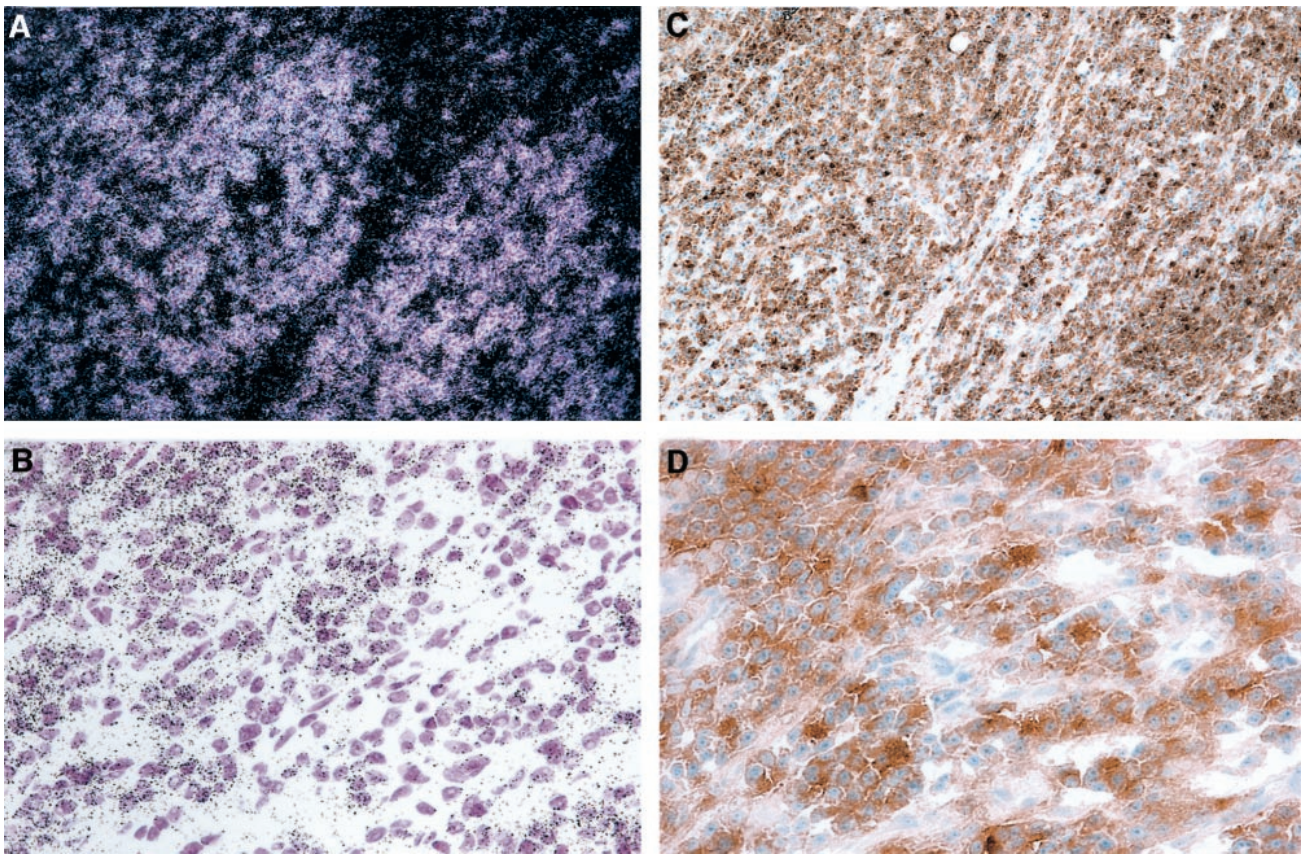

Fig. 3 *A,* dark-field image of one case of high-grade prostate cancer metastatic to regional lymph nodes showing abundant prostate-specific membrane antigen (PSMA) mRNA expression with radiolabeled probe detected by autoradiography on a 5-μm frozen tissue section (PSMA antisense probe with hematoxylin counterstain). *B,* bright-field image of another case of high-grade prostate cancer metastatic to regional lymph nodes showing abundant PSMA mRNA expression detected by radiolabeled *in situ* hybridization with autoradiography (PSMA antisense probe with hematoxylin counterstain). *C,* corresponding immunohistochemical localization of PSMA protein on a frozen tissue block from the same case illustrated in Fig. 1*A* (anti-PSMA with 7E11 antibody, immunoperoxidase with hematoxylin counterstain). *D,* similar corresponding PSMA protein overexpression from the same case illustrated in Fig. 3*B* demonstrated by immunohistochemistry (anti-PSMA with 7E11 antibody, immunoperoxidase with hematoxylin counterstain).

although increased PSMA expression has been associated with higher tumor grade (6) and metastatic disease (8, 9). In comparison with tumor grade, pathological stage, and DNA ploidy status, the prognostic significance of high PSMA levels in the primary tumor is magnified by the recent introduction of anti-PSMA-targeted therapy (11–14). In the present study, the 7E11 anti-PSMA antibody was used for paraffin-based IHC. This antibody was the first PSMA antibody developed and recognizes the internal domain of the PSMA molecule (32, 33). The classic IHC procedure on 4-μm paraffin sections renders the internal domain of PSMA available for antibody detection with the 7E11 clone and appears to reliably indicate the total cellular PSMA expression (6, 8, 9). The 7E11 antibody has also been used to develop a radioconjugate for diagnostic imaging (10–12, 34, 35). ^{111}In-capromab pendetide (ProstaScint) immunoscintigraphy has been used for the management of PCa but has been limited by the dependency of the 7E11 antibody on the exposure of the internal domain of PSMA, an exposure that, in contrast to thin tissue section-based IHC procedures, will not take place in whole tumor cells *in vivo* devoid of apoptosis or necrosis. Antibodies to the external domain of PSMA such as the J-591 antibody have been recently introduced for the treatment of hormone-refractory PCa and also show promise as imaging reagents (11–14).

In conclusion, this IHC-based study of PCa confirms that PSMA expression is higher in high-grade, non-organ-confined disease and, for the first time, that overexpression of PSMA protein in the primary tumor independently predicts disease outcome. Thus, additional studies designed to validate PSMA as a prognostic marker; learn the potential impact of tissue fixation, processing, staining, and heterogeneity of expression on the IHC results; and test the potential clinical utility of PSMA appear warranted.

REFERENCES

1. Israeli, R. S., Powell, C. T., Corr, J. G., Fair, W. R., and Heston, W. D. Expression of the prostate-specific membrane antigen. Cancer Res., *54:* 1807–1811, 1994.

2. Murphy, G. P., Greene, T. G., Tino, W. T., Boynton, A. L., and Holmes, E. H. Isolation and characterization of monoclonal antibodies

Downloaded from http://aacrjournals.org/clincancerres/article-pdf/9/17/6357/2085645/zdf01703006357.pdf by guest on 27 July 2022

Fusion Pharmaceuticals, Inc.
Exhibit 1021.005

specific for the extracellular domain of prostate specific membrane antigen. J. Urol., *160:* 2396–2401, 1998.

3. Tasch, J., Gong, M., Sadelain, M., and Heston, W. D. A unique folate hydrolase, prostate-specific membrane antigen (PSMA): a target for immunotherapy? Crit. Rev. Immunol., *21:* 249–261, 2001.

4. Silver, D. A., Pellicer, I., Fair, W. R., Heston, W. D., and Cordon-Cardo, C. Prostate-specific membrane antigen expression in normal and malignant human tissues. Clin. Cancer Res., *3:* 81–85, 1997.

5. Murphy, G. P., Elgamal, A. A., Su, S. L., Bostwick, D. G., and Holmes, E. H. Current evaluation of the tissue localization and diagnostic utility of prostate specific membrane antigen. Cancer (Phila.), *83:* 2259–2269, 1998.

6. Bostwick, D. G., Pacelli, A., Blute, M., Roche, P., and Murphy, G. P. Prostate specific membrane antigen expression in prostatic intraepithelial neoplasia and adenocarcinoma: a study of 184 cases. Cancer (Phila.), *82:* 2256–2261, 1998.

7. Lapidus, R. G., Tiffany, C. W., Isaacs, J. T., and Slusher, B. S. Prostate-specific membrane antigen (PSMA) enzyme activity is elevated in prostate cancer cells. Prostate, *45:* 350–354, 2000.

8. Sweat, S. D., Pacelli, A., Murphy, G. P., and Bostwick, D. G. Prostate-specific membrane antigen expression is greatest in prostate adenocarcinoma and lymph node metastases. Urology, *52:* 637–640, 1998.

9. Chang, S. S., Reuter, V. E., Heston, W. D., and Gaudin, P. B. Comparison of anti-prostate-specific membrane antigen antibodies and other immunomarkers in metastatic prostate carcinoma. Urology, *57:* 1179–1183, 2001.

10. Murphy, G. P., Maguire, R. T., Rogers, B., Partin, A. W., Nelp, W. B., Troychak, M. J., Ragde, H., Kenny, G. M., Barren, R. J., III, Bowes, V. A., Gregorakis, A. K., Holmes, E. H., and Boynton, A. L. Comparison of serum PSMA, PSA levels with results of Cytogen-356 ProstaScint scanning in prostatic cancer patients. Prostate, *33:* 281–285, 1997.

11. Yao, D., Trabulsi, E. J., Kostakoglu, L., Vallabhajosula, S., Joyce, M. A., Nanus, D. M., Milowsky, M., Liu, H., and Goldsmith, S. J. The utility of monoclonal antibodies in the imaging of prostate cancer. Semin. Urol. Oncol., *20:* 211–218, 2002.

12. Gong, M. C., Chang, S. S., Sadelain, M., Bander, N. H., and Heston, W. D. Prostate-specific membrane antigen (PSMA)-specific monoclonal antibodies in the treatment of prostate and other cancers. Cancer Metastasis Rev., *18:* 483–490, 1999.

13. Gong, M. C., Chang, S. S., Watt, F., O'Keefe, D. S., Bacich, D. J., Uchida, A., Bander, N. H., Reuter, V. E., Gaudin, P. B., Molloy, P. L., Sadelian, M., and Heston, W. D. Overview of evolving strategies incorporating prostate-specific membrane antigen as target for therapy. Mol. Urol., *4:* 217–222, 2000.

14. Holmes, E. H. PSMA specific antibodies and their diagnostic and therapeutic use. Expert Opin. Investig. Drugs, *10:* 511–519, 2001.

15. Wright, G. L., Jr., Grob, B. M., Haley, C., Grossman, K., Newhall, K., Petrylak, D., Troyer, J., Konchuba, A., Schellhammer, P. F., and Moriarty, R. Upregulation of prostate-specific membrane antigen after androgen-deprivation therapy. Urology, *48:* 326–334, 1996.

16. Liu, H., Moy, P., Kim, S., Xia, Y., Rajasekaran, A., Navarro, V., Knudsen, B., and Bander, N. H. Monoclonal antibodies to the extracellular domain of prostate-specific membrane antigen also react with tumor vascular endothelium. Cancer Res., *57:* 3629–3534, 1997.

17. Chang, S. S., O'Keefe, D. S., Bacich, D. J., Reuter, V. E., Heston, W. D., and Gaudin, P. B. Prostate-specific membrane antigen is produced in tumor-associated neovasculature. Clin. Cancer Res., *5:* 2674–2681, 1999.

18. Chang, S. S., Reuter, V. E., Heston, W. D., Bander, N. H., Grauer, L. S., and Gaudin, P. B. Five different anti-prostate-specific membrane antigen (PSMA) antibodies confirm PSMA expression in tumor-associated neovasculature. Cancer Res., *59:* 3192–3198, 1999.

19. Gleason, D. F. Histologic grading of prostate cancer: a perspective. Hum. Pathol., *23:* 273–279, 1992.

20. Ohori, M., Wheeler, T. M., and Scardino, P. T. The New American Joint Committee on Cancer and International Union Against Cancer TNM classification of prostate cancer. Clinicopathologic correlations. Cancer (Phila.), *74:* 104–114, 1994.

21. Ross, J. S., Sheehan, C. E., Ambros, R. A., Nazeer, T., Jennings, T. A., Kaufman, R. P., Jr., Fisher, H. A. G., Rifkin, M. D., and Kallakury, B. V. S. Needle biopsy DNA ploidy status predicts grade shifting in prostate cancer. Am. J. Surg. Pathol., *23:* 296–301, 1999.

22. Isaacs, J. T. Molecular markers for prostate cancer metastasis. Am. J. Pathol., *150:* 1511–1521, 1997.

23. Bostwick, D. G., Grignon, D. J., Hammond, M. E., Amin, M. B., Cohen, M., Crawford, D., Gospadarowicz, M., Kaplan, R. S., Miller, D. S., Montriona, R., Pajak, T. F., Pollack, A., Srigley, J. R., and Yarbro, J. W. Prognostic factors in prostate cancer. College of American Pathologists Consensus Statement 1999. Arch. Pathol. Lab. Med., *124:* 995–1000, 2000.

24. Koch, M. O., Foster, R. S., Bell, B., Beck, S., Cheng, L., Parekh, D., and Jung, S. H. Characterization and predictors of prostate specific antigen progression rates after radical retropubic prostatectomy. J. Urol., *164:* 749–753, 2000.

25. Alers, J. C., Rochat, J., Krijtenburg, P. J., Hop, W. C., Kranse, R., Rosenberg, C., Tanke, H. J., Schroder, F. H., and van Dekken, H. Identification of genetic markers for prostatic cancer progression. Lab. Investig., *80:* 931–942, 2000.

26. Ross, J. S., Sheehan, C. E., Fisher, H. A. G., Kauffman, R. A., Jr., Dolen, E. M., and Kallakury, B. V. S. Prognostic markers in prostate cancer. Expert Rev. Mol. Diagn., *2:* 129–142, 2002.

27. Stattin, P. Prognostic factors in prostate cancer. Scand. J. Urol. Nephrol. Suppl., *185:* 1–46, 1997.

28. Catalona, W. J., Ramos, C. G., and Carvalhal, G. F. Contemporary results of anatomic radical prostatectomy. CA Cancer J. Clin., *49:* 282–296, 1999.

29. Peters-Gee, J. M., Miles, B. J., Cerny, J. C., Gaba, A. R., Jacobsen, G., and Crissman, J. D. Prognostic significance of DNA quantification in stage D1 prostatic carcinoma with the use of image analysis. Cancer (Phila.), *70:* 1159–1165, 1992.

30. Montgomery, B. T., Nativ, O., Blute, M., Farrow, G. M., Myers, R. P., Zincke, H., Therneau, T. M., and Lieber, M. M. Stage B prostate adenocarcinoma. Flow cytometric nuclear DNA ploidy analysis. Arch. Surg., *125:* 327–331, 1990.

31. Ross, J. S., Figge, H., Bui, H. X., del Rosario, A. D., Jennings, T. A., Rifkin, M. D., and Fisher, H. A. G. Prediction of pathologic stage and post prostatectomy disease recurrence by DNA ploidy analysis of initial needle biopsy specimens of prostate cancer. Cancer (Phila.), *74:* 2811–2818, 1994.

32. Troyer, J. K., Beckett, M. L., and Wright, G. L., Jr. Location of prostate-specific membrane antigen in the LNCaP prostate carcinoma cell line. Prostate, *30:* 232–242, 1997.

33. Barren, R. J., III, Holmes, E. H., Boynton, A. L., Misrock, S. L., and Murphy, G. P. Monoclonal antibody 7E11.C5 staining of viable LNCaP cells. Prostate, *30:* 65–68, 1997.

34. Freeman, L. M., Krynyckyi, B. R., Li, Y., Korupulu, G., Saleemi, K., Haseman, M. K., and Kahn, D. The role of ^{111}In capromab pendetide (Prosta-Scint®) immunoscintigraphy in the management of prostate cancer. Q. J. Nucl. Med., *46:* 131–137, 2002.

35. Elgamal, A. A., Troychak, M. J., and Murphy, G. P. ProstaScint scan may enhance identification of prostate cancer recurrences after prostatectomy, radiation, or hormone therapy: analysis of 136 scans of 100 patients. Prostate, *37:* 261–269, 1998.

Downloaded from http://aacrjournals.org/clincancerres/article-pdf/9/17/6357/2085645/zdf01703006357.pdf by guest on 27 July 2022

Fusion Pharmaceuticals, Inc.
Exhibit 1021.006