The NEW ENGLAND JOURNAL of MEDICINE

ESTABLISHED IN 1812 OCTOBER 5, 2006 VOL. 355 NO. 14

Ranibizumab for Neovascular Age-Related Macular Degeneration

Philip J. Rosenfeld, M.D., Ph.D., David M. Brown, M.D., Jeffrey S. Heier, M.D., David S. Boyer, M.D., Peter K. Kaiser, M.D., Carol Y. Chung, Ph.D., and Robert Y. Kim, M.D., for the MARINA Study Group*

ABSTRACT

BACKGROUND

Ranibizumab — a recombinant, humanized, monoclonal antibody Fab that neutralizes all active forms of vascular endothelial growth factor A — has been evaluated for the treatment of neovascular age-related macular degeneration.

METHODS

In this multicenter, 2-year, double-blind, sham-controlled study, we randomly assigned patients with age-related macular degeneration with either minimally classic or occult (with no classic lesions) choroidal neovascularization to receive 24 monthly intravitreal injections of ranibizumab (either 0.3 mg or 0.5 mg) or sham injections. The primary end point was the proportion of patients losing fewer than 15 letters from baseline visual acuity at 12 months.

RESULTS

We enrolled 716 patients in the study. At 12 months, 94.5% of the group given 0.3 mg of ranibizumab and 94.6% of those given 0.5 mg lost fewer than 15 letters, as compared with 62.2% of patients receiving sham injections ($P<0.001$ for both comparisons). Visual acuity improved by 15 or more letters in 24.8% of the 0.3-mg group and 33.8% of the 0.5-mg group, as compared with 5.0% of the sham-injection group ($P<0.001$ for both doses). Mean increases in visual acuity were 6.5 letters in the 0.3-mg group and 7.2 letters in the 0.5-mg group, as compared with a decrease of 10.4 letters in the sham-injection group ($P<0.001$ for both comparisons). The benefit in visual acuity was maintained at 24 months. During 24 months, presumed endophthalmitis was identified in five patients (1.0%) and serious uveitis in six patients (1.3%) given ranibizumab.

CONCLUSIONS

Intravitreal administration of ranibizumab for 2 years prevented vision loss and improved mean visual acuity, with low rates of serious adverse events, in patients with minimally classic or occult (with no classic lesions) choroidal neovascularization secondary to age-related macular degeneration. (ClinicalTrials.gov number, NCT00056836.)

From the Bascom Palmer Eye Institute, University of Miami Miller School of Medicine, Miami (P.J.R.); Vitreoretinal Consultants, Methodist Hospital, Houston (D.M.B.); Ophthalmic Consultants of Boston, Boston (J.S.H.); Retina Vitreous Associates Medical Group, Los Angeles (D.S.B.); the Cole Eye Institute, Cleveland Clinic Foundation, Cleveland (P.K.K.); and Genentech, South San Francisco, CA (C.Y.C., R.Y.K.). Address reprint requests to Dr. Rosenfeld at the Bascom Palmer Eye Institute, Department of Ophthalmology, University of Miami Miller School of Medicine, 900 NW 17th St., Miami, FL 33136, or at prosenfeld@med.miami.edu.

*Principal investigators in the Minimally Classic/Occult Trial of the Anti-VEGF Antibody Ranibizumab in the Treatment of Neovascular Age-Related Macular Degeneration (MARINA) Study Group are listed in the Appendix.

N Engl J Med 2006;355:1419-31.
Copyright © 2006 Massachusetts Medical Society.

The New England Journal of Medicine
Downloaded from nejm.org on January 23, 2024. For personal use only. No other uses without permission.
Copyright © 2006 Massachusetts Medical Society. All rights reserved.

Samsung et al. v. Regeneron IPR2023-00884
Regeneron Pharmaceuticals, Inc. Exhibit 2083 Page 1

Age-related macular degeneration is a leading cause of irreversible blindness among people who are 50 years of age or older in the developed world.[1-3] The neovascular form of the disease usually causes severe vision loss and is characterized by the abnormal growth of new blood vessels under or within the macula, the central portion of the retina responsible for high-resolution vision.

Neovascularization in this disease is classified by fluorescein angiography into major angiographic patterns termed classic and occult, which may be associated with various degrees of aggressiveness of disease, vision loss, and response to various treatment options.[4] Pharmacologic therapies for neovascular disease that are available in the United States and Europe include verteporfin photodynamic therapy[5-8] — approved by the Food and Drug Administration only for predominantly classic lesions (in which 50% or more of the lesion consists of classic choroidal neovascularization) and by the European Agency for the Evaluation of Medicinal Products for both predominantly classic lesions and occult disease with no classic lesions — and pegaptanib sodium.[9] Both treatments can slow the progression of vision loss, but only a small percentage of treated patients show improvement in visual acuity.

The age-related changes that stimulate pathologic neovascularization are incompletely understood, but vascular endothelial growth factor A (VEGF-A) — a diffusible cytokine that promotes angiogenesis and vascular permeability — has been implicated as an important factor promoting neovascularization.[10-15] Multiple biologically active forms of VEGF-A are generated by alternative messenger RNA splicing and proteolytic cleavage,[16] and two isoforms have been detected in choroidal neovascular lesions.[15]

Ranibizumab — a recombinant, humanized monoclonal antibody Fab that neutralizes all active forms of VEGF-A — was recently approved by the Food and Drug Administration for the treatment of all angiographic subtypes of subfoveal neovascular age-related macular degeneration. In phase 1 and 2 clinical studies, ranibizumab demonstrated encouraging signs of biologic activity, with acceptable safety, when administered intravitreally for up to 6 months in patients with neovascular age-related macular degeneration.[17-19] In our phase 3 study, Minimally Classic/Occult Trial of the Anti-VEGF Antibody Ranibizumab in the Treatment of Neovascular Age-Related Macular Degeneration (MARINA), we evaluated ranibizumab for the treatment of minimally classic or occult with no classic choroidal neovascularization associated with age-related macular degeneration.

METHODS

STUDY DESIGN

At 96 sites in the United States, we enrolled 716 patients in our 2-year, prospective, randomized, double-blind, sham-controlled study of the safety and efficacy of repeated intravitreal injections of ranibizumab among patients with choroidal neovascularization associated with age-related macular degeneration. We performed a prespecified primary efficacy analysis at 12 months. The primary efficacy end point was the proportion of patients who had lost fewer than 15 letters (approximately 3 lines) from baseline visual acuity, as assessed with the Early Treatment Diabetic Retinopathy Study (ETDRS) chart, with the use of standardized refraction and testing protocol at a starting test distance of 2 m. We obtained approval from the institutional review board at each study site before the enrollment of patients; all study sites complied with the requirements of the Health Insurance Portability and Accountability Act. The eligibility of lesions was confirmed by an independent central reading center with the use of standardized criteria and trained graders who were unaware of patients' treatment assignments. Patients provided written informed consent before determination of their full eligibility. Screening lasted as long as 28 days.

To be included in the study, patients had to be at least 50 years old; have a best corrected visual acuity of 20/40 to 20/320 (Snellen equivalent determined with the use of an ETDRS chart); have primary or recurrent choroidal neovascularization associated with age-related macular degeneration, involving the foveal center; have a type of lesion that had been assessed with the use of fluorescein angiography and fundus photography as minimally classic or occult with no classic choroidal neovascularization; have a maximum lesion size of 12 optic-disk areas (1 optic-disk area equals 2.54 mm^2 on the basis of 1 optic-disk diameter of 1.8 mm), with neovascularization composing 50% or more of the entire lesion; and have presumed recent progression of disease, as evidenced by observable blood, recent vision loss, or a recent increase in a lesion's greatest linear

The New England Journal of Medicine
Downloaded from nejm.org on January 23, 2024. For personal use only. No other uses without permission.
Copyright © 2006 Massachusetts Medical Society. All rights reserved.

Samsung et al. v. Regeneron IPR2023-00884
Regeneron Pharmaceuticals, Inc. Exhibit 2083 Page 2

diameter of 10% or more. (For a complete list of eligibility criteria, see Table 1 of the Supplementary Appendix, available with the full text of this article at www.nejm.org.) There were no exclusion criteria regarding preexisting cardiovascular, cerebrovascular, or peripheral vascular conditions.

STUDY TREATMENT

We randomly assigned eligible patients in a 1:1:1 ratio to receive ranibizumab (Lucentis, Genentech) at a dose of either 0.3 mg or 0.5 mg or a sham injection monthly (within 23 to 37 days) for 2 years (24 injections) in one eye. The evaluating physician was unaware of the patient's treatment assignment; the physician who administered the injection was aware of the patient's treatment assignment regarding ranibizumab or sham treatment but was unaware of the dose of ranibizumab. Other personnel at each study site (except for those assisting with injections), patients, and personnel at the central reading center were unaware of the patient's treatment assignment.

Verteporfin photodynamic therapy was allowed if the choroidal neovascularization in the study eye became predominantly classic. On the basis of a policy decision by the Centers for Medicare and Medicaid Services to reimburse photodynamic therapy for small, minimally classic, and occult lesions as of April 1, 2004, the study protocol was amended to allow photodynamic therapy for minimally classic or occult disease with no classic lesions that were no larger than 4 optic-disk areas and were accompanied by a loss of 20 letters or more from baseline visual acuity, as confirmed at consecutive study visits. (A score of 55 letters is approximately equal to a Snellen equivalent of 20/80 vision.)

The study was designed and analyzed by a committee composed of both academic investigators and representatives of the industry sponsor. In the analysis of the data and the writing of the manuscript, Dr. Rosenfeld had full and unrestricted access to the data, and all the coauthors contributed to the interpretation of the data and the final version of the manuscript. All the authors vouch for the accuracy and completeness of the reported data.

STATISTICAL ANALYSIS

We performed efficacy analyses on an intention-to-treat basis among all patients with the use of a last-observation-carried-forward method for missing data. For all pairwise comparisons, the statistical model adjusted for baseline score for visual acuity (<55 letters vs. ≥55 letters) and subtype of choroidal neovascularization (minimally classic vs. occult with no classic disease). Between-group comparisons for dichotomous end points were performed with the use of the Cochran chi-square test.[20] Change from baseline visual acuity was analyzed with the use of analysis-of-variance models. For end points for lesion characteristics, analysis-of-covariance models adjusting for the baseline value were used. The Hochberg–Bonferroni multiple-comparison procedure[21] was used to adjust for the two pairwise treatment comparisons for the primary end point. Safety analyses included all treated patients.

We determined the number of patients in each group on the basis of a 1:1:1 randomization ratio, Pearson's chi-square test for the two pairwise comparisons of the primary end point, and the Hochberg–Bonferroni multiple comparison procedure at an overall type I error of 0.0497 (adjusting for the three planned safety interim analyses before the primary efficacy analysis). Monte Carlo simulations were used to evaluate the power of the study. We estimated that the enrollment of 720 patients would provide the study with a statistical power of 95% to detect a significant difference between one or both ranibizumab groups and the sham-injection group in the proportion of patients losing fewer than 15 letters at 12 months, assuming a proportion of 65% in each ranibizumab group and 50% in the sham-injection group. (For more details, see the Methods section of the Supplementary Appendix.)

RESULTS

STUDY PATIENTS

Between March 2003 and December 2003, 716 patients were enrolled and randomly assigned to study treatment. Groups were balanced for demographic and baseline ocular characteristics (Table 1).

More than 90% of patients in each treatment group remained in the study at 12 months, and approximately 80 to 90% remained at 24 months (Table 2 of the Supplementary Appendix). The percentages who were still receiving study treatment were similarly high at 12 months and at the end of the study. After the unmasking of first-year results and discussion with the data and safety monitoring committee, ranibizumab was

The New England Journal of Medicine
Downloaded from nejm.org on January 23, 2024. For personal use only. No other uses without permission.
Copyright © 2006 Massachusetts Medical Society. All rights reserved.

Samsung et al. v. Regeneron IPR2023-00884
Regeneron Pharmaceuticals, Inc. Exhibit 2083 Page 3

Table 1. Baseline Characteristics of the Patients.*

Characteristic	Sham Injection (N=238)	0.3 mg of Ranibizumab (N=238)	0.5 mg of Ranibizumab (N=240)
Sex — no. (%)			
Male	79 (33.2)	85 (35.7)	88 (36.7)
Female	159 (66.8)	153 (64.3)	152 (63.3)
Race — no. (%)†			
White	231 (97.1)	229 (96.2)	232 (96.7)
Other	7 (2.9)	9 (3.8)	8 (3.3)
Age — yr			
Mean	77±7	77±8	77±8
Range	56–94	52–95	52–93
Age group — no. (%)			
50–64 yr	11 (4.6)	13 (5.5)	16 (6.7)
65–74 yr	67 (28.2)	64 (26.9)	64 (26.7)
75–84 yr	132 (55.5)	130 (54.6)	124 (51.7)
≥85 yr	28 (11.8)	31 (13.0)	36 (15.0)
Previous therapy for age-related macular degeneration — no. (%)			
Any treatment	135 (56.7)	140 (58.8)	139 (57.9)
Laser photocoagulation	22 (9.2)	13 (5.5)	14 (5.8)
Medication‡	3 (1.3)	1 (0.4)	3 (1.2)
Nutritional supplements	121 (50.8)	134 (56.3)	127 (52.9)
Other	8 (3.4)	3 (1.3)	3 (1.2)
No. of letters as measure of visual acuity§			
Mean	53.6±14.1	53.1±12.9	53.7±12.8
<55 — no. (%)	109 (45.8)	115 (48.3)	117 (48.8)
≥55 — no. (%)	129 (54.2)	123 (51.7)	123 (51.2)

offered to all patients in October 2005, 2 months before the end of the last patient's final study visit at 24 months. Of the patients in the sham-injection group, 12 were switched to receive 0.5 mg of ranibizumab: 5 patients (2.1%) at 22 months and 7 (2.9%) at 23 months, the last possible injection visit. During the 2-year treatment period, 38 patients in the sham-injection group (16.0%), 2 patients in the group receiving 0.3 mg of ranibizumab (0.8%), and none in the group receiving 0.5 mg of ranibizumab received verteporfin photodynamic therapy at least once. In the second year, 13 patients (5.5%) in the sham-injection group and none in the ranibizumab groups chose to discontinue study treatment and receive pegaptanib sodium, which was approved in the United States in December 2004 for the treatment of neovascular age-related macular degeneration. Of these 13 patients, 8 remained in the follow-up group at 24 months.

PRIMARY AND SECONDARY END POINTS

The primary and key secondary efficacy results at 12 months (prespecified primary analysis) and 24 months are summarized in Figures 1 and 2. The study met its primary end point (Fig. 1A) at 12 months. Of the patients who were treated with ranibizumab, 94.5% of the patients receiving 0.3 mg and 94.6% of those receiving 0.5 mg had lost fewer than 15 letters from baseline visual acuity, as compared with 62.2% in the sham-injection group (P<0.001 for the comparison of each dose with the sham-injection group). At 24 months, this end point was met by 92.0% of the patients receiving 0.3 mg of ranibizumab and 90.0% of those receiving 0.5 mg, as compared with 52.9%

The New England Journal of Medicine
Downloaded from nejm.org on January 23, 2024. For personal use only. No other uses without permission.
Copyright © 2006 Massachusetts Medical Society. All rights reserved.

Samsung et al. v. Regeneron IPR2023-00884
Regeneron Pharmaceuticals, Inc. Exhibit 2083 Page 4

Table 1. (Continued.)

Characteristic	Sham Injection (N=238)	0.3 mg of Ranibizumab (N=238)	0.5 mg of Ranibizumab (N=240)
Visual acuity (approximate Snellen equivalent) — no. (%)§			
20/200 or worse	32 (13.4)	35 (14.7)	31 (12.9)
Better than 20/200 but worse than 20/40	170 (71.4)	176 (73.9)	173 (72.1)
20/40 or better	36 (15.1)	27 (11.3)	36 (15.0)
Type of choroidal neovascularization — no. (%)			
Occult with no classic lesion	151 (63.4)	151 (63.4)	149 (62.1)
Minimally classic lesion	87 (36.6)	86 (36.1)	91 (37.9)
Predominantly classic lesion	0	1 (0.4)	0
Missing data	1 (0.4)	0	0
Size of lesion — optic-disk area¶			
Mean	4.4±2.5	4.3±2.5	4.5±2.6
Range	0.0–11.8	0.1–11.8	0.3–12.0
Size of choroidal neovascularization — optic-disk area¶			
Mean	4.3±2.4	4.1±2.5	4.3±2.5
Range	0.0–11.8	0.0–11.8	0.1–12.0
Size of leakage from choroidal neovascularization plus staining of retinal pigment epithelium — optic-disk area¶			
Mean	3.5±2.5	3.6±2.5	3.5±2.6
Range	0.0–12.9	0.0–12.0	0.0–13.5

* Plus–minus values are means ±SD. Percentages may not total 100 because of rounding.
† Race was determined by the investigators.
‡ Medications included triamcinolone acetonide, prednisolone ophthalmic, and diclofenac sodium.
§ Visual acuity was measured with the use of ETDRS charts at a starting distance of 2 m. A score of 55 letters is approximately equal to a Snellen equivalent of 20/80.
¶ One optic-disk area is equal to 2.54 mm^2 on the basis of one optic-disk diameter of 1.8 mm.

in the sham-injection group (P<0.001 for each comparison). The visual-acuity benefit associated with ranibizumab was independent of the size of the baseline lesion, the lesion type, or baseline visual acuity (Fig. 1B and 1C).

At 12 and 24 months, approximately one quarter of patients treated with 0.3 mg of ranibizumab and one third of patients treated with 0.5 mg of ranibizumab had gained 15 or more letters in visual acuity, as compared with 5.0% or less of those in the sham-injection group (P<0.001 for each comparison) (Fig. 1D).

At both doses of ranibizumab, the mean improvement from baseline in visual-acuity scores was evident 7 days after the first injection (P=0.006 for the 0.3-mg dose and P=0.003 for the 0.5-mg dose), whereas mean visual acuity in the sham-injection group declined steadily over time at each monthly assessment (P<0.001 for both comparisons) (Fig. 2A). At 12 months, mean increases in visual acuity were 6.5 letters in the 0.3-mg group and 7.2 letters in the 0.5-mg group, as compared with a decrease of 10.4 letters in the sham-injection group (P<0.001 for both comparisons). The benefit in visual acuity was maintained at 24 months. The average benefit associated with ranibizumab over that of sham injection was approximately 17 letters in each dose group at 12 months and 20 to 21 letters at 24 months.

At baseline, the percentages of patients with 20/40 vision or better were similar among the three groups (Fig. 2B). At 12 months, approximately 40% of patients receiving ranibizumab had 20/40 vision or better, as compared with 11.3% in the sham-injection group (P<0.001). At 24 months, of the patients receiving ranibizumab, 34.5% of

The New England Journal of Medicine
Downloaded from nejm.org on January 23, 2024. For personal use only. No other uses without permission.
Copyright © 2006 Massachusetts Medical Society. All rights reserved.

Samsung et al. v. Regeneron IPR2023-00884
Regeneron Pharmaceuticals, Inc. Exhibit 2083 Page 5

those in the 0.3-mg group and 42.1% in the 0.5-mg group had at least 20/40 vision, whereas the proportion in the sham-injection group had dropped to 5.9% (P<0.001 for each comparison).

A single patient in the sham-injection group had 20/20 or better vision at baseline. Among patients receiving ranibizumab, 3.8% in the 0.3-mg group and 7.9% in the 0.5-mg group had 20/20 vision or better at 12 months, and 6.7% in the 0.3-mg group and 7.9% in the 0.5-mg group had 20/20 vision or better at 24 months. In the sham-injection group, only two patients (0.8%) had 20/20 vision or better at 12 months (P<0.001 for the comparison with the 0.5-mg group and P=0.03 for the comparison with the 0.3-mg group), and one (0.4%) had 20/20 vision or better at 24 months (P<0.001 for the comparison with each ranibizumab group).

The percentages of patients with visual acuity of 20/200 or worse were similar among the three groups at baseline (Fig. 2C). At 12 and 24 months, the percentages in the ranibizumab-treated groups remained about the same, whereas the percentages in the sham-injection group had increased by 3 to 3.5 times (P<0.001 for the comparison with each ranibizumab dose at 12 and 24 months). Very few patients receiving ranibizumab had severe vision loss (30 letters or more) from baseline (0.8% of the 0.3-mg group and 1.2% of the 0.5-mg group), as compared with 14.3% of the sham-injection group at 12 months; at 24 months, 3.4% of the 0.3-mg group and 2.5% of the 0.5-mg group had severe vision loss, as compared with 22.7% of the sham-injection group (P<0.001 for the comparison with each dose at 12 and 24 months).

Ranibizumab treatment was associated with arrested growth of and leakage from choroidal neovascularization (including intense, progressive staining of the retinal pigment epithelium) (Fig. 3A through Fig. 3D). The mean change from baseline in each of the ranibizumab-treated groups differed significantly from that in the sham-injection group at 12 and 24 months (P<0.001 for each comparison).

Figure 1 (facing page). Rate of Loss or Gain of Visual Acuity at 12 and 24 Months Associated with Ranibizumab, as Compared with Sham Injection.

Panel A shows the percentage of patients in each group who lost fewer than 15 letters from baseline visual acuity at 12 months (the primary efficacy end point) and at 24 months. Panels B and C summarize the percentage of patients who lost fewer than 15 letters at 12 and 24 months, respectively, according to lesion size (1 optic-disk area is equal to 2.54 mm^2 on the basis of 1 optic-disk diameter of 1.8 mm), baseline visual acuity (a score of 55 letters is approximately equal to a Snellen equivalent of 20/80), and lesion type. Panel D shows the percentage of patients who gained 15 or more letters from baseline at 12 and 24 months. For the study overall, treatment comparisons were based on the Cochran chi-square test stratified according to the visual-acuity score at day 0 (<55 letters vs. ≥55 letters) and choroidal neovascularization subtype. Pearson's chi-square test was used for treatment comparisons in each subgroup. The last-observation-carried-forward method was used to handle missing data. All tests were two-sided (P<0.001 for all comparisons between each ranibizumab group and the sham-injection group). I bars represent 95% confidence intervals.

ADVERSE EVENTS

Cumulative adverse events for the 24-month study period are summarized in Table 2. Each of the key serious ocular adverse events occurred in different patients (Table 3 of the Supplementary Appendix). Investigator-reported cases of endophthalmitis, as well as any case of serious uveitis treated with intravitreal antibiotics, were presumed to be endophthalmitis. The presumed endophthalmitis rate was 5 of 477 patients (1.0%) or, alternatively, a rate per injection of 0.05% (5 of 10,443 total injections). In four of the five presumed cases of endophthalmitis, neither vitreous nor aqueous culture showed growth.

Slit-lamp examination revealed inflammation (of any cause, including endophthalmitis) throughout the study in the ranibizumab groups (Table 2, and Table 4 and 5 of the Supplementary Appendix).[22,23] Most of the inflammation in all groups was designated as trace or 1+.

Ranibizumab had no long-term effect on intraocular pressure, on average, as assessed by monthly preinjection measurements during the 2-year follow-up. Intraocular pressure was increased on average 1 hour after ranibizumab injections at protocol-mandated intraocular-pressure assessments; however, the absence of corresponding changes in preinjection measurements suggests the postinjection increases were transient. On average, postinjection intraocular pressure increased from the preinjection value by 1.9 to 3.5 mm Hg in the 0.3-mg group and 2.1 to 3.4 mm Hg

The New England Journal of Medicine
Downloaded from nejm.org on January 23, 2024. For personal use only. No other uses without permission.
Copyright © 2006 Massachusetts Medical Society. All rights reserved.

Samsung et al. v. Regeneron IPR2023-00884
Regeneron Pharmaceuticals, Inc. Exhibit 2083 Page 6

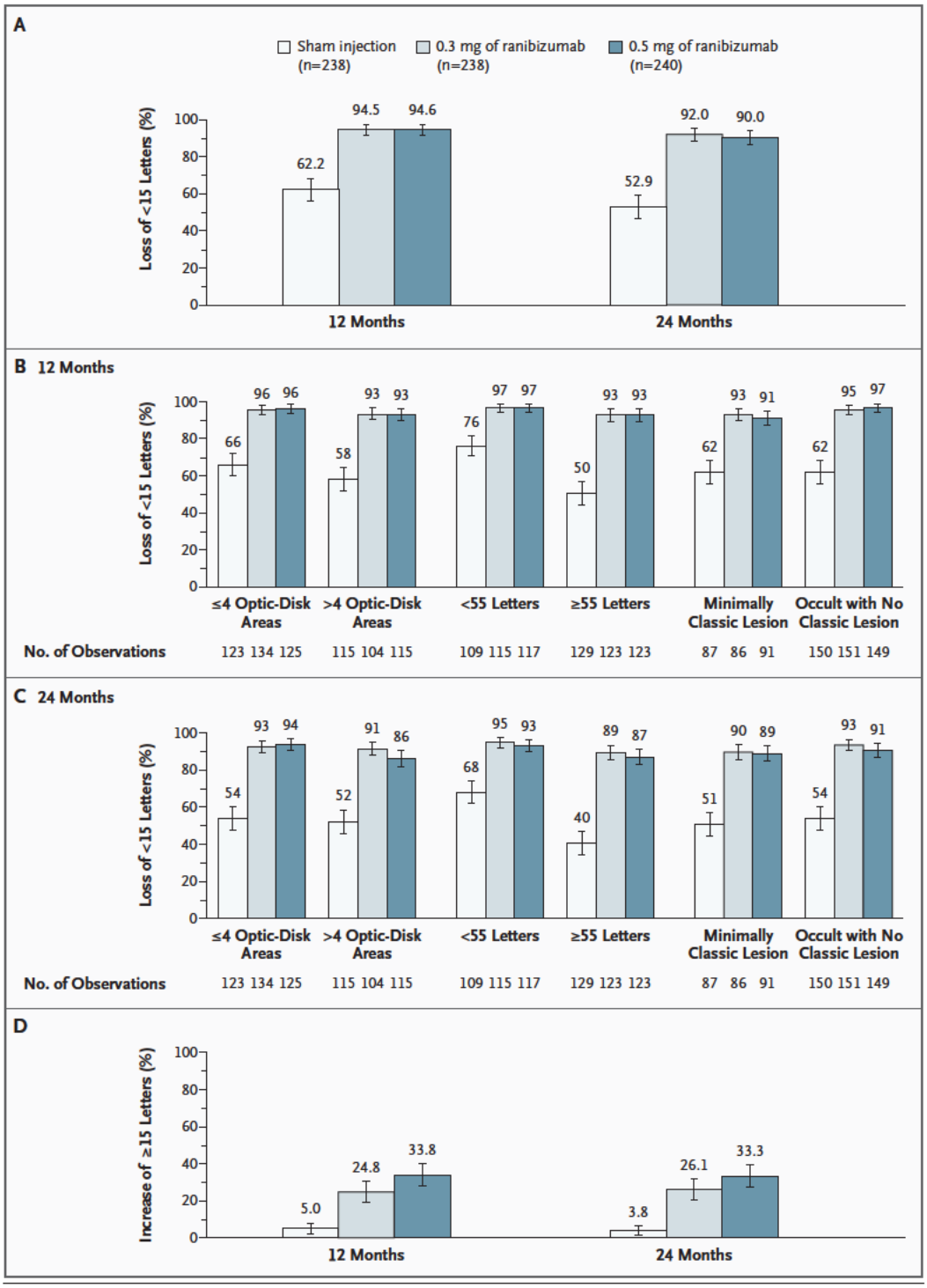

The New England Journal of Medicine
Downloaded from nejm.org on January 23, 2024. For personal use only. No other uses without permission.
Copyright © 2006 Massachusetts Medical Society. All rights reserved.

Samsung et al. v. Regeneron IPR2023-00884
Regeneron Pharmaceuticals, Inc. Exhibit 2083 Page 7

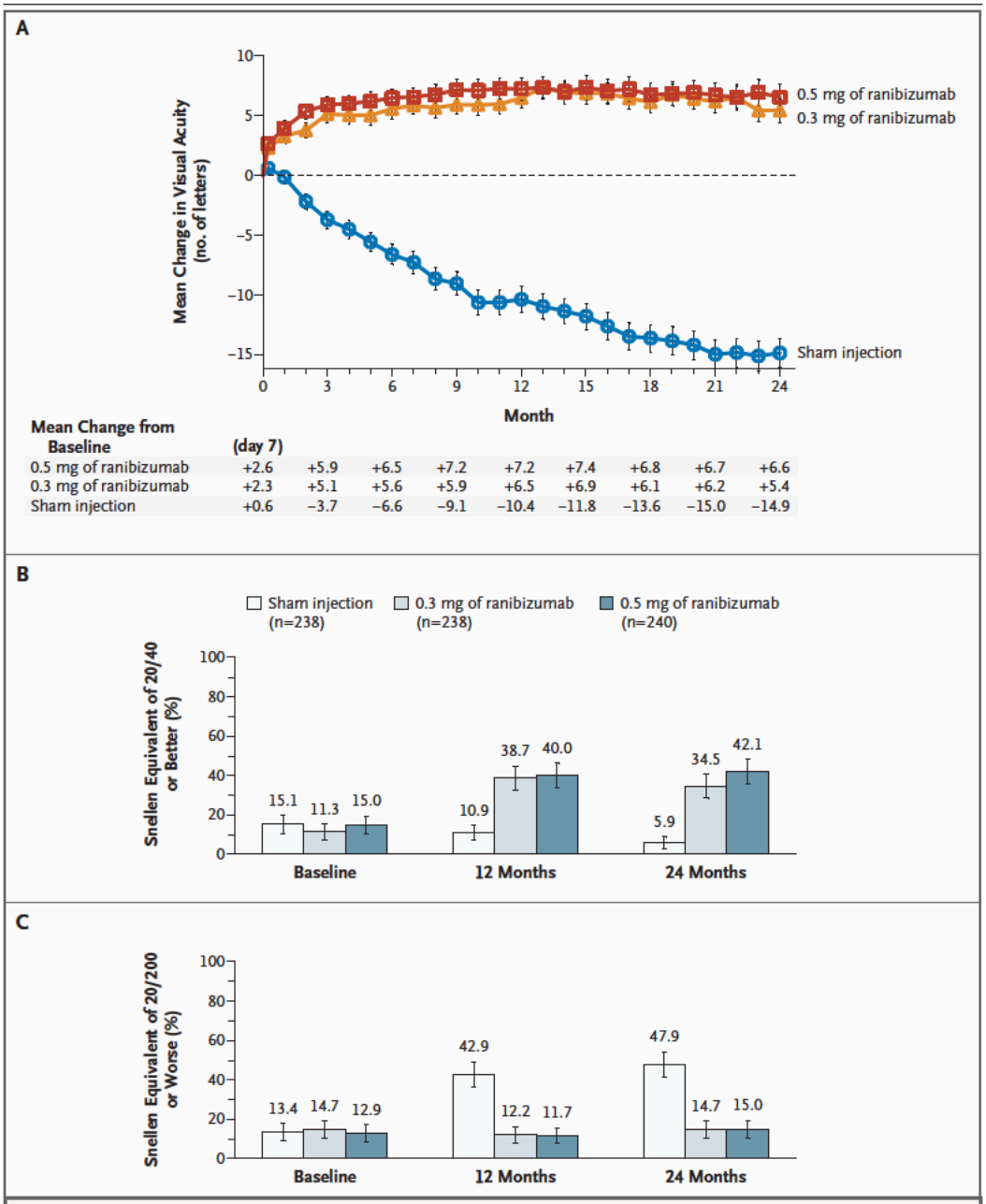

Mean Change from Baseline	(day 7)								
0.5 mg of ranibizumab	+2.6	+5.9	+6.5	+7.2	+7.2	+7.4	+6.8	+6.7	+6.6
0.3 mg of ranibizumab	+2.3	+5.1	+5.6	+5.9	+6.5	+6.9	+6.1	+6.2	+5.4
Sham injection	+0.6	−3.7	−6.6	−9.1	−10.4	−11.8	−13.6	−15.0	−14.9

Figure 2. Mean Changes from Baseline in Visual Acuity and Snellen Equivalents at 12 and 24 Months.

Panel A shows the mean changes from baseline in visual acuity during a 24-month period. At each monthly assessment, P<0.001 for the comparison between each ranibizumab group and the sham-injection group. On day 7, P=0.006 for patients receiving 0.3 mg of ranibizumab and P=0.003 for those receiving 0.5 mg. Panels B and C show the change from baseline in the percentage of patients with a Snellen equivalent of 20/40 or better and the percentage of patients with 20/200 or worse, respectively, at 12 and 24 months (P<0.001 for the comparison between each ranibizumab group and the sham-injection group at 12 and 24 months). Treatment comparisons use pairwise models adjusted for visual-acuity scores at day 0 (<55 letters vs. ≥55 letters) and for the type of choroidal neovascularization. Analysis of variance was used to assess the change in visual acuity from baseline at each monthly assessment. The Cochran chi-square test was used for the comparison of percentages. The last-observation-carried-forward method was used to handle missing data. All statistical tests were two-sided. I bars represent SE in Panel A and 95% confidence intervals in Panels B and C.

The New England Journal of Medicine
Downloaded from nejm.org on January 23, 2024. For personal use only. No other uses without permission.
Copyright © 2006 Massachusetts Medical Society. All rights reserved.

Samsung et al. v. Regeneron IPR2023-00884
Regeneron Pharmaceuticals, Inc. Exhibit 2083 Page 8

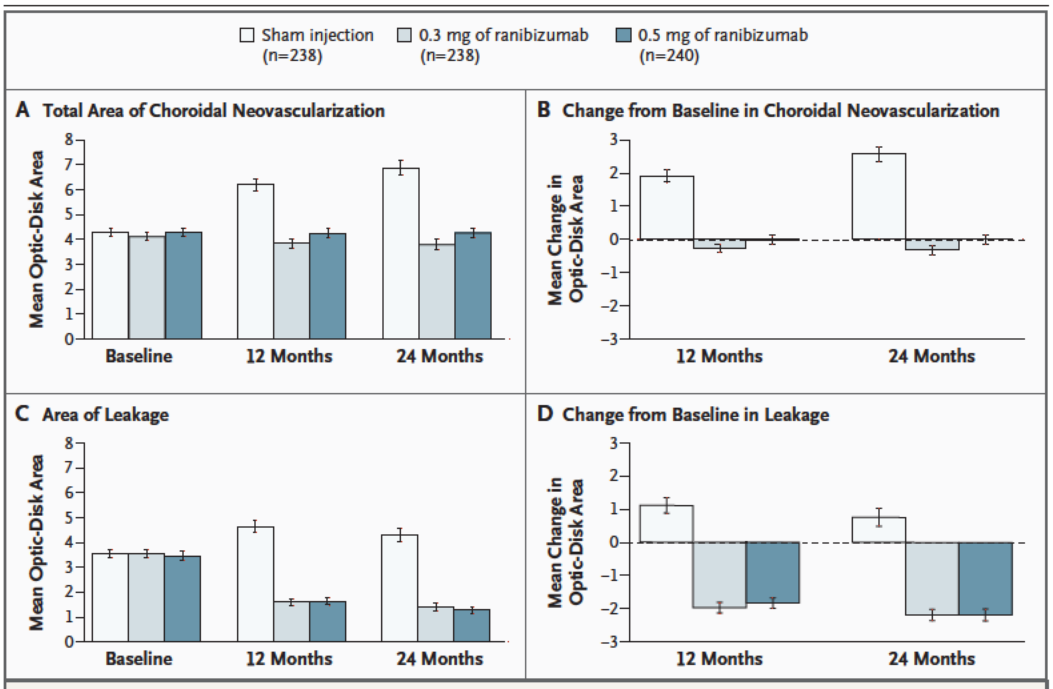

Figure 3. Mean (±SE) Changes in Choroidal Neovascularization and Leakage.

Leakage refers to that associated with choroidal neovascularization plus intense, progressive staining of the retinal pigment epithelium. One optic-disk area is equal to 2.54 mm². Pairwise analysis of covariance was adjusted for the visual-acuity score at day 0 (<55 letters vs. ≥55 letters), the subtype of choroidal neovascularization, and the baseline value of the end point. Missing data were imputed according to the last-observation-carried-forward approach. P<0.001 for the comparison between each ranibizumab group and the sham-injection group at 12 and 24 months. All statistical tests were two-sided.

in the 0.5-mg group, as compared with 0.8 to 1.5 mm Hg in the sham-injection group. Postinjection intraocular pressure of 30 mm Hg or more occurred in approximately 13.0% of patients in the 0.3-mg group and 17.6% of those in the 0.5-mg group, as compared with 3.4% of those in the sham-injection group. Intraocular pressure of 40 mm Hg or more occurred in 2.3% of patients in each ranibizumab group and in no patients in the sham-injection group. A postinjection intraocular pressure of 50 mm Hg or more occurred in 0.6% of each ranibizumab group.

Ranibizumab was not associated with an increased frequency of cataracts (15.7% of patients in the sham-injection group, as compared with 15.5% in each ranibizumab group). However, lens status did change in a few patients during the 2-year treatment period. Of patients whose study eye was phakic at baseline and whose lens status was known at 24 months, the study eye of 6 of 117 patients in the 0.3-mg group (5.1%) and 8 of 111 patients in the 0.5-mg group (7.2%) had become pseudophakic by 24 months, as compared with no patients in the sham-injection group. At 24 months, ranibizumab-treated patients whose study eye had been phakic and then became pseudophakic during the course of the study had visual acuity similar to that of ranibizumab-treated patients overall.

Seventeen deaths occurred during the 2-year study. In the sham-injection group, six patients (2.5%) died: two from strokes, one from congestive heart failure, one from renal failure, one from acute respiratory failure, and one of an unknown cause. In the group receiving 0.3 mg of ranibizumab, five patients (2.1%) died: two from myocardial infarction, one from complications of non-Hodgkin's lymphoma, one from pneumonia, and one from an unknown cause. In the group receiving 0.5 mg of ranibizumab, six patients (2.5%) died: two from stroke, one from a small-bowel infarct, one from traumatic injury from an automobile accident, one from sepsis, and one from chronic asthma and chronic obstructive pulmonary disease. An additional three patients who had completed the study or had withdrawn from

The New England Journal of Medicine
Downloaded from nejm.org on January 23, 2024. For personal use only. No other uses without permission.
Copyright © 2006 Massachusetts Medical Society. All rights reserved.

Samsung et al. v. Regeneron IPR2023-00884
Regeneron Pharmaceuticals, Inc. Exhibit 2083 Page 9

Table 2. Adverse Events at 24 Months.*

Adverse Event	Sham Injection (N=236)	0.3 mg of Ranibizumab (N=238)	0.5 mg of Ranibizumab (N=239)
Serious ocular event — no. (%)			
Presumed endophthalmitis†	0	2 (0.8)	3 (1.3)
Culture not obtained	0	1 (0.4)	0
Culture negative	0	1 (0.4)	3 (1.3)‡
Uveitis	0	3 (1.3)	3 (1.3)§
Rhegmatogenous retinal detachment	1 (0.4)	0	0
Retinal tear	0	1 (0.4)	1 (0.4)
Vitreous hemorrhage	2 (0.8)	1 (0.4)	1 (0.4)
Lens damage	0	0	1 (0.4)
Most severe ocular inflammation — no. (%)¶			
None	206 (87.3)	198 (83.2)	189 (79.1)
Trace	24 (10.2)	19 (8.0)	35 (14.6)
1+	6 (2.5)	14 (5.9)	8 (3.3)
2+	0	2 (0.8)	2 (0.8)
3+	0	2 (0.8)	2 (0.8)
4+	0	3 (1.3)	3 (1.3)
Nonocular adverse event			
Investigator-defined hypertension			
No. of patients (%)	38 (16.1)	41 (17.2)	39 (16.3)
Mean decrease in blood pressure from baseline — mm Hg	3.3/3.5	2.6/2.5	4.4/1.1
Key arterial thromboembolic events (nonfatal) — no. (%)			
Myocardial infarction	4 (1.7)	6 (2.5)§	3 (1.3)‖
Stroke	2 (0.8)**††	3 (1.3)‡‡	6 (2.5)‖§§
Death — no. (%)			
Vascular cause (APTC criteria)	4 (1.7)¶¶	3 (1.3)‡‡‖‖	3 (1.3)***
Nonvascular cause	2 (0.8)	2 (0.8)	3 (1.3)
Nonocular hemorrhage — no. (%)			
Total serious and nonserious events	13 (5.5)	22 (9.2)	21 (8.8)
Reported as a serious adverse event	2 (0.8)	3 (1.3)	5 (2.1)

* APTC denotes Antiplatelet Trialists' Collaboration.
† Events were categorized as presumed endophthalmitis in cases in which intravitreal antibiotics were administered.
‡ One event was reported as uveitis by an investigator.
§ One patient had two episodes.
¶ Ocular inflammation (regardless of cause) was determined on the basis of slit-lamp examination.
‖ One patient had a myocardial infarction and a hemorrhagic stroke, both nonfatal.
** One patient in the sham-injection group received a single 0.5-mg dose of ranibizumab in error approximately 8 months before the onset of the stroke.
†† One patient had a second episode of stroke, which resulted in death.
‡‡ One patient had a nonfatal ischemic stroke and died of an unknown cause.
§§ One patient had a cerebral ischemic incident that was categorized as an ischemic stroke.
¶¶ Two patients died from stroke, one from congestive heart failure, and one from an unknown cause.
‖‖ Two patients died from myocardial infarction, and one from an unknown cause.
*** One patient died from a small-bowel infarct, and two from stroke.

The New England Journal of Medicine
Downloaded from nejm.org on January 23, 2024. For personal use only. No other uses without permission.
Copyright © 2006 Massachusetts Medical Society. All rights reserved.

Samsung et al. v. Regeneron IPR2023-00884
Regeneron Pharmaceuticals, Inc. Exhibit 2083 Page 10

the study before 24 months died: one patient in the sham-injection group from cardiac arrest 15 days after completing the study, one in the group receiving 0.3 mg of ranibizumab from lung cancer 174 days after completing the last study visit at 22 months, and one in the group receiving 0.5 mg of ranibizumab from lung cancer 91 days after completing the last study visit at 23 months.

The overall incidence of any serious or nonserious nonocular (systemic) adverse event, including adverse events previously associated with systemically administered anti-VEGF therapy, such as arterial thromboembolic events and hypertension (Table 2), was similar among the groups. At 24 months, on the basis of the classification system of the Antiplatelet Trialists' Collaboration (APTC),[24] which includes nonfatal myocardial infarction, nonfatal stroke, and death from a vascular or unknown cause, the rate of arterial thromboembolic events among patients in the sham-injection group was 3.8%, the rate among patients receiving 0.3 mg of ranibizumab was 4.6%, and the rate among patients receiving 0.5 mg of ranibizumab was 4.6%; none of the differences were significant. The onset of these events and the time of study treatment appeared to be unrelated. No adverse events of proteinuria were reported. Nonocular hemorrhages occurred at similar rates in the first treatment year in the three groups (3.8% in both the sham-injection group and the 0.3-mg group and 2.1% in the 0.5-mg group).

Cumulative rates of nonocular hemorrhage increased in all groups through the second treatment year, but more so in the ranibizumab groups (Table 2). By 24 months, nonocular hemorrhage had occurred in 5.5% of patients in the sham-injection group, as compared with 9.2% of those receiving 0.3 mg of ranibizumab and 8.8% of those receiving 0.5 mg of ranibizumab; none of the differences were significant. (For cumulative rates of specific types of nonocular hemorrhage, see Table 6 of the Supplementary Appendix.) Since the study was not powered to detect small differences in rates, no conclusion can be drawn regarding whether these differences were drug-related or due to chance alone. Among the 12 patients in the sham-injection group who switched to ranibizumab therapy, no serious adverse events were reported after the switch.

Patients in all three groups were tested for circulating antibodies against ranibizumab at baseline and at months 6, 12, and 24. A small percentage of patients in all three groups tested positive before study treatment, possibly owing to preexisting anti-Fab immunoreactivity. At baseline, immunoreactivity rates were 0.9% in the group receiving 0.3 mg of ranibizumab, 0% in the group receiving 0.5 mg of ranibizumab, and 0.5% in the sham-injection group. During the first treatment year, immunoreactivity rates increased similarly in all treatment groups. However, by the end of the second year, 4.4% of patients in the 0.3-mg group and 6.3% of those in the 0.5-mg group tested positive, as compared with only 1.1% in the sham-injection group. Exploratory subgroup analyses of safety and efficacy outcomes revealed no clinically relevant differences between patients with and those without immunoreactivity to ranibizumab.

DISCUSSION

Our phase 3 study (MARINA) of a treatment for neovascular age-related macular degeneration demonstrated not only prevention of vision loss but also a mean improvement in vision in the prespecified primary analysis at 1 year. The efficacy outcomes for patients receiving ranibizumab at 1 year were maintained through the second year, whereas vision in patients in the sham-injection group continued to decline.

Most of the serious ocular adverse events were attributable either to the injection procedure or to ranibizumab. Presumed endophthalmitis was attributed to the injection and serious uveitis to ranibizumab. Although endophthalmitis could not be definitively distinguished from sterile serious uveitis in patients whose inflammation was treated with intravitreal antibiotics but whose vitreous cultures were negative, the rates of these events were on the order of 1 to 2% during the 2-year treatment period.

The three treatment groups did not clearly differ in their rates of nonocular adverse events. The reported nonserious and serious nonocular adverse events reflect common medical conditions in an elderly population. In regard to potential systemic anti-VEGF side effects, the rates of hypertension were not imbalanced, and no adverse events associated with proteinuria were reported. Nonocular hemorrhages were more frequent in the ranibizumab groups than in the sham-injection group. During the 2-year treatment period, the rates of arterial thromboembolic events

The New England Journal of Medicine
Downloaded from nejm.org on January 23, 2024. For personal use only. No other uses without permission.
Copyright © 2006 Massachusetts Medical Society. All rights reserved.

Samsung et al. v. Regeneron IPR2023-00884
Regeneron Pharmaceuticals, Inc. Exhibit 2083 Page 11

(on the basis of APTC criteria) were similar in the three treatment groups. However, our study was not powered to detect small differences between groups in the rates of uncommon adverse events. Additional ongoing clinical trials may provide further information on the rates of key nonocular adverse events. For example, elsewhere in this issue of the *Journal*, Brown et al. report data from the first year of the phase 3 Anti-VEGF Antibody for the Treatment of Predominantly Classic Choroidal Neovascularization in Age-Related Macular Degeneration (ANCHOR) study,[25] which compares verteporfin photodynamic therapy with ranibizumab treatment at the same doses used in our study. The results of the ANCHOR study are consistent with those of the first year of our study for both safety and efficacy outcomes in the ranibizumab-treated groups.

The clinical significance of the increased rate of systemic immunoreactivity with ranibizumab treatment, which was not present at 1 year but emerged at 2 years, is unclear. Exploratory analyses failed to reveal any effect of immunoreactivity on efficacy or safety.

In conclusion, ranibizumab therapy was associated with clinically and statistically significant benefits with respect to visual acuity and angiographic lesions during 2 years of follow-up in patients with minimally classic or occult lesions with no classic choroidal neovascularization. These efficacy outcomes were achieved with a low rate of serious ocular adverse events and with no clear difference from the sham-treated group in the rate of nonocular adverse events.

Supported by Genentech and Novartis Pharma.

Dr. Rosenfeld reports having received consulting fees from Genentech, Eyetech, Novartis Ophthalmics, Protein Design Labs, Allergan, BioAxone, Tanox, Genaera, Jerini, Quark, and Athenagen; lecture fees from Genentech, Eyetech, and Novartis Ophthalmics; and grant support from Genentech, Eyetech, and Alcon Laboratories. Dr. Brown reports having received consulting fees from Genentech, Eyetech, Alcon Laboratories, and Allergan; having an equity interest in Pfizer; and having received lecture fees from Eyetech and Pfizer. Dr. Heier reports having received consulting fees from Genentech, Eyetech, Jerini, Oxigene, Allergan, Genzyme, iScience, ISTA, Pfizer, Regeneron, Theragenics, VisionCare, and Novartis lecture fees from Genentech, Eyetech, Jerini and Allergan; and grant support from Genentech, Eyetech, Pfizer, Theragenics, and Genaera. Dr. Boyer reports having received consulting fees from Genentech, Eyetech, Pfizer, Novartis, QLT, and Regeneron. Dr. Kaiser reports having received consulting fees, lecture fees, and grant support from Genentech and Novartis. Dr. Chung and Dr. Kim report being employees of Genentech and report owning Genentech stock. No other potential conflict of interest relevant to this article was reported.

We are indebted to the patients who participated in this study, their families, and the research teams at each site; to the members of the data and safety monitoring committee: Frederick L. Ferris III, M.D. (chair), Susan B. Bressler, M.D., Stuart L. Fine, M.D., and Marian Fisher, Ph.D.; to the members of the University of Wisconsin Fundus Photograph Reading Center; to the members of the data-coordinating center (Statistics Collaborative); and to Genentech personnel Charles Semba, M.D. and Steven Butler, Ph.D., for their critical comments and review throughout the design, conduct, and analysis of the study; to Susan Schneider, M.D., Nisha Acharya, M.D., and Angele Singh, M.D., for their critical comments and review of the second-year results; and to staff members for their assistance in the preparation of the manuscript.

APPENDIX

The following principal investigators were members of the MARINA Study Group: T. Aaberg, Associated Retinal Consultants, Grand Rapids, MI; P. Abraham, Black Hills Regional Eye Institute, Rapid City, SD; D. Alfaro III, Retina Consultants of Charleston, Charleston, SC; A. Antoszyk, Southeast Clinical Research Associates, Charlotte, NC; C. Awh, Retina Vitreous Associates, Nashville; G. Barile, Edward Harkness Eye Institute, New York; C. Barr, Louisville, KY; W. Bauman, Brooke Army Medical Center, Fort Sam Houston, TX; P. Beer, Lions Eye Institute, Albany, NY; B. Berger, Austin, TX; A. Bhavsar, Retina Center, Minneapolis; R. Bhisitkul, University of California at San Francisco, School of Medicine, San Francisco; H. Boldt, University of Iowa Hospital and Clinics, Iowa City; D. Boyer, Retina–Vitreous Associates, Beverly Hills, CA; W. Bridges, Western Carolina Retinal Associates, Asheville, NC; R. Brod, Lancaster, PA; D. Brown, Vitreoretinal Consultants, Houston; J. Bryan, Associated Retinal Consultants, Phoenix, AZ; R. Chambers, Retinal Consultants, Columbus, OH; T. Ciulla, Midwest Eye Institute, Indianapolis; T. Connor, Medical College of Wisconsin, Milwaukee; S. Cousins, Bascom Palmer Eye Institute, Palm Beach Gardens, FL; R. Dreyer, Northwest Retina, Portland, OR; W. Dunn, Florida Retina Institute, Daytona Beach, FL; D. Eliott, Kresge Eye Institute, Detroit; P. Ferrone, Long Island Vitreoretinal Consultants, Great Neck, NY; B. Foster, New England Retina Consultants, West Springfield, MA; W. Freeman, University of California at San Diego, Jacobs Retina Center, La Jolla; W. Fung, Pacific Eye Associates, San Francisco; R. Gentile, New York Eye and Ear Infirmary, New York; B. Glaser, National Retina Institute, Chevy Chase, MD, and Towson, MD; D. Glaser, Retina Associates of St. Louis, Florissant, MO; L. Glazer, Vitreo-Retinal Associates, Grand Rapids, MI; V. Gonzalez, Valley Retina Institute, McAllen, TX; R. Goodart, Rocky Mountain Retina Consultants, Salt Lake City; J. Haller, Johns Hopkins University, Baltimore; M. Hammer, Retina Associates of Florida, Tampa; J. Heier, Ophthalmic Consultants of Boston, Boston; B. Hubbard, Emory University, Atlanta; H. Hudson, Retina Centers, Tucson, AZ; D. Ie, Delaware Valley Retina Associates, Lawrenceville, NJ; M. Johnson, University of Michigan, Ann Arbor; R. Johnson, West Coast Retina Medical Group, San Francisco; D. Joseph, Barnes Retina Institute, St. Louis; P. Kaiser, Cleveland Clinic Foundation, Cole Eye Institute, Cleveland; R. Kaiser, Retina Diagnostic and Treatment Associates, Philadelphia; R. Katz, K. Kelly, Palm Beach Eye Foundation, Lake Worth, FL; R. Kingsley, Dean A. McGee Eye Institute, Oklahoma City; G. Kokame, Retina Consultants of Hawaii, Aiea, HI; B. Kuppermann, University of California at Irvine, Irvine; S. Leff, Retina-Vitreous Center, Lakewood, NJ, and New Brunswick, NJ; C. Leong, Bay Area Retina Associates, Walnut Creek, CA; L. Lobes, Retina Vitreous Consultants, Pittsburgh; M. Lomeo, Midwest Retina, Columbus, OH; C. MacDonald, University of Texas Health Science Center, San Antonio; D. Marcus, Southeast Retina Center, Augusta, GA; L. Marouf, Retina Associates of South Texas, San Antonio; R. Martidis, Retina Diagnostic and Treatment Associates, Philadelphia; J. Martinez, Austin

The New England Journal of Medicine
Downloaded from nejm.org on January 23, 2024. For personal use only. No other uses without permission.
Copyright © 2006 Massachusetts Medical Society. All rights reserved.

Samsung et al. v. Regeneron IPR2023-00884
Regeneron Pharmaceuticals, Inc. Exhibit 2083 Page 12

Retina Associates, Austin, TX; D. Maxwell, Jr., Retinal Associates of Oklahoma, Oklahoma City; C. McCannel, Mayo Clinic, Rochester, MN; T. McMillan, Southeastern Retina Associates, Knoxville, TN; L. Morse, University of California at Davis Medical Center, Sacramento; T. Oei, Braverman-Terry-Oei Eye Associates, San Antonio, TX; R. Park, University of Arizona, Tucson; M. Paul, Danbury Eye Physicians and Surgeons, Danbury, CT; P. Pavan, University of South Florida, Tampa; D. Pieramici, California Retina Consultants, Santa Barbara, CA; J. Prensky, Pennsylvania Retina Specialists, Camp Hill, PA; D. Quillen, Penn State Hershey Medical Center, Hershey; E. Reichel, New England Eye Center, Boston; W. Rodden, Retina and Vitreous Center of Southern Oregon, Ashland; P. Rosenfeld, Bascom Palmer Eye Institute, Miami; J. Rubio, Retina Associates of South Texas, San Antonio; P. Runge, Ophthalmic Consultants, Sarasota, FL; S. Sadda, Doheny Eye Institute, Los Angeles; G. Sanborn, Virginia Eye Institute, Richmond; R. Sanders, Retina Group of Washington, Chevy Chase, MD; S. Sanislo, California Vitreoretinal Research Center, Menlo Park, CA; S. Schwartz, Bascom Palmer Eye Institute, Palm Beach Gardens, FL; M. Singer, Medical Center Ophthalmology Associates, San Antonio, TX; L. Snady-McCoy, Rhode Island Eye Institute, Providence; S. Sneed, Retinal Consultants of Arizona, Phoenix; J. Stallman, Georgia Retina, Decatur, GA; W. Stern, Northern California Retina–Vitreous Associates, San Mateo and Mountain View; G. Stoller, Ophthalmic Consultants of Long Island, Rockville Centre, NY; B. Taney, Retina Vitreous Consultants, Ft. Lauderdale, FL; J. Thompson, Retina Specialists, Towson, MD; D. Tom, New England Retina Associates, Hamden, CT; M. Trese, Associated Retinal Consultants, Royal Oak, MI; T. Verstaeten, Allegheny General Hospital, Pittsburgh; C. Vu, Retina Associates, Annapolis, MD; J. Walker, Retina Consultants of Southwest Florida, Fort Myers; H. Weiss, Retina Consultants of Michigan, Southfield; J. Weiss, Retina Associates of South Florida, Margate; C. Wells, Vitreoretinal Associates, Seattle; H. Woodcome, Ophthalmology Consultants, Providence, RI; M. Zarbin, New Jersey Medical School, Newark; and K. Zhang, John Moran Eye Center, University of Utah, Salt Lake City.

REFERENCES

1. Bressler NM. Age-related macular degeneration is the leading cause of blindness. JAMA 2004;291:1900-1.

2. Friedman DS, O'Colmain BJ, Munoz B, et al. Prevalence of age-related macular degeneration in the United States. Arch Ophthalmol 2004;122:564-72.

3. Resnikoff S, Pascolini D, Etya'ale D, et al. Global data on visual impairment in the year 2002. Bull World Health Organ 2004;82:844-51.

4. Barbazetto I, Burdan A, Bressler NM, et al. Photodynamic therapy of subfoveal choroidal neovascularization with verteporfin: fluorescein angiographic guidelines for evaluation and treatment — TAP and VIP report No. 2. Arch Ophthalmol 2003;121:1253-68.

5. Photodynamic therapy of subfoveal choroidal neovascularization in age-related macular degeneration with verteporfin: one-year results of 2 randomized clinical trials — TAP report. Arch Ophthalmol 1999;117:1329-45. [Erratum, Arch Ophthalmol 2000;118:488.]

6. Bressler NM. Photodynamic therapy of subfoveal choroidal neovascularization in age-related macular degeneration with verteporfin: two-year results of 2 randomized clinical trials — TAP report 2. Arch Ophthalmol 2001;119:198-207.

7. Verteporfin in Photodynamic Therapy Study Group. Verteporfin therapy of subfoveal choroidal neovascularization in age-related macular degeneration: two-year results of a randomized clinical trial including lesions with occult with no classic choroidal neovascularization — Verteporfin In Photodynamic Therapy (VIP) report 2. Am J Ophthalmol 2001; 131:541-60.

8. Guidelines for using verteporfin (Visudyne) in photodynamic therapy for choroidal neovascularization due to age-related macular degeneration and other causes: update. Retina 2005;25:119-34.

9. Gragoudas ES, Adamis AP, Cunningham ET Jr, Feinsod M, Guyer DR. Pegaptanib for neovascular age-related macular degeneration. N Engl J Med 2004;351:2805-16.

10. Lopez PF, Sippy BD, Lambert HM, Thach AB, Hinton DR. Transdifferentiated retinal pigment epithelial cells are immunoreactive for vascular endothelial growth factor in surgically excised age-related macular degeneration-related choroidal neovascular membranes. Invest Ophthalmol Vis Sci 1996;37:855-68.

11. Frank RN, Amin RH, Eliott D, Puklin JE, Abrams GW. Basic fibroblast growth factor and vascular endothelial growth factor are present in epiretinal and choroidal neovascular membranes. Am J Ophthalmol 1996;122:393-403.

12. Kvanta A, Algvere PV, Berglin L, Seregard S. Subfoveal fibrovascular membranes in age-related macular degeneration express vascular endothelial growth factor. Invest Ophthalmol Vis Sci 1996;37:1929-34.

13. Kliffen M, Sharma HS, Mooy CM, Kerkvliet S, de Jong PT. Increased expression of angiogenic growth factors in age-related maculopathy. Br J Ophthalmol 1997;81:154-62.

14. Otani A, Takagi H, Oh H, et al. Vascular endothelial growth factor family and receptor expression in human choroidal neovascular membranes. Microvasc Res 2002;64:162-9.

15. Rakic JM, Lambert V, Devy L, et al. Placental growth factor, a member of the VEGF family, contributes to the development of choroidal neovascularization. Invest Ophthalmol Vis Sci 2003;44:3186-93.

16. Ferrara N. Vascular endothelial growth factor: basic science and clinical progress. Endocr Rev 2004;25:581-611.

17. Rosenfeld PJ, Schwartz SD, Blumenkranz MS, et al. Maximum tolerated dose of a humanized anti-vascular endothelial growth factor antibody fragment for treating neovascular age-related macular degeneration. Ophthalmology 2005;112: 1048-53.

18. Heier JS, Antoszyk AN, Pavan PR, et al. Ranibizumab for treatment of neovascular age-related macular degeneration: a phase I/II multicenter, controlled, multidose study. Ophthalmology 2006;113:633-42.

19. Rosenfeld PJ, Heier JS, Hantsbarger G, Shams N. Tolerability and efficacy of multiple escalating doses of ranibizumab (Lucentis) for neovascular age-related macular degeneration. Ophthalmology 2006;113: 623-32.

20. Cochran WG. Some methods for strengthening the common chi-square tests. Biometrics 1954;10:417-51.

21. Hochberg Y. A sharper Bonferroni procedure for multiple tests of significance. Biometrika 1988;75:800-2.

22. Hogan MJ, Kimura SJ, Thygeson P. Signs and symptoms of uveitis. I. Anterior uveitis. Am J Ophthalmol 1959;47:155-70.

23. Grading of vitreous cells. In: Nussenblatt RB, Whitcup SM, Palestine AG. Uveitis: fundamentals and clinical practice. 2nd ed. New York: Mosby, 1996:64.

24. Collaborative overview of randomised trials of antiplatelet therapy — I: Prevention of death, myocardial infarction, and stroke by prolonged antiplatelet therapy in various categories of patients. BMJ 1994; 308:81-106. [Erratum, BMJ 1994;308:1540.]

25. Brown DM, Kaiser PK, Michels M, et al. Ranibizumab versus verteporfin for neovascular age-related macular degeneration. N Engl J Med 2006;355:1432-44.

Copyright © 2006 Massachusetts Medical Society.

The New England Journal of Medicine
Downloaded from nejm.org on January 23, 2024. For personal use only. No other uses without permission.
Copyright © 2006 Massachusetts Medical Society. All rights reserved.

Samsung et al. v. Regeneron IPR2023-00884
Regeneron Pharmaceuticals, Inc. Exhibit 2083 Page 13