MACULAR HEMORRHAGE IN NEOVASCULAR AGE-RELATED MACULAR DEGENERATION AFTER STABILIZATION WITH ANTIANGIOGENIC THERAPY

JONATHAN P. LEVINE, MD,* INNA MARCUS, MD,†
JOHN A. SORENSON, MD,‡§ RICHARD F. SPAIDE, MD,‡§
MICHAEL J. COONEY, MD, MBA,‡§ K. BAILEY FREUND, MD‡§

Purpose: To study patients with neovascular age-related macular degeneration (AMD) who experienced a macular hemorrhage after stabilization with intravitreal antivascular endothelial growth factor (anti-VEGF) agents to improve current treatment regimens and prevent disease progression.

Methods: Retrospective chart review of six patients. The main outcome measures included time between last intravitreal anti-VEGF treatment and date of hemorrhage, time between last office visit and date of hemorrhage, and visual acuity before and after hemorrhage.

Results: Three of 6 eyes had a macular hemorrhage within 4 weeks of a stable examination. One eye had optical coherence tomography (OCT) that demonstrated no fluid 1 day before the macular hemorrhage. The average time between the date of the last injection and macular hemorrhage was 16.8 weeks (range, 7.3–28.9 weeks). The average time between the last stable examination and an event was 4.2 weeks (range, 1 day to 7.3 weeks). Three of six patients had a persistent decline in vision after the hemorrhage. Among the 4 patients, who had better than 20/200 vision before the macular hemorrhage, 2 dropped to 20/200 or worse.

Conclusion: Sight-threatening macular hemorrhages from AMD can occur within days to weeks after a stable examination and absence of fluid on OCT. Regimens that treat "as needed" based on clinical findings and OCT may not be appropriate for certain patients.

RETINA 29:1074–1079, 2009

Bevacizumab and ranibizumab have been welcomed as breakthrough antiangiogenic therapies for the treatment of neovascular AMD.[1–6] The phase IIIb studies of ranibizumab demonstrated the efficacy of monthly intravitreal injections in improving visual outcomes in eyes with neovascular AMD for up to 2 years. More recently, the PrONTO trial, a small nonrandomized study, suggested that a variable dosing regimen, using OCT as a guide for retreatment, could also achieve good visual results with the advantage of fewer treatments than a monthly dosing regimen.[7] Despite the efficacy of existing regimens, sight-threatening recurrences of macular exudation remain a concern for the treating physician. Furthermore, although OCT has become the standard of care for monitoring patients receiving anti-VEGF therapy, it remains unproven whether OCT will reliably detect evidence of recurrent neovascular activity before a visually significant macular hemorrhage.

We present a case series of six eyes with neovascular AMD stabilized after intravitreal bevacizumab or ranibizumab treatment that subsequently developed a sight-threatening macular hemorrhage.

Methods

We reviewed the records of six patients with a history of neovascular AMD at one clinical center

From the *Albert Einstein College of Medicine, Bronx, New York; †New York University School of Medicine; ‡Vitreous-Retina-Macula Consultants of New York; and §The LuEsther T. Mertz Retinal Research Center, Manhattan Eye, Ear, and Throat Hospital, New York, New York.

Supported in part by The LuEsther T. Mertz Retinal Research Center of the Manhattan Eye, Ear, & Throat Hospital and The Macula Foundation, Inc.

Reprint requests: K. Bailey Freund, MD, Vitreous-Retina-Macula Consultants of New York, 460 Park Avenue, 5th Floor, New York, NY 10022; e-mail: vrmny@aol.com

Copyright © by Ophthalmic Communications Society, Inc. Unauthorized reproduction of this article is prohibited.

Samsung et al. v. Regeneron IPR2023-00884
Regeneron Pharmaceuticals, Inc. Exhibit 2085 Page 1

who were initially stabilized with intravitreal bevacizumab or ranibizumab therapy and who subsequently developed a new sight-threatening macular hemorrhage between February 2006 and July 2007. All lesion types were included in this analysis, including those with significant areas of subretinal fibrosis. All patients initially received monthly injections of an anti-VEGF agent until stable. Stability was defined as complete resolution of both intraretinal and subretinal fluid detected on OCT and resolution of all macular hemorrhage when present. Persistent serous pigment epithelial detachment was not an exclusionary criterion. After stabilization, patients either received less frequent maintenance injections ("treat and extend") or were observed for signs of recurrent neovascular activity at the discretion of the treating physician.

We defined a "sight-threatening" macular hemorrhage as a subretinal hemorrhage of any size within 200 μm of the foveal center or a subretinal hemorrhage of at least 2 disk areas within the temporal vascular arcades. All eyes had not shown any signs of choroidal neovascularization activity such as macular hemorrhage or fluid on OCT on the most recent examination and OCT before the occurrence of macular hemorrhage. Information regarding the patient's clinical history and type and dates of treatment were recorded along with clinical details surrounding the hemorrhage. The interval between the last treatment and a macular hemorrhage as well as the interval between the last stable examination and a macular hemorrhage were recorded. Visual acuity was recorded for the last visit before an event and at the most recent visit on follow-up.

Results

Four of 6 patients had baseline vision of 20/200 or better, whereas 2 had vision worse than 20/400 (Table 1). Five eyes were treated with an OCT-guided regimen, whereas one was treated with a "treat and extend" strategy. The average number of injections before the macular hemorrhage was 3.5 (range, 2–6). The average time between the date of the last injection and the macular hemorrhage was 16.8 weeks (range, 7.3–28.9 weeks). The average time between the last stable examination and the macular hemorrhage was 4.2 weeks (range, 1 day to 7.3 weeks). Three of 6 eyes had a macular hemorrhage within 4 weeks of a stable examination. One eye had an OCT showing no fluid on the day before a hemorrhage occurred. Among the 4 patients who had better than 20/200 vision, 2 dropped to 20/200 or worse.

Table 1. Macular Hemorrhage in Neovascular Age-Related Macular Degeneration After Stabilization With Antiangiogenic Therapy

Case No.	Age	Gender	Study Eye	Anticoagulant	No. Injections Before SRH	Examination Findings Before SRH	OCT Findings Before SRH	VA Before SRH	Hemorrhage Size/Location	Weeks Between Last Examination and SRH	Weeks Between Last Injection and SRH	VA at Last Follow-Up
1	87	F	OS	Warfarin	2	Disciform scar with excentric lipid	No SRF or CME	5/400	>12 DA, subfoveal	2.9	11.0	LP
2	88	F	OS	—	6	Atrophic CNV	No SRF or CME	20/60	6 DA, subfoveal	0.1	17.3	3/400
3	75	M	OS	Aspirin	3	Quiescent CNV	No SRF or CME	20/50	1 DA <200 μm from foveal center	3.7	10.0	20/40
4	59	M	OS	—	3	Quiescent CNV	No SRF or CME	20/100	>12 DA, subfoveal	6.3	28.9	20/200
5*	95	F	OS	Aspirin, Warfarin	3	Quiescent CNV, no fluid or blood	No SRF or CME, small extrafoveal PED	20/50	2.5 DA, extrafoveal	7.3	7.3	20/60
6	76	M	OD	Clopidogrel	4	Disciform scar, no hemorrhage	No SRF or CME	10/400	3.4 DA within arcades	5.0	26.0	20/400

*Treat and extend regimen.
SRH, subretinal hemorrhage; VA, visual acuity; F, female; M, male; OS, left eye; OD, right eye; CNV, choroidal neovascularization; SRF, subretinal fluid; CME, cystoid macular edema; PED, pigment epithelial detachment; DA, disk areas.

Copyright © by Ophthalmic Communications Society, Inc. Unauthorized reproduction of this article is prohibited.

Samsung et al. v. Regeneron IPR2023-00884
Regeneron Pharmaceuticals, Inc. Exhibit 2085 Page 2

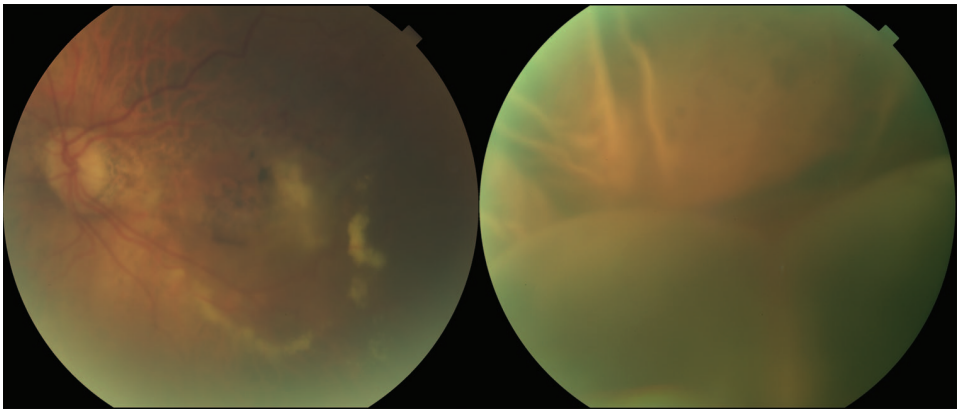

Fig. 1. Case 1. Left, Color photograph of patient 1 showing a quiescent fibrovascular scar secondary to neovascular AMD. Right, Photograph of the same eye 2 weeks later showing a bullous retinal detachment secondary to a massive subretinal hemorrhage.

Case 1

Patient 1 was an 87-year-old woman with a history of advanced neovascular AMD in the left eye for 5 years and a longstanding disciform scar in the right eye. The patient had bilateral 2+ nuclear sclerotic cataracts. She was using latanoprost once daily in the right eye for glaucoma. The patient's medical history included hypertension. She was on warfarin for carotid stenosis. The patient began intravitreal ranibizumab (0.5 mg/0.05 mL) therapy in her left eye for chronic subretinal fluid and a recent small subretinal hemorrhage in the macula. She received a total of two injections. Five weeks after the second injection, visual acuity was stable at 5/400 in the left eye. She was noted to have a quiescent fibrotic choroidal neovascular membrane with no clinically apparent hemorrhage and no fluid detected on OCT (Figure 1, left). Twenty days later, the patient returned with pain and tearing in the left eye for 3 days. On presentation, the patient's visual acuity was light perception in the left eye. Intraocular pressures were 19 in the right eye and 58 in the left eye. Gonioscopy showed a closed angle for 360° in the left eye. Funduscopic examination showed a massive subretinal hemorrhage in the left eye (Figure 1, right). The patient was placed on dorzolamide/timolol and brimonidine drops and acetazolamide (500 mg) orally twice a day to lower the intraocular pressure. A laser iridotomy was performed the next day. Three days later, visual acuity in the left eye remained light perception and the intraocular pressure was 10. There was no view to the posterior pole, but a subretinal and vitreous hemorrhage was evident on B-scan ultrasonography. One month later, the vision was still light perception, and there was persistent subretinal and vitreous hemorrhage.

Case 2

Patient 2 was an 87-year-old woman with neovascular AMD in both eyes. The right eye had a longstanding disciform scar. The left eye received 3 monthly intravitreal injections of bevacizumab (1.25 mg/0.5 mL) for subretinal hemorrhage associated with poorly defined subfoveal choroidal neovascularization. She was monitored for 6 months without additional treatment but later developed a recurrence of subretinal hemorrhage and received 2 additional injections of intravitreal ranibizumab. Four months after her second ranibizumab injection, she was seen for a routine follow-up examination. Visual acuity was counting fingers in the right eye and 20/60 in the left eye. Clinical examination revealed a stable disciform scar in the right eye and pigmentary changes in the left eye without hemorrhage or fluid detected on OCT (Figure 2, left). One day later, she presented with acute loss of vision in the left eye. On examination, visual acuity in the left eye was 20/400. The patient was noted to have a new subfoveal hemorrhage (Figure 2, right). The patient received 4 more intravitreal ranibizumab injections over the next 6 months, but visual acuity remained 3/400. The most recent examination of the left eye revealed a stable fibrotic scar with no hemorrhage or fluid seen clinically and no fluid on OCT.

Case 3

Patient 3 was a 68-year-old man with a history of neovascular AMD in the right eye. His left eye was treated with verteporfin photodynamic therapy followed by 3 monthly injections of intravitreal ranibizumab (0.5 mg/0.5 mL). On examination, 4 weeks after the third injection, visual acuity was 20/800 in the right eye and 20/40 in the left eye. Clinical examination showed a stable disciform scar in the right eye and a small stable area of subretinal fibrosis in the left eye. Fluorescein angiography in the left eye showed no active leakage in the left eye, and OCT in the left eye showed no retinal fluid. The patient returned 5 weeks later with decreased vision in the left eye with

Copyright © by Ophthalmic Communications Society, Inc. Unauthorized reproduction of this article is prohibited.

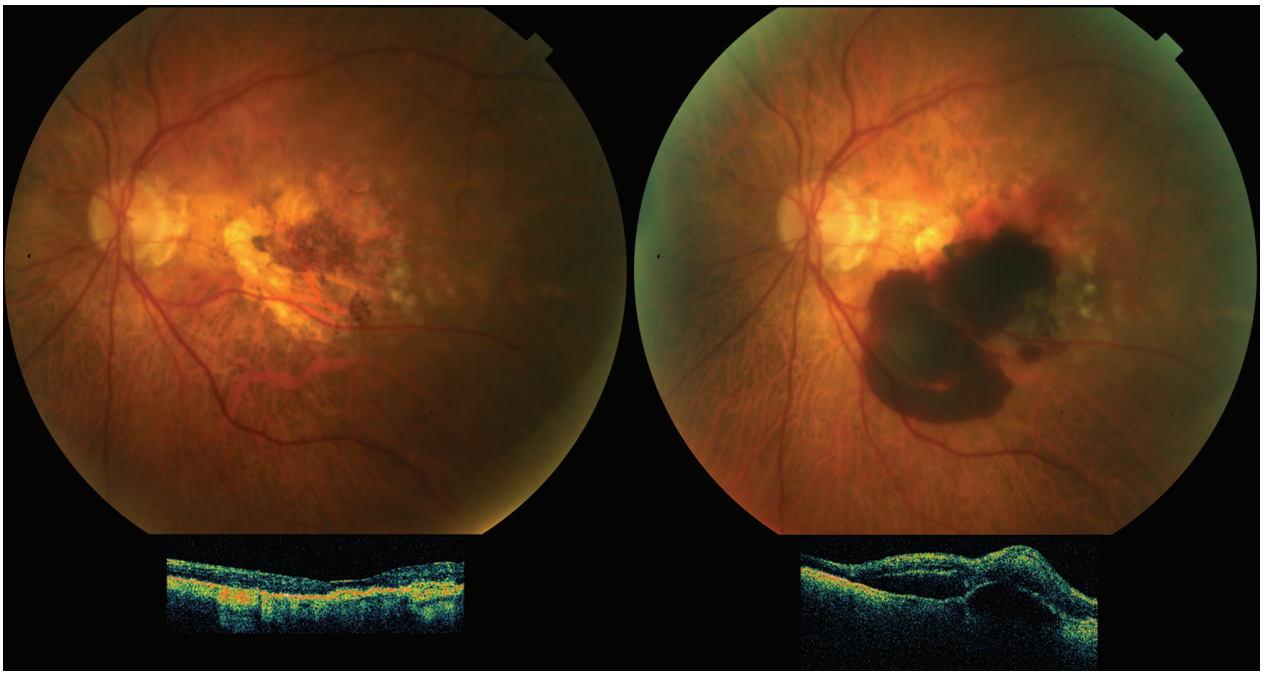

Fig. 2. Case 2. Top and bottom left, Color photograph and OCT of patient 3 demonstrating an absence of subretinal hemorrhage and fluid. Top right, Color photograph of the same eye 1 day later demonstrating subfoveal hemorrhage. Bottom right, OCT demonstrates new subretinal and subretinal pigment epithelium fluid.

a central gray scotoma. Visual acuity was 20/800 in the right eye and 20/100 in the left eye. Clinical examination showed new subretinal blood in the left eye with new retinal fluid on OCT. The hemorrhage and fluid resolved after two monthly intravitreal ranibizumab injections. During a follow-up visit 6 weeks later, the patient's visual acuity was 20/800 in the right eye and 20/50 in the left eye with no clinical evidence of macular hemorrhage or fluid on OCT (Figure 3, left). Based on these findings, no further treatment was given. On examination 4 weeks later, the vision had dropped to 20/125 in the left eye and subretinal hemorrhage and fluid were observed on clinical examination in the left eye (Figure 3, right). The patient was then placed on a maintenance regimen with intravitreal injections of ranibizumab given at intervals of every 5 to 6 weeks. He received 5 additional intravitreal injections of ranibizumab over the next 7 months. At last follow-up, visual acuity had improved to 20/40 in the left eye with no recurrence of macular hemorrhage or fluid on OCT.

Discussion

Intravitreal ranibizumab and bevacizumab have transformed the prognosis for patients with neovascular AMD.[8] Although the optimal dosing regimen of these agents remains uncertain, current treatment algorithms are largely based on the phase IIIb MARINA and ANCHOR trials of ranibizumab in which patients received continuous monthly injections for 2 years.[1–5] Because monthly visits and injections are costly to the healthcare system and difficult to maintain in this elderly patient population, alternative dosing strategies continue to be explored. In the PIER trial of ranibizumab, an initial gain in visual acuity with three monthly injections was lost when patients were switched from monthly injections to quarterly injections as was mandated by the study protocol.[9] This decline in visual acuity was presumably the result of recurrent neovascular activity and associated exudation occurring between injections. More recently, the PrONTO study, using an as-needed dosing regimen guided by monthly eye examinations and OCT, demonstrated visual outcome data similar to monthly dosing. In this small nonrandomized trial, the total number of patient visits remained the same, but the number of injections was reduced by approximately half. The PrONTO strategy is based on the assumption that fluid in the macula will occur before sight-threatening macular hemorrhages and that treating after fluid recurs, rather than before, will give visual results similar to monthly maintenance injections.[5,7]

A recent analysis of the ANCHOR, MARINA, and PIER data demonstrated that monthly intravitreal

Copyright © by Ophthalmic Communications Society, Inc. Unauthorized reproduction of this article is prohibited.

Samsung et al. v. Regeneron IPR2023-00884
Regeneron Pharmaceuticals, Inc. Exhibit 2085 Page 4

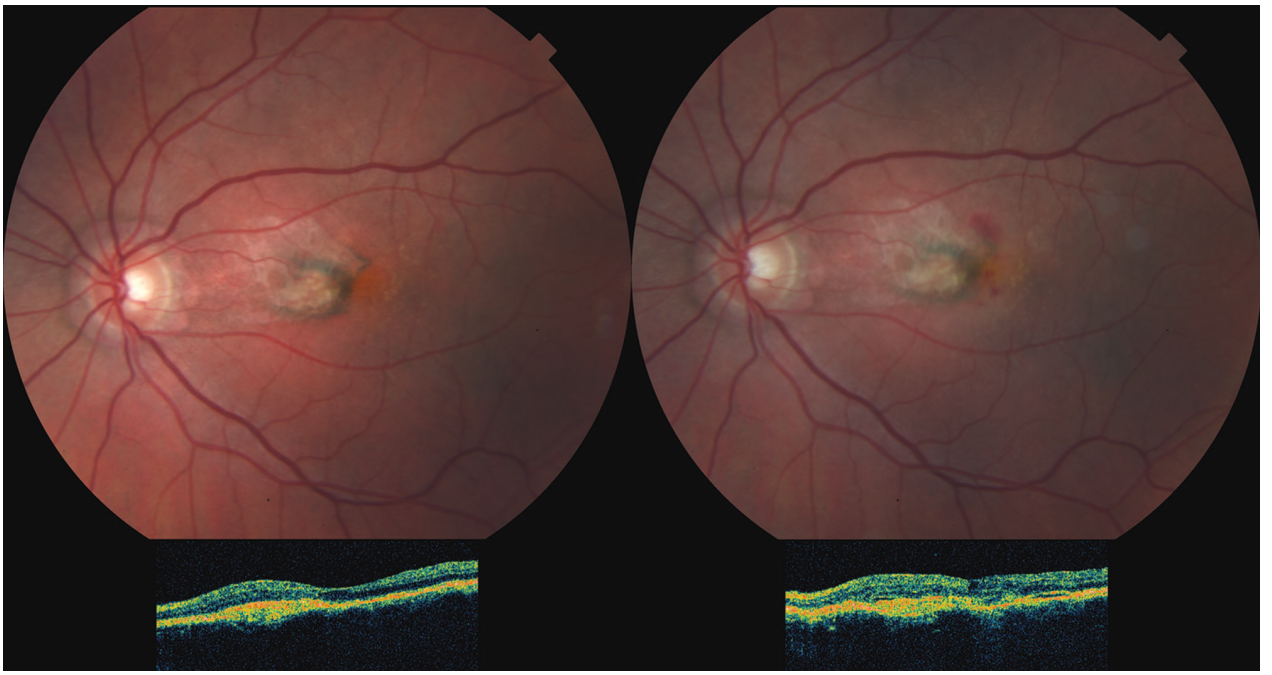

Fig. 3. Case 3. Top and bottom left, Color photograph and OCT of patient 4 demonstrating a quiescent subfoveal fibrovascular scar. Top right, Photograph of the same eye 1 month later showing new subretinal hemorrhage. Bottom right, OCT showing increased retinal thickness temporally.

ranibizumab dosing significantly reduced the frequency of macular hemorrhages compared with the sham controls or photodynamic therapy-treated patients regardless of lesion type. The effect was lost when patients were switched from monthly to quarterly dosing in the PIER study.[10] Reducing the frequency of injections should, therefore, be done with caution.

In our case series, 3 of 6 eyes on intravitreal anti-VEGF therapy developed a sight-threatening macular hemorrhage within 4 weeks of a stable clinical examination and OCT showing an absence of intra- or subretinal fluid. We based our definition of a sight-threatening macular hemorrhage on its size and proximity to the fovea rather than on vision loss per se, although three of our patients had a drop in vision from the hemorrhage. We felt it appropriate to include "near-miss" hemorrhages even if they were not subfoveal or resulted in vision loss. The visual significance of hemorrhagic events is likely influenced by multiple factors such as their size, thickness, proximity to the fovea, and the manner in which they are managed.[11] Hemorrhage size and proximity to the fovea seem to correlate with worse visual outcome in our series (Table 1).

For some patients, a monthly examination schedule similar to the PrONTO strategy may be sufficient to detect early recurrence and allow for timely treatment as needed with fewer treatments than a monthly dosing regimen. However, our findings related to the timing and severity of macular hemorrhages in three of our patients challenge the strategy of treating all patients in this manner. A maintenance regimen may be more appropriate for eyes identified as high risk, in particular eyes with preserved foveal function and patients with poor vision in the fellow eye.

Tilanus et al[12] identified warfarin use as a risk factor for massive intraocular hemorrhage in AMD and noted a possible association between massive hemorrhage and antiplatelet therapy. In our study, 4 of 6 patients were on anticoagulants, 2 were on Coumadin, one was on aspirin, and one was taking clopidogrel. The significance of these agents is uncertain because we do not know the prevalence of anticoagulation use in our general AMD population.

In our study, one patient underwent the "treat and extend" regimen, whereas the other five were treated as needed, based on examination and OCT results. Data on "treat and extend" are limited and primarily based on anecdotal evidence. Furthermore, it is difficult to determine in advance how far one can safely extend a patient's treatment interval without risking a macular hemorrhage. For our patients, the interval between the last injection and an event ranged from 7.3 to 28.9 weeks. A fluorescein angiography may be useful when monitoring patients who are 8 to 10 weeks past their last treatment, especially if considering increasing their interval of retreatment.

Copyright © by Ophthalmic Communications Society, Inc. Unauthorized reproduction of this article is prohibited.

Because this is a retrospective case series without a control group, any conclusions should be appropriately restricted. Given the small size of this series, we were unable to draw meaningful conclusions regarding specific lesion characteristics such as neovascular subtype, lesion size, or presence of subretinal fibrosis that would predispose to these hemorrhagic events. Cross-sectional study comparison is also limited because, unlike the phase IIIb ranibizumab trials, we included eyes with vision worse than 20/400, lesions greater than 12 disk areas, and eyes with significant areas of subretinal fibrosis. We also included patients treated with either intravitreal bevacizumab or ranibizumab. Despite these limitations, we feel these cases represent a significant cohort encountered in clinical practice and provide useful information that can be applied to a broader AMD population.

As the PrONTO study has demonstrated, an as-needed treatment regimen based on the clinical status of the individual patient can be an effective strategy with fewer treatments than a monthly dosing regimen. For some patients, however, a sight-threatening macular hemorrhage can occur without the presence of preceding fluid on OCT performed as recently as 1 day before the event. Prophylactic maintenance therapy may be appropriate in some cases.

Key words: age-related macular degeneration, bevacizumab, choroidal neovascularization, ranibizumab, subretinal hemorrhage.

References

1. Brown DM, Kaiser PK, Michels M, et al; ANCHOR Study Group. Ranibizumab versus verteporfin for neovascular age-related macular degeneration. N Engl J Med 2006;355:1432–1444.
2. Rosenfeld PJ, Brown DM, Heier JS, et al; MARINA Study Group. Ranibizumab for neovascular age-related macular degeneration. N Engl J Med 2006;355:1419–1431.
3. Stone EM. A very effective treatment for neovascular macular degeneration. N Engl J Med 2006;355:1493–1495.
4. Rosenfeld PJ, Rich RM, Lalwani GA. Ranibizumab: phase III clinical trial results. Ophthalmol Clin North Am 2006;19:361–372.
5. Spaide R. Ranibizumab according to need: a treatment for age-related macular degeneration. Am J Ophthalmol 2007; 143:679–680.
6. Avery RL, Pieramici DJ, Rabena MD, Castellarin AA, Nasir MA, Giust MJ. Intravitreal bevacizumab (Avastin) for neovascular age-related macular degeneration. Ophthalmology 2006; 113:363–372.e5.
7. Fung AE, Lalwani GA, Rosenfeld PJ, et al. An optical coherence tomography-guided, variable dosing regimen with intravitreal ranibizumab (Lucentis) for neovascular age-related macular degeneration. Am J Ophthalmol 2007; 143:566–583.
8. Steinbrook R. The price of sight—ranibizumab, bevacizumab, and the treatment of macular degeneration. N Engl J Med 2006;355:1409–1412.
9. Regillo CD, Brown DM, Abraham P, et al. Randomized, double-masked, sham-controlled trial of ranibizumab for neovascular age-related macular degeneration: PIER Study year 1. Am J Ophthalmol 2008;145:239–248.
10. Barbazetto et al. Dosing regimen and the frequency of macular hemorrhages in neovascular age-related macular degeneration treated with ranibizumab. Presented at the Annual Meeting of the Retina Society; September 2008.
11. Scupola A, Coscas G, Soubrane G, Balestrazzi E. Natural history of macular subretinal hemorrhage in age-related macular degeneration. Ophthalmologica 1999;213:97–102.
12. Tilanus MA, Vaandrager W, Cuypers MH, Verbeek AM, Hoyng CB. Relationship between anticoagulant medication and massive intraocular hemorrhage in age-related macular degeneration. Graefes Arch Clin Exp Ophthalmol 2000;238: 482–485.

Copyright © by Ophthalmic Communications Society, Inc. Unauthorized reproduction of this article is prohibited.