A Variable-dosing Regimen with Intravitreal Ranibizumab for Neovascular Age-related Macular Degeneration: Year 2 of the PrONTO Study

GEETA A. LALWANI, PHILIP J. ROSENFELD, ANNE E. FUNG, SANDER R. DUBOVY, STEPHEN MICHELS, WILLIAM FEUER, JANET L. DAVIS, HARRY W. FLYNN, JR, AND MARIA ESQUIABRO

• PURPOSE: To assess the long-term efficacy of a variable-dosing regimen with ranibizumab in the Prospective Optical Coherence Tomography (OCT) Imaging of Patients with Neovascular Age-Related Macular Degeneration (AMD) Treated with intraOcular Ranibizumab (PrONTO) Study, patients were followed for 2 years.

• DESIGN: A 2-year prospective, uncontrolled, variable-dosing regimen with intravitreal ranibizumab based on OCT.

• METHODS: In this open-label, prospective, single-center, uncontrolled clinical study, AMD patients with neovascularization involving the central fovea and a central retinal thickness (CRT) of at least 300 μm as measured by OCT were enrolled to receive 3 consecutive monthly intravitreal injections of ranibizumab (0.5 mg) [Lucentis; Genentech Inc, South San Francisco, California, USA]. During the first year, retreatment with ranibizumab was performed at each monthly visit if any criterion was fulfilled such as an increase in OCT-CRT of at least 100 μm or a loss of 5 letters or more. During the second year, the retreatment criteria were amended to include retreatment if any qualitative increase in the amount of fluid was detected using OCT.

• RESULTS: Forty patients were enrolled and 37 completed the 2-year study. At month 24, the mean visual acuity (VA) improved by 11.1 letters ($P < .001$) and the OCT-CRT decreased by 212 μm ($P < .001$). VA improved by 15 letters or more in 43% of patients. These VA and OCT outcomes were achieved with an average of 9.9 injections over 24 months.

• CONCLUSIONS: The PrONTO Study using an OCT-guided variable-dosing regimen with intravitreal ranibizumab resulted in VA outcomes comparable with the outcomes from the phase III clinical studies, but fewer intravitreal injections were required. (Am J Ophthalmol 2009;148:43–58. © 2009 by Elsevier Inc. All rights reserved.)

See accompanying Editorial on page 1.

Accepted for publication Jan 27, 2009.

From the Bascom Palmer Eye Institute, University of Miami Miller School of Medicine, Miami, Florida.

Anne Fung is currently at the Pacific Eye Associates, California Pacific Medical Center, San Francisco, California. Stephen Michels is currently at the Department of Ophthalmology, University Hospital Zürich, Zürich, Switzerland.

Inquiries to Philip J. Rosenfeld, Bascom Palmer Eye Institute, University of Miami Miller School of Medicine, 900 NW 17th Street, Miami, FL 33136; e-mail: prosenfeld@med.miami.edu

INHIBITION OF VASCULAR ENDOTHELIAL GROWTH FACtor A (VEGF-A) is an effective and safe therapy for the treatment of neovascular age-related macular degeneration (AMD).[1–6] Intravitreal injections of ranibizumab (Lucentis; Genentech Inc, South San Francisco, California, USA), a recombinant, humanized, monoclonal antibody antigen-binding fragment that inhibits all the known biologically active forms of VEGF, were shown to improve mean visual acuity (VA) in eyes with neovascular AMD during the phase III clinical studies. In these studies, monthly ranibizumab injections over the course of 2 years were administered to eyes with minimally classic, occult, and predominantly classic neovascular lesions. On average, the VA letter scores improved and the outcomes were highly statistically significant.

While the phase III trials used monthly injections, it is unclear at this time if monthly dosing is the best dosing interval. Observations made after the earlier phase I/II studies with intravitreal ranibizumab suggested a role for optical coherence tomography (OCT) in determining the appropriate dosing interval for each patient. These observations came about at the completion of the phase I/II studies when subjects were enrolled in an open-label extension study that provided continued intravitreal injections of ranibizumab performed at the discretion of the investigator (Heier JS, et al. IOVS 2005;46:ARVO E-Abstract 1393). Some subjects enrolled in the extension study immediately on completion of the phase I/II trials, whereas others were delayed in their enrollment for up to 1 year after the completion of the phase I/II trials. During this period before enrollment and throughout the extension study, OCT was used to monitor the resolution and recurrence of fluid in eyes as ranibizumab therapy was started and stopped (Rosenfeld PJ, unpublished data, 2003). Patients in the extension trial usually were treated if there was evidence of recurrent leakage from choroidal neovascularization (CNV) as detected using fluorescein angiography (FA) or if there was recurrent fluid as detected using OCT imaging. This recurrence of leakage or fluid in the macula was observed either in the presence or absence

0002-9394/09/$36.00
doi:10.1016/j.ajo.2009.01.024

© 2009 BY ELSEVIER INC. ALL RIGHTS RESERVED.

Samsung et al. v. Regeneron IPR2023-00884
Regeneron Pharmaceuticals, Inc. Exhibit 2097 Page 1

TABLE 1. Major Eligibility Criteria for Enrollment into the PrONTO Study

Inclusion criteria
Age 50 years or older
Active primary or recurrent macular neovascularization secondary to AMD involving the central fovea in the study eye with evidence of disease progression
OCT central retinal thickness ≥ 300 μm
Best-corrected visual acuity, using ETDRS charts, of 20/40 to 20/400 (Snellen equivalent) in the study eye
Exclusion criteria
More than 3 prior treatments with verteporfin photodynamic therapy
Previous participation in a clinical trial (for either eye) involving antiangiogenic drugs (pegaptanib, ranibizumab, anecortave acetate, protein kinase C inhibitors)
Previous subfoveal focal laser photocoagulation in the study eye
Laser photocoagulation (juxtafoveal or extrafoveal) in the study eye within 1 month preceding day 0
Subfoveal fibrosis or atrophy in the study eye
History of vitrectomy surgery in the study eye
Aphakia or absence of the posterior capsule in the study eye
History of idiopathic or autoimmune-associated uveitis in either eye

AMD = age-related macular degeneration; ETDRS = Early Treatment Diabetic Retinopathy Study; OCT= optical coherence tomography; PrONTO = Prospective OCT Imaging of Patients with Neovascular AMD Treated with intraOcular Ranibizumab.

of vision loss. It became apparent that the need for retreatment varied widely among the patients and that the need for retreatment was unpredictable. In addition, it was observed that OCT seemed to detect the earliest signs of reaccumulating fluid in the macula even before leakage could be detected reliably using FA.

These observations from the patients in the extension study served as the basis for investigating whether a variable-dosing OCT-guided regimen with ranibizumab could result in fewer injections and similar clinical outcomes when compared with the phase III regimen that used monthly injections. An investigator-sponsored, open-label, prospective clinical study was designed, known as the Prospective OCT Imaging of Patients with Neovascular AMD Treated with intraOcular Ranibizumab (PrONTO) Study. The 1-year results have been published,[7] and this article represents the full 2-year results of the PrONTO Study at the Bascom Palmer Eye Institute.

METHODS

PrONTO WAS A 2-YEAR, OPEN-LABEL, PROSPECTIVE, SINGLE-center clinical study designed to investigate the efficacy, durability, and safety of a variable-dosing regimen with intravitreal ranibizumab in patients with neovascular AMD. The PrONTO Study was an investigator-sponsored trial supported by Genentech Inc and performed after review by the Food and Drug Administration (FDA). Informed consent was obtained from all patients before determination of full eligibility.

TABLE 2. Timing of the Qualitative Change Retreatment Amendment in Year 2 (n = 39) of the PrONTO Study

First Visit When Amendment Active	No. of Patients
Month 17	5
Month 18	5
Month 19	3
Month 21	4
Month 22	4
Month 23	8
Month 24	5
Withdrew from study before amendment	1
Completed study before amendment	5
Total no. in study	40

PrONTO = Prospective Optical Coherence Tomography Imaging of Patients with Neovascular Age- Related Macular Degeneration Treated with intraOcular Ranibizumab.

The major efficacy endpoints were the change from baseline in VA and OCT measurements and the number of ranibizumab injections (0.5 mg) required over 2 years. At the start of the study, only 1 eye of a patient was determined to be eligible and was assigned as the study eye. The major eligibility criteria are shown in Table 1. The major inclusion criteria were the diagnosis of neovascular AMD with a baseline protocol VA letter score of 20 to 70 letters using the Early Treatment Diabetic Retinopathy Study (ETDRS) chart at 2 m (Snellen equivalent of 20/40 to 20/400)[8] and an OCT central retinal thickness (CRT) of at least 300 μm. There were no exclusion criteria for preexisting cardiovascular, cerebrovascular, or peripheral vascular conditions. Of note, all FA lesion types and lesion sizes were eligible for the study.

Specifications for the digital fundus photography equipment and OCT equipment were described in the PrONTO year 1 report.[7] Angiographic lesion classification, including the diagnosis of retinal angiomatosis proliferation (RAP), was independently assessed and was confirmed by 3 study investigators as previously described.[7] All 6 high-resolution (512 A scans per B-scan) OCT diagonal scans were used to evaluate whether fluid was present in the macula and whether retreatment was needed. For the purposes of this study, fluid in the macula was identified as intraretinal fluid (cysts) or subretinal fluid, and a fluid-free macula was defined by the absence of retinal cysts and subretinal fluid as determined by OCT. Fluid under the retinal pigment epithelium (RPE), otherwise known as a pigment epithelial detachment (PED), was recorded as an

Samsung et al. v. Regeneron IPR2023-00884
Regeneron Pharmaceuticals, Inc. Exhibit 2097 Page 2

TABLE 3. Visual Acuity of Eyes with Neovascular Age-Related Macular Degeneration Treated with a Variable-Dosing Regimen of Ranibizumab through 24 Months

Study Eyes	Baseline VA Letters (Snellen Equivalent), n = 40	Month 12 VA Letters (Snellen Equivalent), n = 40	Month 24 VA Letters (Snellen Equivalent), n = 37	Change in VA Letter Scores from Baseline to Month 24,[a] n = 37
Mean (*P* value)[b]	56.2 (20/80 + 1)	65.5 (20/50; $P < .001$)	67.0 (20/50 + 1; $P < .001$)	11.1 ($P < .001$)
Median (*P* value)[c]	57 (20/80 + 2)	68 (20/40 − 2; ($P < .001$)	68.0 (20/40 − 2; $P < .001$)	14.0 ($P < .001$)

VA = visual acuity.
[a]Change in letter scores compares the 37 patients who completed the study at month 24 with their baseline scores.
[b]Paired Student *t* test.
[c]Paired Wilcoxon signed-rank test.

TABLE 4. Central Retinal Thickness of Eyes with Neovascular Age-Related Macular Degeneration Treated with a Variable-Dosing Regimen of Ranibizumab through Month 24

Patient Study Eyes	Baseline CRT (μm), n = 40	Month 12 CRT (μm), n = 40	Month 24 CRT (μm), n = 37	Change in CRT (μm) from Baseline to Month 24,[a] n = 37
Mean (*P* value)[b]	393.9	216.1 ($P < .001$)	179.3 ($P < .001$)	−211.7
Median (*P* value)[c]	384.5	199.0 ($P < .001$)	171 ($P < 0.001$)	−209.0

CRT = central retinal thickness.
[a]Change in letter scores compares the 37 patients who completed the study at month 24 with their baseline scores.
[b]Paired Student *t* test.
[c]Paired Wilcoxon signed-rank test.

OCT finding in the macula, but was not included in any of the retreatment criteria during the first year.

Eligible patients underwent VA testing and ophthalmoscopic examination at baseline, days 14, 30, 45, and 60, and then monthly thereafter. Fundus photography and OCT imaging were performed at baseline and on days 1, 2, 4, 7, 14, and 30 after the first 2 injections, and then monthly thereafter. FA was performed at baseline, months 1, 2, and 3, and then every 3 months thereafter. All ophthalmic photographers and the single OCT technician involved in the study were previously certified to participate in FDA-approved clinical trials at the Bascom Palmer Eye Institute.

Intravitreal injections of ranibizumab were administered to all patients at baseline, month 1, and month 2. Additional reinjections were given if any of the following changes were observed by the evaluating physician during the first year of the study: 1) VA loss of at least 5 letters with OCT evidence of fluid in the macula, 2) an increase in OCT CRT of at least 100 μm, 3) new macular hemorrhage, 4) new area of classic CNV, or 5) evidence of persistent fluid on OCT 1 month after the previous injection. All criteria were based on comparisons with the previous month's examination or the last time a FA was performed. If any single criterion for reinjection was fulfilled, the intravitreal injection was performed using a standard protocol previously described.[7]

During the second year, an amendment to the study changed the retreatment criteria to include any qualitative change in the appearance of the OCT images that suggested recurrent fluid in the macula. These qualitative changes included the appearance of retinal cysts or subretinal fluid or an enlargement of a PED. Any of these qualitative changes alone was sufficient to permit retreatment. Since this amendment was approved after completion of the first year, the retreatment criteria were applied to patients at different time points in the study. Table 2 shows when the retreatment amendment was applied to the patients during the study. It is important to note that the amendment was in addition to the initial criteria, not in place of them.

At the completion of the study, an audit of drug shipments revealed that the vials in the first drug shipment received from Genentech Inc had a concentration of 6 mg/ml, equivalent to a dose of 0.3 mg in a volume of 0.05 ml. It was concluded that this lower dose, which was being used concurrently in the phase II and III clinical studies, mistakenly was shipped for use in the PrONTO Study. For this reason, the first 19 patients received some 0.3-mg doses rather than the per-protocol dose of 0.5 mg. The first 7 patients received 3 monthly 0.3-mg doses, the next 7 patients received 2 monthly 0.3-mg doses, and the next 5 patients received one 0.3-mg dose at baseline. All subse-

Samsung et al. v. Regeneron IPR2023-00884
Regeneron Pharmaceuticals, Inc. Exhibit 2097 Page 3

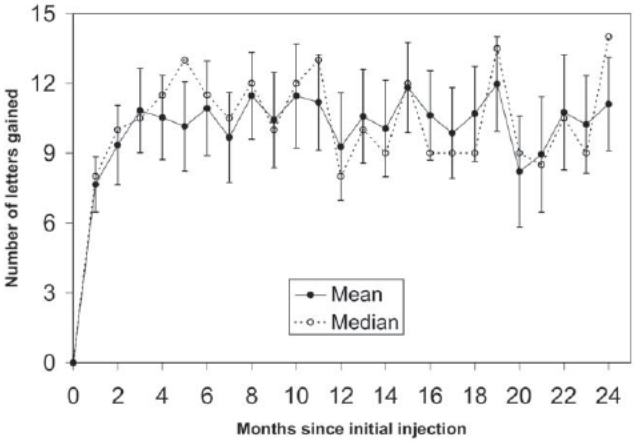

FIGURE 1. Graph showing the mean and median change in visual acuity (VA) through 24 months of eyes with neovascular age-related macular degeneration (AMD) treated with a variable-dosing intravitreal ranibizumab regimen. Vertical lines are 1 standard error (SE) of the means.

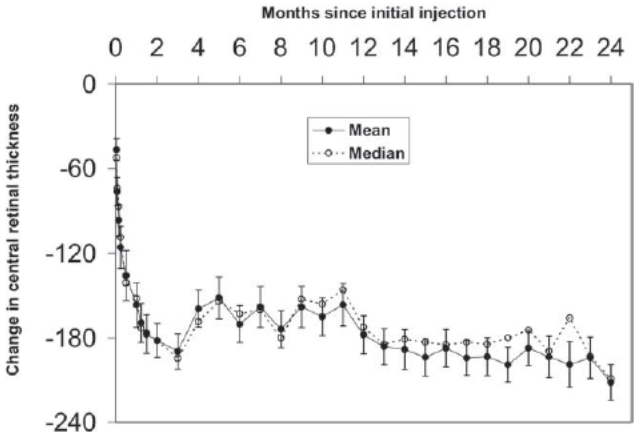

FIGURE 2. Graph showing the mean and median change in optical coherence tomography (OCT) central retinal thickness (CRT) through 24 months of eyes with neovascular AMD treated with a variable-dosing intravitreal ranibizumab regimen. Vertical lines are 1 SE of the means.

quent drug shipments and doses of drug were at the per-protocol concentration of 10 mg/ml, resulting in an intravitreal dose of 0.5 mg in 0.05 ml.

The major 2-year outcome measurements in the PrONTO Study included ETDRS VA letter scores, OCT CRT measurements, the change in VA letter scores and OCT measurements from baseline, and the total number of injections received by a patient during 2 years. For purposes of analysis, a loss of VA was defined as a drop of at least 5 letters between baseline and the 24-month time point. For the mean VA letter scores and CRT measurements, the data were compared statistically with mean baseline values using the paired Student *t* test. Median measurements were compared with median baseline values using the paired Wilcoxon signed-rank test. The influence of baseline FA lesion types on the number of injections over 24 months was assessed using a one-way analysis of variance and the Kruskal-Wallis test. The associations between the number of injections and VA outcomes and the associations between the change in CRT and VA outcomes at different time points during the study were assessed using the Pearson correlation analysis and Spearman nonparametric correlation analysis. Statistical significance was defined as $P < .05$.

RESULTS

• STUDY COMPLIANCE: Patient demographics and enrollment at baseline were described previously.[7] Between August 23, 2004 and April 25, 2005, a total of 69 patients were screened for the study and 40 patients were enrolled. At baseline, the mean and median VA letter scores were 56 ($20/80^{+1}$) and 57 ($20/80^{+2}$), respectively (Table 3). Baseline mean and median OCT 1-mm CRT measurements were 394 and 385 μm, respectively (Table 4). The characteristics of the neovascular lesions were described previously. Of note, the study included occult with no classic lesions (10 eyes; 25%), minimally classic lesions (23 eyes; 57.5%), and predominantly classic lesions (7 eyes; 17.5%) as characterized by FA. Overall, 10 (25%) of the 40 lesions were categorized as RAP lesions.

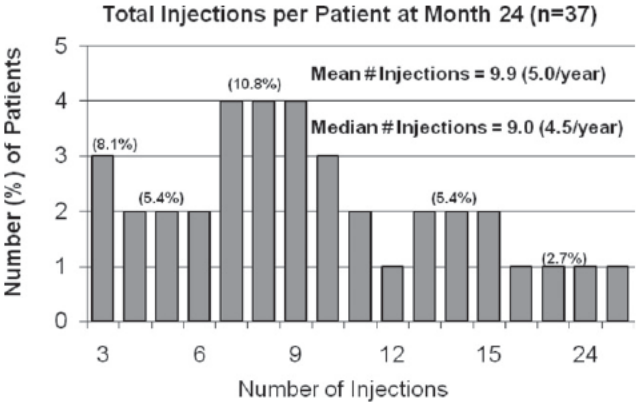

FIGURE 3. Bar graph showing the distribution of patients receiving a given number of ranibizumab injections through 24 months according to the retreatment criteria used in the Prospective OCT Imaging of Patients with Neovascular AMD Treated with intraOcular Ranibizumab (PrONTO) Study.

During the second year, 3 patients withdrew from the study. One patient developed a tear of the RPE with a submacular hemorrhage and experienced a VA loss of 36 letters.[3] Submacular surgery was performed for removal of the hemorrhage and the patient withdrew from the study. The second patient was unable to travel attributable to complications after hip surgery and withdrew at month 20. The third patient died of Creutzfeldt-Jakob disease at

Samsung et al. v. Regeneron IPR2023-00884
Regeneron Pharmaceuticals, Inc. Exhibit 2097 Page 4

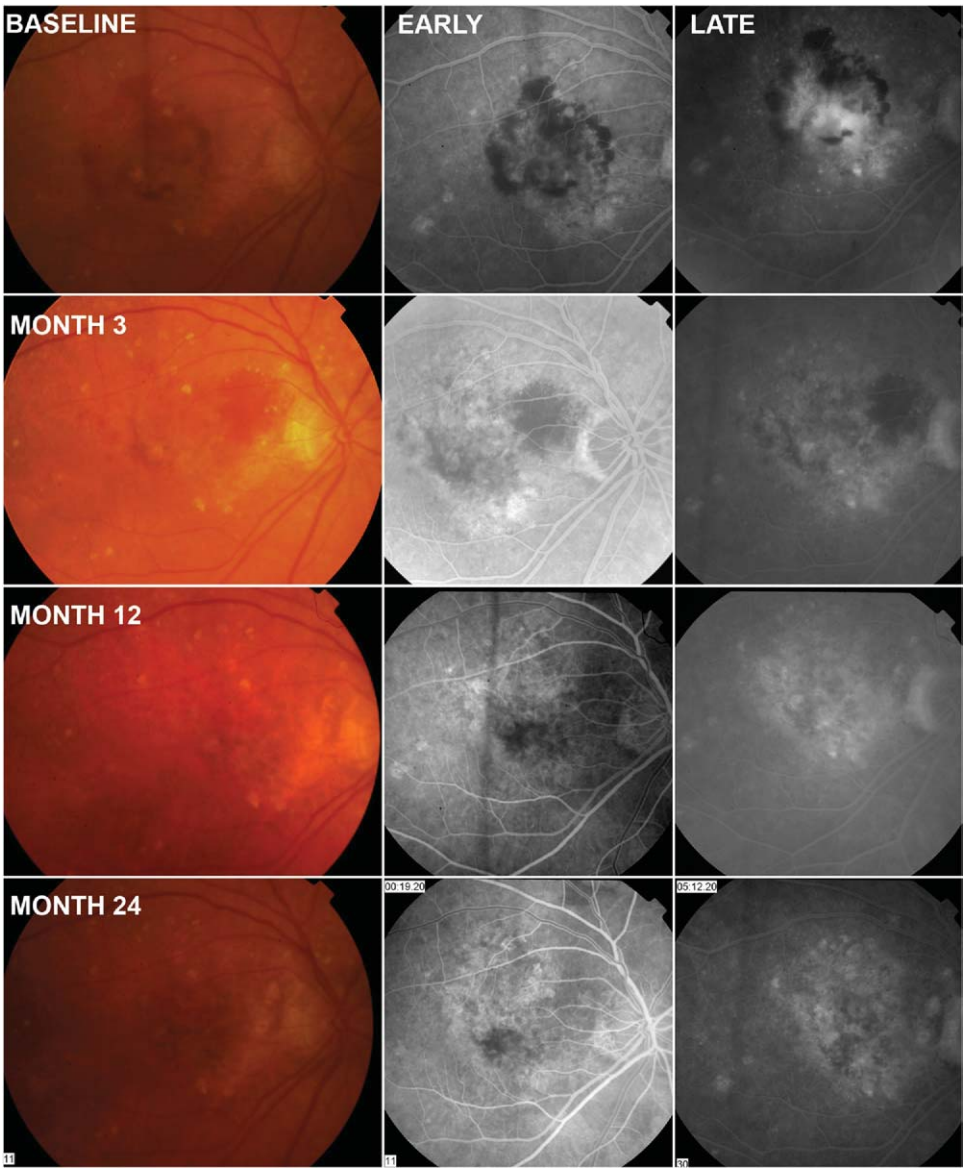

FIGURE 4. Case 1: A 74-year-old woman with neovascular AMD diagnosed with a minimally classic lesion in her right eye. She received only the first 3 required ranibizumab injections and then was followed up for 24 months. Color fundus images with early- and late-phase fluorescein angiographic (FA) images are shown at baseline, month 3 (1 month after the third injection), month 12, and month 24 without any additional injections of ranibizumab.

month 18. This death was not thought to be attributable to ranibizumab and the death was not deemed to be a drug-related adverse event. Data were analyzed from patients who completed the study (observed data set) as well from all the patients who were enrolled in the study by carrying forward their last obtained VA and OCT data before their withdrawal (last observation carried forward data set).

• **VISUAL ACUITY AND OPTICAL COHERENCE TOMOGRAPHY THROUGH 24 MONTHS:** The 1-year results of the PrONTO Study were reported previously.[7] Noteworthy outcomes included an improvement in VA detectable by day 14 and increases in mean and median VA scores at month 3 of 10.8 letters ($P < .001$) and 10.5 letters ($P < .001$), respectively, after the first 3 monthly injections of ranibizumab. At month 12, the improvements in mean and median VA scores compared with baseline were 9.3 letters ($P < .001$) and 11 letters ($P < .001$), respectively (Table 3; Figure 1).

At month 24, the observed final mean and median VA scores for the remaining 37 patients compared with baseline improved by 11.1 letters (standard deviation [SD], 12.2; standard error, 2.0; 95% confidence interval [CI], 7.0 to 15.2; $P < .001$) and 14 letters ($P < .001$), respectively. Sixteen eyes (43%) gained at least 3 lines of vision (95% CI, 60% to

Samsung et al. v. Regeneron IPR2023-00884
Regeneron Pharmaceuticals, Inc. Exhibit 2097 Page 5

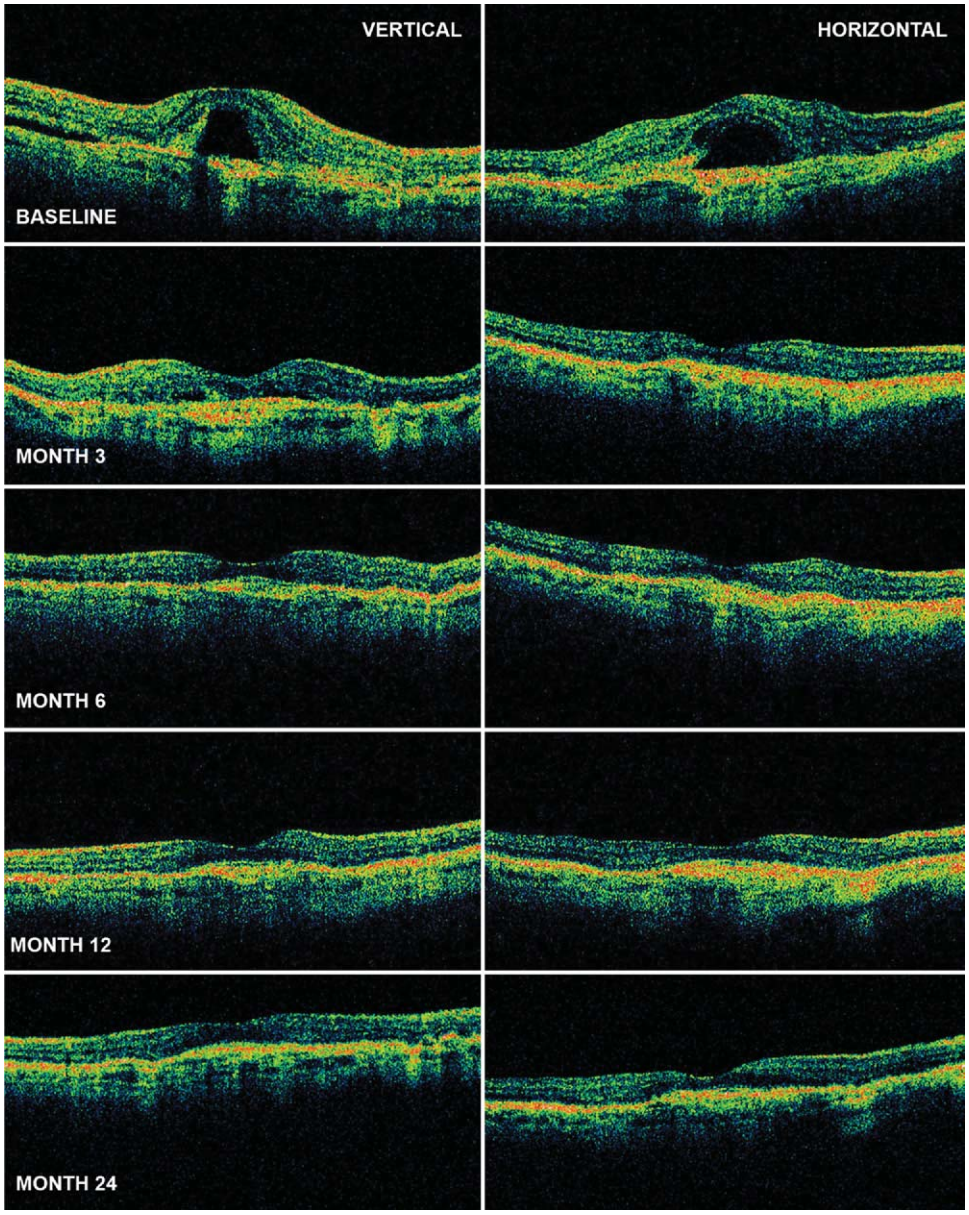

FIGURE 5. Case 1: OCT response from baseline through month 24 in an eye with neovascular AMD and a minimally classic lesion given a total of 3 injections through month 2, with no additional injections through month 24. (Left column) Vertical and (Right column) horizontal OCT scans, CRT measurements, and VA are shown of the left eye at baseline (526 μm; VA, 20/80), first ranibizumab injection; month 3 (188 μm; VA, 20/50), observed; month 6 (178 μm; VA, 20/25), observed; month 12 (198 μm; VA, 20/20), observed; month 24 (176 μm; VA, 20/16), observed.

27%), with 3 eyes (8.1%) gaining at least 6 lines of vision. Twenty-nine (78%) of the 37 eyes completing the study avoided any loss of letters (95% CI, 89% to 61%). All 37 eyes completing the study avoided a loss of 3 lines or more of VA. When calculating VA outcomes using the last observation carried forward for all 40 patients, the mean and median VA scores improved by 10.0 letters ($P < .001$) and 11.5 letters ($P < .001$), respectively, and 39 eyes (97.5%) avoided a loss of 3 lines or more.

The overall improvement in VA was associated with a decrease in CRT. At month 24, the observed mean and median thickness measurements decreased by 212 μm ($P < .001$) and 209 μm ($P < .001$), respectively (Figure 2). When the last observation was carried forward for all 40 patients, the mean and median OCT thickness measurements decreased by 222 μm ($P < .001$) and 230 μm ($P < .001$), respectively. These results were very similar regardless of whether the observed data set or the last observation carried forward data set were used in the final analyses.

These outcomes were achieved with a mean and median number of injections over 2 years of 9.9 (SD, 5.3) and 9.0

Samsung et al. v. Regeneron IPR2023-00884
Regeneron Pharmaceuticals, Inc. Exhibit 2097 Page 6

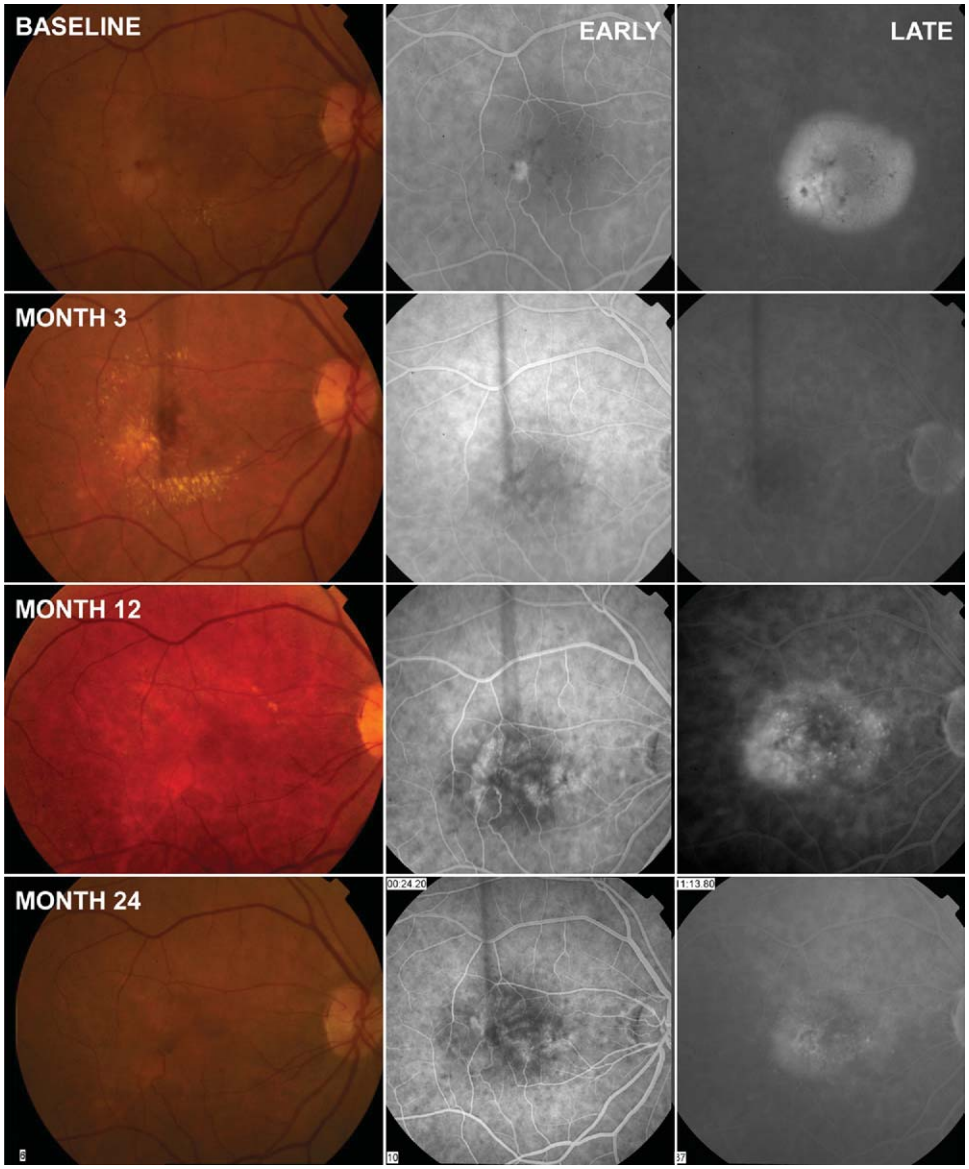

FIGURE 6. Case 2: A 68-year-old woman with AMD diagnosed with a minimally classic lesion and retinal angiomatous proliferation in her right eye. She received 24 injections over 24 months because of recurrent and persistent fluid in the macula after month 3. Color fundus images with early- and late-phase FA images are shown at baseline, month 3, month 12, and month 24. Additional ranibizumab injections were administered monthly except at month 3.

(range, 3 to 25), respectively (Figure 3). Three eyes (8.1%) required only the first 3 injections over 2 years (Figures 4 and 5), whereas 2 eyes (5.4%) required 24 or 25 injections over 2 years (Figures 6 and 7). No patient received anti–VEGF therapy in the fellow eye.

The influence of baseline VA and lesion size in disc areas on the number of reinjections was assessed with both Pearson correlation and Spearman nonparametric correlation analyses. No correlation was found between number of reinjections and baseline acuity (Pearson, $r = 0.14$ and $P = .39$; Spearman, $r = -0.01$ and $P = .97$) or lesion size (Pearson, $r = 0.05$ and $P = .78$; Spearman, $r = 0.07$ and $P = .67$). When comparing baseline angiographic lesion types with the mean number of reinjections during follow-up, we did not observe statistical significance using a one-way parametric analysis of variance ($P = .67$). The variation in injection rate for different lesion types was less evident during the second year of the study as compared with the first year. Overall, occult with no classic component received 10.0 injections (SD, 5.7), minimally classic lesions received 9.4 injections (SD, 4.6), and predominantly classic lesions received 11.6 injections (SD, 7.4). RAP lesions received 11.6 (SD, 5.9) injections. The tendency for RAP lesions to require more frequents retreatments during the first year was less apparent over the 2 years.

Samsung et al. v. Regeneron IPR2023-00884
Regeneron Pharmaceuticals, Inc. Exhibit 2097 Page 7

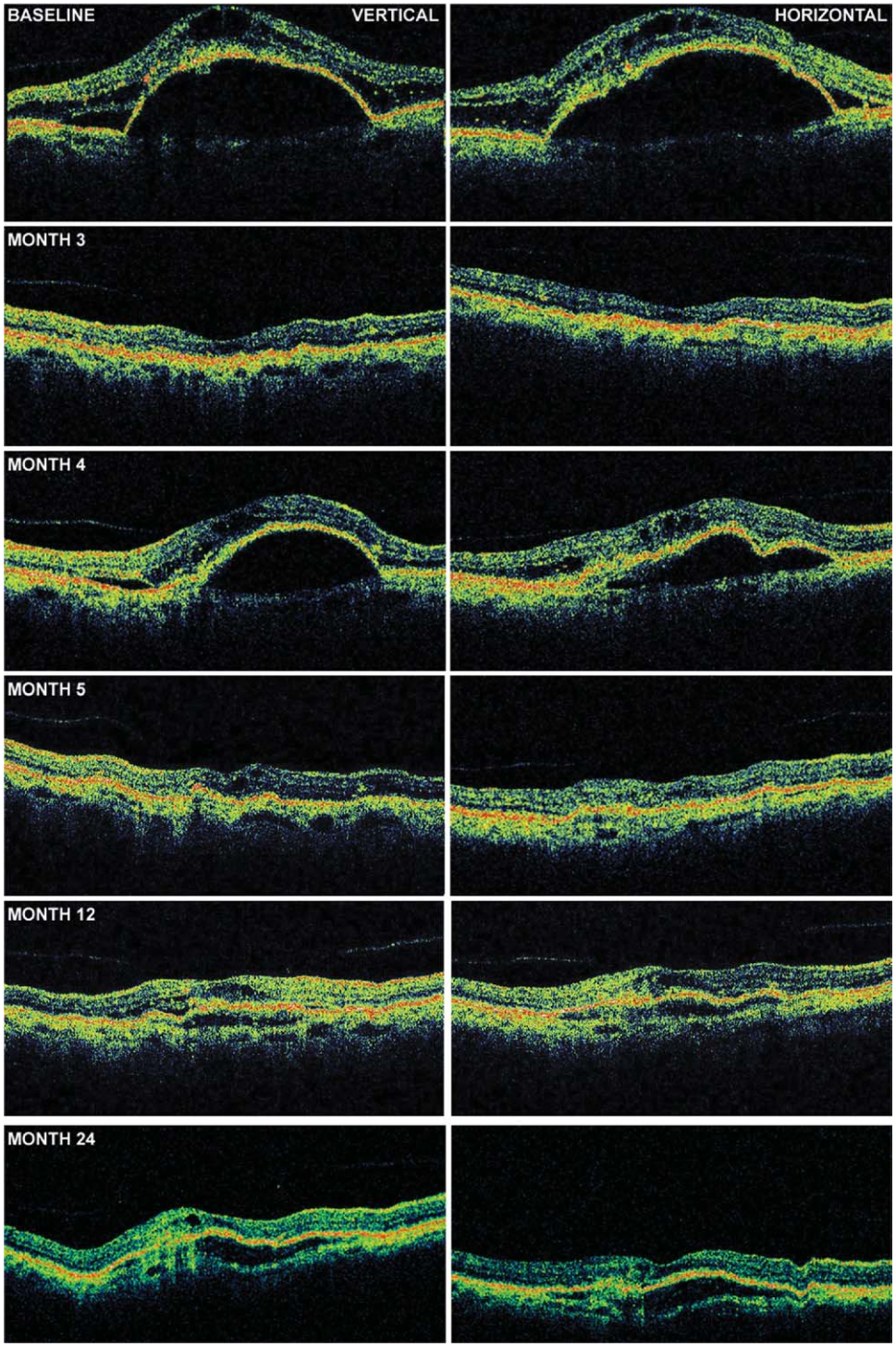

FIGURE 7. Case 2: OCT response from baseline through month 24 with a total of 24 ranibizumab injections over 24 months. (Left column) Vertical and (Right column) horizontal OCT scans, CRT measurements, and VA of her right eye are shown at baseline (345 μm; VA, 20/63), first ranibizumab injection; month 3 (164 μm; VA, 20/20), observe; month 4 (306 μm; VA, 20/40), fourth ranibizumab injection; month 5 (216 μm; VA, 20/32), fifth ranibizumab injection; month 12 (248 μm; VA, 20/25), twelfth ranibizumab injection; and month 24 (173 μm; VA, 20/25), twenty-fourth ranibizumab injection.

The influence of the number of reinjections on VA outcomes was assessed with both Pearson parametric correlation and Spearman nonparametric correlation analyses. Pearson and Spearman correlations between the change in letter scores at month 24 and the total number of injections were −0.12 (P = .48) and −0.04

Samsung et al. v. Regeneron IPR2023-00884
Regeneron Pharmaceuticals, Inc. Exhibit 2097 Page 8

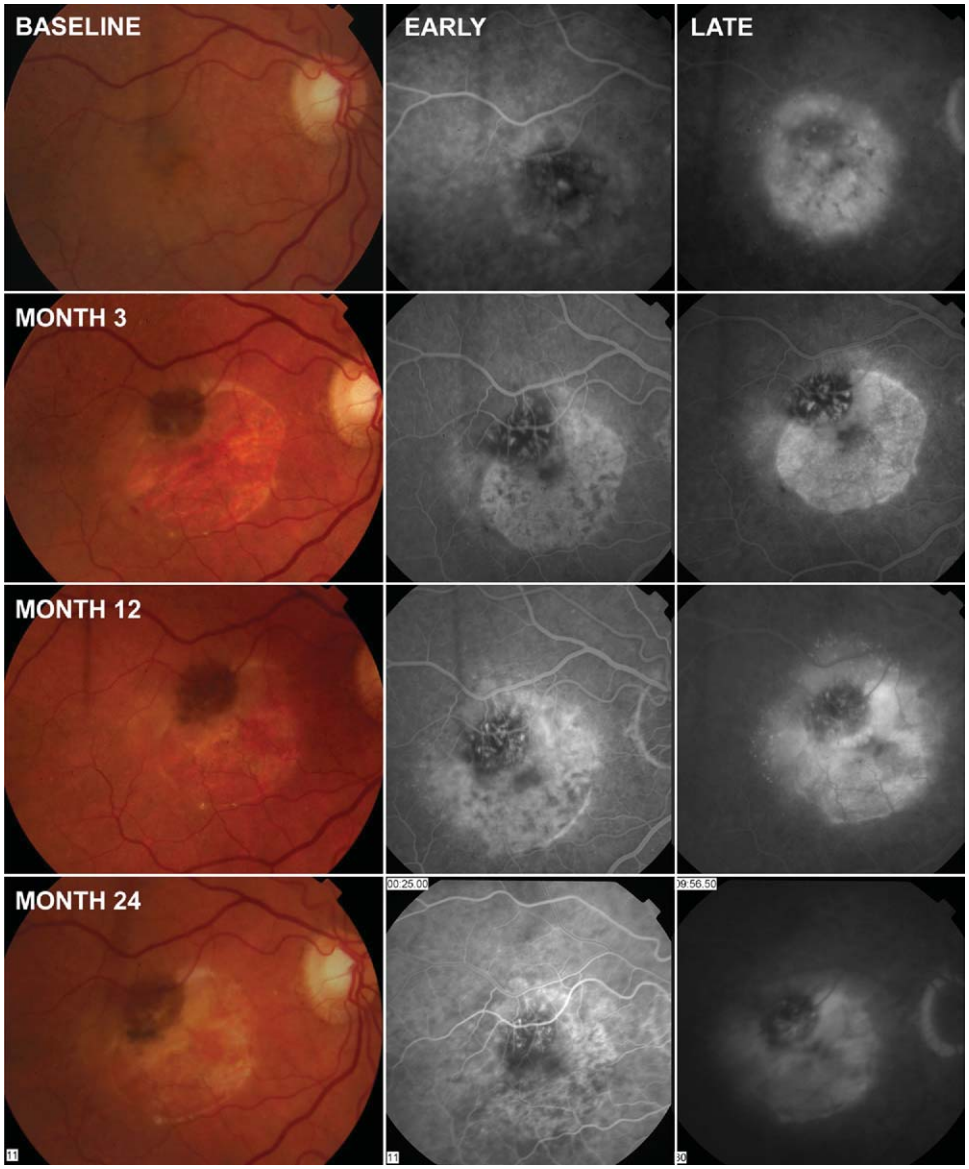

FIGURE 8. Case 3: A 96-year-old woman with neovascular AMD diagnosed with a minimally classic lesion and retinal angiomatous proliferation in the right eye. She developed a tear of the retinal pigment epithelium after the first injection. She was given seven intravitreal ranibizumab injections over 24 months. Color fundus images with early- and late-phase FA images are shown at baseline, month 3 (1 month after the third injection), month 12, and month 24. Four additional ranibizumab injections were given at month 5, month 13, month 21, and month 22.

(P = .082). No statistically significant correlation was found between the need for more frequent injections and VA outcomes.

Correlation analyses between the change in OCT-CRT and VA measurements were performed at different time points in the study to examine the predictive value of these OCT measurements. Once again, Pearson parametric and Spearman nonparametric correlations were used in these analyses. As previously reported, statistically significant correlations were found between the OCT-CRT measurements and VA at months 2, 3, and 12.[7] At month 24, no correlation was detected using either analytic technique (Pearson, r = 0.055 and P = .74; Spearman, r = 0.08 and P = .64). Another strategy was to examine the association between OCT changes at month 1 with VA changes thereafter to determine if OCT improvements could serve as a predictor of future VA improvements. Statistically significant correlations were detected when the OCT-CRT measurements at month 1 were correlated with the VA changes at month 2 (Pearson, r = 0.57 and P < .001; Spearman, r = 0.47 and P = .002), month 3 (Pearson, r = 0.51 and P = .001; Spearman, r = 0.36 and P = .021), month 12 (Pearson, r = 0.37 and P = .019; Spearman, r = 0.38 and P = .015), and month 24 (Pearson, r = 0.41 and P = .011; Spearman, r = 0.36 and P = .031).

Samsung et al. v. Regeneron IPR2023-00884
Regeneron Pharmaceuticals, Inc. Exhibit 2097 Page 9

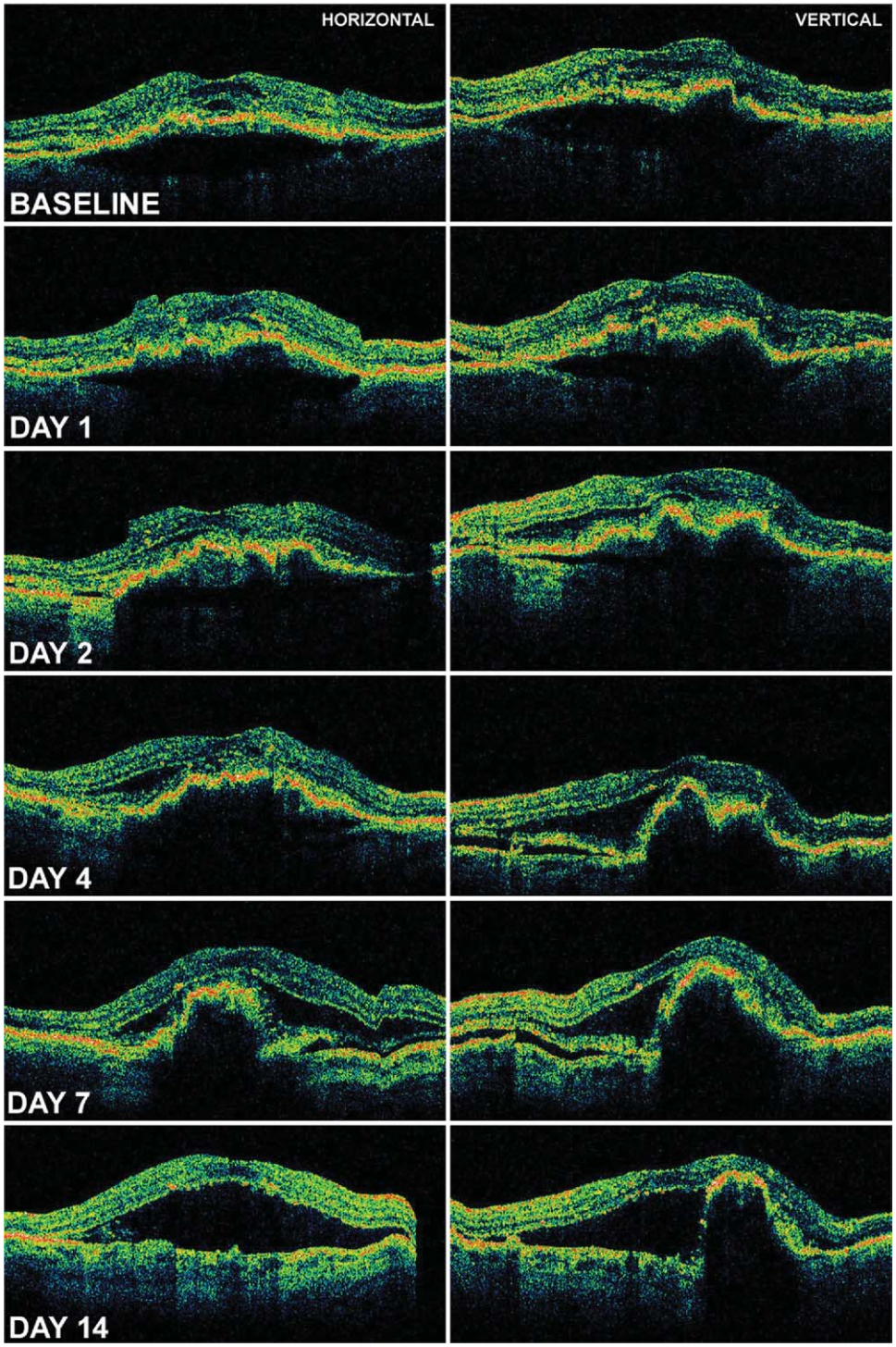

FIGURE 9. Case 3. OCT response to the first ranibizumab injection from baseline through day 14. (Left column) Vertical and (Right column) horizontal OCT scans and CRT measurements at baseline (382 μm), day 1 (400 μm), day 2 (321 μm), day 4 (295 μm), day 7 (585 μm), and day 14 (764 μm; VA, 20/25).

• **VISION LOSS:** For the purposes of analysis, vision loss in the PrONTO Study was defined as a loss of at least 5 letters between baseline and month 24. Of 37 eyes with complete follow-up, 29 eyes (78%) avoided any loss of letters at 24 months. Of the remaining 8 eyes, only 4 lost 5 letters or more. Of the 3 eyes that did not complete follow-up, only 1 had lost 5 letters or more at the last follow-up. Only the patient who withdrew after a submacular hemorrhage lost more than 3 lines of vision. Therefore, a total of 5 eyes lost 5 letters or more at their final follow-up visit.

Samsung et al. v. Regeneron IPR2023-00884
Regeneron Pharmaceuticals, Inc. Exhibit 2097 Page 10

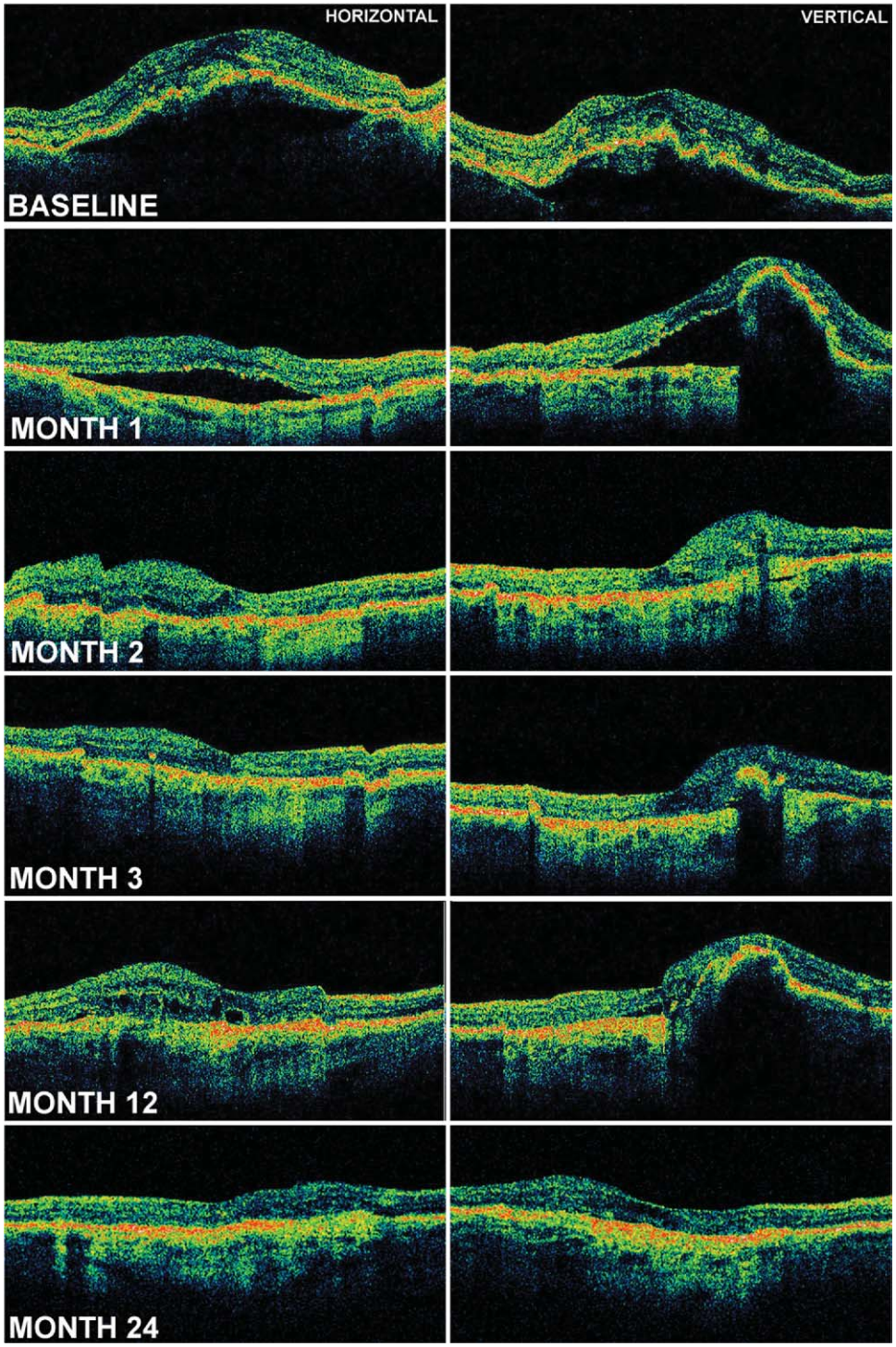

FIGURE 10. Case 3: OCT response from baseline through month 24 for a total of 7 ranibizumab injections over 24 months. (Left column) Vertical and (Right column) horizontal OCT scans, CRT measurements, and VA are shown at baseline (382 μm; VA, 20/50), month 1 (596 μm; VA, 20/200), month 2 (276 μm; VA, 20/125), month 3 (340 μm; VA, 20/160), month 12 (305 μm; VA, 20/125), and month 24 (220 μm; VA, 20/63).

Vision loss in the PrONTO Study was attributable to tears of the RPE (2 eyes; Figures 8 to 10), progression of the underlying dry AMD (2 eyes; Figures 11 and 12), and formation of subfoveal fibrosis (1 eye). Both of the eyes which developed RPE tears had minimally classic lesions characterized as RAP with an associated PED. One eye developed the RPE tear after the first injection. The evolution of the tear is depicted in Figure 9. Vision

Samsung et al. v. Regeneron IPR2023-00884
Regeneron Pharmaceuticals, Inc. Exhibit 2097 Page 11

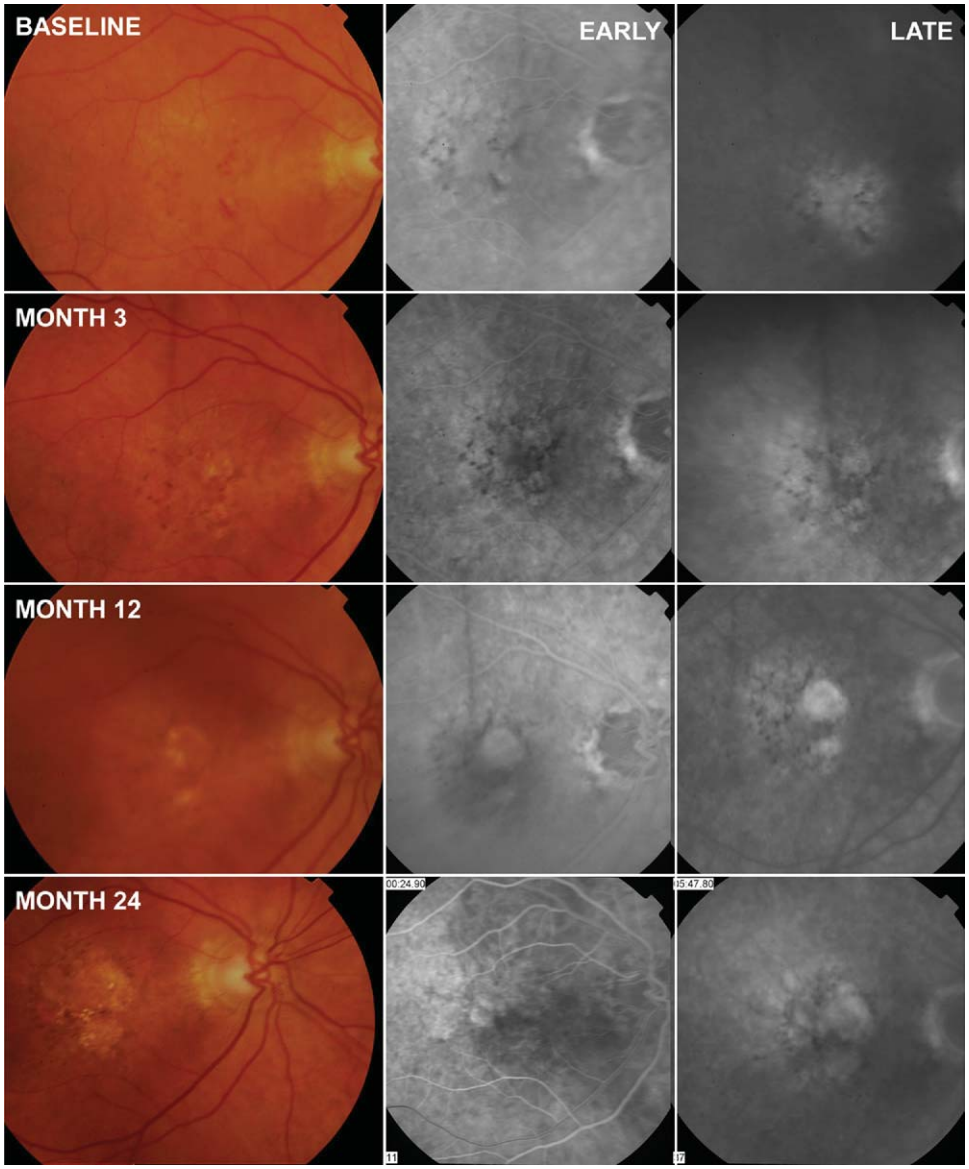

FIGURE 11. Case 4: An 89-year-old woman with AMD diagnosed with an occult-only lesion in her right eye. She achieved a fluid-free macula after the first 3 ranibizumab injections. She received a total of 9 intravitreal injections of ranibizumab over 24 months. She showed continued progression of geographic atrophy. Color fundus images with early- and late-phase FA images are shown at baseline, month 3, month 12, and month 24.

remained good until the subretinal fluid disappeared. Over the ensuing 2 years, the vision gradually improved after intermittent treatment with ranibizumab. The second eye with a tear of the RPE experienced an enlargement of the PED before the RPE tear and hemorrhage developed at the end of the first year. Prior to the hemorrhage at month 11, this patient had responded to therapy. After the initial 3 monthly injections, there was no evidence of fluid in the macula, and therefore no injection was given at month 3. Gradually, fluid reaccumulated in the macula with enlargement of a PED, but no injection was given until month 5 because none of the original quantitative retreatment criteria were fulfilled. At month 5, the patient was retreated because of a more than 100-μm increase in the OCT-CRT measurement and a loss of 11 letters. At month 6, the VA improved by 8 letters with complete resolution of the subretinal and intraretinal fluid and no injection was given. Injections were given again at month 7 and at month 9 because of reaccumulating fluid in the macula. At month 10, no fluid was detected in the retina or under the retina, so no injection was given even though the PED did show an increase in height. An increase in the height or size of a PED was not one of the retreatment criteria during the first year of the study. Shortly thereafter, before the

Samsung et al. v. Regeneron IPR2023-00884
Regeneron Pharmaceuticals, Inc. Exhibit 2097 Page 12

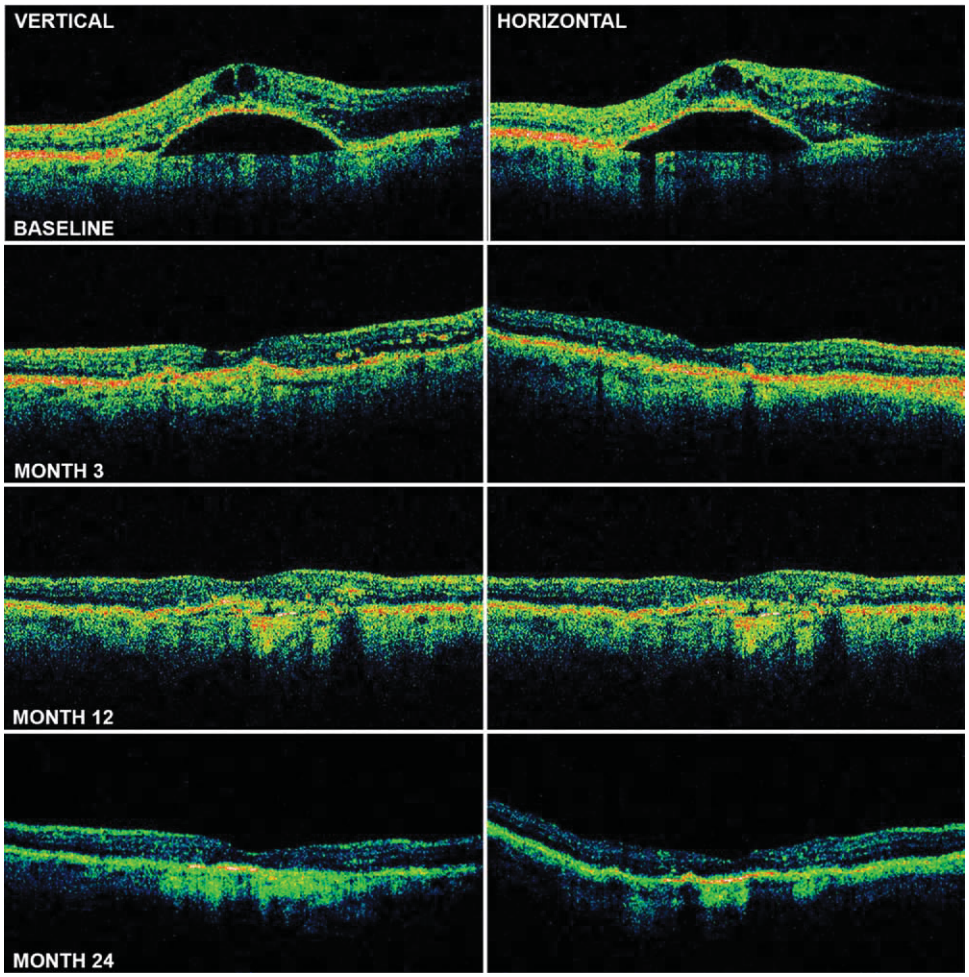

FIGURE 12. Case 4: OCT response in an eye with neovascular AMD from baseline through month 24 while receiving a total of 9 ranibizumab injections over 24 months. (Left column) Vertical and (Right column) horizontal OCT scans, CRT measurements, and VA are shown at baseline (348 μm; VA, 20/63); month 3 (187 μm; VA, 20/32), observe; month 12 (191 μm; VA, 20/40); and month 24 (160 μm; VA, 20/100).

month 11 visit, a submacular hemorrhage developed, approximately 7 weeks after the previous injection at month 9. Injections were then given at month 11 and month 12. At month 12, the VA letter score was 31 (20/250) compared with a letter score of 80 (20/25) at the month 10 visit just before the hemorrhage. The patient subsequently elected to undergo submacular surgery during month 13 and withdrew from the study. Overall, this patient received 8 injections of ranibizumab over 12 months.

Of the remaining 3 eyes with vision loss, 2 eyes had progression of geographic atrophy with gradual vision loss. These 2 eyes showed enlargement of their geographic atrophy at rates at or below 0.7 disc areas per year or 1.8 mm^2 per year. This rate was within the normal expected growth rate for geographic atrophy.[9–11] The fifth eye with vision loss had subretinal fibrosis which developed by month 3 after the 3 monthly injections and remained stable thereafter.

- **SAFETY:** There were no ocular or systemic adverse events attributable to the injection of ranibizumab. A total of 386 injections were performed without any episodes of endophthalmitis, uveitis, retinal detachment, retinal tear, vitreous hemorrhage, lens damage, cataract progression, or prolonged intraocular pressure elevation. No systemic thromboembolic events or deaths attributable to the medication occurred. No hypertension was newly diagnosed during the study.

DISCUSSION

IN THE PrONTO STUDY, INTRAVITREAL INJECTIONS OF ranibizumab were shown to improve VA and rapidly to reduce the amount of macular fluid in most patients with neovascular AMD. This decrease in retinal thickness, which was detectable within 1 day after the first injection, continued through the first 3 months and was maintained through 24 months using an OCT-guided vari-

Samsung et al. v. Regeneron IPR2023-00884
Regeneron Pharmaceuticals, Inc. Exhibit 2097 Page 13

able-dosing regimen. During the first year, strict quantitative retreatment guidelines were followed. These guidelines were developed to determine if more fluid continued to accumulate after a small amount of fluid reaccumulated in a dry macula. Another objective was to assess whether VA or OCT was better at determining when fluid was reaccumulating in the macula. It became evident that fluid continued to increase if left untreated and that the qualitative assessment of OCT B scans was better at detecting fluid in the macula than waiting for changes in VA. The need to incorporate qualitative changes into the retreatment criteria was exemplified by the 1 patient in whom a hemorrhage developed after the increase in size of the PED. Based on this and other observations, it was decided that it would be unethical to continue the strict quantitative retreatment guidelines into the second year. Therefore, the protocol was amended to permit retreatment at the earliest sign of reaccumulating fluid in the retina, under the retina, or under the RPE. The change in retreatment criteria during the second year was considered to be consistent with the study objective to determine if OCT-guided therapy could minimize the number of injections over 2 years while achieving VA outcomes comparable with the outcomes achieved using monthly injections in the phase III trials.

The final VA outcomes in the PrONTO Study were comparable with the results from the phase III clinical trials.[1,2] The PrONTO outcomes were achieved even though there was a dosing error in the first 18 patients enrolled in the study who received an initial 0.3-mg dose rather than the per-protocol 0.5-mg dose. This dosing error should not have made a difference in light of the similarity in outcomes when the 0.3- and 0.5-mg doses were compared in the phase III trials.

In the MARINA trial, the final mean VA improved by 7.2 letters, and in the ANCHOR trial, the final mean VA improved by 11.3 letters. By comparison, VA in the PrONTO Study improved by 11.1 letters at 24 months with a 95% CI ranging from 7 letters to 15.2 letters, suggesting results comparable with the phase III trial results. Whereas patients in the MARINA and ANCHOR trials received 24 injections over 24 months, the patients in the PrONTO Study received an average of just 9.9 injections with a median of 9.0 injections out of a possible 25 injections over 24 months. Other VA efficacy endpoints were comparable as well. In the MARINA and ANCHOR trials, 94.6% and 96.4% of patients avoided a 15-letter VA decrease, whereas in the PrONTO Study, 97.5% of patients avoided such a loss. In the MARINA and ANCHOR trials, 34% and 40.3% of patients gained at least 15 letters of VA compared with 43% of patients in the PrONTO Study. Finally, when comparing the proportion of patients with 0 or more letters gained at 12 months, the MARINA and ANCHOR studies reported 71.3% and 78%, whereas the PrONTO Study had 78% of patients without any letters lost. The totality of the data from the PrONTO Study suggests that OCT-guided retreatment with ranibizumab seems to be comparable with the VA outcomes from monthly injections; however, a prospective, randomized, double-masked study will be necessary to confirm these conclusions. Currently, the Comparison of AMD Treatment Trials now underway will test whether an OCT-guided variable-dosing regimen is comparable with a fixed monthly dosing regimen with intravitreal ranibizumab.

The retreatment criteria chosen for the PrONTO Study required strict monthly visits and month-to-month comparisons of all 6 OCT radial scans. These criteria were based on careful observations after the completion of the phase I/II ranibizumab studies when patients in the extension study could be treated at the discretion of the investigator. Based on that experience, it was proposed that OCT could detect the earliest signs of recurrent fluid in the macula as soon as ranibizumab therapy had dried the macula. It is important to emphasize that the criteria for retreatment depended on close follow-up with monthly visits and careful examination of all 6 diagonal OCT scans with comparisons with the previous visit's scans to determine if any fluid had persisted or reaccumulated in the macula. It was found that whenever a patient was retreated in the PrONTO Study, regardless of the criteria used, the need for retreatment could have been predicted based on careful assessment of the qualitative OCT findings alone. After publication of the first year's data, some clinicians adopted the PrONTO retreatment criteria without adopting the strict follow-up schedule, without carefully examining all 6 OCT diagonal scans, and without comparing all current scans with the scans from the previous visit. Although it may be possible to base retreatment guidelines on fewer diagonal scans and less frequent follow-up, such a regimen was not tested in the PrONTO Study, and it is not possible to extrapolate the results to other retreatment paradigms.

The PrONTO Study was designed to minimize the number of retreatments but not the number of visits. There are other strategies that may yield similar or even better VA outcomes and that require fewer visits. One such strategy is known as *treat and extend*, which is particularly appealing for use in routine clinical practice.[12] This strategy may minimize the number of clinic visits, but it may not necessarily minimize the number of reinjections. Although a PrONTO-style regimen or a treat-and-extend regimen may differ in the number of retreatments and the number of clinic visits, the overall goal is the same: to optimize VA outcomes while using OCT to maintain a dry macula in order to decrease the overall number of injections compared with monthly dosing.

The correlation between OCT retinal thickness measurements at month 1 and VA outcomes at subsequent

Samsung et al. v. Regeneron IPR2023-00884
Regeneron Pharmaceuticals, Inc. Exhibit 2097 Page 14

time points implies that the initial OCT response is a predictor of future VA improvements. The strength of the correlation is affected by the fluctuations in macular fluid that occur after the third month and the fact that OCT changes are detected before VA is affected. In addition, visual recovery after resolution of macular fluid in neovascular AMD likely depends on many variables including chronicity of disease, viability of photoreceptors and the RPE, progression of the underlying dry AMD (geographic atrophy), as well as the presence of epiretinal membranes, RPE tears, and fibrosis. Despite all these variables, the initial response to ranibizumab characterized by resolution of fluid in the macula as assessed by OCT seems to correlate with future VA improvement and may serve as a useful predictor of treatment efficacy.

In a few patients, the lack of correlation between the change in OCT retinal thickness and the change in VA can be explained by their loss of VA resulting from tears of the RPE, progression of underlying dry AMD, and the occurrence of fibrosis. These patients initially responded to therapy with a decrease in retinal thickness and a decrease in FA leakage, but proceeded to lose vision during the course of the study. This vision loss represents a true treatment failure. Moreover, the cause of this vision loss is unlike the causes of vision loss observed with previous therapies such as thermal laser, verteporfin photodynamic therapy, and pegaptanib sodium, where most of the vision loss was the result of enlarging neovascular lesions, hemorrhage, and fibrosis. For this reason, the term *ranibizumab treatment failure* should be applied to lesions associated with vision loss and not to lesions that require frequent reinjection because there was no correlation between the need for reinjection and VA outcomes.

Although ranibizumab effectively may remove the fluid from the macula and may prevent the growth and leakage of neovascular lesions, the continued progression of the underlying dry AMD explains why some patients experienced little if any VA benefit from therapy, and probably explains why some patients experience continued vision loss over an extended period while receiving ranibizumab therapy. The growth of geographic atrophy measured in the patients with vision loss was within the expected growth rate considered to be consistent with normal disease progression.[9–11] The possibility of a direct neurotoxic effect on the macula by ranibizumab seems unlikely because of absence of decreasing VA outcomes in the MARINA and ANCHOR trials over 2 years, when eyes were subjected to monthly dosing. Therefore, it stands to reason that to avoid treatment failures, therapies that target both the neovascular component and the underlying dry AMD are needed. Without this combination approach, it seems unlikely that any other antiangiogenic therapy will achieve VA outcomes better than the outcomes achieved with ranibizumab therapy alone.

In summary, the PrONTO Study used an OCT-guided variable-dosing regimen with ranibizumab resulting in VA outcomes comparable with those of the phase III studies with monthly dosing while averaging fewer than half the number of injections over 2 years.

THIS STUDY WAS SUPPORTED BY GENENTECH INC, SOUTH SAN FRANCISCO, CALIFORNIA; THE DEPARTMENT OF OPHTHALmology at the Bascom Palmer Eye Institute, Miami, Florida; an Unrestricted Grant from Research to Prevent Blindness Inc, New York, New York; Core Grant No. P30 EY014801 from the National Eye Institute, National Institutes of Health, Bethesda, Maryland; and the German Research Foundation (DFG), Bonn, Germany. Drs Rosenfeld and Fung received research grants from Genentech Inc. Drs Rosenfeld, Fung, Davis, and Michels received clinical research grants from Novartis Ophthalmics, Alcon Laboratories, CoMentis, and Quark. Drs Rosenfeld, Fung, Michels, Davis, and Flynn have participated in competing scientific advisory boards and have received honorarium and reimbursement for travel expenses. Involved in design of study (P.J.R., A.E.F., S.M., M.E.); conduct of study (P.J.R., G.A.L., A.E.F., M.E.); data collection (P.J.R., S.D., J.D., H.W.F.); management (P.J.R., A.E.F., M.E., S.D.), analysis (P.J.R., G.A.L., W.F.), and interpretation of data (P.J.R., G.A.L., W.F.); and preparation (G.A.L., P.J.R., W.F.), review and approval of the manuscript (G.A.L., P.J.R., A.E.F., S.D., S.M., H.W.F., J.D., M.E.). Before the initiation of the study, approval to perform the PrONTO Study was obtained from the FDA and the Institutional Review Board at the University of Miami Miller School of Medicine. The study was registered with www.clinicaltrials.gov (no. NCT00344227). The study was performed in accordance with Health Insurance Portability and Accountability Act regulations.

REFERENCES

1. Rosenfeld PJ, Brown DM, Heier JS, et al. Ranibizumab for neovascular age-related macular degeneration. N Engl J Med 2006;355:1419–1431.
2. Brown DM, Michels M, Kaiser PK, et al. Ranibizumab versus verteporfin photodynamic therapy for neovascular age-related macular degeneration: Two-year results of the ANCHOR Study. Ophthalmology 2009;116:57–65.e5.
3. Boyer DS, Antoszyk AN, Awh CC, Bhisitkul RB, Shapiro H, Acharya NR. Subgroup analysis of the MARINA Study of ranibizumab in neovascular age-related macular degeneration. Ophthalmology 2007;114:246–252.
4. Kaiser PK, Blodi BA, Shapiro H, Acharya NR. Angiographic and optical coherence tomographic results of the MARINA Study of ranibizumab in neovascular age-related macular degeneration. Ophthalmology 2007;114:1868–1875.
5. Kaiser PK, Brown DM, Zhang K, et al. Ranibizumab for predominantly classic neovascular age-related macular degeneration: subgroup analysis of first-year ANCHOR results. Am J Ophthalmol 2007;144:850–857.
6. Regillo CD, Brown DM, Abraham P, et al. Randomized, double-masked, sham-controlled trial of ranibizumab for neovascular age-related macular degeneration: PIER Study year 1. Am J Ophthalmol 2008;145:239–248.

Samsung et al. v. Regeneron IPR2023-00884
Regeneron Pharmaceuticals, Inc. Exhibit 2097 Page 15

7. Fung AE, Lalwani GA, Rosenfeld PJ, et al. An optical coherence tomography-guided, variable-dosing regimen with intravitreal ranibizumab (Lucentis) for neovascular age-related macular degeneration. Am J Ophthalmol 2007;143:566–583.
8. Photodynamic therapy of subfoveal choroidal neovascularization in age-related macular degeneration with verteporfin: one-year results of 2 randomized clinical trials—TAP report 1. Treatment of Age-Related Macular Degeneration with Photodynamic Therapy (TAP) Study Group. Arch Ophthalmol 1999;117:1329–1345.
9. Sunness JS, Bressler NM, Tian Y, Alexander J, Applegate CA. Measuring geographic atrophy in advanced age-related macular degeneration. Invest Ophthalmol Vis Sci 1999;40:1761–1769.
10. Sunness JS, Gonzalez-Baron J, Applegate CA, et al. Enlargement of atrophy and visual acuity loss in the geographic atrophy form of age-related macular degeneration. Ophthalmology 1999;106:1768–1779.
11. Holz FG, Bindewald-Wittich A, Fleckenstein M, Dreyhaupt J, Scholl HP, Schmitz-Valckenberg S. Progression of geographic atrophy and impact of fundus autofluorescence patterns in age-related macular degeneration. Am J Ophthalmol 2007;143:463–472.
12. Spaide R. Ranibizumab according to need: a treatment for age-related macular degeneration. Am J Ophthalmol 2007; 143:679–680.

Samsung et al. v. Regeneron IPR2023-00884
Regeneron Pharmaceuticals, Inc. Exhibit 2097 Page 16

Biosketch

Geeta A. Lalwani, MD, graduated with honors in Chemistry and East Asian Studies from Smith College in 1994 and received her MD from MCP-Hahnemann School of Medicine in 2001, where she was elected into the Alpha Omega Alpha honor society. Dr Lalwani completed her ophthalmology residency at Case Western University and a subsequent fellowship in vitreoretinal surgery at the Bascom Palmer Eye Institute in Miami, Florida. In 2007, she joined the faculty at the Bascom Palmer Eye Institute where she continues clinical research in numerous areas.

Samsung et al. v. Regeneron IPR2023-00884
Regeneron Pharmaceuticals, Inc. Exhibit 2097 Page 17