Romanian Journal of Ophthalmology, Volume 59, Issue 3, July-September 2015. pp:133-136

REVIEW

DIABETIC MACULAR EDEMA

Ovidiu Musat, Corina Cernat, Mahdi Labib, Andreea Gheorghe, Oana Toma, Madalina Zamfir, Ana Maria Boureanu
Central Military Emergency University Hospital „Dr. Carol Davila", Ophthalmology Department, Bucharest, Romania

Correspondence to: Cernat Corina Cristina M.D.
31 Dinicu Golescu Blvd, Floor 4, District 1, Bucharest, Romania
Mobile phone: +40721 567 809, E-mail: corina_crisa@yahoo.com

Accepted: July 15, 2015

Abstract

Diabetic macular edema (DME) remains the most common cause of vision loss among diabetic patients. New understanding of the underlying pathophysiology has interest in the potential benefits of the specific pharmacologic therapy, such as treatment with intraocular steroids, anti-vascular endothelial growth factor (VEGF), and protein kinase C-beta (PKCβ) inhibition. At the last time, laser photocoagulation, according to the guidelines of the Early Treatment of Diabetic Retinopathy Study (ETDRS), continues to be primary standard care treatment in most communities.

Optical coherence tomography (OCT) is very useful in monitoring macular edema progression and response to treatment.

Key words: diabetic macular edema, risk factors, clinical presentations, physiopathology

Definition

Diabetic macular edema (DME) is manifested as retinal thickening caused by the accumulation of intraretinal fluid, primarily in the inner and outer plexiform layers. It is believed to be a result of hyperpermeability of the retinal vasculature. DME can be present with any level of diabetic retinopathy.

ETDRS Criteria for Clinically Significant Macular Edema (CSME)(1):

- Retinal thickening at the center of the macula
- Retinal thickening and/or adjiacent hard exudates at or within 500 μ of the center of the macula (**Fig. 1**)
- An area of retinal thickening greater than or equal to one disc area, any part of which is within 1 disc diameter of the center of the macula

Fig. 1 CSME

Prevalence and incidence [1] [2]

In USA: The WHO (World Health Organization) estimates 15 million DME half

Romanian Society of Ophthalmology
© 2015

Samsung et al. v. Regeneron IPR2023-00884
Regeneron Pharmaceuticals, Inc. Exhibit 2123 Page 1

undiagnosed and 50% of 8 million without eye care, 25-30% risk of vision loss from CSME. International, WHO estimates more than 150 million patients with diabetes worldwide. However, the absolute prevalence of DME might be increasing due to the overall increased prevalence of diabetes in industrialized nations. It is expected that the incidence of DME will decrease as excellent metabolic control is increasingly embraced as a therapeutic goal by patients and health care workers.

Pathology and pathophysiology of dme

Normal retinal circulation is unique: retinal capillaries are non-fenestrated and capillary endothelial cells have tight jonctions; normal capillaries do not leak fluid, blood. There is no lymphatc system in the retina, so in the presence of retinal pathology, leaking fluid can accumulate and cause edema or swelling. Retina responds to ischemia by stimulating growth factors to produce new vessels (called neovascularization).

DME is the result of microvascular changes in diabetes leading to incompetence of vessels, edema. Hypoxic state stimulate VEGF causing more edema.

Thus, 2 key changes occur:

• Vessel permeability

- Damaged endothelial wall becomes more porous

- Vessel leaks fluid, lipids, erythrocytes

- Accumulation of the fluid results in edema (macular edema if located within the central region of the retina)

• Vessel closure

- Supply of oxigen and nutrients are decreased

New fragile growth occurs (secondary to ischemia)

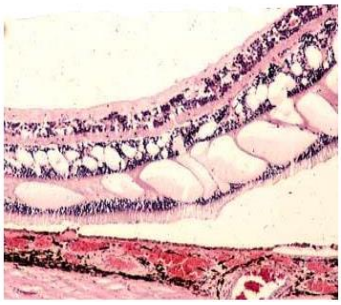

Fig. 2 Photomicrograph of cystoids spaces and subretinal fluid in the retina of a diabetic patient with severe DME

Clinical associations and risk factors

Macular edema is strongly positively associated with diabetic retinopathy severity. Glycemic control is a conclusively identifies risk factor for retinopathy progression as well as for DME. Duration of diabetes is strongly correlated with prevalence and incidence of macular edema, retinopathy progression, and other diabetic complications. The diagnosis of diabetes in type 2 subjects occasionally occurs sometime after subclinical diabetes has been manifest, which yields a small proportion of patients who may present with macular edema at the time of diagnosis, or even have decreased vision from macular edema at the presenting sign. In contrast, persons with type 1 diabetes are very unlikely to experience advanced retinopathy and macular edema before 5 years of duration.

Clinical Associations with Diabetic Macular Edema Severity: [**2**] [**3**]

• Duration of Diabetes – increased risk of diabetic retinopathy

• Glycemic control – The Diabetes Control and Complication Trial (DCCT) clearly demonstrated that tighter control of blood sugar is associated with reduced incidence of diabetic retinopathy (Glycosylated hemoglobin (HbA1c) should be less than 7%)

• Nephropathy – proteinuria is a good marker for development of diabetic retinopathy; thus, patients with diabetic with nephropathy should be observed more closely

• Hypertension – increased risk of retinopathy (diabetic retinopathy with superimposed hypertensive retinopathy)

• Dislipidemia – normalization of lipid levels reduces retinal leakage and exudates deposition

• Pregnancy – diabetic retinopathy can progress rapidly in pregnant women, especially those with preexisting diabetic retinopathy

• Intraocular surgery

• Uveitis

• Panretinal Photocoagulation

Clinical presentation of diabetic macular edema

Patients with DME present with a range of visual symptoms depending on the degree to

Romanian Society of Ophthalmology
© 2015

Samsung et al. v. Regeneron IPR2023-00884
Regeneron Pharmaceuticals, Inc. Exhibit 2123 Page 2

which the fovea is involved and the chronicity of the edema. If the macula center is not involved patients are rarely symptomatic; only a few very observant individuals may notice relative paracentral scotomas corresponding to focal edema and hard exudates. Some patients with central macular involvement have excellent acuity and no visual complains, presumably because of only recent involvement of the center. Over time, patients experience a gradual progressive vision loss over weeks to month. Patients may complain of loss of color vision, poor night vision and washing-out of vision in bright sunlight with poor dark-light adaptation.

Metamorphopsia is not uncommon. Frequently, patients with center involved DME note fluctuation of vision from day-to-day or even over the course of a day. In some cases, the patient may relate such changes to fluid retention, hyper or hypoglycemia, or ambient lighting.[**4**][**5**]

On fundus examination with slit lamp biomicroscopy or contact lens, retinal thickening may present in some commonly identified patterns. Focal edema often occurs associated with a cluster of microaneurysms, sometimes surrounded by an incomplete ring of hard exudates. Diffuse DME may be very difficult to identify clinically if the retina is of uniform thickness, due to the lack of reference landmarks. Clues include the height of the retinal blood vessels over the pigment epithelium, loss of the foveal depression or even cystoids spaces. Other features sometimes seen with macular edema include variable loss of retinal transparency, a large burden of microaneurysms and intraretinal hemorrhages, and dispersed flecks of hard exudates.

Fig.3 Color photograph of a diabetic patient with focal macular edema, with circinate hard exudates roughly circumscribing the area of retinal thickening

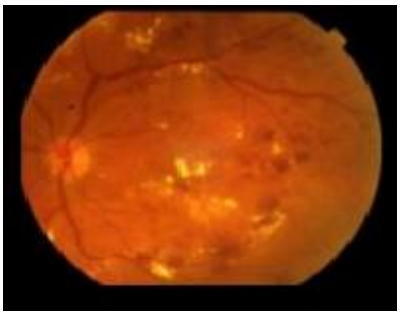

Fig. 4 Color photograph of a diabetic patient with diffuse macular edema

Stereoscopic fundus photographs provide an opportunity to evaluate long-term changes in the retina.

Fluoresceine angiography is useful in demonstrating the breakdown of the blood-retinal barrier by delineating retinal capillary leakage and capillary nonperfusion. Fluorescein angiography is not relevant in aiding in the diagnosis of CSME but should be performed if treatment of CMSE is being considered.

Optical coherence tomography (OCT) is able to demonstrate a moderate correlation between retinal thickness and best corrected visual acuity, and it is able to demonstrate 3 basic structural changes of the retina from diabetic macular edema, that is, retinal swelling, cystoid edema, and serous retinal detachment. OCT is not currently required to establish a diagnosis and is not prescribed by current practice guideline; however, OCT has gained widespread acceptance as an additional modality to help identify and evaluate macular pathology. Quantitative measurement of macular thickness and subjective analysis of the foveal architecture allow a precise and reproducible way to monitor macular edema.

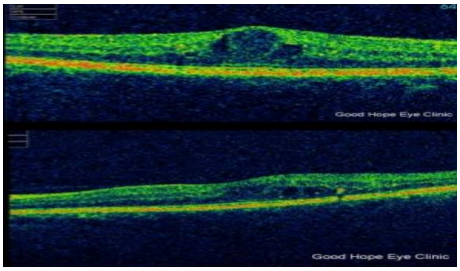

Fig. 5 OCT scan demonstrates cystoid edema

Romanian Society of Ophthalmology
© 2015

Samsung et al. v. Regeneron IPR2023-00884
Regeneron Pharmaceuticals, Inc. Exhibit 2123 Page 3

Treatment

Optimizing diabetic, hypertensive, and lipid control has been shown to positively impact diabetic retinopathy.

The ETDRS conclusively demonstrated that focal/grid laser photocoagulation was safe and effective in reducing vision loss due to DME. Significant visual improvement is uncommon; the goal of macular laser treatment is to reduce progression. [**6**] Photocoagulation reduced the risk of moderate visual loss from diabetic macular edema by 50%, from 24% to 12%, 3 years after initiation of treatment. Laser treatment is most effective when initiated before visual acuity is lost from diabetic macular edema; this emphasizes the need for diligent monitoring and follow-up care. Fluorescein angiography and fundus photos are obtained prior to initiation of laser theraphy. Ophthalmologist views the FA to guide treatment of CSME: for focal leakage, direct laser theraphy using green-only Argon laser is applied to all leaking microaneurysm between 500 and 3000 µm from the center of the macula; for diffuse leakage of capillary nonperfusion adjiacent to the macula, a light-intensity grid pattern using green-only Argon laser is applied to all areas of diffuse leakage more than 500µm from the center of the macula and 500µm from the temporal margin of the optic disc. Multiple sessions spread out over many months are frequently necessary for resolution of DME.

Given the importance of VEGF in vascular permeability and its up regulation in diabetic retinopathy, the rationale for use of anti-VEGF drugs is clear. Current specific anti-VEGF therapy is given intravitreal at frequent intervals, which may temporarily blunt the effects of VEGF and lessen macular edema.

Intravitreal triamcinolone acetonide (IVTA) has been shown to significantly reduce macular edema and to improve visual acuity, particularly when macular edema is pronounced. Some studies advocate IVTA as primary therapy, whereas others label it as adjunctive therapy to macular photocoagulation.[**7**][**8**]

A subset of patients with DME has coexistent epiretinal membranes and/or partial posterior vitreous detachment with retinal traction. These patients may benefit from pars plana vitrectomy to address the mechanical issues contributing to the retinal edema. Even without obvious retinal traction, some clinicians believe that many cases of DME respond to removal of the vitreous, with or without removal of the internal limiting membrane. No large randomized trials have evaluated the treatment to date.[**9**]

The landscape of DME management is rapidly changing with the advent of research advances leading to better understanding of pathophysiologic mechanisms and discovery of potential therapeutic compounds. There are several challenges that remain in bringing forth new treatments with adequate evidence base to guide clinicians in timely patient care.

References

1. Albert and Jakobiec's Principles and Practice of Ophthalmology Third edition, second volume2008, Editura SAUNDERS ELSEVIER, Canada, page 1793 - 1996
2. Pr Gabriel Coscas Oedemes maculaires Aspects cliniques et therapeutiques , Editura Springer Science & Business Media, 15 sept. 2011, Spain, page 110 - 196
3. Oct & Retine dr. Marie – Benedicte Rougier, Pr. Marie – Noelle Delyfer, Pr. Jean- Francois Korobelnik Centre Hospitalier Universitaire de Bordeaux, Editura: Laboratoire Thea, 12 Rue Louise Bleriote, France, page 33- 63
4. 4.Miron Yanoff " Ophtalmology" Fourth Edition, Editura: Elsevier – 2014, London, page: 600 - 715
5. Kanski "Clinical Ophtalmology: a systemic approach" Autor: Brad Bowling, Editura: Elsevier, 2015, page 615-668
6. Abu el Asrar, A. M., & Morse, P. H. (1991). Laser photocoagulation control of diabetic macular oedema without fluorescein angiography. Br J Ophthalmol, 75(2), 97-99, ISSN 0007-1161 (Electronic)
7. Bresnick, G. H. (1983). Diabetic maculopathy. A critical review highlighting diffuse macular edema. Ophthalmology, 90(11), 1301-1317, ISSN 0161-6420 (Electronic)
8. Klein R, Klein BEK, Moss SE, Cruickshanks K: The Wisconsin Epidemiologic Study of Diabetic Retinopathy, XVII: the 14-year incidence and progression of diabetic retinopathy and associated risk factors in type I diabetes. Ophthalmology105:1801–1815, 1998, Editura: Arch Ophthalmology, San Francisco, page : 1801–1815
9. Medical Retina Essentials in Ophthalmology 2007, pp 131-146 Diabetic Macular Edema: Current Treatments.Florian K. P. Sutter, Mark C. Gillies, Horst Helbig Editura: Springer , Berlin Heidelberg NewYork, page 131-146

Romanian Society of Ophthalmology
© 2015

Samsung et al. v. Regeneron IPR2023-00884
Regeneron Pharmaceuticals, Inc. Exhibit 2123 Page 4