European Heart Journal (1992) **13**, 704–708

Transluminal implantation of artificial heart valves. Description of a new expandable aortic valve and initial results with implantation by catheter technique in closed chest pigs

H. R. ANDERSEN*, L. L. KNUDSEN* AND J. M. HASENKAM†

*Departments of *Cardiology, †Thoracic and Cardiovascular Surgery, and the Institute of Experimental Clinical Research, Skejby University Hospital, Aarhus, Denmark*

KEY WORDS: Expandable stent–valve, transluminal implantation, prosthetic heart valve, pigs.

A new artificial aortic valve prosthesis was developed for implantation by the transluminal catheter technique without thoracotomy or extracorporal circulation. The new heart valve was prepared by mounting a porcine aortic valve into an expandable stent. Before implantation, the stent–valve was mounted on a balloon catheter and compressed around the deflated balloon. The stent–valve mounted balloon catheter was then advanced retrogradely to the ascending aorta or the aortic root in anaesthetized pigs. Implantation was performed by balloon inflation which expanded the stent–valve to a diameter exceeding the internal diameter of the vessel — thus ensuring a stable fixation against the vessel wall. A total of nine implantations were performed in seven 70 kg closed chest pigs. Sub- and supracoronary implantation was performed in two and three pigs, respectively, while implantation in both positions was done in two. Angiographic and haemodynamic evaluation after implantation revealed no significant stenosis ($\leqslant$ 16 mmHg) in any of the nine valves and trivial regurgitation in only two. Complications were associated with restriction of the coronary blood flow in three animals. This preliminary study indicates that artificial aortic valves can be implanted in closed chest animals by transluminal catheter technique.

Introduction

In 1952, Hufnagel and Harvey[1] performed the first implantation of a prosthetic heart valve in a patient with severe aortic regurgitation. The artificial valve was implanted in the descending thoracic aorta and prevented severe regurgitation to the left ventricle[2]. This technique was used in small series of operations for aortic regurgitation[3,4]. The development of extracorporal circulation made it possible for Harken *et al.* to perform the first subcoronary implantation in 1960[5], and since then, implantation of prosthetic heart valves has been an open heart surgical procedure. If, however, implantation could be accomplished without thoracotomy, it would be attractive.

In 1989, we constructed a new artificial heart valve designed for implantation by transluminal catheter technique without thoracotomy and heart surgery[6]. This paper describes the new prosthetic heart valve, the implantation technique, and the initial preliminary results with implantation in the sub- and supracoronary position in pigs.

Material and methods

A NEW CONCEPT FOR IMPLANTATION OF ARTIFICIAL HEART VALVES

The idea was conceived of mounting a foldable biological cardiac valve inside a balloon expandable metalic stent. Implantation of such a device (stent + valve = the stent–valve), would enable implantation of artificial heart valves by the transluminal catheter technique.

The stent was constructed of two 0·55 mm surgical stainless steel wires (monofilament), each folded in 15 loops (Fig. 1(a)). Three of the loops were 14 mm high, designed to the commisures of a porcine aortic valve. The remaining loops in the first wire and all the second wire loops were 8 mm high. Each folded wire was bent into a circle (diameter, 22 mm) which was closed end-to-end by soldering. The two circles were then stacked upon each other and interfixed by Merseline 2-0 sutures (Fig. 1(a)).

The foldable valve was a porcine aortic valve taken from a 90 kg slaughtered pig (mixed Danish Landrace and Yorkshire). The aortic valve was carefully dissected and cleaned manually to remove unwanted material. The diameter, thickness, and height of the cleaned valve annulus was 27 mm, 1 mm, and 2 mm, respectively. The height of the three commisural sites were 8 mm.

The stent–valve was prepared by mounting the cleaned aortic valve inside the stent (Fig. 1(b) and (c)). The aortic annulus, which included the three commissural sites, were fixed to the metalic stent by 45–50 Prolene 5-0 sutures. The external diameter of the stent–valve was approximately 12 mm when collapsed (Fig. 1(d) and (e)), and 32 mm when entirely expanded (Fig. 1(f) and (g)). After the stent–valve had been manually compressed on the carrier balloon catheter, the stiffness of the metal prevented it from uncoiling spontaneously (Fig. 1(d) and (e)). After expansion, the stiffness of the metal minimized spontaneous recoil, when the balloon was deflated (Fig. 1(f) and (g)). However, a small recoil (< 10% diameter

Correspondence. Henning Rud Andersen, MD, Department of Cardiology, Skejby University Hospital, Brendstrupgaardsvej, DK-8200 Aarhus N, Denmark.

0195-668X/92/050704 + 05 $03 00/0

© 1992 The European Society of Cardiology

Edwards v. Aortic Innovations
U.S. Patent 11,337,834
Edwards Ex. 1034

Downloaded from https://academic.oup.com/eurheartj/article/13/5/704/514435 by guest on 26 August 2021

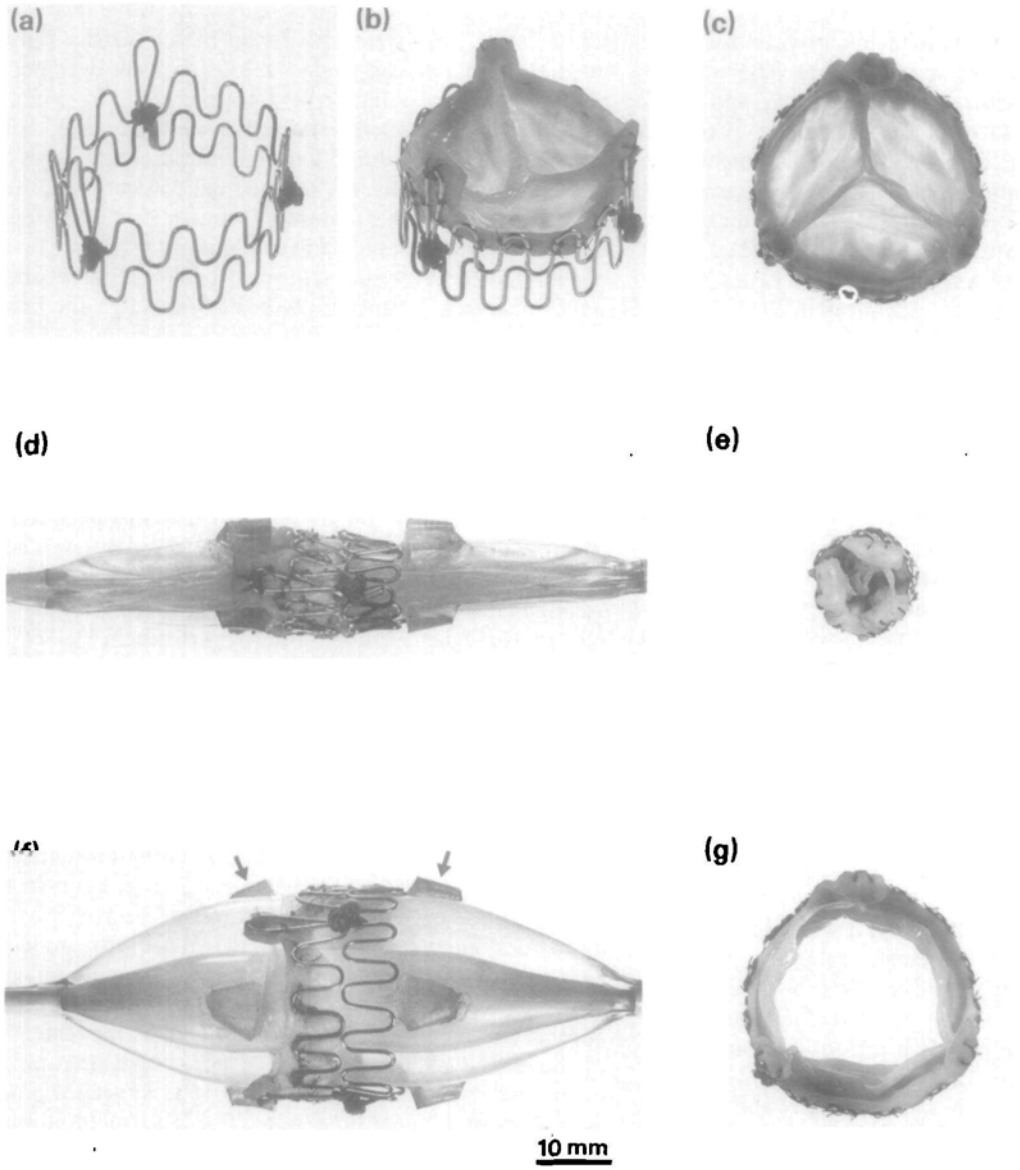

Figure 1 The stent was constructed with two 0·55 mm stainless steel wires folded in 15 loops (a). A three-leaflet porcine aortic valve was mounted inside the stent and fixed to the metal by sutures to form the stent–valve (b) and (c). Before implantation the stent–valve was mounted on a deflated three-foiled balloon dilatation catheter (d). The diameter of the collapsed stent–valve was 12 mm (d) and (e). Balloon inflation expanded the stent–valve to an external diameter of 32 mm (f) and (g). Each of the three balloons were mounted with two elastic blocks (indicated by arrows), to prevent migration of the stent–valve from the middle of the balloons.

reduction) was often seen during balloon deflation. After preparation, the stent–valves were kept frozen (−20 °C) until implantation some days later. Since only acute studies were performed in this initial phase, the valves were neither sterilized, heparinized nor treated by drugs or chemical agents.

The carrier balloon catheter used for implantation was a conventional No. 12 F three-foiled aortic valvuloplasty balloon dilatation catheter (Schneider, Zürich, Switzerland). Each of the three balloons was 70 mm long and had a diameter of 15 mm. The total diameter of the three balloons were 31 mm when inflated. Two soft rubber blocks (3 mm high) were mounted on each of the three balloons, separated by a distance of 18 mm (Fig. 1(d) and (f)). The blocks ensured the stent–valve's stable position in the middle of the balloons, and avoided migration during catheter advancement and balloon inflation. The carrier balloon catheter was mounted in a self-constructed No. 41 F flexible introducer sheath (external diameter 13·6 mm, internal diameter 12·5 mm, length 75 cm). The stent–valve loaded carrier balloon catheter was retracted into the introducer sheath during intravascular introduction and advancement to minimize friction against the vessel wall. A standard guidewire, 300 cm long and 0·9 mm in diameter, was used for conventional catheter-over-guidewire advancement of the carrier balloon catheter.

Downloaded from https://academic.oup.com/eurheartj/article/13/5/704/514435 by guest on 26 August 2021

ANIMAL PREPARATION

Seven pigs weighing 70 kg (mixed Danish Landrace and Yorkshire) were used for implantation. The animals were anaesthetized, endotracheally intubated, and ventilated artificially. Surface ECG and blood pressures were recorded on a Sirecust 961 Monitor (Siemens AG, Erlangen, Germany) and on paper by a Mingograph-62 ink-jet galvanometer recorder (Siemens, Stockholm, Sweden). A No. 9 F introducer sheath was placed in the right carotid artery after surgical exposure of the vessel. A No. 8 F pigtail catheter was advanced to the ascending aorta through the sheath, and used for pressure monitoring and for angiography. After stent–valve implantation, the pigtail catheter was exchanged with a No. 8 F multipurpose coronary arteriography catheter with an open end-hole which was advanced retrogradely through the stent–valve, and used for pressure measurements. A No. 12 F Foley balloon catheter (Rüsch, Kernen, Germany) with a balloon diameter of 40 mm was introduced into a neck vein, and advanced to the pulmonary trunk guided by fluoroscopy. The balloon could be inflated to decrease blood flow through the lungs and consequently through the left ventricle. This was used to minimize the high blood velocities past the valve prosthesis, causing pulsatile movements of the carrier balloon catheter during stent–valve implantation in the heart.

Because the femoral arteries of 70-kg pigs are only 3–4 mm in diameter, retroperitoneal access to the abdominal aorta was made through a midline laparotomy. The aorta was exposed over a distance of 6–7 cm cranial to the renal arteries and cross-clamped proximally and distally. During temporary cross-clamping, a 4 cm long incision enabled a 8–10 cm long vascular prosthesis (diameter 20 mm), to be sutured end-to-side to the aorta at an angle of 45°. The prosthesis was used to gain intravascular access for the No. 41 F introducer sheath. The animals were given no antiplatelet or anticoagulant drugs, and after implantation, angiography and pressure measurements, the pigs were exsanguinated under continuous anaesthesia.

IMPLANTATION OF THE STENT–VALVE

The guidewire was advanced retrogradely into the left ventricle under continuous fluoroscopy, and subsequently, the introducer sheath was advanced over the guidewire into the descending thoracic aorta. The carrier balloon catheter was then pushed out from the sheath and advanced further around the aortic arch. For supracoronary implantation, the stent–valve was positioned just beneath where the right brachiocephalic artery started. For subcoronary implantation the stent–valve was positioned in the aortic root/left ventricular outflow tract beneath the coronary arteries at the level of the native aortic valve. The position of the stent–valve was guided by transthoracic echocardiography and fluoroscopy in the initial four pigs. Due to inaccuracy of echocardiography (heavy echoes from the stent), the implantations in the subsequent three pigs were guided by fluoroscopy and angiography. In these three experiments, ventriculography and aortography were recorded on videotape for immediate playback to guide the stent–valve implantation. When the stent–valve was placed in the right position, implantation (stent–valve expansion) was performed by balloon inflation (4 atmospheres in 15 s) which overdilated (overstretched) the vessel. The elastic recoil of the vessel secured fixation and minimized periprosthetic leakage. Subsequently, the deflated balloon catheter, the guidewire, and the sheath were withdrawn. Two pigs were exposed to double stent–valve implantation with the first one implanted in the supracoronary position; the second stent–valve was advanced retrogradely through the first valve and implanted in the subcoronary position.

MEASUREMENTS AFTER IMPLANTATION

Pressure measurements were performed immediately after implantation. Measurements were obtained during slow withdrawal of the catheter from the left ventricle to the aortic arch distal to the stent–valve. Afterwards, ventriculography and aortography were obtained by contrast injection through the pigtail catheter (Fig. 2). Following exsanguination, the heart and the aorta were excised and gross pathological examination was performed.

Results

THE IMPLANTATION PROCEDURE

The introducer sheath was easily inserted through the vascular prosthesis and advanced to the thoracic aorta guided by fluoroscopy. Before balloon inflation (stent–valve expansion) the carrier balloon was kept easily in a stable position in the blood-stream. When the carrier balloon was inflated, the blood-flow carried it approximately another 3–4 mm distally (downstream). The pulmonary artery balloon was inflated in two pigs, both with subcoronary implantation, because of pulsatile movements of the carrier balloon. The blood-flow could be totally obstructed for a short period (10–15 s, if needed), or decreased for a longer time (min). The latter method was used in two animals (Nos 5 and 6). Seven pigs had nine stent–valves implanted (four in the subcoronary and five in the supracoronary position; Table 1).

HAEMODYNAMICS AND ANGIOGRAPHY

All the animals survived the initial post-implant period; and pressure measurement and angiography was accomplished (Table 1). None of the stent–valves caused severe stenosis and only trivial contrast regurgitation was seen in two pigs (Nos 1 and 3). Left ventricular end-diastolic pressures were unchanged after stent–valve implantation in five out of seven pigs, but increased in two (Nos 3 and 4) due to left ventricular failure caused by restriction of the coronary blood-flow.

ANATOMICAL FINDINGS

All nine prosthetic valves were undamaged by the implantation procedure, and the sutures kept the biological valves inside the stents stable. No haematoma, bleeding or aortic dissection was seen in any of the seven pigs. Four pigs, in which no mechanical complications were

Downloaded from https://academic.oup.com/eurheartj/article/13/5/704/514435 by guest on 26 August 2021

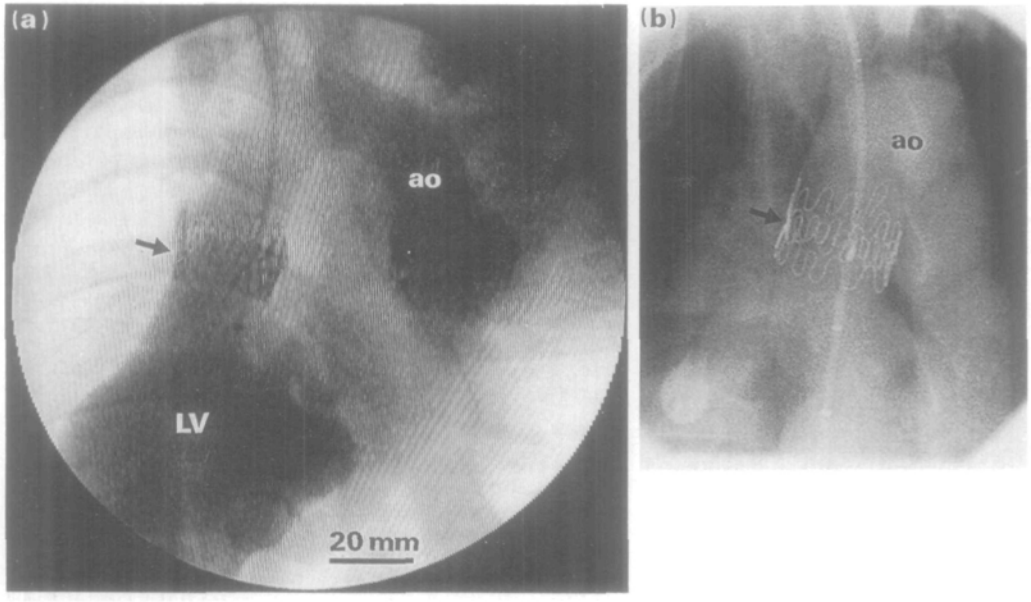

Figure 2 Angiography showing stent–valves (indicated by arrows) implanted in subcoronary position (a) and supracoronary position (b). ao: aorta, LV: left ventricle.

Table 1 Blood pressure measurements following stent–valve implantation

Pig no.	Survival (h)	Site of implantation		Blood pressure (mmHg)			
		Subcoronary	Supracoronary	Left ventricle	Above subcoronary stent–valve	Below supracoronary stent–valve	Above supracoronary stent–valve
1	2·5	+	+	100/0	100/60	100/60	100/60
2	2·5		+	120/7	–	105/75	105/75
3	0·25	+		64/30	60/35	–	–
4	0·25		+	43/18	–	–	40/17
5	1·5	+		150/−5	134/97	–	–
6	2·5	+	+	110/0	100/60	102/58	103/58
7	2·0		+	115/6	–	100/57	100/57

seen, fulfilled the study's protocol. In three animals, the coronary flow was restricted.

With supracoronary implantation, all five stent–valves were fixed in the ascending aorta; the aortic diameter was overstretched by 3–4 mm. Four of the five stent–valves were positioned more than 1·5 cm above the genuine valves; none of the valves obstructed the brachiocephalic artery. In one animal (No. 4), in which the stent–valve was implanted 3 mm above the native aortic valve, the stent–valve was competent, thus leaving only a small volume of blood between the native valve and the stent–valve available for coronary flow in diastole. This caused ST elevation and pump failure. All the stent–valves were competent at inspection and without coagulated blood on the cusps. However, small thrombi were seen on the metal and sutures.

With subcoronary implantation, all stent–valves were implanted at the level of the genuine valves which were completely compressed between the metal stent and the vessel/heart wall. Two of the four stent–valves were implanted beneath the origin of the coronary arteries. The other two (Nos 3 and 5) restricted coronary flow. In pig No. 3, both coronary arteries were obstructed, and the pig died due to pump failure. In pig No. 5 the left coronary ostium was free of the stent–valve, but the right coronary artery was partially obstructed. This animal was haemodynamically stable, but died suddenly from ventricular fibrillation 1·5 h after implantation. Mild regurgitation at aortography was found in two stent–valves. This was caused by tightness of one of the stent-valve cusps in one case (probably caused by the preparation); in the other there was a small paraprosthetic leak.

Discussion

IMPLANTATION OF PROSTHETIC HEART VALVES WITHOUT THORACOTOMY

This paper presents the first description and preliminary results of a new expandable artificial heart valve designed for permanent implantation by transluminal

Downloaded from https://academic.oup.com/eurheartj/article/13/5/704/514435 by guest on 26 August 2021

catheter technique without thoracotomy. Catheter-mounted valves have previously been constructed for short-term treatment of acute aortic insufficiency[7,8]. These devices were mounted on long catheter wires which extended out through the vessel wall. Their position in the bloodstream was secured by external fixation of the extending catheter wires to the skin. Consequently, such valves were not suitable for permanent implantation. In contrast, the new stent–valve is fixed intravascularly at the site of implantation without stent material projecting into the bloodstream or penetrating the vessel wall, thus making it more suitable for permanent implantation.

THE STENT–VALVE

The present devices were self-constructed from available materials. The 0·55 mm wire fulfilled the criteria of minimal spontaneous 'uncoil' and 'recoil' after compression and dilatation. If the metal loops were longer than 8 mm, it was much easier to dilate the stent, but this resulted in larger deformation by the opposing elastic recoil from the vessel and/or the heart. If the loops were smaller, the stent was too stiff to be fully expanded by the balloon. We used biological valves, because they were easy to obtain and mount inside the stent. Other types of foldable valves may also prove suitable, e.g. the tricuspid polyurethane heart valve[9,10].

THE IMPLANTATION PROCEDURE

The extrathoracic approach was mandatory. As femoral arteries are very small in pigs we chose the abdominal aortic route for catheterization. Obviously, the femoral route should be used in humans, preferentially by a percutaneous approach, alternatively by arteriotomy. Implantation was easy in both the ascending and descending aortas[6] where small movements of the carrier balloon catheter were not critical. However, with subcoronary implantation such movements proved to be a problem. A catheter which does not obstruct the blood-flow during stent–valve expansion could be the solution.

LIMITATIONS OF THE STUDY AND FUTURE TECHNICAL DEVELOPMENTS

This is a very preliminary technical study, and many important questions remains to be answered about the stent–valve. Since only acute studies were performed the long-term durability of the valve is unknown. Questions regarding neointimalization, calcification, thrombogenicity, and dislodgement during long-term follow-up should be addressed. There may be a risk of dislodgement and distal migration due to long-term gradual dilation or even necrosis of the portion of the aorta where the valve is implanted. Furthermore, valvular or aortic pathology, such as calcium, vegetative debris, fibrosis, and abscess formation could prevent accurate fixation or become a source of embolization. Thus, many more complex and long-term animal studies must be performed before even speculation concerning clinical use is begun.

POSSIBLE CLINICAL IMPLICATIONS

This preliminary feasibility study cannot clarify the clinical applicability of the stent–valve. However, it might be a treatment for patients with aortic regurgitation who are not candidates for open heart surgery. Implantation of the stent–valve in a supracoronary position may protect the left ventricle from severe regurgitation[1–4].

This study was supported by a grant from the Danish Heart Foundation, Copenhagen, Denmark.

References

[1] Hufnagel CA, Harvey WP. The surgical correction of aortic regurgitation. Preliminary Report, Bull. Georgetown Univ. Med Center 1953; 6: 3–6.
[2] Hufnagel CA. Basic concepts in the development of cardiovascular prostheses. Am J Surg 1979; 137: 285–300.
[3] Hufnagel CA, Harvey WP, Rabil PJ, McDermott TF. Surgical correction of aortic insufficiency. Surgery 1954; 35: 673–83.
[4] Conklin WS, Grismer JT, Aalpoel JA. Hufnagel valve surgery for aortic insufficiency. J Thoracic Surg 1958; 36: 238–46.
[5] Harken DE, Soroff HS, Taylor WJ, Lefemine AA, Gupta SK, Lunzer S. Partial and complete prosthesis in aorta insufficiency. J Thorac Cardiovasc Surg 1960; 40: 744–62.
[6] Andersen HR, Knudsen LL, Hasenkam JM. Transluminal catheter implantation of a new expandable artificial cardiac valve (the stent–valve) in the aorta and the beating heart of closed chest pigs (Abstract). Eur Heart J 1990; 11 (Suppl): 224a.
[7] Boretos JW, Poirer RA. Aortic heart valve catheter. United States Patent (No. 4.056.854), 1977.
[8] Moulopoulos S. Catheter mounted artificial heart valve for implanting in close proximity to a defective natural heart valve. United States Patent (No. 3.671.979), 1972.
[9] Lo HB, Herold M, Reul H *et al.* A tricuspid polyurethane heart valve as an alternative to mechanical prostheses or bioprostheses. Trans Am Soc Artif Intern Organs 1988; 34: 839–44.
[10] Hilbert SL, Ferrans VJ, Tomita Y, Eidbo EE, Jones M. Evaluation of explanted polyurethane trileaflet cardiac valve prosthesis. J Thorac Cardiovasc Surg 1987; 94: 419–29.

Downloaded from https://academic.oup.com/eurheartj/article/13/5/704/514435 by guest on 26 August 2021