Transapical Transcatheter Mitral Valve-in-Valve Implantation in a Human

Anson Cheung, MD, John G. Webb, MD, Daniel R. Wong, MD, MPH, Jian Ye, MD, Jean-Bernard Masson, MD, Ronald G. Carere, MD, and Samuel V. Lichtenstein, MD, PhD

Divisions of Cardiac Surgery and Cardiology, St. Paul's Hospital, University of British Columbia, Vancouver, Canada

We describe a human transcatheter transapical mitral valve implant within a mitral bioprosthesis (valve-in-valve). A high-risk, 80-year-old man with symptomatic bioprosthetic mitral stenosis was positioned for anterior minithoracotomy. Left ventricular apical access was obtained. After balloon valvuloplasty, a cuffed, 26-mm Cribier-Edwards transcatheter valve (Edwards Lifesciences LLC, Irvine, CA) was deployed within the mitral xenograft, using rapid ventricular pacing. The transcatheter valve functioned properly postoperatively; however, the patient died of multiple organ dysfunction.

(Ann Thorac Surg 2009;87:e18–20)
© 2009 by The Society of Thoracic Surgeons

Transcatheter aortic valve implantation, both transfemoral and transapical, has been performed in high-risk patients with native and prosthetic aortic stenosis [1–4]. Transcatheter valves have also been implanted in bioprosthetic mitral valves in swine [5]. We report a transcatheter mitral valve-in-valve implant in a patient.

An 80-year-old man presented with progressive dyspnea. Seven years ago, he underwent mitral valve replacement with chordal preservation using a 25-mm bioprosthesis (Carpentier-Edwards PERIMOUNT Plus 6900P valve; Edwards Lifesciences LLC, Irvine, CA) for degenerative mitral regurgitation (MR), with concomitant coronary artery bypass grafts. Comorbid conditions included previous myocardial infarction, chronic obstructive pulmonary disease, and chronic renal insufficiency (creatinine, 170 μmol/L).

Echocardiography revealed severe prosthetic mitral stenosis (valve area, 0.7 cm^2; mean gradient, 17 mm Hg) with elevated pulmonary artery systolic pressure (90 mm Hg). Ejection fraction was 0.65. The sewing ring inner diameter measured 24 mm by transesophageal echocardiogram (TEE). All bypass grafts were patent.

The Society of Thoracic Surgeons (STS) score predicted a 20.6% risk of death for redo mitral valve replacement, and the patient consented to transcatheter mitral valve-in-valve implantation after twice being refused conventional reoperation. The procedure was approved by the Institutional Review Board.

Concerned about difficulty crossing the stenotic bioprosthesis retrogradely and entanglement within the preserved chords, we first attempted an antegrade approach through the left atrium, using a right anterior minithoracotomy, but were unable to cross the xenograft. This approach was abandoned.

A left anterior minithoracotomy through the sixth intercostal space was centered over the left ventricular (LV) apex. Two pledgetted sutures were placed apically for control. The mitral valve was easily crossed, and the wire was advanced into the pulmonary veins for anchoring. This approach provided a direct shot from apex to valve (Fig 1a).

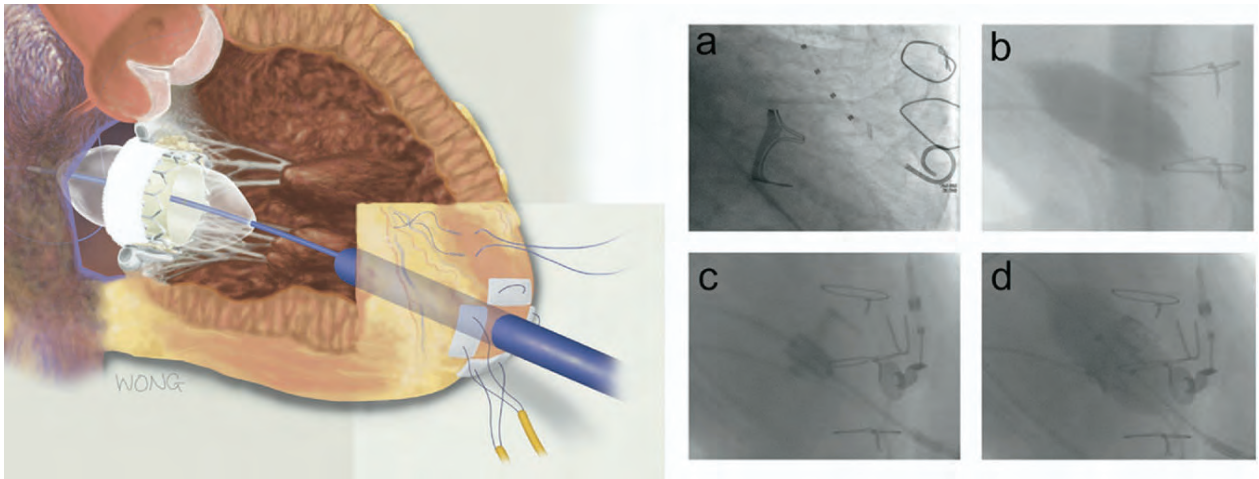

Fig 1. (Left) Technique for transapical mitral valve-in-valve implantation shows the cuffed valve being deployed within the bioprosthesis (cut away). (Panel a) Pigtail catheter in the apex during preoperative angiography. The xenograft commissural posts are marked by the radiopaque nickel-cobalt alloy wire form, with the support ring also visible. Intraoperative fluoroscopy demonstrates (b) balloon valvuloplasty, (c) positioning the transcatheter valve (a few millimeters atrially beyond the support ring), and (d) deployment.

Accepted for publication Oct 8, 2008.

Address correspondence to Dr Cheung, Division of Cardiac Surgery, St. Paul's Hospital, 1081 Burrard St, Vancouver, British Columbia, V6Z 1Y6, Canada; e-mail: acheung@providencehealth.bc.ca.

Dr Cheung discloses that he has a financial relationship with Edwards Lifesciences, Medtronic Inc, Atricure, and St. Jude Medical; Dr Webb with Edwards Lifesciences.

© 2009 by The Society of Thoracic Surgeons
Published by Elsevier Inc

0003-4975/09/$36.00
doi:10.1016/j.athoracsur.2008.10.016

Edwards v. Aortic Innovations U.S. Patent 11,491,033
Edwards Ex. 1017

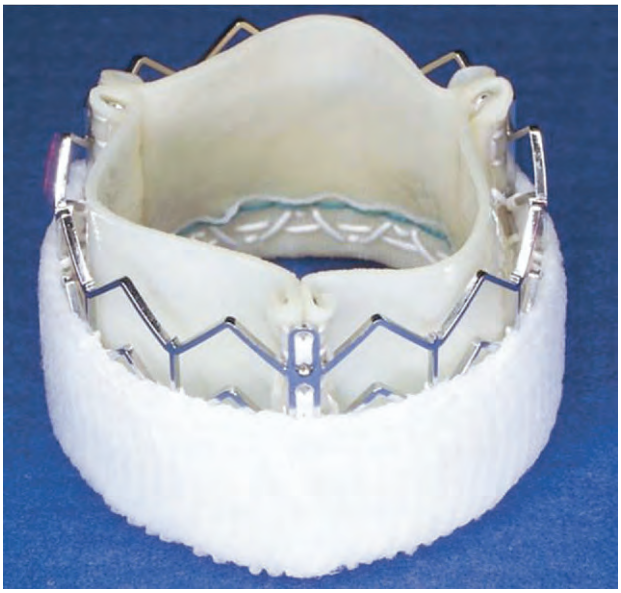

Fig 2. The fabric cuff surrounding the Cribier-Edwards transcatheter valve may provide a better seal for valve-in-valve applications (photograph courtesy of Edwards Lifesciences LLC, Irvine, CA).

After heparinization, mitral balloon valvuloplasty was performed (Fig 1b) with rapid ventricular pacing [6]. A 26-mm Cribier-Edwards 9000MIS (Edwards Lifesciences) transcatheter valve—constructed of equine pericardial leaflets within a stainless steel stent, surrounded by a fabric cuff (Fig 2)—was delivered through a 33F sheath. It was positioned slightly atrially within the mitral bioprosthesis to take advantage of the rigid support ring for secure stent fixation (Fig 1c) and was balloon-deployed during rapid pacing (Fig 1d). Three episodes of ventricular tachycardia required defibrillation.

The postprocedural TEE demonstrated no paravalvular or transvalvular MR, minimal mitral gradient (3 mm Hg), and new LV apical thrombus despite an activated clotting time exceeding 250 seconds. Echocardiography, cardiac catheterization, and fluoroscopy 5 weeks later showed a stable transcatheter valve (Fig 3) that was functioning normally.

The patient awoke neurologically intact and hemodynamically stable, but 3 days later sustained an embolic stroke. The patient recovered neurologically, but pneumonia, sepsis, and multiple organ dysfunction developed. After 47 days, care was withdrawn. No autopsy was performed.

Comment

Mitral valve reoperation is a formidable undertaking [7]. Since the first transcatheter valve procedure [8], expanding applications for this technology have been proposed. The valve-in-valve concept was first demonstrated in swine [5], with the first human aortic valve-in-valve procedure following thereafter [3]. Unlike animal models, human valve-in-valve implants typically are performed many years later; and pannus, leaflet thickening, and calcification may impede xenograft crossing, limit full valve-stent expansion, contribute to paravalvular or transvalvular leaks, and increase the likelihood of embolization of particulate matter or even the valve itself. Our patient's stroke may have been caused by such embolization, although the apical thrombus was more likely the source despite standard precautions including heparinization. We have not previously seen apical thrombus in our transcatheter experience, although strokes occurred in 4%.

Case selection remains crucial. The transapical approach offers direct access with excellent device stability. Nevertheless, future attempts at an antegrade approach through the lower-pressure chamber may still be warranted.

Valve-in-valve procedures differ from implants in native valves because the rigid xenograft substitutes for the leaflet and annular calcification required for stability while providing a ready fluoroscopic landing marker, simplifying positioning. Although acoustic shadowing can hinder echocardiographic visualization, in our experience this did not hamper positioning. The nondistensible support ring especially necessitates accurate sizing of the Edwards valve, currently only available in 23- and 26-mm models. We used a cuffed device for the valve-in-valve implant to provide a better seal within the rigid support ring, minimizing paraprosthetic leak.

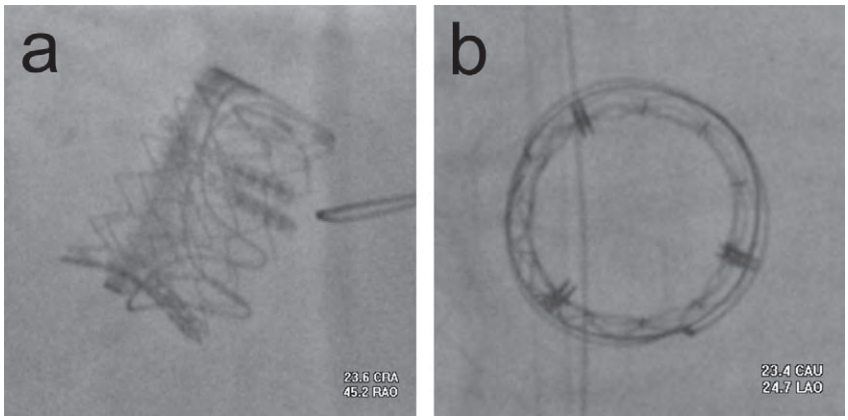

Fig 3. The transcatheter mitral valve-in-valve viewed by cineangiography 5 weeks postoperatively shows (a) lateral view and (b) coaxial view.

Valve-in-valve procedures may increasingly supplant conventional redo valve procedures, even among lower-risk patients. Furthermore, transcatheter valves may be deployed within transcatheter valves, eliminating the need for repeat reoperations. These developments may mark a tipping point toward increased use of bioprosthetic valves and a pivotal change in the management of valvular disease.

References

1. Lichtenstein SV, Cheung A, Ye J, et al. Transapical transcatheter aortic valve implantation in humans: initial clinical experience. Circulation 2006;114:591–6.
2. Webb JG, Chandavimol M, Thompson CR, et al. Percutaneous aortic valve implantation retrograde from the femoral artery. Circulation 2006;113:842–50.
3. Walther T, Kempfert J, Borger MA, et al. Human minimally invasive off-pump valve-in-a-valve implantation. Ann Thorac Surg 2008;85:1072–3.
4. Webb JG. Transcatheter valve in valve implants for failed prosthetic valves. Catheter Cardiovasc Interv 2007;70:765–6.
5. Walther T, Falk V, Dewey T, et al. Valve-in-a-valve concept for transcatheter minimally invasive repeat xenograft implantation. J Am Coll Cardiol 2007;50:56–60.
6. Webb JG, Pasupati S, Achtem L, Thompson CR. Rapid pacing to facilitate transcatheter prosthetic heart valve implantation. Catheter Cardiovasc Interv 2006;68:199–204.
7. Jamieson WR, Burr LH, Miyagishima RT, et al. Reoperation for bioprosthetic mitral structural failure: risk assessment. Circulation 2003;108(suppl 1):II98–102.
8. Cribier A, Eltchaninoff H, Bash A, et al. Percutaneous transcatheter implantation of an aortic valve prosthesis for calcific aortic stenosis: first human case description. Circulation 2002; 106:3006–8.