Catheterization and Cardiovascular Interventions 75:295–300 (2010)

Current Balloon-Expandable Transcatheter Heart Valve and Delivery Systems

Fabian Nietlispach, MD, Namal Wijesinghe, MD, David Wood, MD, Ronald G. Carere, MD, and John G. Webb,* MD

Objectives: Transcatheter valve and valve delivery systems are undergoing rapid evolution. We describe the current generation balloon-expandable valve and delivery systems. Background and Methods: The SAPIEN XT valve represents the newest generation balloon-expandable aortic bioprosthesis. A cobalt-chromium alloy frame and additional design modifications facilitate a reduction in delivery profile while maintaining structural integrity, hemodynamics, and durability. The RetroFlex 3™ delivery system represents the latest clinically available delivery system. It incorporates a fixed, tapered, and deflecting crossing tip to facilitate atraumatic introduction and a rapid inflation lumen to reduce valve motion during deployment. The NovaFlex™ delivery system represents the next generation delivery catheter. When used in conjunction with the SAPIEN XT™ valve and a specially constructed introducer sheath the inner and the outer diameters are 18 and 21 F, respectively. Results: The RetroFlex 3 delivery system was utilized in nine patients and the NovaFlex delivery system in four. The valve implanted was the SAPIEN in six and the SAPIEN XT valve in seven. Implantation was successful in all patients. A reduction in device movement during balloon deployment was apparent as compared with earlier delivery systems. Aortic mean gradient fell from 45.6 (±15.1) mm Hg to 13.2 (±5.1) mm Hg, valve area rose from 0.68 (±0.19) to 1.5 (±0.28) cm^2. No patient had more than mild paravalvular regurgitation. Conclusion: Transcatheter valves and delivery systems continue to improve in terms of profile and ease of use. © 2009 Wiley-Liss, Inc.

Key words: transcatheter heart valve; SAPIEN XT; RetroFlex; NovaFlex

INTRODUCTION

Transfemoral aortic valve implantation (TAVI) may offer clinical benefit to patients not well suited to conventional surgery [1–8]. New developments in delivery systems and valve technologies may make the procedure safer, thereby paving the way for a broader application of transfemoral aortic valve implantation. We describe the current developments in balloon-expandable transcatheter heart valve and valve delivery systems.

METHODS

Patients

Patients with severe symptomatic aortic stenosis were eligible for transarterial aortic valve replacement if the risk of conventional open-heart aortic valve replacement was considered excessive by a consensus group of cardiologists and heart surgeons. All patients signed an informed consent. Patients included in The PARTNER Trial (randomized, controlled) were excluded from this analysis. A minimal femoral arterial diameter of 7 mm for the 22 F and 8 mm for the 24 F RetroFlex 3 system and 6 mm for the 18 F and 6.5 mm for the 19 F NovaFlex system were required.

Procedure

The basic TAVI procedure has been described elsewhere [1]. General anesthesia and preimplantation balloon valvuloplasty were routine [9]. A percutaneous

Department of Cardiology, St. Paul's Hospital, Vancouver, British Columbia, Canada

Conflict of interest: Dr. John G. Webb is a consultant to Edwards Lifesciences Inc.

Grant sponsor: Dr. Fabian Nietlispach receives an unrestricted grant from the Swiss National Research Foundation (Bern, Switzerland).

*Correspondence to: John G. Webb, MD, Department of Cardiology, St. Paul's Hospital, 1081 Burrard Street, Vancouver, British Columbia, Canada V6Z 1Y6. E-mail: webb@providencehealth.bc.ca

Received 2 September 2009; Revision accepted 3 September 2009

DOI 10.1002/ccd.22279
Published online 2 November 2009 in Wiley InterScience (www.interscience.wiley.com)

© 2009 Wiley-Liss, Inc.

Edwards v. Aortic Innovations
U.S. Patent 11,491,033
Edwards Ex. 1036

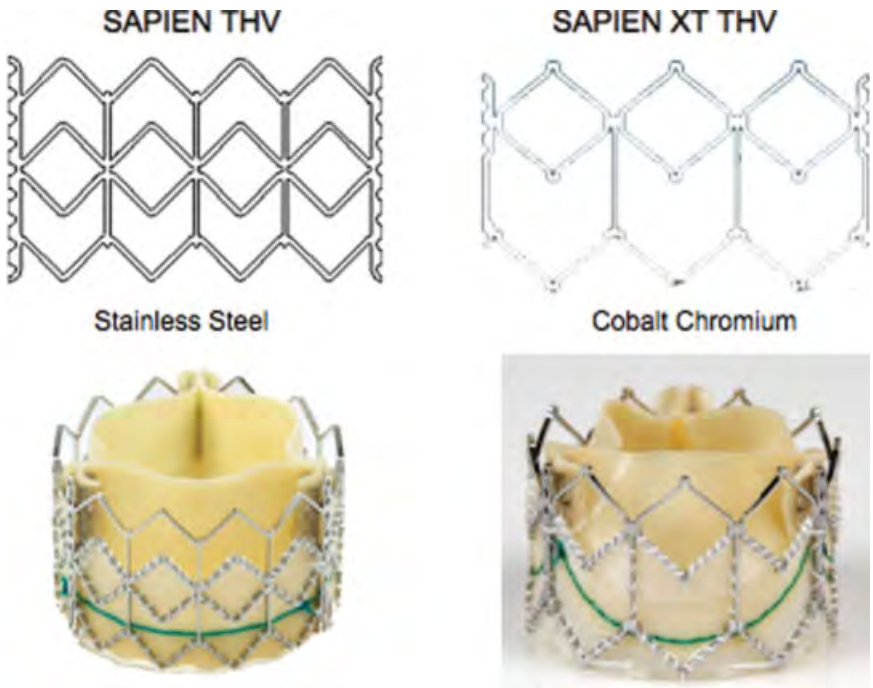

Fig. 1. The new design of the SAPIEN XT valve (right) as compared with the former SAPIEN valve (left). Top: Diagrammatic illustration of the stent struts. Bottom: Example of the valve consisting of the stent, the valve leaflets, and the sealing cuff.

femoral arterial sheath allows introduction of the delivery system into the descending aorta. Flexion of the delivery catheter tip facilitates atraumatic passage through the aortic arch and stenotic native valve. The delivery catheter is withdrawn to the ascending aorta to fully expose the deployment balloon during expansion. The valve is deployed during rapid pacing. Finally the delivery system was retrieved and femoral access site closed, either utilizing previously inserted percutaneous sutures (ProGlide™ and Prostar™, Abbott Vascular, Abbott Park, IL) or by surgical cutdown.

SAPIEN XT Valve

The new valve consists of bovine pericardial leaflets, a cobalt-chromium frame and a sealing cuff on the inflow aspect of the stent to prevent paravalvular regurgitation [10] (Fig. 1). As with the preceding SAPIEN valve, the bovine pericardium utilized undergoes a proprietary anti-calcification treatment (Thermafix™). Tissue leaflets are matched for thickness and deflectability. New scallop-shaped leaflets are attached to the frame in a crown-like manner (Fig. 1), resulting in superior hemodynamic properties and reduced shear stress. The leaflets of the SAPIEN XT valve are semi-closed when in the neutral position, as compared with fully open position in previous iterations. This semi-closed position decreases time and pressure required to close the leaflets. By further increasing coaptation of the leaflet tips, the potential for transvalvular regurgitation is reduced. The redesigned frame incorporates a more open design and a reduction in strut thickness. Stainless steel utilized in the SAPIEN valve is now replaced with a stronger cobalt-chromium alloy (Fig. 1). The design and the material allow for tighter crimping of the valve, without loss of stability or radial force. The SAPIEN XT aortic valve will be available in four sizes: 20, 23, 26, and 29 mm external diameter valves. It is slightly longer than the previous SAPIEN valve.

RetroFlex 3

The RetroFlex delivery system family is comprised of three generations. All consist of a delivery sheath and a deflectable catheter with the SAPIEN valve crimped onto an inflatable balloon. With RetroFlex 1 (Fig. 2a), the inflatable balloon with the valve frame formed the leading tip. With RetroFlex 2 (Fig. 2b), a moveable nosecone was introduced. This was separate from, and during introduction covered the distal balloon catheter, requiring a mechanism to advance and retract the nosecone before and after valve deployment. With RetroFlex 3 (Fig. 2c), a fixed crossing tip was incorporated into the balloon catheter. The RetroFlex 3 delivery catheter allows introduction of the SAPIEN 23 or 26 mm valve through 22 and 24 French sheaths,

Fig. 2. Evolution of the RetroFlex™ balloon-expandable valve. (A) RetroFlex 1. (B) RetroFlex 2 incorporated a conical retractable nosecone to facilitate atraumatic passage through the aorta and the native valve. (C) RetroFlex 3: A shorter fixed crossing tip improved ease of use and reduced the risk of ventricular injury.

respectively. The lower profile of the SAPIEN XT allows introduction through 20 and 22 French sheaths, respectively.

NovaFlex

The NovaFlex delivery system allows for a reduction in sheath size to 18 French (for the 23 mm valve; 19 French for the 26 mm valve). The smaller diameter allows use in patients with smaller diameter iliofemoral arteries: 6 mm for the 18 French and 6.5 mm arterial diameter for the 19 French system (Fig. 3).

The delivery catheter incorporates an outer deflectable catheter and an inner balloon catheter with a tapered crossing tip. The valve itself is crimped on the inner catheter proximal to the inflatable balloon (Fig. 4). This reduces the maximal diameter of the delivery catheter and allows for a reduction in sheath size. Once the delivery catheter and prosthesis have been passed through the femoral sheath, the two must be aligned in the descending aorta. The inner balloon catheter is withdrawn back into the outer catheter, while maintaining wire position. The outer catheter then advances the prosthesis distally on the inner catheter shaft and onto the balloon. Optimal alignment of the stent on the balloon is indicated when the frame is



Fig. 3. Reduction in sheath size from 22 French (right) to 18 French (left) for the 23 mm valve.

Fig. 4. The NovaFlex™ delivery system with the valve (striped arrow) crimped proximal to the inflatable balloon (black arrow) catheter.

positioned between the two fluoroscopic markers (Fig. 5). Imaging in a fluoroscopic view perpendicular to the markers is important for accurate positioning. Advancing the prosthesis too distally is prevented by a slightly larger distal tip of the balloon catheter (Fig. 6). Fine adjustment is achieved by turning a valve alignment wheel situated on the handle of the delivery system. The remaining procedural steps are then the same as for the RetroFlex 3 system.

Both the RetroFlex 3 and the NovaFlex systems incorporate a larger inflation lumen to facilitate more rapid balloon inflation. Both systems tend to inflate the distal (ventricular) end of the balloon before the proximal (aortic) end of the balloon (Fig. 7), as opposed to previous systems, leading to increased valve stability during inflation.

Statistical Analysis

Numerical variables are presented as means and standard deviation (SD), whereas ordinal data are presented as medians and interquartile ranges (IQR). Comparison of these variables was done using the student's *t*- and the Mann-Whitney-test as appropriate. A P value of ≤ 0.05 was considered statistically significant.

RESULTS

The cohort consisted of 16 patients. Mean age was 82 ± 10 years, 62.5% were male, mean STS risk score

Fig. 5. Fluoroscopic markers at the catheter tip indicate the correct valve position on the balloon. Left: valve exiting the sheath. Middle: valve halfway advanced. Right: after correct alignment with the valve positioned between the two markers.

was 9% ± 5.7% and logistic EuroSCORE was 19.5% ± 14%. Mean left ventricular ejection fraction was 57% ± 15%. Comorbidities included MR grade ≥3 in 31.25%, porcelain aorta in 12.5%, prior cardiac surgery in 31.25%, and severe COPD in 18.75% of paients.

The SAPIEN XT valve was used in seven patients. In the initial three patients, the delivery system used was RetroFlex 2, and in the other four patients, the SAPIEN XT valve was used on the NovaFlex. The RetroFlex 3 system was used in nine patients together with the SAPIEN valve. All procedures were successful with a functioning valve implanted within the annulus. Coronary obstruction, valve embolization, major vascular injury requiring surgery (other than surgical closure of the puncture site), and major bleeding did not occur. There were no intraprocedural deaths.

In one patient a RetroFlex 3 system with a SAPIEN valve was positioned too low within the aortic annulus resulting in poor sealing. Severe paravalvular regurgitation required temporary transfemoral extracorporal bypass on the contralateral leg. A second valve was implanted within the first (valve-in-valve), but slightly higher to as to improve annular sealing. Paravalvular regurgitation was reduced to mild. The patient was immediately weaned from support and remains well.

Post-dilatation of the valve was performed in four patients because of a grade 2 paravalvular leak, with a reduction in regurgitation to grade 1 in all. At the completion of the procedure paravalvular regurgition was grade 0–1 in eight patients and grade 2 in eight patients. No patient was left with ≥grade 3 paravalvular regurgitation. Final median paravalvular regurgitation was grade 1 (IQR: 0.75–2). No patient had more than trivial transvalvular regurgitation. Echocardiographic transaortic gradient decreased from 40 (±18) mm Hg to 12 (±5) mm Hg ($P < 0.05$) and mean aortic valve area increased from 0.7 (±0.1) to 1.5 (± 0.3) cm^2 ($P < 0.05$).

Fig. 6. Outer catheter shaft with its flex catheter tip, enables advancing of the valve.

Technical Observations

Balloon inflation appeared to occur more rapidly with the RetroFlex 3 and NovaFlex systems as compared with earlier delivery systems. Moreover, balloon expansion generally begins distal (ventricular) to the prosthesis first, followed by expansion proximal (aortic) to the prosthesis and finally by expansion of the central portion of the balloon. The result is initial expansion of the prosthesis within the left ventricular outflow tract (LVOT). This is the opposite of what occurred with earlier delivery systems. Presumably as a consequence a reduction in movement of the prosthesis during balloon expansion was observed in comparison with earlier delivery systems (Fig. 7).

DISCUSSION

These new technologies aim to improve ease of use, reduce procedural complications, improve clinical outcomes, enhance durability, and expand the population of patients in whom this therapy can be applied.

Vascular and bleeding complications have been a major concern limiting wider application of TAVI [3,11,12]. Early balloon-expandable transcatheter devices were 26 French, generally requiring surgical cutdown or transvenous access [5,8,13]. Subsequently, the

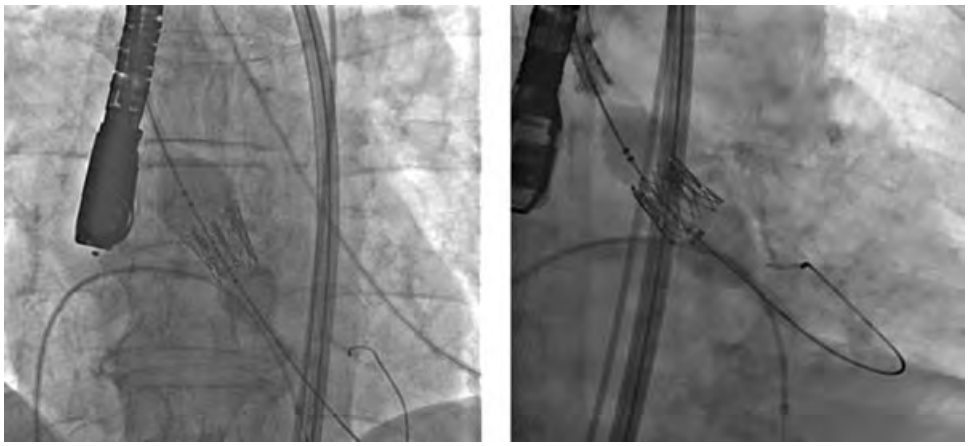

Fig. 7. Balloon expansion during inflation: Expansion begins in the distal part with earlier generations of delivery systems (left), as compared with later generations (RetroFlex 3, NovaFlex) where expansion begins in the LVOT (right).

Retroflex 1 system allowed a profile reduction to 22 or 24 French for the 23 mm and 26 mm valves, respectively [1]. Addition of the SAPIEN XT valve on the NovaFlex delivery system allows a further reduction in internal sheath diameter to 18 French and 19 French, respectively. The low mean minimal arterial diameter of 6.2 mm $\pm$ 4 mm in the low-profile NovaFlex cohort demonstrates the ability to push the boundaries of acceptable arterial anatomy further than previously. Although this experience is small, the absence of major vascular complications and major bleeds is encouraging.

Positioning of balloon-expandable valves at the time of deployment has been problematic. Generally balloon expansion is associated with movement of the prosthesis toward the aorta despite rapid pacing. The amount of this movement averages 1–3 mm, however, this is variable in individual patients [9]. It appears that this movement is reduced and placement is more predictable with the newer delivery systems (RetroFlex 3 and NovaFlex). With the first generation delivery system (RetroFlex 1), initial balloon expansion occurred proximal to the prosthesis (aortic). The prosthesis would tend to contact and fix the native leaflets. As these folded up into the native sinuses, the prosthesis was to a variable extent lifted up as well. In contrast, the new design tends to result in balloon expansion being initiated distally (ventricular). As the prosthesis expands distally, it first contacts the outflow tract, rather than the leaflets. Subsequently, proximal (aortic) expansion is less likely to result in movement in the direction of blood flow and the native leaflets. Presumably more rapid balloon inflation due to the larger inflation lumen helps.

Reduced and more predictable movement of the prosthesis during expansion has implications for positioning during deployment. Valves positioned low within the outflow tract are vulnerable to poor sealing and regurgitation and may require a second valve. By implication, valves may have to be positioned slightly more toward the aorta than previous experience with older delivery systems has suggested. Although minor adjustments in technique may be required, a more predictable end result is obviously desirable.

CONCLUSION

Newer valves and delivery systems may offer incremental benefits and increase the potential for broader application of transfemoral transcatheter aortic valve implantation.

REFERENCES

1. Webb JG, Chandavimol M, Thompson CR, Ricci DR, Carere RG, Munt BI, Buller CE, Pasupati S, Lichtenstein S. Percutaneous aortic valve implantation retrograde from the femoral artery. Circulation 2006;113:842–850.
2. Webb JG, Pasupati S, Humphries K, Thompson C, Altwegg L, Moss R, Sinhal A, Carere RG, Munt B, Ricci D, Ye J, Cheung A, Lichtenstein SV. Percutaneous transarterial aortic valve replacement in selected high-risk patients with aortic stenosis. Circulation 2007;116:755–763.
3. Webb JG, Altwegg L, Boone RH, Cheung A, Ye J, Lichtenstein S, Lee M, Masson JB, Thompson C, Moss R, Carere R, Munt B, Nietlispach F, Humphries K. Transcatheter aortic valve implantation: Impact on clinical and valve-related outcomes. Circulation 2009;119:3009–3016.
4. Descoutures F, Himbert D, Lepage L, Iung B, Detaint D, Tchetche D, Brochet E, Castier Y, Depoix JP, Nataf P, Vahanian A. Contemporary surgical or percutaneous management of severe aortic stenosis in the elderly. Eur Heart J 2008;29:1410–1417.

5. Grube E, Laborde JC, Zickmann B, Gerckens U, Felderhoff T, Sauren B, Bootsveld A, Buellesfeld L, Iversen S. First report on a human percutaneous transluminal implantation of a self-expanding valve prosthesis for interventional treatment of aortic valve stenosis. Catheter Cardiovasc Interv 2005;66:465–469.
6. Grube E, Schuler G, Buellesfeld L, Gerckens U, Linke A, Wenaweser P, Sauren B, Mohr FW, Walther T, Zickmann B, Iversen S, Felderhoff T, Cartier R, Bonan R. Percutaneous aortic valve replacement for severe aortic stenosis in high-risk patients using the second- and current third-generation self-expanding CoreValve prosthesis: Device success and 30-day clinical outcome. J Am Coll Cardiol 2007;50:69–76.
7. Piazza N, Grube E, Gerckens U, den Heijer P, Linke A, Luha O, Ramondo A, Ussia G, Wenaweser P, Windecker S. Procedural and 30-day outcomes following transcatheter aortic valve implantation using the third generation (18 Fr) corevalve revalving system: Results from the multicentre, expanded evaluation registry 1-year following CE mark approval. EuroIntervention 2008;4:242–249.
8. Cribier A, Eltchaninoff H, Tron C, Bauer F, Agatiello C, Sebagh L, Bash A, Nusimovici D, Litzler PY, Bessou JP, Leon MB. Early experience with percutaneous transcatheter implantation of heart valve prosthesis for the treatment of end-stage inoperable patients with calcific aortic stenosis. J Am Coll Cardiol 2004;43:698–703.
9. Webb JG, Pasupati S, Achtem L, Thompson CR. Rapid pacing to facilitate transcatheter prosthetic heart valve implantation. Catheter Cardiovasc Interv 2006;68:199–204.
10. Webb JG, Altwegg L, Masson JB, Al Bugami S, Al Ali A, Boone RA. A new transcatheter aortic valve and percutaneous valve delivery system. J Am Coll Cardiol 2009;53:1855–1858.
11. Cubeddu RJ, Jneid H, Don CW, Witzke CF, Cruz-Gonzalez I, Gupta R, Rengifo-Moreno P, Maree AO, Inglessis I, Palacios IF. Retrograde versus antegrade percutaneous aortic balloon valvuloplasty: Immediate, short- and long-term outcome at 2 years. Catheter Cardiovasc Interv 2009;74:225–231.
12. Ree RM, Bowering JB, Schwarz SK. Case series: Anesthesia for retrograde percutaneous aortic valve replacement–experience with the first 40 patients. Can J Anaesth 2008;55:761–768.
13. Cribier A, Eltchaninoff H, Bash A, Borenstein N, Tron C, Bauer F, Derumeaux G, Anselme F, Laborde F, Leon MB. Percutaneous transcatheter implantation of an aortic valve prosthesis for calcific aortic stenosis: First human case description. Circulation 2002;106:3006–3008.