J591

ISSN 0021-9509
J Cardiovasc Surg

VOL. 28 - No. 5
SEPTEMBER-OCTOBER 1987

The Journal of Cardiovascular Surgery

OFFICIAL JOURNAL OF THE INTERNATIONAL SOCIETY FOR CARDIOVASCULAR SURGERY



Published by Minerva Medica

Edwards v. Aortic Innovations
U.S. Patent 11,491,033
Edwards Ex. 1111

A collagen coated vascular prosthesis

Stewart M. Scott, M.D., Lee R. Gaddy, B.A., Reinhart Sahmel, M.D., and Harmon Hoffman, Ph.D.*

From the Division of Cardiovascular and Thoracic Surgery,
Veterans Administration Medical Center, Asheville, North Carolina, U.S.A.

SUMMARY.—A woven, double velour Dacron vascular graft was made nonporous by coating it with a layer of collagen prepared from fresh, young calf skin. Grafts were implanted in the thoracic aorta of 24 mongrel dogs and were examined at intervals up to 180 days. The grafts did not require preclotting or special preparation before being implanted. They sutured easily and did not bleed. When explanted all grafts were patent and covered with neointima. The bovine collagen was almost completely resorbed by 90 days and was replaced with native tissue. The collagen was neither thrombogenic, antigenic, cytotoxic, or pyrogenic.

KEY WORDS.—Collagen - Vascular prostheses - Grafts.

Blood loss through vascular prostheses can be controlled by using tightly woven or nonporous fabrics, by preclotting grafts with autologous blood, or by coating porous prostheses with absorbable materials. An absorbable material which has been used to control the porosity of vascular grafts is collagen.[1 2] Collagen tubes have been used as vascular grafts in the past with varying degrees of success.[3-10] Many forms of collagen tend to be thrombogenic and this unfortunate trait has limited the usefulness of some of the older collagen prostheses.[9] More recently, it has been observed that thrombogenicity and other characteristics can be altered by crosslinking collagen with naturally occurring mucopolysaccharides.[11] Collagen can also be crosslinked by reaction with selected chemical agents. The result is a blood compatible substance which can be used as a bioimplant.

Much of our knowledge about collagen is recent. Collagen is a protein found primarily in the extracellular matrix. It accounts for approximately one third of total body protein. The collagen molecule is unlike other protein molecules. It is a complex triple helix composed of three alpha chains of some 20 or more amino acids with glycine occupying every third position on each chain and with proline and hydroxyproline accounting for about twenty percent of the amino acid content. Hydroxyproline rarely occurs in any other protein.[12] Five different types of collagen which can be distinguished by their molecular structure have been identified and characterized (Table 1).[13] The most common collagen is the type I. The material used in this study is a type I collagen derived from fresh young calf skin.

In this study, Dacron grafts coated with crosslinked bovine collagen were evaluated for use as vascular prostheses.

Material and methods

Vascular prostheses. All vascular prostheses were designed and prepared by Meadox Medicals, Inc. The collagen was prepared from young bovine skin by a sequence of steps including mechanical cleaning, washing, and chemical treatment. The processed skin was finally homogenized to produce an off-white paste composed primarily of collagen microfibers. The processed material, containing over 90% pure collagen, passed all of the basic requirements for an implant material including pyrogenicity, cytotoxicity and antigenicity.[14]

*Meadox Medicals, Inc, Oakland, New Yersey, U.S.A.

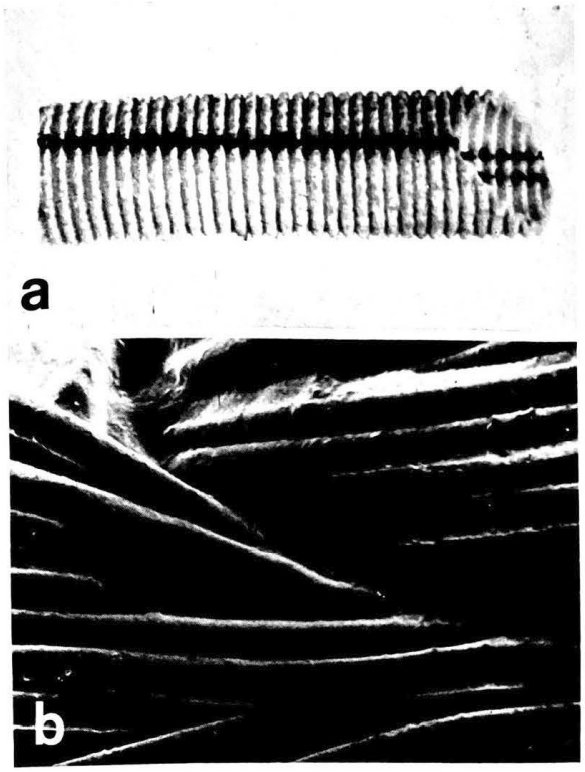

Fig. 1.—(A) A woven double velour Dacron polyester graft coated with bovine collagen. (B) Scanning electron microscopy of graft in 1A. A thin layer of collagen completely covers the fibers and interstices of the fabric (500×).

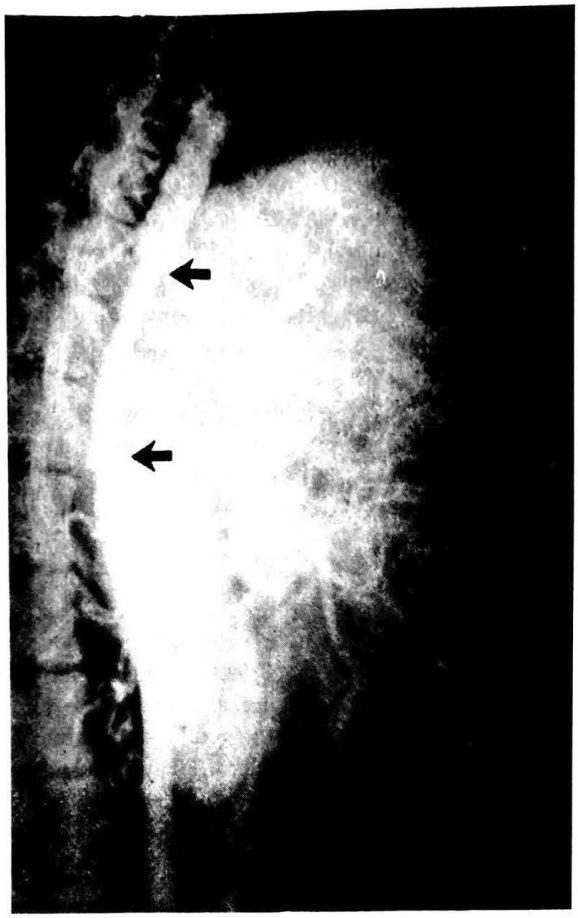

Fig. 2.—Aortogram showing a 8 mm collagen coated woven double velour Dacron graft in a dog's descending thoracic aorta.

TABLE 1.—*Collagen types and distributions.*

Collagen	α chains	Molecular species	Tissue
Type I	α1(I), α2(I)	$[\alpha1(I)]_2\,\alpha2(I)$, $[\alpha1(I)]_3$	Bone, cornea, dentin, fibrocartilage, tendon (>95%). Dermis, gingiva, heart valve (85%). Intestinal, large vessel, and uterine wall (50-60%).
Type I-trimer	——	——	Dentin, dermis, tendon (<2-3%).
Type II	α1(II)	$[\alpha1(II))]_3$	Notochord, nucleus pulposus, hyaline cartilage, vitreous (>95%).
Type III	α1(III)	$[\alpha1(III)]_3$	Intestinal, large vessel, and uterine wall (35-45%). Dermis, gingiva, heart valve (10-15%).
Type IV	α1(IV), α2(IV)	$[\alpha1(IV)]_3$ $[\alpha2(IV]_3$	Endothelial, epithelial basement membrane (>95%).
Type V	α1(V), α2(V), α3(V)	$[\alpha1(V)]_2\,\alpha2(V)$, $[\alpha1(V)]_3$, α1(V) α2(V) α3(V)	Cornea, placental membrane, large vessel wall (5%). Bone, gingiva, heart valve, hyaline cartilage (<5%).

Adapted from: Miller EJ. Chemistry of the collagens and their distribution. In: Piez K, Reddi A, eds. Extracellular matrix biochemistry. Elsevier, 1984:43-76.

Woven double velour grafts made from Type 56 Dacron polyester multifilament yarn 1.5 to 2.0 denier/filament were selected for coating with the collagen preparation. The porosity of these grafts before coating with collagen was 277±4 ml/min/cm². The bursting strength was 475±25 psi and the average wall thickness was 0.53 mm. The outside pile height was 0.38 mm and the inside pile height was 0.18 mm. After being coated with collagen the grafts were completely non-porous (Fig. 1).

Animal model. Prostheses 6 cm long and 8 mm in diameter were implanted in the thoracic aorta of 24 conditioned mongrel dogs (Fig. 2). The grafts were sewn end-to-end with continuous 6-0 polypropylene sutures. Sterile collagen coated grafts were not preclotted or prepared in any way prior to implantation. The control grafts, which were woven double velour Dacron grafts without collagen, were preclotted and implanted in the same manner. To determine the effect of cautery when used on the collagen grafts, a disposable battery activated cautery was used to divide and seal the ends of two grafts which were implanted and examined after 90 days. All other grafts were divided and trimmed with surgical scissors. The animals were heparinized and a femoral artery to carotid artery shunt was used while the thoracic aorta was occluded. Graft patency was confirmed in each animal by angiography immediately before the animal was sacrificed.

Observations and measurements. Healing characteristics of the implanted grafts were studied by gross inspection, conventional histology, and scanning electron microscopy. Four animals with investigational grafts and one animal with a control graft were sacrificed at 30, 90 and 180 days (Table 2). In addition, seven animals were sacrificed at 1, 2, 3, 4, 6, 7, and 8 day intervals. These seven animals, all with implanted collagen grafts, were examined primarily to determine the rate of resorption of bovine collagen. Two more animals with implanted collagen grafts which had been cauterized at the anastomosis were sacrificed and their grafts examined at 90 days.

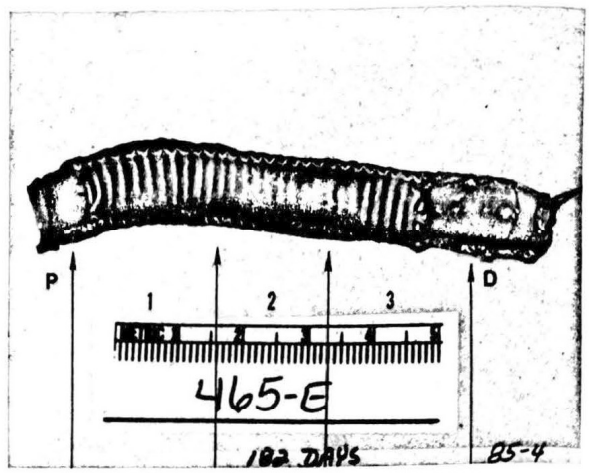

Fig. 3.—Collagen coated graft explanted after 182 days. Lumen surface is almost completely covered with neointima. Arrows indicate the three segments from which specimens are removed for light histology and ultrastructure.

Explanted grafts were fixed in 5% gluteraldehyde. The specimens were divided longitudinally for gross inspection. To facilitate their description, the grafts were divided into three equal segments (Fig. 3). Segment one includes the proximal anastomosis. Segment two is the inner segment, and segment three extends to and includes the distal anastomosis. The extent to which neointima covered the grafts was determined by gross inspection by three independent observers and their results were averaged.

Neointimal thickness was measured by preparing longitudinal sections for light microscopy. An ocular micrometer was used to measure the

TABLE 2.—*Area of collagen coated grafts covered with neointima.*

	30 days		90 days		180 days	
	No. of animals	% neointima	No. of animals	% neointima	No. of animals	% neointima
Collagen graft	4	37	4	75	4	93
Control graft	1	30	1	85	1	75
Cauterized collagen graft	—	—	2	70	—	—

Fig. 4.—Fixed specimen stained with hematoxylin and eosin of graft implanted for 90 days. Arrows indicate portion of neointima measured for thickness with ocular micrometer.

thickness of the tissue overlying the apex of the convoluted graft at multiple sites and averaged (Fig. 4).

Representative sections from each segment of each graft were inspected by light microscopy for inflammation, foreign body giant cell reaction, and intimal fibrosis. Each parameter was graded from 0 to 2 by a pathologist. Specimens were not identified until after all examinations had been completed. Inflammation was defined as the presence of plasma cells, lymphocytes, and polymorphoneutrophils in the wall of the vessel adjacent to the graft. The degree of inflammation was quantitated: 0=absent to mild; 1=mild to moderate; 2=moderate to severe. Foreign body giant cell reaction was defined as the presence of multinucleated giant cells and histiocytes around synthetic fibers. The degree of foreign body reaction was quantitated as follows: 0=minimal reaction on the medial side extending into the graft less than 1/3 of its thickness; 1=foreign body reaction extending up to 2/3 of the thickness of the graft from the medial side; 2=foreign body reaction on both sides of the graft fabric. Fibrosis is defined as the degree of fibrosis on the intimal surface. The degree of fibrosis was quantitated as follows: 0=predominately fibrin and red cells; 1=some fibroblasts with some fibrin; 2=all fibroblasts and collagen.

Scanning electron microscopy was used to demonstrate the presence of endothelial-like cells on the neointimal surfaces. Representative sections were taken from areas of grafts which appeared to be covered with neointima and from other areas where thrombus was present. These sections were processed, sputter coated with gold palladium, and examined with a Philips Model 505* scanning electron microscope.

Histologic sections were stained with hematoxylin and eosin and with Masson's trichrome. Additional sections were stained with picro-Sirius red and examined under polarized light to distinguish bovine collagen fibers from native collagen.

Selected specimens of endothelium were examined for Factor VIII related antigen using a peroxidase-antiperoxidase technique**. Other specimens were examined by transmission electron microscopy using a RCA model EMU-4B electron microscope to search for Weibel-Palade bodies within endothelial and endothelial-like cells.

Results

Gross appearance. All grafts were patent when the animals were sacrificed at intervals ranging from 1 to 180 days. The extent of endothelialization was measured on all grafts of animals sacrificed after 30, 90, and 180 days of implantation (Table 2). The average of the values in each period for the collagen grafts was 37% neointima at 30 days, 75% at 90 days, and 93% at 180 days. There was only one control graft in each group, and this does not allow for statistical comparison. However, healing was not impaired by the collagen coat and perhaps it was somewhat enhanced in the 180 day specimens.

Scanning electron microscopy. Endothelial-like cells were present on all surfaces where neointima was found to be present by gross examination (Fig. 5). Endothelial-like cells were not present in sections made from areas which were bare or which were covered with clot.

Intimal thickness. The mean intimal thickness measured over the apex of the convolutions of the collagen grafts was 99 μ at 30 days, 115 μ

*Philips Electronic Instruments, Eindhoven, Holland.
**Immunohistochemical Kit, Immuno Nuclear Corporation, Stillwater, Minnesota, U.S.A.

TABLE 3.—*Histological appearance of collagen coated grafts.*

Graft	#Days implanted	#Specimens	Inflammation [1]	Foreign body giant cell reaction [2]	Int'mal fibrosis [3]
Collagen	30	12	0.3	1.3	1.4
Control	30	3	1.0	1.0	1.3
Collagen	90	11	0.6	1.2	2.0
Control	90	3	0	2.0	2.0
Collagen	180	10	0.2	1.5	1.8
Control	180	2	1.0	2.0	2.0

Degree of tissue response in each category was graded subjectively. Values in each group were averaged for comparison.
(1) Plasma cells, lymphocytes, polymorphoneutrophils; 0=mild to absent; 1=mild to moderate; 2=moderate to severe.
(2) Giant cells and histiocytes; 0=minimal reaction and in less than 1/3 of graft thickness; 1=reaction in 2/3 of graft from medial side; 2=reaction on both sides of fabric.
(3) Fibrosis of intimal surface; 0=fibrin and RBC; 1=some fibroblasts with fibrin; 2=all fibroblasts and collagen.

at 90 days, and 111 μ at 180 days. The control graft in each group had a corresponding neointimal thickness of 92, 104, and 107 microns. These values were not significantly different from those of the investigational grafts.

Histological appearance. Representative sections from each segment of each graft in the 30, 90, and 180 day animals were inspected for inflammation, foreign body reaction, and intimal fibrosis, and were graded for severity. Subjective evaluation by a pathologist revealed no obvious or significant differences in the histological appearances of the collagen coated grafts and the control grafts after 30, 90, or 180 days of implantation. It is difficult to quantitate observations of this type although an attempt to do so was made by asking the pathologist to examine unlabeled sections and estimate the degree of reaction. The results are presented in Table 3.



Fig. 5.—Scanning electron micrograph of endothelial-like cells covering the flow surface of a collagen graft explanted after 180 days (500×).

It was possible to identify the bovine collagen when sections were stained with picro-Sirius red dye and viewed under polarized light. A thin layer of deep red staining collagen, approximately 10 μ to 12 μ thick, covered both surfaces of the unimplanted investigational graft (Fig. 6). After two days of implantation, the collagen layer appeared pale and swollen. Less than 10% of the bovine collagen remained on the graft after 30 days and less than 2% of the graft surface had bovine collagen after 90 days. No bovine collagen was seen 180 days after implantation (Table 4).

The thin monolayers of endothelial-like cells seen with the scanning electron microscope were examined with the transmission electron microscope for Weibel-Palade bodies and with perox-

TABLE 4.—*Rate of resorption of bovine collagen from dacron grafts.*

Days implanted	No. of animal	% collagen remaining
1	1	95
2	1	80-90
3	1	80-90
4	1	80-90
6	1	60-70
7	1	60-70
8	1	60-70
30	4	10
90	4	1
180	4	0

Fig. 6.—(A) Specimen of collagen graft before implantation fixed and stained with picro-Sirius red to show bovine collagen (arrows) surrounding the fabric. (B) Same graft as in A. at higher magnification.

idase-antiperoxidase for the presence of Factor VIII related antigens. Neither could be convincingly demonstrated in our animal specimens.

Effect of cautery. In two animals, collagen coated grafts were implanted after the ends of the grafts had been cauterized causing the Dacron polyester fibers to melt and fuse along the edge of the graft at the site of anastomosis. The tissue reaction seen in these grafts was the same as that seen in the grafts trimmed with scissors instead of cautery.

Discussion

All the grafts in this study were patent when the animals were sacrificed. This is not surprising since the grafts were relatively large in diameter (8 mm) and had been placed in a high blood flow setting, the thoracic aorta. The collagen coated grafts healed and developed a smooth neointima lined with endothelial-like cells that looked the same as those seen on the uncoated control grafts. Fibrous tissue and capillaries were present in the medial and intimal layers and appeared similar in both collagen coated and control grafts. There was no evidence that the collagen impaired healing in any way although there was no proof that collagen actually improved healing. Similar observations have been made by Ruhland [15] who implanted collagen coated knitted double velour grafts 4 mm in diameter in the femoral arteries of dogs and grafts 6 mm in diameter in canine iliac arteries. Patency was better in the collagen coated grafts than in the uncoated control grafts but the differences were not statistically significant.

A vascular prosthesis should be blood compatible at the time it is implanted and it should have characteristics that allow for long term healing. It has been shown that Dacron polyester grafts, whether woven or knitted, and whether with or without velour surfaces, heal in a satisfactory manner.[16 17] The porosity of the fabric contributes to the development of a firmly attached vascularized neointima. However, a nonporous graft is much more satisfactory at the time of surgery for controlling blood loss, particularly in heparinized patients. A porous fabric graft converted to a nonporous prosthesis by coating it with a resorbable material is a reasonable alternative provided the material used to coat the graft does not impart any objectionable qualities. The modified bovine collagen used in this study satisfies this requirement.

The collagen grafts prepared for surgery are soft, pliable, and easy to handle. The ends of the grafts do not fray. The fabric is easily penetrated by vascular needles and sutures. The grafts are completely nonporous and there is no bleeding through the graft even in the heparinized animal model. Delayed bleeding did not occur in any of the animals. The grafts do not require any special handling, preparation, or precaution.

The collagen developed for this study is blood compatible. It does not induce platelet aggregation or cause intravascular clotting and does not interfere with the normal clotting mechanism.[14]

Interference with the normal coagulation mechanism can occur, for example, if an excessive amount of an anticoagulant such as heparin is released from a heparin bonded surface.

By crosslinking, collagens can be made not only blood compatible, but nonantigenic, more resistant to resorption, and of varying tensile strength. Crosslinking can be effected chemically, by irradiation, or by dehydration.[11] The most commonly used chemical is gluteraldehyde.[18] This is very effective but residual aldehydes are toxic and must be carefully removed. Gamma radiation from cobalt-60 is a good example of the irradiation method.

Crosslinking collagen with mucopolysaccharides will alter the properties of the collagens. Many of these combinations have been found to improve blood compatibility, to reduce antigenicity, and to modify other characteristics. Naturally occurring mucopolysaccharides are derived from animal tissues. They are part of the macromolecular proteoglycans which are present in all connective tissues. Some of these mucopolysaccharides which are also known as glycosaminoglycans are hyaluronic acid, chondroitin-4-sulfate, chondroitin-6-sulfate, dermatin sulfate, keratin sulfate, heparin, and heparin sulfate. Crosslinked collagen composites made with either chondroitin-6-sulfate or heparin can prolong whole blood clotting time beyond sixty minutes.

Many different collagen combinations can be produced which have blood and tissue compatible properties. These collagens can be used with a variety of natural and synthetic substrates to develop new and different materials for vascular prostheses. The grafts developed for this study are a practical improvement in vascular prostheses and are a significant step toward the goal of preparing an ideal prosthetic graft.

References

1. Humphries AW, Hawk WA, Cuthbertson AM. Arterial prosthesis of collagen-impregnated Dacron tulle. Surgery 1961; 50:947-54.
2. Krajicek M, Zastava V, Chvapil M. Collagen-fabric vascular prostheses. Biological and morphological experience. J Surg Res 1964; 4:290-6.
3. Eiken O. Autogenous connective tissue tubes for replacement of small artery defects. A preliminary report of an experimental study in dogs. Acta chir scandinav 1960; 120:47-50.
4. Sparks CH. Die-grown reinforced arterial grafts: Observations on long-term animal grafts and clinical experience. Ann Surg 1970; 172:787-94.
5. Sparks CH. Silicone mandril method for growing reinforced autogenous femoro-popliteal artery grafts in situ. Ann Surg 1973; 177:293-300.
6. Kott I, Peirce EC, Mitty HA, Geller SA, Jacobson JH. The tissue tube as a vascular prosthesis. Arch Surg 1973; 106:206-7.
7. Perloff LJ, Christie BA, Ketharanathan V *et al.* A new replacement for small vessels. Surgery 1981; 89:31-41.
8. Keshishian JM, Smyth NPD, Adkins PC, Camp F, Yahr WZ. Clinical experience with the modified bovine arterial heterograft. Ann Surg 1970; 172: 690-700.
9. Dillon ML, Scott SM, Vasquez MD, Postlethwait RW, Dart CH. Tissue response to an arterial substitute of bovine origin. Arch Surg 1972; 105:577-81.
10. Dardik H, Ibrahim IM, Dardik I. Evaluation of glutaraldehyde-tanned human umbilical cord vein as a vascular prosthesis for bypass to the popliteal, tibial, and peroneal arteries. Surgery 1978; 83: 577-88.
11. Yannas IV, Tobolsky AV. Crosslinking of gelatin by dehydration. Nature 1967; 215:509-10.
12. Woodhead-Galloway J. Collagen: the anatomy of a protein. In: The institute of biology's studies in biology 117. Edward Arnold Ltd., 1980:1-60.
13. Miller EJ. Chemistry of the collagens and their distribution. In: Piez K, Reddi A, eds. Extracellular matrix biochemistry. Elsevier, 1984:43-76.
14. Hoffman H. Personal communication. 1985.
15. Ruhland DD. A preclinical canine study on collagen coated knitted Dacron double velour grafts. Unpublished, 1983.
16. Scott SM, Hoffman H, Gaddy LR, Sethi GK, Bridgman AH. A new woven double velour vascular prosthesis. J Cardiovasc Surg 1985; 26:175-81.
17. Lindenauer SM. The synthetic vascular prosthesis. In: Rutherford RB, ed. Vascular Surgery. WB Saunders, Philadelphia, 1977:367-79.
18. Kambic H, Picha G, Kiraly R, Koshino I, Nose Y. Application of aldehyde treatments to cardiovascular devices. Trans Amer Soc Artif Int Organs 1976: 22:664-72.

[Authors' address:

S. M. Scott

Veterans Administration Medical Center
Asheville, North Carolina 28805 (U.S.A.)]