**Figure 3.** *The aspect of the eye after elimination of larvae and orbital exenteration.*

or without chemical immobilization of the larvae are the options of treatment, depending on the time and degree of infestation. The preservation of larvae in ethanol for genus identification may be useful for epidemiological purposes and the subsequent application of large-scale measures to reduce the fly population. Outbreaks of *C hominivorax* have been reported, and although considered to be confined to the New World, reports have identified the parasite in Africa and Asia.[2]

The massive infestation seen here may have been precipitated by an open wound caused by basal cell carcinoma in the nasal canthus. This hypothesis is based on previous observations that adult flies of *C hominivorax* locate their hosts via visual and olfactory stimuli and are strongly stimulated by fresh blood, usually present in this type of skin neoplasia.[3] Alcoholism and the prolonged state of unconsciousness in a rural location contributed to the fast destruction of the orbit of our patient. Exenteration was conducted to prevent intracranial progression.

Although there is no method for completely protecting against myiasis, prevention may be conducted on a local scale by practicing adequate personal hygiene and proper care of wounds. To our knowledge, this is the first reported case of ophthalmomyiais caused by *C hominivorax* in which exenteration was necessary to contain the progression of the infestation.

*Eduardo M. Rocha, MD*
*Jorge L. Yvanoff, MD*
*Leopoldo M. S. Silva, MD*
*Angelo P. Prado, PhD*
*Roberto Caldato, MD*
*Campinas, Brazil*

*Corresponding author: Eduardo M. Rocha, MD, Faculty of Medical Sciences, State University of Campinas (UNICAMP), Rua Alexandre Fleming, s/n, Campinas, SP, CEP 13081-970, Brazil (e-mail: emrocha@unicamp.br).*

1. Kersten RC, Shoukrey NM, Tabbara KF. Orbital myiasis. *Ophthalmology*. 1986;86:1228-1232.
2. Chodosh J, Clarridge J. Ophthalmomyiasis: a review with special reference to *Cochliomyia hominivorax*. *Clin Infect Dis*. 1992;14:444-449.
3. Holt GG, Adams TS, Sundet WD. Attraction and ovipositional response of screw worms, *Cochliomyia hominivorax* (Diptera: Calliphoridae), to simulated bovine wounds. *J Med Entomol*. 1979; 16:248-253.

## Ocular Injuries Caused by Airsoft Guns

In the past 2 years, we observed in our outpatient clinic an escalating number of ocular injuries caused by "airsoft" or "softgun" toy weapons. In contrast to the conspicuous hazard of classical air guns (BB guns), this new kind of toy weapon implies a dangerously misleading harmlessness, both because of the airsoft name and because the gun is made of plastic. These toy guns have gained popularity among youngsters since they are relatively cheap, can be purchased without age restrictions, and look real.

To our knowledge, no reports have previously been published on eye injuries caused by these guns. The purpose of this study is to illustrate their potential ocular hazards and to propose preventive measures.

**Airsoft Guns.** Airsoft guns consist of a plastic pistol that shoots hard plastic bullets with a diameter of 6.0 mm (**Figure 1**). These bullets are available in different weights (0.12, 0.2, and 0.25 g), all of which are much lighter than the lead bullets used in BB guns (0.52-1.6 g). The guns use the direct force of a spring coil or compressed air to fire bullets. In an independent ballistic investigation,[1] the calculated energy for bullets weighing 0.2 and 0.12 g was 0.363 and 0.347 J, respectively. This energy results in velocities of 61.5 and 74.9 m/s, respectively, and in-flight ranges of 30 to 50 m, respectively. The bullets are made of a very hard and noncompressible plastic material and thus, do not absorb energy. They can cause injuries, even when they ricochet from rigid surfaces. In comparison, BB gun bullets reach speeds of 100 to 200 m/s and a flight range of 100 to 150 m.

**Patients.** Between October 1996 and July 1998, 9 male patients were treated, 8 at the eye clinic of the University of Bern and 1 at the eye clinic of the University of Basel, Switzerland, for ocular injuries caused by airsoft bullets. After reviewing the



**Figure 1.** *Realistic looking plastic airsoft pistol and bullet of 6-mm diameter.*



©1999 American Medical Association. All rights reserved.
1 of 3
PETITIONERS' EXHIBIT 1048
Prime Time Toys et al. v. Spin Master, Inc.
IPR2023-01339

**Anterior and Posterior Segment Injuries***

| Patient No. | Age, y | Eye | Visual Acuity Initial | Visual Acuity Final | Anterior Segment Injuries: Corneal Abrasion | Epithelial Edema | Stromal Edema | Hematocornea | Hyphema | Traumatic Mydriasis | Iridodialysis | Angle Recession | ↑IOP Temporary | Cataract |
|---|---|---|---|---|---|---|---|---|---|---|---|---|---|---|
| 1 | 17 | OS | 20/60 | 20/20 | x | x | | | x | | | | | |
| 2 | 12 | OS | CF | 20/20 | x | x | x | | x | x | x | | x | x |
| 3 | 17 | OS | 20/20 | 20/20 | | | | | | | | | | |
| 4 | 16 | OS | 20/100 | 20/20 | x | x | x | | | x | | | | x |
| 5 | 13 | OD | 20/20 | 20/20 | | | | | x | | | | | |
| 6 | 11 | OD | LP | 20/25 | x | x | | x | x | x | | | x | x |
| 7 | 13 | OD | 20/25 | 20/20 | | | | | x | | | x | | |
| 8 | 12 | OD | 20/25 | 20/20 | x | x | x | | x | | | | | |
| 9 | 14 | OS | CF | 20/20 | x | x | x | | x | x | | x | | |

*↑ *indicates increase in; IOP, intraocular pressure; CF, counting fingers; LP, light perception; x, finding present on initial clinical examination; conserv, conservative treatment; IOL, implantation of a posterior chamber intraocular lens; and ppV, pars plana vitrectomy.*

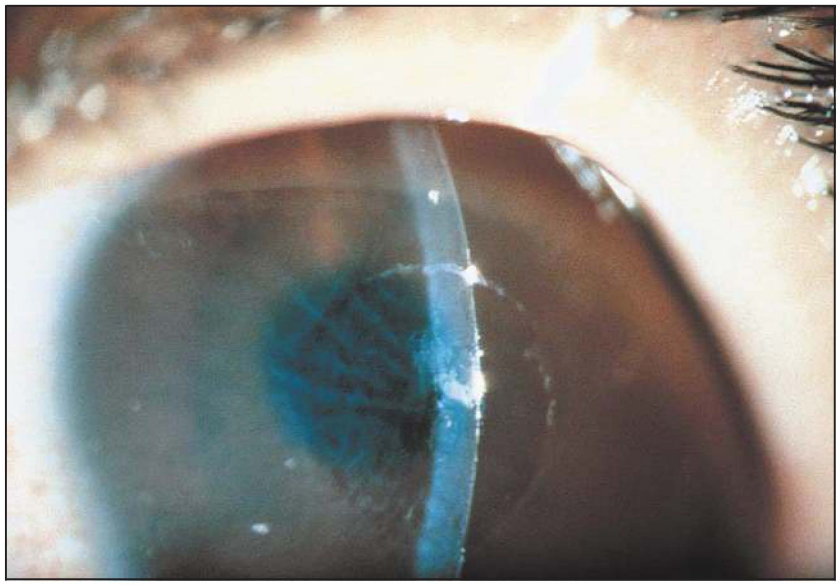

**Figure 2.** *Case 2. Corneal erosion in size and shape of an airsoft bullet. Note beginning stromal edema and descemet folds.*

medical charts, patients were scheduled for an additional eye examination. Mean follow-up was 8.8 months (range, 0.5-24 months). Mean ± SD age was 13.9 ± 2.3 years (range, 11-17 years). All patients were male and only 1 eye was affected. In 2 cases, bullets ricocheted from a wall into the eye; in the other 7 cases, the eye was hit directly.

**Results.** A summary of the results is given in the **Table**. Initial visual acuity was counting fingers or light perception in 3 patients, between 20/100 and 20/25 in 4, and 20/20 in 2. Final visual acuity was 20/20 in 8 patients and 20/25 in 1.

In 6 patients, corneal erosion and stromal edema matching the bullet size (**Figure 2**) were seen. Cataract development was observed in 3 patients; 2 showed a transient increase of intraocular pressure due to hemorrhagic glaucoma. Chamber angle recession was present in 2 patients, iridodialysis in another.

Injuries of the posterior segment were observed in 5 eyes. In 1 of these eyes, there was total hyphema with subsequent hematocornea and dense vitreous hemorrhage. A pars plana vitrectomy, combined with phacoemulsification and a posterior chamber lens implantation, was performed. Initial visual acuity was light perception; final visual acuity of 20/25 was attained 3 months after injury.

Another case of posterior segment injury showed a peripheral choroidal rupture but only a small vitreous hemorrhage. Initial and final visual acuity was 20/20. The area of choroidal rupture remained unchanged during the 14-month follow-up.

**Comment.** Previous to our series, ocular injuries due to air guns have been reported only in the context of BB guns,[2] including penetrating globe injuries or retrobulbar optic nerve trauma leading to severe visual impairment or loss of the eye.[3,4] Other severe nonocular injuries have been observed, some of which have led to death.[5] This severity is due to the much higher energy of BB bullets (0.072 J/mm$^2$)—which exceedes that necessary for scleral penetration (0.06 J/mm$^2$)[6]—than the considerably lower energy density (0.01 J/mm$^2$) of airsoft bullets.[1]

In our series, airsoft bullet injuries ranged from light contusions to severe sight-threatening closed-globe injuries. These are less severe than with BB guns, possibly because airsoft bullets are larger and have lower energy. The worst injury in our series was a total hyphema combined with traumatic cataract, and a dense vitreous hemorrhage.

However, in contrast to BB guns, airsoft guns are easily available and their sale is not restricted by age. Airsoft guns were designed as a toy and are still marketed as a toy. The innocent name and misleading marketing contribute to the danger of airsoft guns. Safety goggles are not supplied with the guns, but are at least recommended in product manuals. In all cases, goggles could have prevented injuries.



©1999 American Medical Association. All rights reserved.

| Posterior Segment Injuries | | | |
|---|---|---|---|
| Vitreous Hemorrhage | Choroidal Rupture | Retinal Edema | Procedure |
| x | | x | conserv |
| | | | conserv |
| x | x | x | conserv |
| | | | conserv |
| | | | conserv |
| x | | x | IOL/ppV |
| x | | x | conserv |
| | | x | conserv |
| | | | conserv |

Airsoft guns have the additional liability that it is very easy to replace the plastic bullets with much heavier steel or lead bullets, which develop the same energy at a distance of 40 to 50 m that plastic bullets develop at 10 m.[7]

Airsoft guns should not be considered to be toys but rather, as weapons with the potential of causing severe eye injuries. Globe ruptures or penetrating traumas were not observed in our series, but 1 injury was severe enough to require intraocular surgery. In the United States, some states recently passed legislations limiting the import and sale of these weapons.

All patients with eye injuries due to airsoft guns should be referred to an ophthalmologist for further evaluation. Safety goggles should be included with the guns and wearing them should be mandatory while playing. Age or sale restrictions should also be considered.

*Johannes C. Fleischhauer, MD*
*David Goldblum, MD*
*Beatrice E. Frueh, MD*
*Fritz Koerner, MD*
*Bern, Switzerland*

*Corresponding author: Beatrice E. Frueh, MD, Department of Ophthalmology, University Hospital, Inselspital, Freiburgstrasse, CH-3010 Bern, Switzerland (e-mail: beatrice.frueh.epstein@insel.ch).*

1. Kneubühl B. Ballistische Kolumne: Bogen, Armbrust und andere Federwaffen. *Internationales Waffenmagazin*. 1998;3:160-162.
2. Bond S, Schnier G, Miller F. Air-powered guns: too much firepower to be a toy. *J Trauma*. 1996; 41:674-678.
3. Schein O, Enger C, Tielsch J. The context and consequences of ocular injuries from air guns. *Am J Ophthalmol*. 1994;117:501-506.
4. Sharif K, McGhee C, Tomlinson R. Ocular trauma caused by air-gun pellets: a ten-year survey. *Eye*. 1990;4(pt 6):855-860.
5. Amirjamshidi A, Abassioun K, Roosbeh H. Air-gun pellet injuries to the head and neck. *Surg Neurol*. 1997;47:331-338.
6. Sellier A, Kneubühl B. Wound ballistics of handgun ammunition. In: *Wound Ballistic and the Scientific Background*. Amsterdam, the Netherlands: Elsevier Science Publishers; 1994: chap 6.
7. Kneubühl B. Ballistische Kolumne: Bogen, Armbrust und andere Federwaffen. *Internationales Waffenmagazin*. 1998;5:328-330.



©1999 American Medical Association. All rights reserved.