ResearchGate

See discussions, stats, and author profiles for this publication at: https://www.researchgate.net/publication/276026692

# Clinical Digital Photography in Orthodontics: Professional Photographic Records in Daily Practice.

**Article** *in* The Jordan dental journal · May 2013

CITATIONS
6

READS
9,912

**1 author:**

Shadi Samawi
Samawi Dental and Orthodontic Center

**5** PUBLICATIONS **39** CITATIONS

SEE PROFILE

All content following this page was uploaded by Shadi Samawi on 09 May 2015.

The user has requested enhancement of the downloaded file.

JDJ

# Clinical Digital Photography in Orthodontics: Professional Photographic Records in Daily Practice.

**Shadi S. Samawi** *BDS, MMedSci (Orth), MOrthRCSED*
** Specialist Orthodontist*
** Private Practice - Amman, Jordan.*

*Correspondence:*
*Dr. Shadi Samawi*
*E-mail: info@sdoc.jo*

## Abstract

In recent years, Clinical Photography has grown to become a very important aid and requirement for proper clinical diagnosis, treatment planning and case documentation in Orthodontics and Dentistry in general. The advent of mainstream digital photography a little over a decade ago with its wide-spread appeal, cost-effectiveness and relative ease of use, along with an increased emphasis on smile esthetics and overall facial harmony - particularly in Orthodontics - has largely contributed to its increased relevance to every-day practice.

This article will present an overview of the significance of clinical digital photography in every-day orthodontic practice, a general description of some relevant equipment as well as present an outline of requirements and best-practices for achieving proper high quality photographic records in a clinical setup.

**Keywords:** *photography, digital photography, clinical photography, orthodontics, records.*

*Received: March 2013, Published: May 2013*

## Introduction

### The Significance of Clinical Photography

With more and more emphasis from the orthodontic community on the achievement of balanced facial harmony and smile esthetics for our patients - in addition to the traditional goals of a well-aligned and functional dentition - the need for proper clinical photographic records of the orthodontic patient has become even more essential for proper treatment-planning and follow-up.[1]

Clinical photographs allow the orthodontist to carefully evaluate the existing patient's soft-tissue patterns during the treatment planning stage.[2] Lip morphology and tonicity, the smile arc

and the degree of incisal show upon smiling and overall smile esthetics can all be assessed from various angles at any time. Thus, they allow us to study the patient in a so called "social" setting, and all without the patient ever being present. Such information greatly aids the orthodontist in formulating the best possible treatment plan for each patient, and monitoring any changes in subsequent follow-ups.

Needless to say, the need for photographic records for purposes of research and publication, lecturing and for teaching presentations has always been present. In addition, the growing importance for the need for such records for medico-legal reasons cannot be ignored.[2,3]

Going for a digital camera is the obvious choice in this digital age. One of the major reasons is the relative ease of use of such cameras, along with the ability to repeat or delete unsuitable images on the spot. There is no need to wait until the film is developed to check your photos. Any problems can be easily rectified immediately. Another important advantage is the issue of "running cost"; Digital camera setups are cost-effective; eliminating the cost of photographic film, developing costs and hassles, as well as solving the issue of "physical storage" of slides and photographs of large numbers of patients.[3,4] All that is required is a one-time investment in a suitable digital camera setup, one or two high capacity memory cards, and a computer with a reasonably-sized hard disk setup for processing, storage and back-up purposes.

One of the main advantages of digital photography is the ability to enhance, or "post-process" your images. Even if some images are still not suitably aligned, rotated, or the color, brightness or saturation etc. is not up to standard, it is usually relatively easy to adjust those using a suitable image-editing software on your computer, before saving the images in the patient's file. [1,5]

However, it is vital not to overlook the ethical issues raised by such enhancement procedures and as such, any photo manipulation beyond the basic general improvement of the properties of the original image as described in this article is not advised and is considered - by all means - ethically and professionally unacceptable, and may ultimately lead to legal ramifications.

## Recommended Equipment

There are several types of digital cameras available on the market today. Most compact cameras i.e "Point and Shoot" cameras available today have sufficient image quality and sophistication to produce reasonable clinical

dental photographs, although at the expense of proper illumination of the scene due to limitations of their built-in Single-point Flash units. However, their results are often inconsistent and require too much time and trial and error to get the desired outcome. The ideal camera setup that is best-suited and recommended for clinical photography is a Digital Single Lens Reflex camera setup (DSLR) with a suitable Ring Flash unit.[3,6,7] The minimum accepted image resolution that would provide us with high quality photos for screen presentation or 4x6 prints - if desired - would be around 4 Megapixels. However, current cameras can produce much higher-resolution photos than this minimum requirement, therefore it can be generally determined that any current camera with a resolution of 8 Megapixels or higher would be more than adequate for orthodontic record-taking purposes. This setup is described in more detail in the following sections.

### A. The Digital Camera

A DSLR provides full manual control over all exposure parameters in photography, in addition to the usual automatic and semi-automatic programs available on most cameras today. Therefore, they allow maximum flexibility and customization for producing the highest possible quality of digital images.[7] They are of a superior build quality and thus would be a solid long-term investment for the practice. Many DSLRs now come with High Definition (HD) video recording capabilities as well, that may prove useful in certain clinical situations. An entry-level DSLR camera is recommended for clinical photography, as it will produce the highest quality results while being a more cost-effective option than other high-end DSLRs.

### B. The Lens

Although zoom lenses can generally be used for clinical photography, the recommended lens to use is a dedicated Macro lens e.g. a 100mm focal length Macro lens.

### Macro Lens vs Macro Function

Macro photography refers to close-up photography; the classical definition that the image projected on the "film plane" (i.e film or a digital sensor) is the same size as the subject. Most Point-&-Shoot digital cameras have a built-in Macro function that is actually very good for dental photography purposes. However, a dedicated Macro lens attached to a DSLR camera provides even better close-up photos usually with higher definition and better focus, and is by far the superior choice.[8]

## C. The Flash

### Ring Flash vs Point Flash

The Single Point Flash built into most compact digital cameras and some DSLR may occasionally produce fairly good light distribution when used for clinical photographs, but the results are very inconsistent and largely depend on camera orientation and pre-existing lighting conditions in the clinic. Dark distracting shadows, which may obstruct important details frequently occur. These are often irreparable even by using image editing software, and will detract from the final quality of the image, and possibly the information gained from it. In contrast, A dedicated Ring Flash - eliminates almost all shadows by providing a more even distribution of light during extra and intra-oral photographs (Figure 1), and thus the quality of the image is enhanced due to overall better illumination. Therefore, it is highly recommended to use a Ring Flash for orthodontic photography.[1,3,4,7]

Figure 1 Canon MR-14EX TTL Macro Ring Lite Flash (Canon USA)

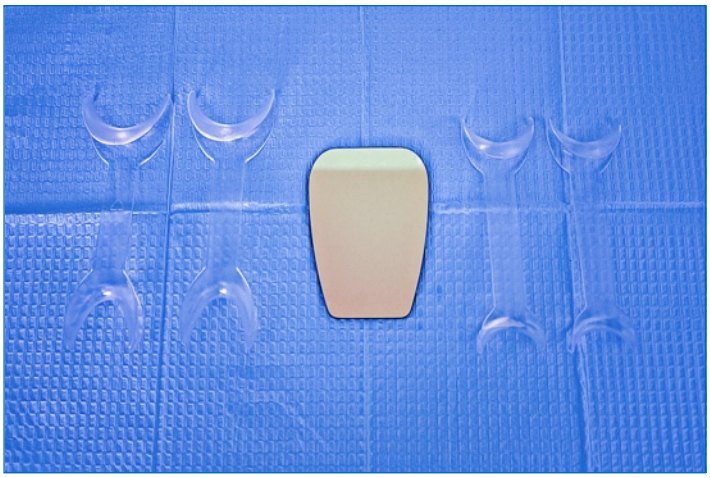

Figure 2 Large and Small Double-ended Cheek Retractors and Medium-sized, Front-silver coated Dental Mirror.

## D. Retractors

The recommended cheek retractors to be used for best results in clinical photography are two pairs of variable-size double-ended retractors shown (Figure 2).[1,3]

There are two sets of double-ended retractors; one set with a regular and small size either end. These are mainly used for intra-oral occlusal shots (mirror shots). The other set has a narrow end and a wide end on the other. These are used for intra-oral frontal and buccal shots.

Although other types of retractors are available on the market, it is accepted by many that this selection presents an ideal set to be used for clinical photography, as they greatly facilitate taking almost any kind of intra-oral photographs with clarity and with the largest possible field of vision. Smaller one-piece orthodontic bonding retractors are generally not a good choice for orthodontic purposes, especially for buccal and occlusal shots, as their retraction potential is very limited, and it can often prove to be a "painful experience" for the patient.[9]

It is a wise long-term investment to buy good quality retractors to ensure durability and reliability, with recurrent disinfection procedures.

**E. Dental Photography Mirrors**

Many types of mirrors may be used for clinical photography, ranging from front-silvered mirrors to highly polished Stainless Steel mirrors of various shapes and sizes. Many authorities in the field recommend front-coated silvered mirrors as they offer the best image quality and light distribution over other types of mirrors. With front-silvered mirrors, no "ghost" image, or "double-layering" occurs. In contrast, when using glass or rear-coated silvered mirrors, "ghosting" can severely affect the quality of the image, resulting in haziness or a "Double-Image". Also, light reflection is not on par with the front-silvered mirrors, leading to a dimmed, darkened image as an end-result. Therefore front-coated silvered mirrors are highly recommended over other types (Figure 2).[1,3]

It is generally preferred to use long-handled mirrors (see Image) as they allow better control and handling by the clinician during the occlusal shots. Different sizes can be found for use with different patients depending on age and mouth-opening size, with medium-sized mirrors generally being fit for use with most patients.

Mirrors with no handles may also be used successfully but are trickier to handle, especially when juggling an expensive digital camera in the other hand.

It is important to mention that the previously mentioned equipment are not - by any means - the only recommended equipment for the purposes of clinical photography, nor are they necessarily the best for all clinicians, and should be considered as a basic recommendation that - in the author's personal opinion and experience - represents the simplest, most cost-effective and easy-to-use setup that will produce the highest quality professional results in a consistent fashion.

## How Many Photographs Do We Need?

There is no "standard" set of clinical photographs that is universally approved as a rule of thumb. However, it can generally be accepted - based on many practitioners' opinions - that a complete "Clinical Photographic Set" for any orthodontic patient at any stage of treatment, that would enable the clinician to obtain maximum benefit and information, should include a minimum of nine photographs; four extra-oral, and five intraoral photographs per set, with a minimum of two sets; Pre and Post-treatment sets.

However, a clinician may also choose to take additional views, as needed to document the entire case in further detail.

## Clinical Photographic Technique

### General Camera Settings

As mentioned earlier, DSLRs allow maximum control and customization of camera settings to achieve the best possible results. In most cases, it is recommended to set the camera dial to Aperture Priority Mode (A or Av, depending on camera brand). Aperture Priority mode allows the photographer to control the aperture dimension, through which light enters the lens, while leaving the camera to balance the best exposure as it determines the other variables automatically. The aperture (F number) is best set to f22 or higher; this will ensure a high depth of field and focus throughout the various extra and intra-oral photographs.[1,2,3] The use of a Ring flash is essential in this case to ensure proper lighting and illumination of the scene. Clinicians with a good understanding of photographic exposure principles may choose to use the Full Manual setting (M) and control all the exposure variables themselves as they see fit.[8]

It is important to note that these are only general recommendations and some trial and error may still be required depending on the existing clinical lighting and situation.

### Extra-oral Clinical Photographs

They are usually the first and simplest photographs to take. They require proper positioning of the patient and clinician in front of a suitable plain background; in addition to the digital camera setup itself. It is recommended to use a plain-white or dark-blue background or alternatively a large wall-mounted light box behind the patient's head, in order to maintain the best definition of the soft tissue profile of the patient with no distractions in the background.[3,7]

Standardizing extra-oral photographs by maintaining a fixed distance between the patient and the camera is preferred as it would provide a consistent magnification factor and add a professional appearance to the photos. This may be done by using a tripod set at a fixed marked distance from the background and marking a line on the floor at a certain distance from the background where patients should consistently stand while being photographed.

Extra-oral photos consist of the following four photographs, taken in the following sequence:

1. Face-Frontal (lips relaxed).
2. Face-Frontal (Smiling).
3. Profile (Lips relaxed).
4. (45 °) Profile (also known as 3/4 Profile - Smiling).

These four shots provide the clinician with maximum possible information about the patient's facial and soft tissue features, proportions, and overall smile esthetics.

**1. Face-Frontal (lips relaxed)**

The patient should stand at the marked distance form the background with their head in the Natural Head Position, eyes looking straight at the camera and the teeth and lips relaxed in the rest position. The whole of the patient's face should be clearly visible. Ensuring that the inter-pupillary line is horizontally leveled is vital (Figure 3).

The camera should be held in the vertical portrait orientation for this and all extra-oral photographs and the photograph taken at 90 degrees to the facial midline for best results, while ensuring proper framing of the entire head and neck.

**2. Face-Frontal (Smiling)**

The same principles apply as in the first photograph with the important exception that the patient should be smiling in a natural relaxed manner with the anterior teeth clearly visible, in order to properly showcase overall smile esthetics from the front (Figure 4).

**3. Profile (Lips relaxed)**

The profile view has an extremely high diagnostic value for the orthodontist. The patient is required to turn to bodily to their left thus having their right profile visible to the clinician. Ideally, the whole of the right

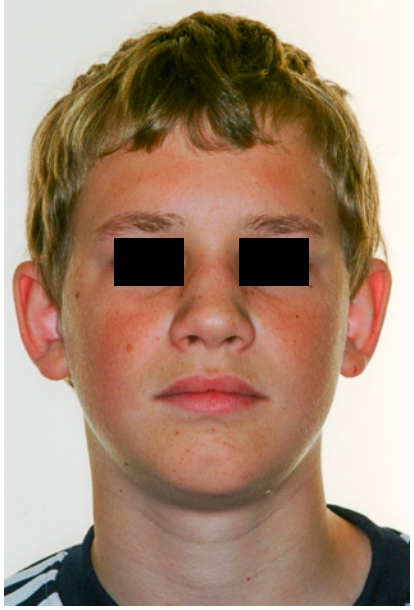

Figure 3: Full-face Frontal - Lips at Rest.

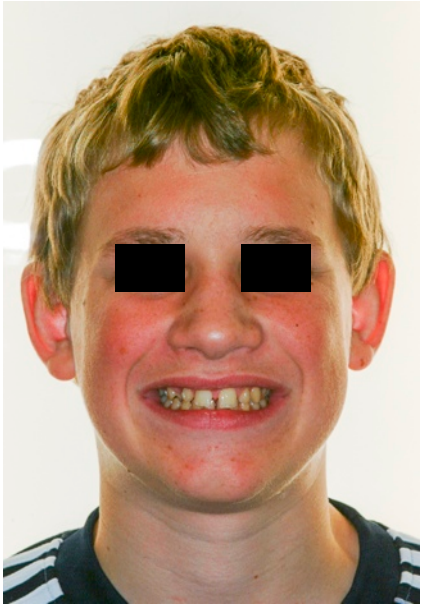

Figure 4: Full-face Frontal - Smiling.

Figure 5: Right Profile View - Lips at Rest.

Figure 6: 3/4 Profile - Smiling View.

side of the face should be clearly visible with no obstructions such as hair, hats or scarfs. The head should be in the Natural Head Position, with their eyes fixed horizontally - preferably at a specific point at eye-level, or at the reflection of their own pupils in a mirror (Figure 5). The use of a Ring flash here is particularly important, as it will eliminate any shadowing of the border of the patient's profile onto the background, which can very distracting and considerably compromise the quality of the photo and the information gained from it.

**4. (45 °) Profile (also known as 3/4 Profile - Smiling)**

From the Profile photo position, the patient is asked to turn their heads slightly to their right - about 3/4 of the way, hence the name - while keeping their body still in the previous "Profile Shot" position i.e. Facing forward. They are then instructed to look into the camera, and then smile. It is essential that the patient's teeth show clearly when smiling, otherwise the photograph would be of minimum benefit (Figure 6).

This shot conveys the patient as if in "social interaction", and can provide valuable information regarding the smile esthetics' changes pre and post-treatment.

**Intra-oral Clinical Photographs**

Intra-oral photos require the proper cheek retractors, dental photography mirrors, as well as a well-trained assistant if possible - in addition to the camera setup. They require more attention to detail to produce excellent results.

There are five essential intra-oral photographs - taken in the following sequence:

1. Frontal - in occlusion
2. Right Buccal (in occlusion)
3. Left Buccal (in occlusion)
4. Upper Occlusal (mirror)
5. Lower Occlusal (mirror)

**1. Frontal (in occlusion)**

The patient is seated in the dental chair with head raised to the clinician's elbow level. The dental assistant stands behind the patient and uses the larger set of retractors from their wider ends to retract the patient's lips sideways and outward, away from the teeth and gingivae. Maximum field of view is required for visualization of all teeth and associated tissues. The photo should be taken 90° to the facial mid-line & central incisors. With the occlusal plane properly leveled according to the patient's existing occlusion. The Ring-Flash will greatly aid in producing a quality photograph by ensuring the best possible illumination with no shadows, especially in the deeper parts of the oral cavity and buccal vestibules (Figure 7).

**2. Right Buccal (in occlusion)**

Here, the assistant flips the right retractor to the narrower side, while the left retractor remains in place as for the previous frontal shot. The patient is asked to turn their head to their left so their right side will be facing the clinician (Figure 8).

The clinician holds the right retractor and stretches it to the extent that the last present molar is visible if possible, while the assistant maintains hold of the left retractor, without undue stretching. Again, the shot is taken 90° to the canine-premolar area for best visualization of the buccal segment relationship, as this is very important in orthodontic assessment. A useful tip would be for the clinician to fully stretch the right retractor just before taking the shot to minimize any discomfort for the patient, and

Figure 7 Frontal View - In Occlusion.

Figure 8 Right Buccal View - In Occlusion.

Figure 9 Left Buccal View - In Occlusion.


Dental Monitoring Ex. 2040
Page 11 of 14

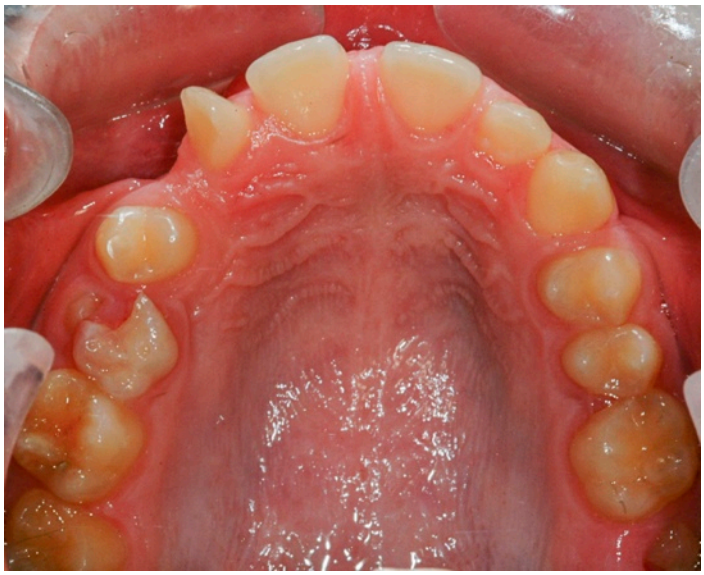

Figure 10 Upper Occlusal View - Mirror.

achieve maximum visibility of the last present molar, if possible.

### 3. Left Buccal (in occlusion)

The assistant now switches the retractors with the narrow end on the photo side (patient's left) and the wide end on the other (patient's right). The same principles as for the right buccal shot apply. The clinician should move their body slightly to the right while holding the retractor on the photo side, to ensure the photo is taken at 90 degrees to the canine-premolar area, while the patient turns their head all the way to their right (Figure 9).

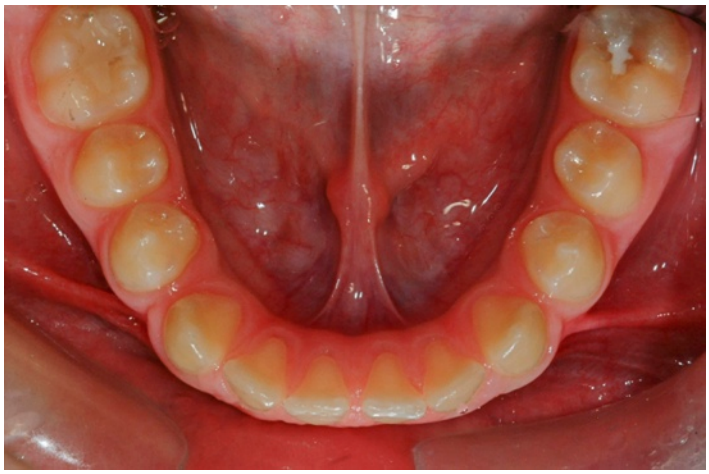

Figure 11 Lower Occlusal View - Mirror.

### 4. Upper Occlusal (mirror)

The assistant now switches to the smaller retractor set and with the patient's mouth held open, the retractors are inserted in a "V" shape to retract the upper lips sideways and away from the teeth. The clinician inserts the mirror with its wider end inwards to capture maximum width of the arch posteriorly, and pulls it slightly downwards so that the whole upper arch is visible to the last present molar (Figure 10).

The shot must be taken 90° to the plane of the mirror for best visibility and no visual distortion. The mid-palatal raphe is used as a guide to level the palate in the photo. Minimal retractor visibility in the image is recommended, and no fingers should be visible in the final photo, if possible.

### 5. Lower Occlusal (mirror)

The assistant now lowers the smaller retractors into a Reverse "V" shape to retract the lower lips sideways and away from the teeth. The clinician would now lift the mirror upwards so he/she may visualize the reflection of the lower arch, while the patient is be asked to "lift their chin up" slightly. Ideally, the shot should be taken 90° to the plane of the mirror, with the last molar present visible. An important issue here would be the tongue position of the patient while taking the photo. It is best to ask the patient to "roll back" their tongue behind the mirror so that it won't interfere with the visibility of any teeth, particularly in the posterior area (Figure 11).

## Additional Photographic Views

There are several other views that may be taken by the clinician to fully document the case at hand, depending on his or her needs. Functional Occlusion views may be taken by the orthodontist to demonstrate canine guidance or Group Function of the occlusion to supplement existing records. A close-up of the lips and mouth upon smiling may be taken for closer examination of overall smile esthetics, or a close-up view of the overjet from one side may be taken to demonstrate the amount of incisor overjet and overbite present. Close-ups focusing on certain aspects of existing appliances, brackets or arch-wires and associated auxiliaries may be individually taken as needed, although many clinicians prefer to crop the necessary details out of the complete photographic set described earlier, provided that they are taken using a high resolution setting, to avoid any deterioration in image quality upon cropping.[10]

## Helpful Tips for Best Results

It is recommended that all photographic records be taken before impression-taking, to eliminate the possibility of impression material being stuck between the teeth or on the face during photographic record-taking.[3,7]

Wetting the retractors just before insertion eases their proper positioning in the mouth with minimum patient discomfort.

The direction of pull of the retractors is always sideways and slightly forward and outward, away from the gingival tissues.

This maximizes the field of view and minimizes patient discomfort.

When taking occlusal views with the mirror, slightly warming the mirror in warm water prior to insertion in the mouth helps prevent "Fogging" of the mirrors which would prevent a clear image from being obtained.[1,9]

With some patients, profuse salivary flow and "frothing" can affect the quality of the image being taken, thus a saliva ejector can be used to eliminate saliva prior to taking each photograph.[3]

## Post-Processing

Once all photographic records are obtained, they should be downloaded to the computer and an initial back-up of the original files performed onto a separate computer, hard disk or suitable removable media prior to post-processing the photos for final archiving, to ensure the originals are always available in case of a computer or hard disk failure or if something goes wrong during post-processing.[10] This will be the subject of another article.

## References

1. Sandler J, Murray A; *Digital Photography in Orthodontics*. Journal of Orthodontics, 2001, 28:197-201

2. Mizrahi E; *Orthodontic Pearls: A Selection of Practical Tips and Clinical Expertise*; 2004, Taylor & Francis Group. (Sandler J, Murray A; *Ch 4: Orthodontic Photography*)

3. Sandler J, Murray A; *Current Products and Practice: Clinical Photographs - The Gold Standard*. Journal of Orthodontics, 2002, 29:158-67

4. Sandler J, Murray A; *Recent Developments in Clinical Photography*. British Journal Of Orthodontics, 1999, 26: 269-72

5. Mah J, Ritto K; *The Cutting Edge*. Journal of Clinical Orthodontics, 2002, 36: 11; 619-625

6. Palomo J, Wolf G, Hans M; *Use of Digital Photography in the Case Orthodontic Clinic*. Am J Orthod Dentofacial Orthop 2004; 126: 381-5

7. Terry D.A, Snow S.R, Mclaren E.A; *Contemporary Dental Photography: Selection and Application. Functional Esthetics & Restorative Dentistry*, 2008; Series 1, No. 1.

8. *Mastering Digital SLR Photography: The Serious Photographer's Guide to High Quality Digital SLR Photography,* Busch D, 2005, Thomson Publishing.

9. Mckeown H.F, Sandler P.J, Murray A.M; *How to avoid common errors in clinical photography*. Journal of Orthodontics, 2005, 32: 43-54

10. *Aperture: Digital Photography Fundamentals*. 2005. Apple Inc.



View publication stats