Standardization for serial intraoral photography

Ross G. Kaplan*
Portland, Ore.

Currently orthodontists include among their case records pretreatment, posttreatment, and possibly postretention intraoral color photographs. These photographs complement the other orthodontic records—study casts, intraoral and extraoral radiographs, and facial photographs. Intraoral color photographs play a very important clinical and legal role; they record the status of the oral soft and hard tissues, especially as regards pretreatment oral hygiene status, gingival health, and the presence of enamel defects, both congenital and acquired. From a diagnostic point of view, what might not make a mental imprint on intraoral examination will make a strong impression when a slide is projected onto a screen and enlarged many times life size.

Intraoral photographs also provide a valuable aid in case presentations, as they are visually more striking to parents and patients than white plaster casts. In fact, a series of photographic slides documenting the progress of treatment in certain types of cases is an excellent visual aid.

Case presentations to study clubs and other groups would be greatly improved if, in addition to pre- and posttreatment slides, serial photographs taken throughout the treatment period to document treatment mechanics were also shown. Many orthodontists already do this in selected cases, but it is time consuming and the photographic results are not always entirely satisfactory. One of the major problems is the difficulty in taking consistently good standardized photographs. A camera setup for intraoral occlusal views is currently available commercially.† This camera takes excellent standardized photographs, but only prints (black and white or color) are produced. For the purposes of visual aids, intraoral slide exposures are desirable.

The purpose of this article is to report a convenient and relatively accurate method of taking standardized buccal and occlusal intraoral photographs and to show how a series of photographs taken through the treatment period might best be presented.

The photographic system

The two most popular clinical intraoral camera systems in use today employ the 35 mm. single lens reflex camera body. One system uses an extension bellows with a 100 mm. or 105 mm. short-mount lens. The other uses a macro lens with a focal length of 90 or 100 mm.

An advantage of the bellows system for serial photography is that the extension rail is

*Associate Professor, Department of Orthodontics, University of Oregon Health Sciences Center.
†Orthoscan, Unitek Corp., Monrovia, Calif.

0002-9416/79/040431+07$00.70/0 © 1979 The C. V. Mosby Co.

Dental Monitoring Ex. 2038
Align Technology, Inc., v. Dental Monitoring SAS.
IPR2024-00110
Page 1 of 7

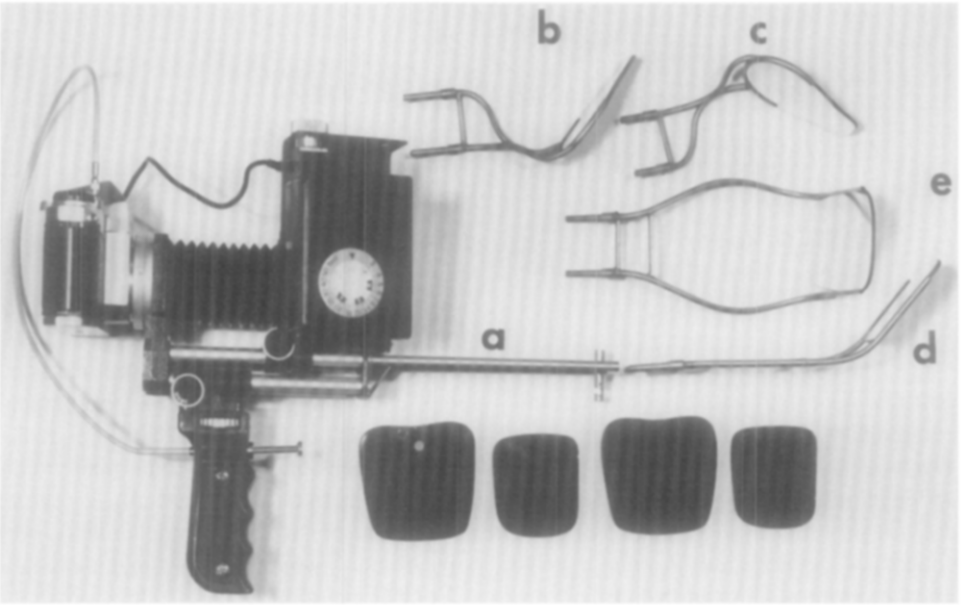

Fig. 1. The camera setup. A 35 mm. single lens reflex camera with extension bellows and a 100 mm. short-mount lens, with a pistol grip, cable release, and rotating bracket carrying the electronic flash unit. Fitting into the upper rail of the bellows is a universal attachment *(a)* into which fits the mirror holders: left *(b)* and right *(c)*, buccal and upper *(d)* and lower *(e)* occlusal. There are three sizes of occlusal mirror. One size of buccal mirror fits all.

calibrated and the amount of extension can be recorded for future reference. In this way, the same image size on the film can be reproduced for each exposure.

A pistol grip with cable release is incorporated into both systems, so that the camera is held with one hand while the photographer has the other hand free. The flash unit of choice is one that provides a point source of illumination. The electronic flash unit is mounted on a rotating bracket which can be positioned to provide optimal illumination for each view taken.

Five intraoral views are commonly taken in orthodontic cases: a frontal view with the teeth in occlusion, right and left buccal views with the teeth in occlusion, and upper and lower occlusal views. The frontal view is taken with the lips retracted with cheek retractors. In addition, rhodium-coated first-surface mirrors* greatly facilitate the buccal and occlusal views. Frequently one sees published intraoral buccal views that were taken with only cheek retraction. The result is that the molar teeth are excluded from the photograph. Rarely is the camera lens at a right angle to the buccal teeth, and this results in a distorted view of the buccal occlusion. This can be overcome by use of the buccal mirror. Most patients can easily be shown how to hold the cheek retractors, thus allowing the operator to concentrate on the photography. With only one hand free, however, the operator has difficulty focusing the camera and adjusting the position of the mirror in the patient's mouth. While a chairside assistant can help, she cannot see the camera field, and with

*Evaporated Metal Films, Ithaca, N. Y.



Fig. 2. Close-up of the fit of the universal attachment (Fig. 1, *a*) into the upper rail of the bellows.

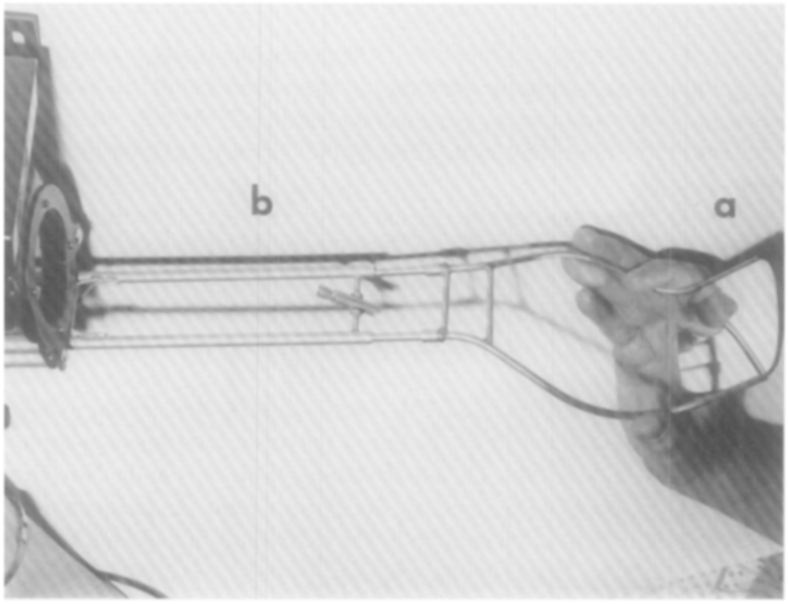

Fig. 3. Close-up of an occlusal mirror holder *(a)* fitted into the universal attachment *(b)*.

verbal instructions valuable time is lost before everything is correctly oriented. In many offices the whole photographic procedure is usually carried out by an assistant alone. Therefore, there is a definite need to simplify mirror orientation.

To ensure standardized views of the mouth, one would like to have the object being photographed occupy the same area of the frame at each exposure. Most important, however, the orientation of the camera to the teeth being photographed should be consistently reproducible. Since the buccal and occlusal views are best taken as reflections in an

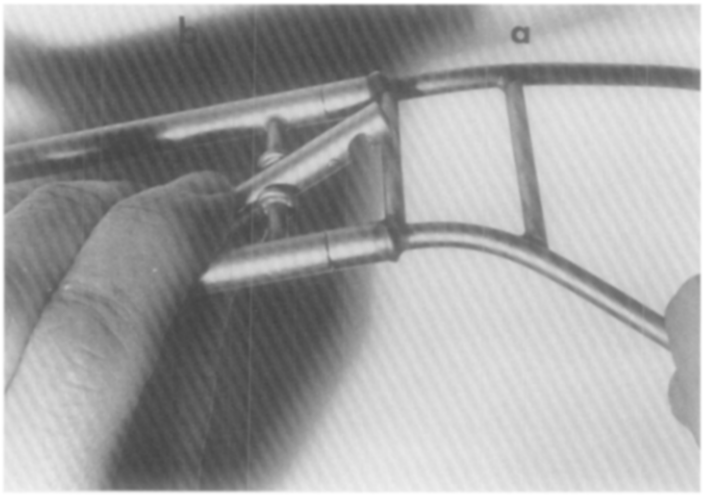

Fig. 4. Close-up of the spring-loaded mechanism locking the mirror holder *(a)* and the universal attachment *(b)*.

intraoral mirror, it is much more difficult to get the three elements—camera, mirror, and teeth—in a reproducible relationship. However, if the mirror is held in a fixed relationship to the camera, the image-size and focusing are standardized. The only other variable then is for the operator to be consistent in positioning the mirror in relation to the teeth to be photographed.

I have developed a set of mirror holders and designed intraoral rhodium-coated mirrors which greatly facilitate the taking of standardized intraoral photographs. The advantage of these mirror holders is that they make intraoral photography a one-person operation which can be achieved in less time and with greater ease, as well as improving the results. With practice, it is relatively easy to reproduce the orientation of the mirror for a particular view.

The mirror holders are constructed of $^{3}/_{16}$ inch stainless steel tubing with solid ends measuring $^{7}/_{32}$ inch in diameter which fit into a universal attachment made of ¼ inch stainless steel tubing which, in turn, fits into the tubing of the rails of the Novoflex bellows system (Figs. 1, 2, 3, and 4). (The universal attachment could be designed to screw into the tripod screw hole under the camera body for use with a macro lens system or with another bellows system, such as Minolta's.)

There are four mirror holders: a right and left buccal, and an upper and lower occlusal (Fig. 1). The mirrors slide into a groove formed by cutting the tubing at the end of the mirror holder in half (Fig. 5).

One buccal mirror of universal size suffices. The mirror is tapered at its posterior end so that it will fit small mouths. Its shape produces cheek retraction as well. Three different-sized occlusal mirrors are necessary for the range of arch widths encountered (Fig. 1). All these mirrors fit into the same occlusal mirror holder.

In this setup the film-mirror distance is fixed. A more complicated system could be devised with an adjustable film-mirror distance, but this is not necessary. The angulation of the buccal mirror to the film plane and to the buccal teeth is approximately 45 degrees,

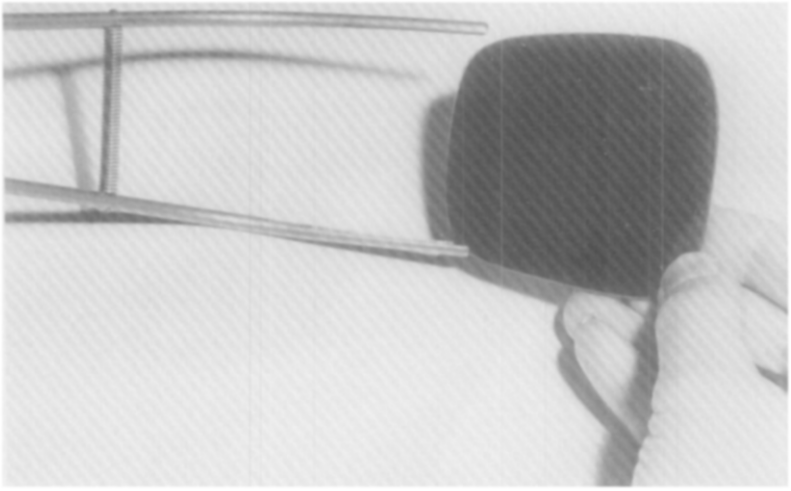

Fig. 5. Fitting an occlusal mirror into the mirror holder.

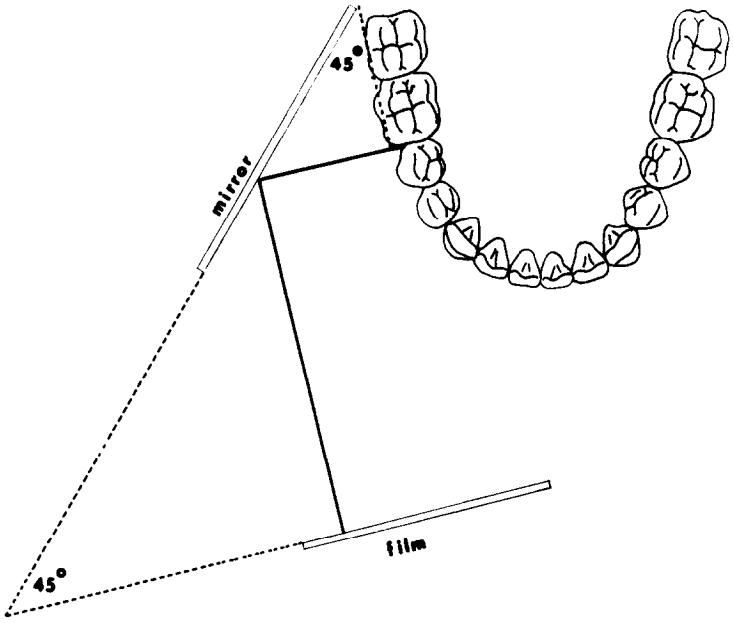

Fig. 6. The buccal mirror should be oriented at 45 degrees to the buccal line of occlusion. The mirror is fixed in relation to the film plane at 45 degrees.

so that in the resultant photograph the light rays are at right angles to the buccal occlusion (Fig. 6).

The angulation of the occlusal mirrors is also at 45 degrees to the occlusal plane, but sometimes it is difficult to achieve this because of limitations in mouth opening. As a result either the occlusal view is not right-angled, or the second molars have to be left out of the picture.

Fig. 7. A view showing the positioning of the left buccal intraoral mirror in a patient. Note that the procedure is a single-handed operation. All the photographer has to do is orient the mirror in relation to the buccal occlusion.

The photographic procedure

Prior to the photography, the four mirrors in their holders are placed in a bowl of warm water to prevent fogging in the mouth. When the photographer is ready, the mirror to be used is removed from the water and wiped dry with a soft paper tissue. The mirror holder is then fastened to the universal attachment (Fig. 3).

The patient is instructed to swallow to clear the mouth of saliva. If a buccal view is to be taken, one cheek retractor is placed on the side of the mouth opposite the mirror. If an occlusal view is to be taken, both cheek retractors are placed in the mouth. The mirror is then placed in position in the subject's mouth.

For the buccal views (Fig. 7), excessive cheek retraction by the patient is undesirable, as it stretches the lips and cheeks, making it difficult to position the mirror at 45 degrees to the buccal teeth. The mirror image should include the second molars, and the occlusal plane should bisect the mirror.

For the occlusal views bilateral cheek retraction is used with the occlusal mirrors. The retractors should be torqued slightly, so that the lip is retracted from the incisors of the arch being photographed. The patient should open as wide as possible to facilitate correct positioning of the occlusal mirrors. In some cases it is difficult to get an undistorted occlusal view and still include second molars in the picture. Obtaining the upper occlusal view is facilitated by positioning the chair in its lowest position with the back upright. The lower occlusal view is best taken with the dental chair raised so that the patient's mouth is

at the approximate level of the camera, comfortably held by the photographer in the standing position.

The frontal view, while it does not employ intraoral mirrors, can be standardized by ensuring that the initial photograph eliminates most of the cheek retractors from the view. At this time the amount of bellows extension (on the calibrated rail) should be noted. Subsequent frontal views should be made with the same bellows extension.

While the slides may include within the frame some of the stainless steel tubing from the mirror holders, this is preferable to having fingers in the view. Also, it is a simple matter to mask the border of the slide.

To obtain a series of slides for the whole treatement sequence, intraoral slides should be taken at the beginning of each visit to the office. It would be optimal if the interval between visits was 1 to 2 weeks, especially during leveling, alignment, and space closure, but of course this usually is impractical. The reason for photographing at the beginning of the appointment is to record the mechanics, arch wires, and auxiliaries which have produced the change to that point in time. Patients should brush their teeth prior to the photographic procedure, so as to remove any plaque or food debris present.

Showing the slides as a serial sequence

The slides should be presented as a serial sequence, one view at a time. Two methods can be used. One method employs a dissolve unit to simulate time-lapse photography. Eastman Kodak manufactures a dissolve unit which is used with two slide projectors. The first projector shows one slide, which then dissolves into the next slide located in the second projector, etc. Rollei produces a projector with two lenses and a dissolve mechanism in one unit.

The other method is to produce a film strip or videotape from the slide sequence. Obviously, this depends on the equipment available for showing the series. However, with the commercial production of videotape recorders which can be played through a home television set, the use of the videotape in the office is a definite possibility.

In producing a videotape from slides, if there are slight discrepancies in mirror-to-teeth orientation, this can be corrected by tilting the slide projector so that a "best fit" superimposition exists from one slide to the next.

Summary

A recently developed system of mirror holders which makes the taking of standardized intraoral photographs less time consuming and more precise has been described. By fixing the relationship of the intraoral mirror to the camera, all that is necessary is to consistently orient the mirror to the teeth being photographed. Because the operator no longer has to position the mirror with one hand while holding the camera in the other hand, the whole operation of intraoral photography is greatly simplified.

By producing serial slides of the progress of orthodontic treatment, a visual sequence of treatment can be prepared for viewing by patients, for educational purposes, and for showing at meetings and study clubs.

The author would like to thank Bud Renner who made the mirror holders and Paul Klein for his helpful advice.