A Phase I Study of Intravitreal Vascular Endothelial Growth Factor Trap-Eye in Patients with Neovascular Age-Related Macular Degeneration

Quan Dong Nguyen, MD, MSc,[1] Syed Mahmood Shah, MBBS,[1] David J. Browning, MD,[2] Henry Hudson, MD,[3] Peter Sonkin, MD,[4] Seenu M. Hariprasad, MD,[5] Peter Kaiser, MD,[6] Jason S. Slakter, MD,[7] Julia Haller, MD,[1] Diana V. Do, MD,[1] William F. Mieler, MD,[5] Karen Chu, MS,[8] Ke Yang, PhD,[8] Avner Ingerman, MD,[8] Robert L. Vitti, MD, MBA,[8] Alyson J. Berliner, MD, PhD,[8] Jesse M. Cedarbaum, MD,[8] Peter A. Campochiaro, MD[1]

Purpose: To determine the safety, tolerability, maximum tolerated dose, and bioactivity of an intravitreal injection of vascular endothelial growth factor (VEGF) Trap-Eye, a fusion protein of binding domains from human VEGF receptors 1 and 2 with human immunoglobulin-G Fc that binds VEGF family members, in patients with neovascular age-related macular degeneration (AMD).

Design: Dose-escalation, multicenter, interventional clinical trial.

Participants: Twenty-one patients (13 female, 8 male) with neovascular AMD (NVAMD) and lesions ≤12 disc areas in size and ≥50% active choroidal neovascularization (CNV) with best-corrected visual acuity (BCVA) ≤20/40 received a single intraocular injection of 0.05 mg (n = 3), 0.15 mg (n = 3), 0.5 mg (n = 3), 1 mg (n = 6), 2 mg (n = 3), or 4 mg (n = 3) of VEGF Trap-Eye.

Methods: Safety assessments included eye examinations, vital signs, and laboratory tests. Measures of bioactivity included changes from baseline in BCVA, optical coherence tomography (OCT), and fluorescein angiography. The primary end point was 6 weeks and patients were followed up for 12 weeks.

Main Outcome Measure: Safety assessments.

Results: There were no serious adverse events and no identifiable intraocular inflammation. The mean decrease in excess foveal thickness for all patients was 104.5 μm at 6 weeks, and the mean increase in visual acuity was 4.43 letters. In the 2 highest dose groups combined (2 and 4 mg), the mean increase in BCVA was 13.5 letters, with 3 of 6 patients demonstrating improvement of ≥3 lines and 3 patients requiring no adjunctive treatment of any type for 12 weeks. Some showed elimination of fluorescein leakage and reduction in area of CNV.

Conclusions: Intravitreal injection of up to 4 mg of VEGF Trap-Eye in patients with NVAMD was well tolerated with no evidence of ocular inflammation. Although the number of patients in each cohort was small, there was evidence of bioactivity, because several patients, especially those receiving 2 or 4 mg of VEGF Trap-Eye, showed substantial improvement in BCVA associated with reductions in foveal thickness. Phase III trials to investigate the efficacy of intraocular VEGF Trap-Eye in patients with NVAMD are under way.

Financial Disclosure(s): Proprietary or commercial disclosure may be found after the references.
Ophthalmology 2009;116:2141–2148 © 2009 by the American Academy of Ophthalmology.

Age-related macular degeneration (AMD) is the most common cause of severe vision loss in patients aged more than 60 years in developed countries.[1] Patients with non-neovascular AMD are at risk for development of choroidal neovascularization (CNV) and thereby converting to neovascular AMD (NVAMD). Patients with NVAMD account for only approximately 10% of patients with AMD, but they account for the majority of severe vision loss.[1]

The pathogenic events underlying conversion from non-neovascular to NVAMD are uncertain, but studies in animal models suggest that increased expression of vascular endothelial growth factor (VEGF) is likely to play a critical role. Inhibition of VEGF receptor signaling by systemic administration of kinase inhibitors[2] or blockade of VEGF by intraocular injection of an anti-VEGF antibody fragment[3] significantly suppresses CNV in animal models. These data suggest that VEGF is an important therapeutic target for treatment of CNV. This concept has been confirmed in clinical trials testing the effects of VEGF antagonists in patients with NVAMD. Intraocular injections of pegaptanib

© 2009 by the American Academy of Ophthalmology
Published by Elsevier Inc.
ISSN 0161-6420/09/$–see front matter
doi:10.1016/j.ophtha.2009.04.030

Celltrion Exhibit 1028
Page 1

(Macugen, OSI Pharmaceuticals, Melville, NY), an aptamer that specifically binds $VEGF_{165}$, every 6 weeks for 1 year in patients with NVAMD reduced the percentage of patients who experienced severe loss of vision (≥15 letters) from 45% in the sham injection group to 30% but did not lead to significant improvement in vision.[4] Monthly intraocular injections of ranibizumab (Lucentis, Genentech, San Francisco, CA), a Fab fragment of an antibody that binds all isoforms of VEGF-A, reduced the percentage of patients who had severe loss of vision to 5% and caused significant improvement in visual acuity (VA) in 34% to 40%.[5,6] It is not certain why ranibizumab is so superior to pegaptanib, but one possibility is that other isoforms of VEGF in addition to $VEGF_{165}$ play an important role in the pathogenesis of CNV.

There are a number of gene products that share homology with VEGF-A and have similar activities because they activate VEGF receptor 1 or 2. The genes that code for VEGF-A and these other proteins, VEGF-B, C, and D, and placental growth factors 1 and 2, constitute the VEGF gene family. The role of VEGF family members other than VEGF-A in ocular neovascularization has not been completely elucidated, but there is evidence to suggest that placental growth factor 1 participates.[7]

VEGF Trap is a recombinant protein in which the binding domains of VEGF receptors 1 and 2 are combined with the Fc portion of immunoglobulin-G. The receptor portion of the molecule has a high affinity for all VEGF-A isoforms (Kd<1 pM), placental growth factors 1 and 2, and VEGF-B.[8] Therefore, VEGF Trap is distinguished from ranibizumab by its higher binding affinity for all VEGF-A isoforms and its ability to inhibit other VEGF family members. A randomized, multicenter, placebo-controlled clinical trial investigating the effect of intravenous VEGF Trap in patients with NVAMD showed elimination of approximately 60% of excess retinal thickness after either single or multiple infusions.[9] The maximum tolerated dose of intravenous VEGF Trap in this study population was 1.0 mg/kg; at 3 mg/kg, hypertension and proteinuria, which are class effects of systemic anti-VEGF therapy, were noted. Thus, alternative routes of delivery to increase therapeutic window and to decrease adverse events, were investigated.

Intravitreal administration of VEGF Trap strongly suppressed laser-induced CNV in mice[10] and primates (Wiegand et al. ARVO abstract 1411, 2005). These findings led to the development of a formulation for intraocular delivery, VEGF Trap-Eye, a formulation using ultra-purified VEGF Trap with a combination and concentration of buffers compatible with ocular tissues. In primate toxicology studies, there were no systemic safety signals after intraocular injections of VEGF Trap-Eye, and there was an excellent ocular safety profile based on ocular examinations, color photography, fluorescein angiography (FA), electroretinography, and postmortem microscopic examination of ocular tissues.[11] The only abnormality identified was mild, reversible inflammation in the anterior chamber and vitreous in some primates after intraocular injection, clearing the way for the Phase 1 clinical trial reported.

Materials and Methods

Study Design

The study was conducted at 5 study sites in compliance with the Declaration of Helsinki, US Code 21 of Federal Regulations, and the Harmonized Tripartite Guidelines for Good Clinical Practice (1996) and was reviewed and approved by the Western Institutional Review Board. A dose-escalation design was used to investigate 6 doses of VEGF Trap-Eye (0.05, 0.15, 0.5, 1, 2, and 4 mg) in patients with subfoveal CNV due to NVAMD. There was a 2-week waiting period after dosing the last patient in each cohort and dosing the first patient in the next cohort to watch for safety signals. Six weeks after injection of VEGF Trap-Eye, patients returned to standard care and were able to receive any treatment judged to be indicated by the investigator. Patients were monitored for 12 weeks after intravitreal VEGF Trap-Eye administration as part of the active phase of the study but were monitored for safety with eye examinations every 3 months for 1 year.

Table 2. Baseline Characteristics of the Study Population

Parameters	Mean	Range
Age	78 yrs	67–88 yrs
BCVA*	39.3	0–72
Snellen equivalent	~20/160	20/40 to >20/800
Foveal thickness† (automated, fast macular scans)	375 μm	259–616 μm (normal = 179 μm)
Foveal + lesion thickness (manual, posterior pole scans)	552 μm	332–1021 μm (normal = 270 μm)
No. of prior treatments in study eye (PDT ± steroids, pegaptanib, or investigational small interfering RNA)	None: 10 patients ≥1: 11 patients	
Lesion type	Classic: 3 (14%) Occult: 8 (38%) Minimally classic: 6 (29%) Predominantly classic: 4 (19%)	
Gender	13 female : 8 male	
Study eye	11 left : 10 right	

BCVA = best-corrected visual acuity; PDT = photodynamic therapy; VA = visual acuity.
*Early Treatment Diabetic Retinopathy Study letters read as measured by electronic VA.
†Scans were gradable in 20 of 21 patients.

Celltrion Exhibit 1028
Page 2

Study Population

The main inclusion criteria for the study were as follows: (1) male or female (any ethnicity), 50 years of age or older; (2) diagnosis of NVAMD in the study eye with leaking subfoveal CNV ≤12 disc areas (measured according to the protocol of the Macular Photocoagulation Study);[12] (3) best-corrected visual acuity (BCVA) of 20/40 or worse; and 4) central subfield thickness ≥250 μm measured by optical coherence tomography (OCT). Other inclusion criteria and exclusion criteria are listed in Table 1 (available at http://aaojournal.org).

Intravitreal Administration of Vascular Endothelial Growth Factor Trap-Eye and Study Activities

A sterile lid speculum was inserted, topical anesthesia was applied, and the conjunctiva was irrigated with 5% povidone iodine. After additional local anesthesia, a 30-gauge needle was inserted through the pars plana and 100 μl containing a prespecified amount of VEGF Trap-Eye was injected into the vitreous cavity. Funduscopic examination was done to confirm retinal perfusion, and the patients were observed for 1 hour or until intraocular pressure returned to normal. Patients were closely monitored for safety and tolerability using the following assessments and procedures: BCVA; slit-lamp biomicroscopy; indirect ophthalmoscopy; tonometry; adverse events reporting; vital signs; physical examinations; serum electrolytes; creatinine; quantitative protein determination in 24-hour urine specimens; and measurement of serum neutralizing antibodies directed against VEGF Trap-Eye. Stereoscopic color fundus photographs and FA were performed at baseline and week 6. Optical coherence tomography was performed at each study visit.

Optical Coherence Tomography

The Digital Angiographic Reading Center (DARC, New York, NY) analyzed fluorescein angiograms, and the DARC/Digital OCT Reading Center (Cleveland, OH) analyzed OCT scans. All images were evaluated with the grader masked with respect to treatment group. Optical coherence tomography was performed using StratusOCT (Carl Zeiss Meditec, Dublin, CA). The Digital OCT Reading Center provided detailed instruction in the protocol for image acquisition. Standard protocol (6-mm fast macular thickness map and 6×6-mm cross-hair) was used. Foveal thickness (in micrometers, defined as the mean height of the neurosensory retina in a central 1-mm diameter area) and total macular volume (in

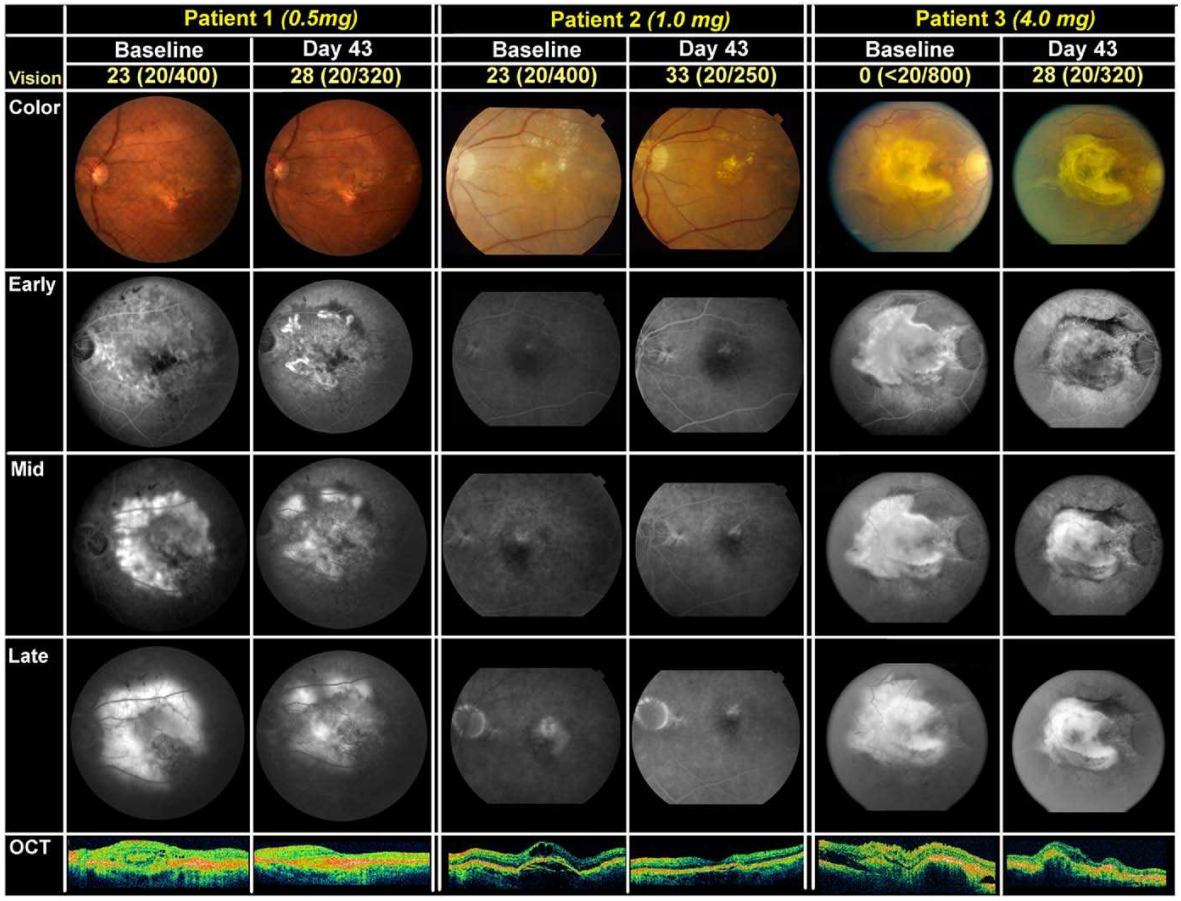

Figure 1. Color fundus photographs, fluorescein angiograms, and OCT at baseline and 6 weeks (Day 43) after intravitreous injection of 1 mg (Patient 1), 2 mg (Patient 2), or 4 mg (Patient 3) of vascular endothelial growth factor Trap-Eye. OCT = optical coherence tomography.

Celltrion Exhibit 1028
Page 3

cubic millimeters) were automatically computed by the StratusOCT software version 4.0. The median baseline central retinal/lesion thickness was measured by masked graders.

Fluorescein Angiography

High-resolution digital FA was performed using a Zeiss FF4 fundus camera (Carl Zeiss, Oberkochen, Germany) attached to a Medical Research Professionals (Boston, MA) capture station. A modified FA acquisition protocol was used for image acquisition, and compliance was monitored by a site visit. Digital images of FA were then sent to the DARC for analyses.

Data Analysis

Analyses of biological activity included central retinal/lesion thickness, foveal thickness as assessed by OCT, CNV area and total lesion size assessed by FA, and VA. The primary analyses included assessment of change from baseline in bioeffect variables at Day 43. Mean changes from baseline at each visit were displayed. Analyses were also performed by pooled dose groups of low (0.05, 0.15, and 0.5 mg), intermediate (1.0 mg), and high (2.0 and 4.0 mg) doses to show the bioeffect at different dose levels. The number of patients who needed additional treatments after the primary end point was determined and evaluated with regard to their bioeffect. All data including images were made available to the investigators.

Results

The baseline characteristics of the 21 patients included in the study are listed in Table 2. Although the majority of the patients had

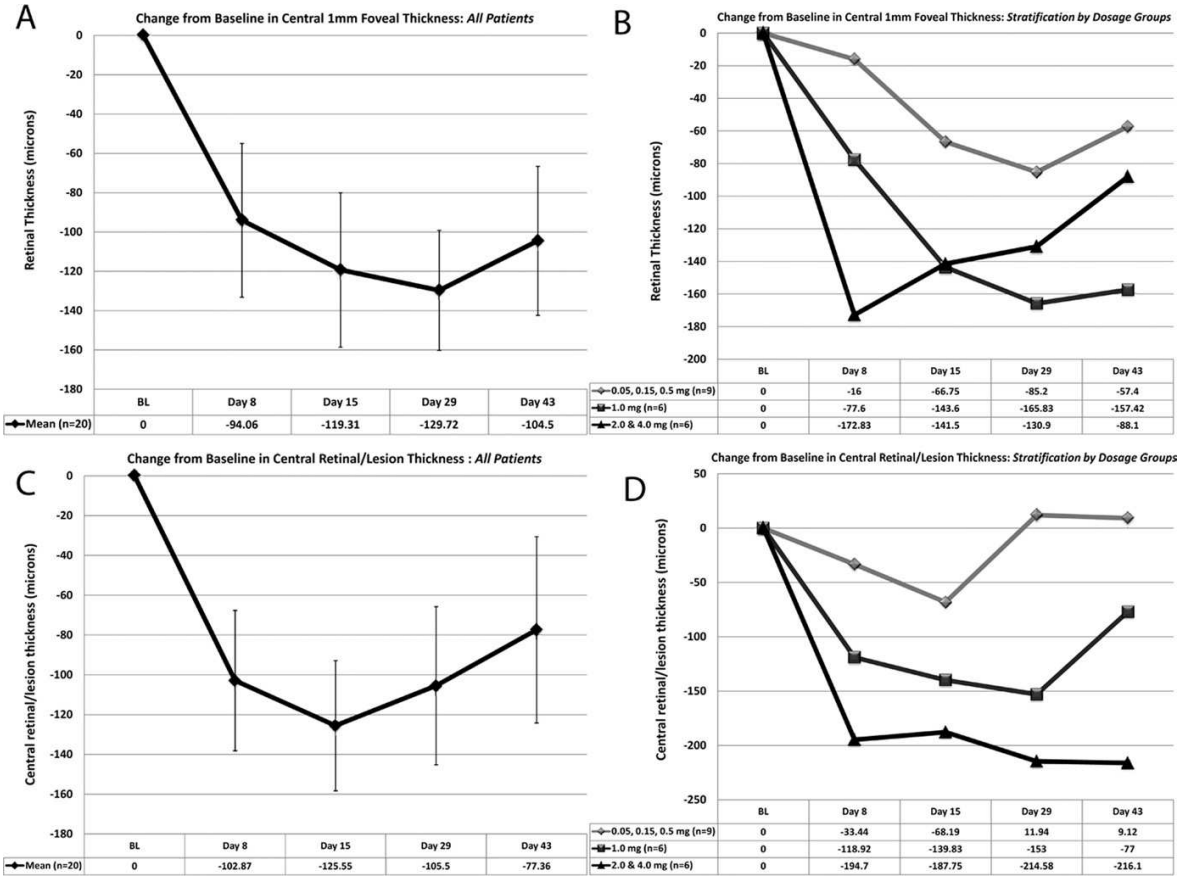

Figure 2. Changes in foveal thickness or combined foveal and lesion thickness after a single injection of VEGF Trap-Eye. Patients received a single intraocular injection of 1 of 6 doses of VEGF Trap-Eye and at several time points after injection had Fast Macular OCT scans to measure central subfield foveal thickness **(A, B)** and posterior pole scans to measure combined foveal and lesion thickness **(C, D)**. Data are shown for 20 of 21 study patients who had gradable scans. The mean change from baseline in foveal thickness for all patients was substantially reduced 1 week (Day 8) after injection, was maximally reduced by 2 weeks (Day 15), and remained stable between 2 and 6 weeks (Day 43) **(A)**. Stratification into low- (0.05, 0.15, and 0.5 mg), intermediate- (1.0 mg), and high- (2.0 and 4.0 mg) dose groups of VEGF Trap-Eye showed minimal effect in the low-dose group, whereas the intermediate and high-dose groups showed substantial and comparable reductions in foveal thickness **(B)**. The mean change from baseline in combined foveal and lesion thickness was similar to that for foveal thickness between baseline and 2 weeks (Day 15) but regressed somewhat between 2 and 6 weeks (Day 43) **(C)**. The mean reduction from baseline in lesion and foveal thickness was greater in the intermediate- and high-dose groups compared with the low-dose group **(D)**. OCT = optical coherence tomography; VEGF = vascular endothelial growth factor.

Celltrion Exhibit 1028
Page 4

received prior treatments for their NVAMD, an effort was made to determine the presence of classic or occult CNV within lesions.

Safety

There were no ocular serious adverse events or evidence of inflammation. There were also no systemic serious adverse events or changes in laboratory values. There was no dose-limiting toxicity, and a maximum tolerated dose was not identified.

Fluorescein Angiography and Optical Coherence Tomography

Many of the patients in this study had advanced disease with substantial subretinal fibrosis and a poor visual prognosis but had active CNV in addition to subretinal fibrosis, allowing some assessments of drug effects. Because of advanced disease, not all fluorescein angiograms were able to be assessed for changes in lesion characteristics or size. Figure 1 shows fluorescein angiograms and OCT scans at baseline and 6 weeks after intravitreous injection of VEGF Trap-Eye in 3 patients. One patient (Patient 1) had 20/400 vision due to a large CNV lesion that showed substantial leakage during the late phase of the angiogram and moderate thickening of the overlying retina on OCT (Fig 1, column 1). Six weeks after injection of 0.5 mg of VEGF Trap-Eye, BCVA was 20/320 and there was less filling of the CNV, as illustrated by areas of relative hypofluorescence, reduced leakage shown by less fuzziness of most regions of the lesion, and decreased macular thickening on OCT (Fig 1, column 2). Another patient (Patient 2) had BCVA of 20/400 and showed a small region of classic CNV associated with a larger temporal arc of occult CNV and substantial leakage, as illustrated by fuzziness during the late phase of the angiogram and a pocket of intraretinal fluid on OCT (Fig 1, column 3). Six weeks after injection of 1 mg of VEGF Trap-Eye, BCVA was 20/250, the small area of classic CNV stained but did not leak, and the occult CNV was indiscernible, suggesting possible regression (Fig 1, column 4). The pocket of intraretinal fluid seen on the baseline OCT scan was eliminated. At baseline, a third patient (Patient 3) had BCVA of 20/800 due to a large lesion containing central subretinal fibrosis surrounded by active CNV associated with subretinal hemorrhage (Fig 1, column 5). There was staining of the fibrosis and leakage from the surrounding CNV, which appeared fuzzy during the late phase of the angiogram, and the OCT showed subretinal and intraretinal fluid. Six weeks after injection of 4 mg of VEGF Trap-Eye, BCVA was 20/320, the subretinal fibrosis was more defined on the color photograph and still stained during FA, but the surrounding CNV was gone, suggesting regression or contraction. There was no leakage, and OCT showed resolution of subretinal fluid and minimal intraretinal fluid (Fig 1, column 6).

Changes in Optical Coherence Tomography Measurements

The OCT scans from 20 patients were analyzed by the reading center; by mistake 1 patient did not receive an OCT at baseline and therefore could not be included in the analysis. The mean decrease in foveal thickness at 6 weeks for all patients across all 6 doses of VEGF Trap-Eye was 104.5 μm (Fig 2A). Patients were divided into those receiving low (0.05, 0.15, and 0.5 mg), intermediate (1.0 mg), and high (2.0 and 4.0 mg) doses of VEGF Trap-Eye. Patients injected with 1.0 mg or greater of VEGF Trap-Eye showed a substantially greater reduction in foveal thickness compared with those injected with 0.5 mg or less (Fig 2B).

Posterior pole scans measure thickness in the CNV complex, subretinal fluid, and retinal thickness. The reduction in this combined measure of lesion and foveal thickness after injection of VEGF Trap-Eye was similar to but somewhat less than that for foveal thickness.

As was true for foveal thickness, the reduction in combined foveal and lesion thickness was greater for those patients injected with 1.0 mg or more of VEGF Trap-Eye compared with those injected with 0.5 mg or less (Fig 2D).

Changes in Visual Acuity

Ninety-five percent of patients injected with any dose of VEGF Trap-Eye showed stable or improved vision at 6 weeks, and the mean increase in VA was 4.7 letters (Fig 3A). Only 1 patient showed a reduction in BCVA 6 weeks after injection of VEGF

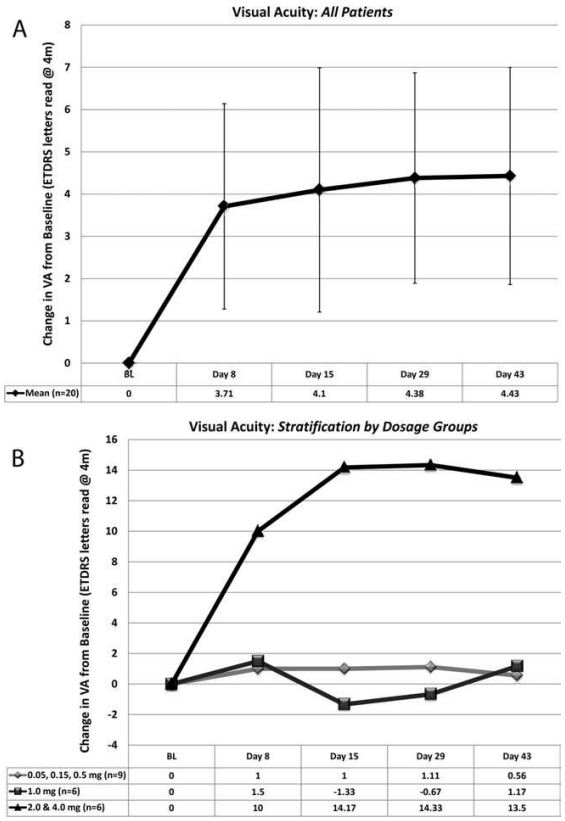

Figure 3. Change in BCVA from baseline after a single intraocular injection of VEGF Trap-Eye. Patients received a single intraocular injection of 1 of 6 doses of VEGF Trap-Eye and at several time points after injection had BCVA measured by the Early Treatment Diabetic Retinopathy Study protocol. **A,** The mean (± standard error of the mean) change in number of letters read at 4 m (not change in Early Treatment Diabetic Retinopathy Study VA score) for all patients showed an improvement of approximately 1 line at 6 weeks (Day 43). **B,** Stratification into low- (0.05, 0.15, and 0.5 mg), intermediate- (1.0 mg), and high- (2.0 and 4.0 mg) dose groups of VEGF Trap-Eye showed negligible change in the low-dose group, 1 letter in the intermediate and 13.5 letters in the high-dose group. BCVA = best-corrected visual acuity; ETDRS = Early Treatment Diabetic Retinopathy Study; VA = visual acuity; VEGF = vascular endothelial growth factor.

Celltrion Exhibit 1028
Page 5

Trap-Eye; that patient received a 1.0 mg injection and had a reduction of 18 letters. Patients in the low and intermediate dose groups had a mean increase in VA of 1 letter. Patients in the high-dose group had a mean increase in VA of 13.5 letters with 3 of the 6 patients improved by 3 or more lines (Fig 3B).

Need for Additional Treatment 6 Weeks after Injection of Vascular Endothelial Growth Factor Trap-Eye

Nine of 21 patients received other treatment in the study eye 6 weeks after injection of VEGF Trap-Eye, and 1 patient received

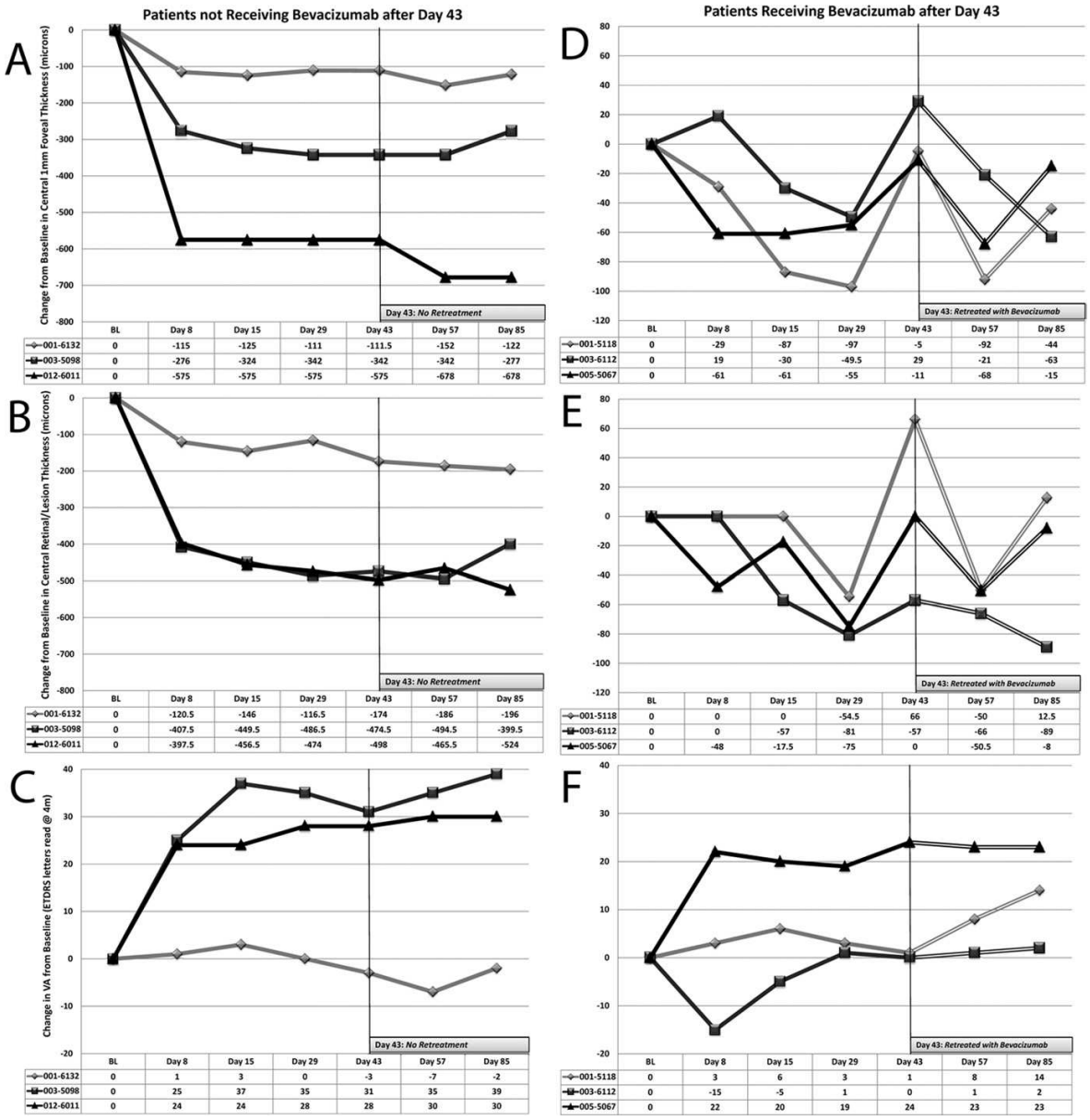

Figure 4. Changes in foveal thickness and BCVA at all time points to 12 weeks (Day 85) in patients treated with 2 or 4 mg of VEGF Trap-Eye. **A, B,** Change from baseline in central subfield foveal thickness and combined foveal and lesion size thickness, respectively, in 3 patients who showed no evidence of recurrent leakage at 6 weeks (Day 43). Relative stability is demonstrated between 1 and 12 weeks (Day 85) after a single injection. **C,** Change from baseline in BCVA measured as number of letters read at 4 m in 3 patients who showed no evidence of recurrent leakage at 6 weeks (Day 15). Relative stability is demonstrated between 1 and 12 weeks (Day 85) after a single injection. **D, E,** Change from baseline in central subfield thickness combined foveal and lesion size thickness, respectively, in 3 patients who showed recurrent leakage at 6 (Day 43) weeks and required an intraocular injection of bevacizumab. **F,** Change from baseline in BCVA in 3 patients who showed recurrent leakage at 6 (Day 43) weeks and required an intraocular injection of bevacizumab. BCVA = best-corrected visual acuity; VEGF = vascular endothelial growth factor.

Celltrion Exhibit 1028
Page 6

additional treatment at 4 weeks. Among the 6 patients injected with 2 or 4 mg of VEGF Trap-Eye, 3 had no evidence of leakage and no increase in foveal and combined lesion thickness at 6 weeks (Fig 4A, B), whereas 3 showed leakage and an increase in foveal and combined lesion thickness between 4 and 6 weeks and thus received an intraocular injection of 1.25 mg of bevacizumab (Fig 4D, E). The 3 patients who did not require treatment at 6 weeks were still stable with regard to foveal and combined lesion thickness (Fig 4A, B) and VA (Fig 4C) at 12 weeks. One of the patients in the high-dose VEGF Trap-Eye group who required additional treatment at 6 weeks showed improvement in VA from baseline of 20 letters despite the need for additional treatment, and this benefit was maintained 6 weeks after the injection of bevacizumab (Fig 4F).

Discussion

Intravenous infusions of VEGF Trap showed evidence of biologic activity in patients with NVAMD by reducing excess foveal thickness and halting progression of CNV, but infusions of 3 mg/kg were complicated by hypertension.[9] In this study, VEGF Trap specifically formulated for intraocular injection, VEGF Trap-Eye, was investigated in patients with NVAMD. After a single intraocular injection of doses ranging from 0.05 to 4 mg of VEGF Trap-Eye, there were no ocular or systemic serious adverse events and none of the patients showed any hypertension or proteinuria. There was no intraocular inflammation or other significant problems in the eye. Thus, a single intraocular injection of up to 4 mg of VEGF Trap-Eye appears safe and well tolerated.

Optical coherence tomography is an outstanding tool for assessing effects of drugs on CNV because it provides an objective measure of the amount of fluid within or under the retina. Excess foveal thickness is a measure of excess fluid within the retina, and it was substantially reduced in a dose-dependent manner after intraocular injection of VEGF Trap-Eye. There were modest effects after single injections of 0.05 to 0.5 mg and substantial effects after single injections of 1.0 to 4.0 mg. Foveal thickness is completely objective because it is calculated by the software, but it suffers from errors in recognizing correct retinal borders and does not take into account the thickness of CNV lesions and subretinal fluid. Masked grading of combined thickness of CNV lesions and overlying retina takes into account fluid beneath the retina, as well as fluid within the retina, and this parameter was also reduced in a dose-dependent manner by injections of VEGF Trap-Eye. This improvement in anatomic outcome measures was accompanied by evidence of functional improvement in VA, which was also most prominent after injections of 1.0 mg or more of VEGF Trap-Eye. Four of 6 patients treated with 2.0 or 4.0 mg of VEGF Trap-Eye improved by 3 or more lines on an Early Treatment Diabetic Retinopathy Study VA chart. Despite the lack of a placebo control group, the magnitude of these improvements in VA, their dose-dependency, and their correlation with anatomic improvement all strongly indicate that they represent true VEGF Trap-Eye–related effects and not random changes.

Patients were evaluated for the need for adjunctive treatments 6 weeks after injection of VEGF Trap-Eye. Three of 6 patients who had received 2 or 4 mg showed no evidence of recurrent leakage or increase in foveal thickness between 2 and 6 weeks. These patients continued to show no leakage and maintained gains in VA at 12 weeks after injection, suggesting that a single injection of 2 or 4 mg may have persistent effects for 3 months in some patients.

Many of the patients had substantial subretinal fibrosis, making grading of FAs difficult, but as exemplified in Figure 1, some patients who received 1 mg or more of VEGF Trap-Eye showed marked reduction in fluorescein leakage correlating with decreased central retinal thickening on OCT. Reduced leakage indicating resorption of intraretinal and subretinal fluid is a well-recognized class effect of VEGF antagonists in patients with NVAMD.[5] In addition, some patients (see Patients 2 and 3 in Fig 1) showed areas of CNV seen at baseline that were no longer distinguishable at 6 weeks after injection of VEGF Trap-Eye, suggesting the possibility of regression of CNV. Although the results are preliminary and must be confirmed, they raise the possibility that VEGF family members other than VEGF-A may contribute to survival of endothelial cells in CNV in patients with NVAMD and that by blocking multiple VEGF family members, partial regression of CNV may occur. Partial regression may delay the recurrence of leakage, therefore prolonging the therapeutic effects of the drug. In diseases other than AMD, such as pathologic myopia and ocular histoplasmosis, endothelial cells in CNV may show greater dependence on VEGF-A for survival than is the case in patients with NVAMD, because partial regression of CNV was seen after systemic infusions of bevacizumab.[13] In that setting, partial regression of CNV was also associated with prolonged leakage-free periods.

In conclusion, the results of this study are encouraging and intriguing, and they raise many questions. How often does intraocular injection of VEGF Trap-Eye cause partial regression of CNV in patients with NVAMD and how strongly is it correlated with prolonged leakage-free periods? Can repeated injections of VEGF Trap-Eye promote further regression CNV? What is an appropriate interval between injections? Will repeated injections result in retinal toxicity? What are the long-term effects of VEGF Trap-Eye on VA in patients with NVAMD? These questions and others are being addressed in ongoing clinical trials.

References

1. Klein R, Klein BE, Linton KP, DeMets DL. The Beaver Dam Eye Study: the relation of age-related maculopathy to smoking. Am J Epidemiol 1993;137:190–200.
2. Kwak N, Okamoto N, Wood JM, Campochiaro PA. VEGF is major stimulator in model of choroidal neovascularization. Invest Ophthalmol Vis Sci 2000;41:3158–64.
3. Kryzstolik MG, Afshari MA, Adamis AP, et al. Prevention of experimental choroidal neovascularization with intravitreal anti-vascular endothelial growth factor antibody fragment. Arch Ophthalmol 2002;120:338–46.
4. Gragoudas ES, Adamis AP, Cunningham ET Jr, et al, VEGF Inhibition Study in Ocular Neovascularization Clinical Trial Group. Pegaptanib for neovascular age-related macular degeneration. N Engl J Med 2004;351:2805–16.

Celltrion Exhibit 1028
Page 7

5. Rosenfeld PJ, Brown DM, Heier JS, et al, MARINA Study Group. Ranibizumab for neovascular age-related macular degeneration. N Engl J Med 2006;355:1419–31.
6. Brown DM, Kaiser PK, Michels M, et al, ANCHOR Study Group. Ranibizumab versus verteporfin for neovascular age-related macular degeneration. N Engl J Med 2006;355:1432–44.
7. Carmeliet P, Moons L, Luttun A, et al. Synergism between vascular endothelial growth factor and placental growth factor contributes to angiogenesis and plasma extravasation in pathological conditions. Nat Med 2001;7:575–83.
8. Holash J, Davis S, Papadoupoulos N, et al. VEGF-Trap: a VEGF blocker with potent antitumor effects. Proc Natl Acad Sci U S A 2002;99:11393–8.
9. Nguyen QD, Shah SM, Hafiz G, et al, CLEAR-AMD 1 Study Group. A phase 1 trial of intravenously administered vascular endothelial growth factor Trap for treatment in patients with choroidal neovascularization due to age-related macular degeneration. Ophthalmology 2006;113:1522–32.
10. Saishin Y, Saishin Y, Takahashi K, et al. VEGF-TRAP(R1R2) suppresses choroidal neovascularization and VEGF-induced breakdown of the blood-retinal barrier. J Cell Physiol 2003;195:241–8.
11. Zimmer E, Christian BJ, Miller PE, et al. Safety evaluation of intravitreal administration of VEGF trap in Cynomolgus monkeys for 13 weeks. Invest Ophthalmol Vis Sci 2006;47:E-Abstract 1751.
12. Macular Photocoagulation Study Group. Argon laser photocoagulation for neovascular maculopathy: five year results from randomized clinical trials. Arch Ophthalmol 1991;109:1109–14.
13. Nguyen QD, Shah SM, Hafiz G, et al. Intravenous bevacizumab causes regression of choroidal neovascularization secondary to diseases other than age-related macular degeneration. Am J Ophthalmol 2008;145:257–66.

Footnotes and Financial Disclosures

Originally received: January 20, 2009.
Final revision: April 12, 2009.
Accepted: April 15, 2009.
Available online: August 22, 2009. Manuscript no. 2009-85.

[1] Johns Hopkins Wilmer Eye Institute, Baltimore, Maryland.
[2] Charlotte Eye, Ear, Nose, and Throat Associates, Charlotte, North Carolina.
[3] Retina Center, PC, Tucson, Arizona.
[4] Retina-Vitreous Associates, PC, Nashville, Tennessee.
[5] University of Chicago, Chicago, Illinois.
[6] Cleveland Clinic Foundation, Cleveland, Ohio.
[7] Vitreous Retina Macula Consultants of New York, New York.
[8] Regeneron Pharmaceuticals, Inc., Tarrytown, New York.

Financial Disclosure(s):
The author(s) have made the following disclosure(s):
QDN is a recipient of a K23 Career Development Award (EY 13552) from the National Eye Institute. PAC is the George S. and Dolores Dore Eccles Professor of Ophthalmology and Neuroscience. QDN is on the Steering Committee for the phase 3 studies of VEGF Trap-Eye for NVAMD. PAC is on the Safety and Data Monitoring Board for the Regeneron Phase 3 trial of VEGF Trap-Eye for NVAMD, but was not during the time frame of this study. QDN and the Johns Hopkins University have received research funding from Regeneron to support the studies of VEGF Trap-Eye in retinal vascular diseases. KC, KY, AI, RV, and JC were employees of Regeneron during the conduct of the study, which has a commercial interest in VEGF Trap-Eye. JSS received research grant support and travel reimbursement from Regeneron.

Presented in part at: the Meeting of the American Academy of Ophthalmology, November 2006, Las Vegas, Nevada.

Correspondence:
Peter A. Campochiaro, MD, Maumenee 719, The Wilmer Eye Institute, The Johns Hopkins University School of Medicine, 600 North Wolfe Street, Baltimore, MD 21287-9277. E-mail: pcampo@jhmi.edu.

Celltrion Exhibit 1028
Page 8

Table 1. Additional Inclusion and Exclusion Criteria

Inclusion Criteria

(1) Patients eligible for a standard therapy were recommended to have it and could only participate if they refused standard therapy.
(2) For men and women of childbearing potential, willingness to use adequate contraception from screening to 12 weeks after the last dose of VEGF Trap or pegaptanib sodium. Adequate contraceptive measures include oral contraceptives (stable use for ≥2 or more cycles before screening); intrauterine device; Depo-Provera (Pfizer U.S. Pharmaceuticals, New York, NY); Norplant System implants (Wyeth, Madison, NJ); bilateral tubal ligation; vasectomy; condom or diaphragm plus contraceptive sponge, foam, or jelly.
(3) Clear ocular media and clear lens(es) to permit good-quality stereoscopic fundus photography.
(4) If history of ocular or major systemic surgery, including fine-needle biopsy/aspiration, placement of a central venous access device, or removal/biopsy of a skin lesion, it must have been done at least 12 weeks before Visit 2 (Day 1).
(5) Electrocardiogram within 12 weeks before Day 1 that shows no clinically significant abnormalities.
(6) Treated or untreated blood pressure <140/90 mmHg or isolated systolic pressure of <160 mmHg with diastolic pressure of <85 mmHg.
(7) Willingness to comply with study medication and evaluation procedures.
(8) Willing, committed, and able to return for ALL clinic visits.
(9) Able to understand and sign the Informed Consent Form.

Exclusion Criteria

(1) Eligibility for standard therapy unless it was refused.
(2) Presence of a disease other than NVAMD in the study eye that could affect vision or safety assessments.
(3) Previous laser photocoagulation to the center of the fovea in the study eye.
(4) Intraocular surgery or another treatment in the study eye within 3 months of screening.
(5) Symptomatic or unstable coronary artery disease, angina, congestive heart failure, or an arrhythmia requiring active medical management within the last 30 days.
(6) Myocardial infarction or treatment for acute congestive heart failure within the past 6 months.
(7) Malignancy other than basal cell carcinoma of the skin diagnosed and treated within the last 5 years.
(8) History of or present peripheral vascular disease.
(9) Blood pressure, treated or untreated, of >140/90 mmHg on at least 3 repeated determinations on separate days during the 6 weeks before study entry.
(10) Abnormal renal function, as defined by creatinine > upper limit of normal, or proteinuria ≥1+ on 2 repeat determinations, urine protein: creatinine ratio ≥1 or 24-hour urinary protein excretion of ≥300 mg/24 hours.

NVAMD = neovascular age-related macular degeneration; VEGF = vascular endothelial growth factor.

Celltrion Exhibit 1028
Page 9