DECLARATION OF ROGER LOPEZ

I, Peng Hua, pursuant to 28 U.S.C. § 1746 and 37 C.F.R. § 1.68, hereby declare as follows:

1. I am a Translator for ZHCN-EN Translations.

2. I submit this declaration to certify the accuracy of the English translation of a printout of the file 11470032.pdf.

3. I am qualified to perform Chinese to English translations and certify the accuracy of Chinese to English translations.

4. My statements are based on personal knowledge and my review of the printout of the file 11470032.pdf and its Chinese to English translation. If called as a witness about the facts contained in these statements, I could testify competently based on such personal knowledge and the investigation I have conducted.

5. Attached as **Exhibit A** is a true and accurate copy of the printout of the file 11470032.pdf.

6. Attached as **Exhibit B** is a true and accurate copy of an English translation of the printout of the file 11470032.pdf (hereinafter, "File Translation"), which I prepared based on Exhibit A and my personal knowledge of the Chinese and English languages.

7. File Translation is a true and accurate translation of the printout of the file 11470032.pdf from Chinese to English.

8. All statements made herein of my own knowledge are true, and all statements made on information and belief are believed to be true.

Neurent 1114
Neurent v. Foundry
IPR2024-00280

9. I have been warned and am aware that these statements are made with the knowledge that willful false statements and the like so made are punishable by fine or imprisonment, or both, under 18 U.S.C. § 1001.

10. I understand that by submitting this declaration I may be asked to appear for a deposition asking me questions limited to the material in my declaration. With my signature below, I agree to make reasonable efforts to make myself available for such a deposition at a reasonable place and time.

* * *

I declare under the penalty of perjury that the foregoing is true and correct. Executed on ____January 13, 2025_____ in Missouri.

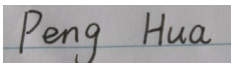

_____

Peng Hua

Exhibit A

附：慢性鼻窦炎鼻息肉临床分型分期及内窥镜鼻窦手术疗效评定标准（1997 年，海口）

中华医学会耳鼻咽喉科学分会

中华耳鼻咽喉科杂志编辑委员会

慢性鼻窦炎的分期依据

病史、内窥镜检查和 CT 扫描。

慢性鼻窦炎、鼻息肉的分型、分期（以侧计，前后筛窦分开计）

1 型单纯型慢性鼻窦炎（保守治疗无效）

1 期：单发鼻窦炎；

2 期：多发鼻窦炎；

3 期：全组鼻窦炎。

2 型慢性鼻窦炎伴鼻息肉

1 期：单发鼻窦炎伴单发性鼻息肉；

2 期：多发鼻窦炎伴多发性鼻息肉；

3 期：全组鼻窦炎伴多发性鼻息肉。

3 型多发性鼻窦炎或全组鼻窦炎伴多发性、复发性鼻息肉和 / 或筛窦骨质增生。

疗效评定标准（以鼻内窥镜检查为准）

治愈：症状消失，内窥镜检查窦口开放良好，窦腔粘膜上皮化，无脓性分泌物；

好转：症状明显改善，内窥镜检查见窦腔粘膜部分区域水肿、肥厚或肉芽组织形成，有少量脓性分泌物；

无效：症状无改善，内窥镜检查见术腔粘连，窦口狭窄或闭锁，息肉形成，有脓性分泌物。

随访

近期随访不少于 6 个月，远期随访一年以上。

（收稿：1998-03-30）

（本文编辑：姬广茜）

附：变应性鼻炎诊断标准及疗效评定标准（1997 年修订，海口）

中华医学会耳鼻咽喉科学分会

中华耳鼻咽喉科杂志编辑委员会

诊断标准

一、常年性变应性鼻炎

1．记分条件：①常年性发病，具有打喷嚏（每次连续 3 个以上）、流清涕和鼻粘膜肿胀三个主要临床表现，一年内发病日数累计超过 6 个月，一日内发病时间累计超过 0．5 小时；②病程至少一年。

2．记分标准：有明确吸入物致敏原线索，有个人和 / 或家族过敏性疾病史，发作期有典型的症状和体征，各记 1 分，共 3 分。变应原皮肤试验阳性反应，至少有一种为（＋＋）或（＋＋）以上；特异性 IgE 抗体检测阳性或变应原鼻激发试验阳性，且与皮肤试验及病史符合，各得 2 分，共 4 分。鼻分泌物涂片检查嗜酸粒细胞阳性和 / 或鼻粘膜刮片肥大细胞（嗜碱粒细胞）阳性得 1 分。

得分 6～8 分诊断为常年性变应性鼻炎，3～5 分为可疑变应性鼻炎，0～2 分可能为非变应性鼻炎。

二、花粉症

1．季节性发病，每年发病季节基本一致，且与致敏花粉传粉期相符合；至少两年在同一季节发病。

2．发作期有典型的临床症状和体征。

3．发作期鼻分泌物（和 / 或结膜刮片）嗜酸粒细胞阳性，或鼻粘膜刮片肥大细胞（嗜碱粒细胞）阳性。

4．花粉变应原皮肤试验呈阳性反应，至少一种为（＋＋）或（＋＋）以上，或变应原鼻激发试验阳性、眼结膜试验阳性。

疗效评定标准

1. 为了准确地、客观地评定疗效，应进行：症状分级（附表）和体征分级。

体征分级：下鼻甲与鼻底、鼻中隔紧靠，见不到中鼻甲，或中鼻甲粘膜息肉样变、息肉形成，记录为 3 分；下鼻甲与鼻中隔（或鼻底）紧靠，下鼻甲与鼻底（或鼻中隔）之间尚有小缝隙，记录为 2 分；下鼻甲轻度肿胀，鼻中隔、中鼻甲尚可见，记录为 1 分。

2．临床研究和总结资料时应设对照组。

3．根据治疗前后症状和体征记分的总合，改善的百分率按下列公式评定常年性变应性鼻炎的疗效：

附表 症状分级记分标准

分级记分	喷嚏（一次连续个数）	流涕 鼻堵 鼻痒	鼻堵	鼻痒
1 分	3～9	≤4	偶有	间断
2 分	10～14	5～9	介于两者之间	蚁行感，但可忍受
3 分	≥15	≥10	几乎全天用口呼吸	蚁行感，难忍

$$\frac{\text{治疗前总分治疗后总分}}{\text{治疗前总分}} \times 100\%$$

≥51%为显效，50％～21％为有效，≤20%为无效。

5．前瞻性研究时花粉症治疗前后症状和体征记分应与当地、当年空气中飘散的花粉数量和种类相比较。

疗效评定分为近期（脱敏治疗除外）和远期疗效，近期疗效在治疗结束时评定，远期疗效至少在治疗结束后一年评定。

减敏治疗疗效在持续治疗两年后评定（不含快速减敏治疗）。

（收稿：1998-03-30）

（本文编辑：姬广茜）

• 病例报告 •

中后颅底巨大脑膜瘤五例

王天铎 李梅 许安廷

我科收治 5 例中、后颅底巨大脑膜瘤，根据肿瘤的发生部位及侵犯范围，分别采用了 4 种入路手术。

例 1 男，37 岁。1960 年 10 月 17 日因左侧颈上部包块 25 年入院。诉声嘶，吞咽阻挡，时有误吸、头痛、头晕等。左耳前、下、后和下颌膨隆及颈侧部包块约 10cm ×10cm ×5cm 大小，质硬与皮肤无粘连。左耳道下壁被压迫上移，左侧软腭隆起，扁桃被推向前下内。咽侧壁自鼻咽至下咽均向内膨隆，左杓状软骨、会厌被推移位，左声带活动受限。11 月 2 日经颈腮入路手术，因颈动、静脉及迷走神经均为瘤体包绕，出血甚猛，难以自瘤内分出而予以与肿瘤一块切除。切开肿瘤见颈内动脉甚细且迂曲，颈内静脉腔闭。病理诊断为脑膜瘤，术后痊愈出院。36 年后复诊，CT 见中颅底脑膜瘤有局限性复发灶，但无任何症状，年已 73 岁，未再予手术治疗。

例 2 女，13 岁。1974 年 2 月 9 日因右颈上部包块 3 年余入院。查体右下颌深处及下颌角后下包块约 6cm ×5cm ×4cm 大小，质硬与皮肤粘连，较固定。鼻咽、口咽及喉咽侧壁均向咽腔内膨隆。2 月 13 日经颈腮入路手术，见颈内动、静脉及迷走神经均包于瘤体内，难以分出，根据家属意见停止手术。术时取活检病理诊断为脑膜瘤。于 3 月 6 日再次手术，分离肿瘤因刺激颈动脉球，曾一度血压下降呼吸停止，经抢救后完整切除肿瘤。伤口愈合良好，遗有声嘶。术后 10 年无复发，以后失访。

例 3 男，28 岁。1974 年 6 月 9 日因右耳鸣及耳聋 1 年半，头痛 4 个月，右面瘫 4 天以颞部肿瘤收入院。见右鼓室下部肿物。于 7 月 3 日手术行颞额切口，咬除颞骨鳞部切开硬脑膜见肿瘤向外膨出，沿肿瘤基部边缘电灼切割至半月神经节后，逐步将肿瘤切除。瘤体约 5cm ×6 cm ×6 cm 大小。因身体较差鼓室内病变未处理。8 个月后，因右耳流水 2 个月再入院，鼓室内肿物已突至外耳道口。1975 年 3 月 24 日行乳突凿开术，见肿瘤充满外耳道、鼓室及咽鼓管，颈内动脉周围均为肿瘤，且出血多，动脉周围肿瘤未能完全切除。术后病理诊断为恶性脑膜瘤。2 年后死于肿瘤复发。

例 4 男，38 岁。因左面颊部肿物 5 年及左眼球突出、鼻塞 8 个月于 1995 年 7 月 17 日入院。左眼球突出向前上，左面颊部隆起，可扪及肿物，质软。左鼻腔后端及鼻咽有暗红色肿物。MRI 和 CT 片见肿物累及左鼻腔、鼻窦、鼻咽、翼腭裂、眶尖、颞下窝，颅中凹及海绵窦。8 月 3 日与神经外科共同施术。颅外肿瘤切除：上颌骨截除皮肤切口切开皮肤及皮下组织，制作包括上颌窦内壁、顶及前壁以咬肌为蒂的骨瓣，翻向下外，见上颌窦腔明显缩小，上颌窦后壁菲薄，窦内粘膜完整。肿瘤位于翼腭窝、颞下窝，眶的下半、眶尖、颊部，并累及筛窦、鼻咽侧壁，呈分叶状，切除时出血较多。颅内肿瘤切除：自耳屏前 1cm 向上入发际弯向前额中点做颞额皮肤切口，帽状腱膜下翻起皮瓣向前下，自后向前下翻起颞肌，咬除颧弓，将颞肌转向下外方。咬除蝶骨大翼外侧份，以蝶骨嵴为中心剪开硬脑膜，见脑组织张力较高，电灼切除左侧颞极，肿瘤呈多结节状，表面布满迂曲血管，占据中颅凹。电灼切开肿瘤上壁，囊内切除部分肿瘤，然后切除囊壁至海绵窦外侧壁。侵及海绵窦及鞍部肿瘤未予切除。病理诊断为脑膜瘤。一年后复诊见颅内肿瘤有所扩展，未予治疗。

例 5 男，35 岁。1996 年 1 月 10 日因脑膜瘤复发入院。15 年前作过桥小脑角脑膜瘤切除，4 年前行 γ 刀治疗。查体：右侧Ⅶ～Ⅻ颅神经麻痹，右下颌角触及包块。CT 扫描见后颅窝、岩骨、中耳乳突部肿物向前扩展侵占中颅底。11 月 21 日行耳后大“C”型切口，翻起皮瓣向前，先切除中耳乳突、岩骨及部分后颅凹肿瘤，将下颌骨踝状突自关节盂内脱位，分开蝶骨及茎突下颌韧带，推下颌向前下，显露咽旁及颞下窝肿物，予以全切除，以颞肌瓣填塞中耳乳突及岩骨部缺损。伤口一期愈合。现患者情况良好。

（收稿：1997-07-10 修回：1997-10-20）

（本文编辑：包务业）

作者单位：250012 济南山东医科大学第一附属医院耳鼻咽喉科

Exhibit B

Chin J. Otorhinolaryngol, June 1998, Vol 33, No. 3

Attachment: Clinical Typing and Staging of Chronic Sinusitis and Nasal Polyps and Evaluation Criteria for Curative Effect of Endoscopic Sinus Surgery (Haikou, 1997)

Otorhinolaryngology Branch of Chinese Medical Association
Editorial Board of Chinese Journal of Otorhinolaryngology

Staging basis for chronic sinusitis

Medical history, endoscopy, and CT scan.

Typing and staging of chronic sinusitis and nasal polyps (based on lateral view, with separate evaluation of the anterior and posterior ethmoid sinuses)

Type 1 simple chronic sinusitis (conservative treatment failed)

Stage 1: solitary sinusitis;
Stage 2: multiple sinusitis;
Stage 3: pansinusitis.

Type 2 chronic sinusitis with nasal polyps (CRSwNP)

Stage 1: solitary sinusitis with solitary nasal polyp;
Stage 2: multiple sinusitis with multiple nasal polyp;
Stage 3: pansinusitis with multiple nasal polyp;

Type 3 multiple sinusitis or pansinusitis with multiple, recurrent nasal polyps and/or ethmoid bone hyperplasia.

Efficacy evaluation criteria (subject to nasal endoscopy)

Resolved: Symptoms disappear completely; the aperture to the mastoid antrum is adequately open; epithelization of the sinus cavity mucosa is present; and no purulent secretion is present;

Improved: Symptoms are obviously improved; endoscopic examination shows that part of the sinus cavity mucosa has edema, tissue thickening, or granulation tissue, with a small amount of purulent secretion;

Not resolved: Symptoms are not improved; endoscopic examination shows cavity adhesion, sinus stenosis or atresia, polyp, and purulent secretion.

Follow-up

The short-term follow-up should be not less than 6 months, and the long-term follow-up should be more than one year.

(Received: Mar-30-1998)

(Editor: Ji Guangxi)

Attachment: Diagnostic Criteria and Efficacy Evaluation Criteria of Allergic Rhinitis (revised in 1997, Haikou)

Otorhinolaryngology Branch of Chinese Medical Association
Editorial Board of Chinese Journal of Otorhinolaryngology

Diagnostic Criteria

I. Perennial allergic rhinitis

1. Scoring conditions: ① perennial onset, with three primary clinical manifestations: sneezing (more than 3 consecutive times), runny nose, and nasal mucosa swelling; the cumulative number of onset days in one year exceeds 6 months, and the cumulative onset time in one day exceeds 0.5 hours; ② the course of disease lasts at least one year.

2. Scoring criteria: clear sign of inhaled allergens, personal and/or family history of allergic diseases, and typical signs and symptoms during onset, each rated with 1 point, amounting to 3 points. Positive allergy skin test, with at least one indicator reaching (+ +) or more; positive specific IgE antibody test or positive nasal allergen challenge (NAC) test, and consistent with skin test and medical history; each rated with 2 points, amounting to 4 points. Positive eosinophils on the nasal secretion smear and/or mast cells (basophils) on nasal mucosa smear, rated with 1 point.

A condition rated as 6-8 points will be diagnosed as perennial allergic rhinitis, a condition rated as 3-5 points will be suspected of allergic rhinitis, and a condition rated as 0-2 points may be diagnosed as non-allergic rhinitis.

II. Pollinosis

1. It is a seasonal disease, occurring basically at the same season every year, and it is consistent with the pollinating period of allergenic pollens; it will occur in the same season for at least two years.

2. There are typical clinical signs and symptoms during onset.

3. The nasal secretion (and/or conjunctival scrape) during onset is tested positive for eosinophils, or the nasal mucosa smear is tested positive for mast cells (basophils).

4. The skin test of pollen allergen is positive, with at least one indicator reaching (+ +) or more, or the nasal allergen challenge (NAC) is positive and the conjunctival test is positive.

Efficacy Evaluation Criteria

1. In order to accurately and objectively evaluate the efficacy, signs and symptoms (attached table) should be graded.

Sign grading: if the inferior turbinate is tightly pressed against the nasal base and septum, with the middle turbinate not visible, or the polypoid changes and polyp formation of the middle turbinate mucosa are observed, it is rated as 3 points; if the inferior turbinate is tightly pressed against the nasal septum (or nasal base), with a small gap between the inferior turbinate and nasal base (or nasal septum), it is rated as 2 points; if the inferior turbinate is mildly swollen, with nasal septum and middle turbinate visible, it is rated as 1 point.

2. A control group should be established when conducting clinical studies and summarizing data.

3. Based on the total scores of symptoms and signs before and after treatment, the percentage of improvement is calculated according to the following formula to assess the efficacy of perennial allergic rhinitis:

Attached Table Scoring Criteria for Symptom Grading

Score for grade	Sneezing (number of consecutive sneezes)	Runny nose (frequency of nose-blowing)	Nasal congestion	Nasal itching
1 point	3-9	≤4	Occasional	Intermittent
2 points	10-14	5-9	In-between	Formication, but tolerable
3 points	≥15	≥10	Breathing with mouth almost all day	Formication, intolerable

$$\frac{\text{Total score before treatment} - \text{Total score after treatment}}{\text{Total score before treatment}} \times 100\%$$

≥ 51% is deemed as significantly effective, 50%-21% is deemed as effective, and ≤ 20% is deemed as ineffective.

5. In the prospective study, the symptoms and signs scores before and after pollinosis treatment should be compared with the quantity and species of pollens floating in the air in the local area that year.

Efficacy assessment is divided into short-term (except desensitization treatment) and long-term efficacy. The short-term efficacy will be assessed at the end of treatment, and the long-term efficacy will be assessed at least one year after the end of treatment.

The efficacy of desensitization therapy will be assessed after two years of continuous treatment (excluding rapid desensitization therapy).

(Received: Mar-30-1998)

(Editor: Ji Guangxi)

- Case Report -

Five Cases of Giant Meningioma of Middle and Posterior Skull Base

Wang Tianduo, Li Mei, Xu Anting

Five patients with giant meningioma of the middle and posterior skull base were admitted in our department. Based on the location and invasion extent of the tumor, four different surgical approaches were used.

Patient 1, male, 37 years old. On Oct-17-1960, he was admitted to our hospital for 25 years of left upper neck mass. He complained of hoarseness, dysphagia, occasional aspiration, headache, dizziness, etc. He was observed with the anterior, inferior, posterior, and mandibular bulge of the left ear, a firm mass on the lateral part of the neck with a size of about 10 cm × 10 cm × 5 cm without adhesion to the skin. The inferior wall of the left ear canal was compressed and displaced upward, the left soft palate was bulged, and the tonsil was pushed anteroinferiorly and medially. The lateral pharyngeal wall bulged inward from the nasopharynx to the hypopharynx, the left arytenoid cartilage and epiglottis were displaced, and the left vocal cord mobility was restricted. On Nov-2-1960, the surgery was performed via the transcervical-transparotid approach. Since the carotid arteries and veins and vagus nerves were enveloped by the tumor, with severe bleeding, making it difficult to separate the tumor from these tissues, the surrounding tissues were excised along with the tumor. When the tumor was incised, it was observed that the internal carotid artery was very thin and tortuous, and the internal jugular vein cavity was closed. The pathological diagnosis was meningioma. The patient recovered and was discharged after surgery. After 36 years, at a follow-up visit, CT scan showed the patient relapsed the localized meningioma at the middle cranial base, with no symptoms. He was 73 years old and not treated by further surgery.

Patient 2, female, 13 years old. On Feb-9-1974, she was admitted to our hospital for more than 3 years of a mass in the upper part of her right neck. Physical examination: a firm and stabilized mass with a size of about 6 cm × 5 cm × 4 cm was observed deep in the right mandible and posterior mandibular angle, with adherence to the skin. The lateral walls of nasopharynx, oropharynx, and laryngopharynx were swollen and bulged inward into the pharyngeal cavity. On Feb-13-1974, she underwent a surgery via the transcervical-transparotid approach. It was found that the internal carotid arteries and veins and vagus nerves were encapsulated in the tumor, which was difficult to isolate. The surgery was stopped due to the opinions of her family members. Biopsy was taken during the surgery, and the pathological diagnosis was meningioma. On Mar-6-1974, she underwent a second surgery. When isolating the tumor, the stimulation of glomus caroticum led to the temporary drop in blood pressure and respiratory arrest. After rescue therapy, the tumor was completely excised. The wound healed well, with a sequela of hoarseness. She had no recurrence for 10 years after surgery and was lost to follow-up later.

Patient 3, male, 28 years old. On Jun-9-1974, he was admitted to our hospital for temporal tumor with one and a half years of tinnitus and deafness of right ear, 4 months of headache, and 4 days of right facial paralysis. A mass in the lower part of the right tympanic cavity was observed. On Jul-3-1974, the temporofrontal incision was performed. When removing the squamous part of the temporal bone with a rongeur and cutting open the cerebral dura mater, it was found that the tumor bulged outward. After electrocautery was performed along the base of the tumor to the semilunar ganglion, the tumor was resected step by step. The tumor size was about 5 cm × 6 cm × 6 cm. Due to his poor condition, tympanic lesions were not treated. Eight months later, he was re-admitted to our hospital due to water running from the right ear for 2 months, and the mass in the tympanic cavity had protruded to the opening of the external auditory canal. On Mar-24-1975, a mastoidotomy was performed. It was found that the tumor filled the external auditory canal, tympanic cavity, and eustachian tube. There were tumors around the internal carotid artery with excessive bleeding. The tumor around the artery could not be completely removed. Postoperative pathological diagnosis was malignant meningioma. He died of tumor recurrence 2 years later.

Patient 4, male, 38 years old. On Jul-17-1995, he was admitted to our hospital due to a tumor on the left cheek for 5 years, protopsis of left eyeball, and nasal congestion for 8 months. The left eyeball protruded forward and upward, and a soft mass was palpable on the left cheek. A dark red mass was observed at the posterior end of the left nasal cavity and nasopharynx. MRI and CT films showed that the mass involved the left nasal cavity, nasal sinuses, nasopharynx, pterygomaxillary fissure, orbital apex, infratemporal fossa, middle cranial fossa, and cavernous sinus. On Aug-3-1995, he underwent a surgery with the help of the Department of Neurosurgery. Extracranial tumor resection: the skin and subcutaneous tissue were incised by the skin incision over the maxillary bone, and a bone flap was created from the inner, superior, and anterior walls of the maxillary sinus, with the masseter muscle as the pedicle. It is rotated outward and downward. The maxillary sinus cavity was obviously reduced in size, the posterior wall of the maxillary sinus was thin, and the intrasinus mucosa was intact. The tumor was lobulated and located in the pterygopalatine fossa, infratemporal fossa, lower half of the orbit, orbital apex, and buccal, and involved the ethmoid sinus and the lateral wall of nasopharynx. When it was resected, there was a lot of blood loss. Intracranial tumor resection: a temporofrontal skin incision was made 1 cm in front of the tragus, extended upward into the hairline, and curved to the midpoint of the forehead, the subgaleal skin flap was turned forward and downward, the temporal muscle was turned from forward and downward, the zygomatic arch was removed with a rongeur, and the temporal muscle was turned downward and outward. The lateral part of the greater wing of the sphenoid bone was removed with a rongeur, and the dura mater was cut with the sphenoid ridge as the center. It was seen that the tension of brain tissue was high, the left temporal pole was resected by electrocautery, the tumor was multi-nodular, with the surface covered by tortuous blood vessels, and it occupied the middle cranial fovea. The upper wall of the tumor was incised by electrocautery, part of the tumor was excised within the cyst, and then the cyst wall was excised to the lateral wall of the cavernous sinus. The tumor invading the cavernous sinus and the sellar region was not resected. The pathological diagnosis was meningioma. One year later, the follow-up visit showed that the intracranial tumor had expanded but was not treated.

Patient 5, male, 35 years old. On Jan-10-1996, he was admitted to our hospital due to recurrence of meningioma. He received meningioma resection of the cerebellopontine angle 15 years ago and the gamma knife treatment 4 years ago. Physical examination: paralysis of the right cranial nerve VII-XII, and a mass palpable at the right mandibular angle. CT scan showed that the tumor at the posterior cranial fossa, petrous bone, and mastoid mass of middle ear expanded forward and encroached on the middle skull base. On Nov-21-1996, a large C-shaped incision was made behind the ear, and the flap was turned forward. First, the tumor at the mastoid, petrous bone, and partial posterior cranial fossa of the middle ear were removed. The condyloid process of the mandible was dislocated from the glenoid cavity, and the mandibular ligament of the sphenoid and styloid processes was separated. The mandible was pushed forward and downward to expose the mass at the parapharyngeal and infratemporal fossa and completely remove the mass. The defects in the mastoid and petrous bone of the middle ear were filled with the temporal muscle flap. The wound had primary healing. The patient is in good condition now.

(Received: Jul-10-1997; Revised: Oct-20-1997)

(Editor: Bao Wuye)

petrous bone and partial posterior cranial fossa of the middle ear were removed. The condyloid process of the mandible was dislocated from the glenoid cavity, and the mandibular ligament of the sphenoid and styloid processes was separated. The mandible was pushed forward and downward to expose the mass at the parapharyngeal and infratemporal fossa and completely remove the mass. The defects in the mastoid and petrous bone of the middle ear were filled with the temporal muscle flap. The wound had primary healing. The patient is in good condition now.

(Received: 10-Jul-1997; Revised: 20-Oct-1997)

(Editor: Bao Wuye)

Author's affiliation: E.N.T Department, The First Affiliated Hospital of Shandong First Medical