Techniques in Regional Anesthesia and Pain Management (2010) 14, 3-9

Techniques in
Regional Anesthesia
& Pain Management

# Radiofrequency and cryoablation for cancer pain

**Dhanalakshmi Koyyalagunta, MD, and Danesh Mazloomdoost, MD**

*From the Department of Pain Medicine, University of Texas M.D. Anderson Cancer Center, Houston, Texas.*

**KEYWORDS:**
Cancer pain;
Radiofrequency ablation;
Cryoablation

Prevalence of pain in patients with cancer is high and is a feared and burdensome symptom. There has been a paradigm shift away from the World Health Organization ladder with adoption of interventional treatments early on in the treatment of cancer pain. Intentional destruction of nerves (neurolysis) with chemical (alcohol or phenol), heat (radiofrequency), or cold (cryo) are treatment modalities used to treat cancer pain. These management modalities have become both mainstays of cancer pain therapy and adjuvants to medical management. Chemical neurolysis with phenol or alcohol are commonly used for sympathetic neurolysis. Radiofrequency ablation (conventional and pulsed) and cryoablation are widely used in the treatment of nonmalignant pain. The published data on the use of theses modalities in the cancer population consist mainly of case reports. At the University of Texas MD Anderson Cancer Care Center, neuroablative techniques are frequently used to control refractory cancer pain. The evolution, histologic effect of radiofrequency and cryoablation, and their application are reviewed herein. Common clinical applications and specific techniques conducted at MD Anderson Cancer Care Center are used as examples of how these techniques can be applied to treat cancer related pain.
© 2010 Elsevier Inc. All rights reserved.

Pain is one of the most burdensome and feared symptoms among cancer patients. The incidence of pain in patients with advanced cancer is 58-69%, and 44-73% in those who are receiving active therapy.[1] Significant advances in cancer therapy have improved cancer survival rates and a rapidly growing population of cancer survivors.[2] Therefore, there is a wide spectrum of patients who need ongoing pain management, including those in active cancer therapy and those at the palliative end, as well as cancer survivors. The pain associated with cancer could be from any of the following sources: the disease itself; invasion of bone, soft tissues, vascular vessels, hollow organs, or nerves/nervous system structures; treatment; or it can be unrelated to the malignancy.[3] The treatment of cancer related pain varies widely from adopting the World Health Organization ladder, interventional therapies, and/or a combination of these. Neurolysis is intentional destruction of the nerves causing pain, by chemical (alcohol or phenol), heat, or cold. Using local anesthetic and/or steroid will serve as a diagnostic block, and subsequent radiofrequency or cryoablation would theoretically give a longer lasting effect. Somatic and sympathetic nerves can be neurolysed using conventional radiofrequency and cryoablation to give pain relief for 3-6 months. Pulsed radiofrequency ablation (RFA) is a promising option without the fear of neuritis or deafferentation pain, a possible complication with conventional RFA. A sizeable body of published data exists, mostly retrospective studies and case reports, on the benefit of pulsed RFA demonstrating few if any adverse affects.[4] Percutaneous computed tomography-guided RFA of upper spinal cord pathways is a modality for intractable cancer pain[5] performed by neurosurgeons. Chemical ablation is frequently used for celiac or hypogastric plexus neurolysis, but due to the risk of associated spillage to neighboring neural structures and potential neuritis, it is not a first-line therapy for neurolysis of somatic nerves.

**Address reprint requests and correspondence:** Dhanalakshmi Koyyalagunta, MD, Department of Pain Medicine, University of Texas M.D. Anderson Cancer Center, 1400 Holcombe Blvd, Houston, TX-77030.
E-mail address: dkoyyala@mdanderson.org.

1084-208X/$ -see front matter © 2010 Elsevier Inc. All rights reserved.
doi:10.1053/j.trap.2009.12.001

NEURENT 1069

## History

### Cryoablation

Freezing as preoperative analgesia was first described by Avicenna of Persia (980-1070 AD), and its use thereafter has been reproduced throughout history.[6] Napoleon's surgeon-general, for instance, noticed that soldiers tolerated limb amputation during the wintry battles in Moscow with relatively little pain.[6] The analgesic effects of cold were used up through World War II in limb surgeries.[7] The advent of more modern analgesics made cold obsolete for the operative environment; however, Cooper developed a cryo-probe in 1961[7] for surgical applications in tumor ablation. It was not until 1974 when Nelson described a technique using cold as an analgesic for post-thoracotomy pain that anesthesiology began redeveloping the science of freezing for use in pain management. By 1976, Lloyd and colleagues first demonstrated its use in chronic pain management by using it to treat facial and back pain.[8] Although Cooper's probe used liquid nitrogen to cool tissue as low as −190°C; current technique relies upon the expansion of compressed gasses, such as carbon dioxide or nitrous oxide into the contained bulb of a cryoprobe.[9] In going from 600-800 psi to near atmospheric pressures (10-15 psi) through a fine orifice, the probe cools to −50° to −70°C causing disruption of neuronal axons. Because the probe must contain a lumen for circulating gases as well as a nerve stimulator and a thermistor for nerve localization and temperature monitoring, they tend to be larger than radiofrequency probes or chemical neurolysis needles. They range 1.4-2.0 mm forming a sphere of ice 3.5-5.5 mm in diameter from the probe, respectively.

The analgesic effect results from ice crystal formation both intra- and extracellularly,[10] causing microvascular changes and compromise of axonal wall integrity. Moorjani et al[8] demonstrated that the damage causes Wallerian degeneration while preserving the endoneurium and perineurium, since the Schwann cell basal lamina is spared during cryoablation. As the axon regenerates, it relies upon the macroarchitecture to complete native neural circuitry, so the development of neuromas is minimized.[6] The histologic explanation reinforces the repeated scientific observations of cryotherapy as an effective modality for acute postoperative pain, wherein neurocircuitry returns to normal after 5-6 months.[11]

### Conventional radiofrequency ablation

RFA evolved from the observation that electrolytic lesions can be elicited by using direct current applied to tissue. Beginning in the late 19th century, Beaunis and Forunie applied electrodes to animal brains and described the lytic effects when a current is induced through the tissue.[12] However, it was quickly discovered that the lesions were of unpredictable and variable sizes because the imposed current took the path of least electrical resistance. As a result, the area of ablation was dependent upon the anatomy and vasculature of the surrounding tissue. In the 1950s, it became clear that by rapidly changing the current's direction with alternations in electrical polarity, the resultant lesion could be controlled and made predictable.[12] Initially, this alternating current was fluxed as frequently as a million times per second (1 MHz), frequencies used commonly in radio waves, hence the name RFA.

Alternating currents generate oscillatory movement of charged organic molecules, namely proteins, and result in heat created by the friction of colliding proteins. The heat generated was sufficient to denature proteins and create a field of ablation. The protein oscillation dissipates rapidly with the voltage drop in going from the fine tip of a radiofrequency probe to the large surface area of a grounding pad, according to the following equation:[13]

$$\text{Thermal energy} \propto \frac{\text{Current}^2}{\text{Distance}^4} \times \log\ (\text{Constant} \times \text{Time})$$

Modern RFA probes use frequencies of 100-500 kHz. By changing the size and shape of a RF probe or the time during which a current is applied, the clinician can manipulate the lesion size. Most probes are elongated, so the field of ablation is ovoid. The width of the lesion generated at 80°C for 90 seconds results in a maximum area 1-1.5 times the width of the electrode.[13]

### Pulsed radiofrequency ablation

One of the earliest applications of RFA was in the percutaneous ablation of a gasserian ganglion in 1942.[14] This ganglion analogous to dorsal root ganglion (DRG) at the spinal cord only relays sensory fibers, so it did not pose risks of ablating motor or proprioception nerves. To make RFA applicable to other pain syndromes, preferential blockade affecting pain fibers and sparing sensory and motor fibers was necessary because many nociceptive nerves overlap with desired nerves, relaying motor and sensory signals. However, conventional RFA did not accomplish this, since its ablation field was the result of indiscriminate temperature rise around the probe. Protein coagulation begins with temperatures above 50°C,[15] and conventional RFA generates temperatures of 80-90°C.

In 1964, it was postulated that by intermittently pausing the current, a differential blockade could be produced.[16] By pulsing the RFA current, temperature rise in the tissue surrounding the probe can be reduced from 80°C-90°C to around 40°C, just less than the temperature of protein coagulation. Using lower electrode tip temperatures, the targeted neural structure is exposed to a train of short-duration, high-frequency (500 kHz) but low voltage (50 V) RF pulses, in contrast to the continuous thermocoagulative current used in conventional RF. Thus, pulsed radiofrequency imposes less tissue damage on the cellular level.

Until recently, however, it was not clear how pulsed radiofrequency reduced nociceptive signaling. One explanation came about from electron microscopy at the level of organelles. The electric field generated within the cells depends on the impedance of the cell itself, so unmyelinated and smaller-diameter neurons are prone to greater electric fields intracellularly than myelinated or large-diameter nerve fibers[17]; therefore, they incur more damage for a given voltage and current. C-fibers (unmyelinated and small-diameter) and A-delta (small-diameter) nerves, which carry nociceptive signaling, are therefore most susceptible to organelle damage than are motor and other sensory neurons because of their lower impedance. By applying pulsed radiofrequency rather than conventional RFA, the damage incurred is not due to universal temperature rise in a sphere surrounding the probe, but rather due to microscopic temperature rise intracellularly. So, the macroarchitecture is preserved and the damage is primarily at the level of mitochondria, microfilaments, and microtubules.[17] This decreases the likelihood of more painful complications, such as deafferentation injury and neuritis.

Another explanation for the effect of pulsed RFA is at the neurobiological level; it is known to induce c-Fos expression in the dorsal horn, whereby continuous RFA does not. It is this expression of the c-Fos gene that leads to the formation of the second RNA messenger preproendorphin, which in turn increases the production of endorphins to modulate an analgesic response. The change in the dorsal horn may be related to the current fluctuation with the pulsed RF signal, which is much greater in amplitude than the continuous RF signal. Pulsed radiofrequency seems to have neuromodulatory effects in the pain pathway.

## Technique

Before ablating a nerve by any modality, a diagnostic nerve block is necessary to determine the projected effect of imposing prolonged injury at the nerve site. After a successful diagnostic block, the ablative procedure can be scheduled on a subsequent appointment. Imaging modalities, such as fluoroscopy, ultrasound, computed tomography-guidance and availability of necessary equipment, particularly the compatible dimensions of probe and introducer, should be confirmed before commencing the case. While the patient may be sedated at the initiation of the procedure, they must be arousable before ablation to confirm safe probe placement. After sterile preparation and draping, subcutaneous local anesthetic is infiltrated, taking care to avoid the nerve to be ablated because stimulation is also necessary to confirm proper probe placement. After the preparations are completed, a cryoprobe introducer or RFA needle is advanced to the respective nerve under appropriate visualization or by anatomic landmark. Cryoablative probes typically require a 14 gauge angiocatheter introducer since they are blunt and large to accommodate a lumen for circulating gases. RFA needles are smaller than cryoprobes as they do not need a lumen for gas flow—typically around 22 gauge or higher. Both RFA and cryoprobes have thermistors to provide temperature feedback for safety and quality control and nerve stimulators to confirm proper probe placement. Sensory nerve stimulation occurs at around 50-100 Hz, beginning with the lowest voltage that produces vibratory sensation. The goal is to overlap the stimulation with the area of pain. To identify ideal probe placement, voltage can be raised to as high as 2 V with sequential decrements as the probe position is refined. Voltages higher than 0.5 V suggest insufficient proximity to the nerve for encapsulation within the ablative sphere and lower voltages may indicate intraneural probe placement that could result in macroarchitectural damage and resultant complications. Motor stimulation of 2 Hz at highest voltage tolerable is used to rule out motor nerve inclusion in the ablation area.

### Cryoablative procedure

On proper probe placement, the cryoprobe is activated by starting gas flow at $9 \pm 1$ or $10 \pm 2$ L/m for probe sizes of 1.4 and 2.0 mm, respectively. With the first cycle of freezing, patients typically feel a burning sensation in the distribution of the nerve intended to be addressed. Subsequent iterations are needed to completely ablate the nerve; however, these are not painful since freezing numbs the nerve distribution. Repeating 2 to 3 iterations of 3-minute freezes with 30 second defrosting periods between each cycle is the convention. After the final iteration, the probe is gently removed after a complete thaw, taking care to avoid tension on the cryosphere so as not to shear the frozen nerves. Bupivacaine infiltration after the ablation provides postoperative pain control for several hours. The published data on cryoablation are biased toward acute pain therapies, specifically comparing cryoablation of intercostal nerves to epidural or opiate postoperative pain control. Although many studies acknowledge its efficacy in treating post-thoracotomy pain,[11] the evidence is controversial on whether it is superior to other modalities, such as epidural[18,19] or intravenous morphine.[20] The studies, however, vary in timing of cryoablative application (pre-vs intra-vs postoperative) and there is a dearth of studies taking into consideration the impact of pre-emptive analgesia. Furthermore, it has not demonstrated wide efficacy across a spectrum of diseases.[21] In postherpetic neuralgia, for instance it remains shown to be effective.[22]

### Radiofrequency ablation

Conventional and pulsed RFA is initiated after confirming proper placement of the probe with motor and sensory stimulation. RFA can be painful, so after sensory and motor stimulation is done, the patient may be sedated or local anesthetic infiltrated through the introducer. Steroids may also be injected to reduce postoperative inflammation and

pain. The lesion is initiated by applying current to the probe through a RF generator. Generators have evolved into complex medical devices capable of simultaneously monitoring the temperature rise and adjusting the current, voltage, or pulse width to maintain the desired ablative temperature. The anatomy surrounding the probe influences the temperature generated. Vasculature, bone, and CSF can all act as heat-sinks and dissipate heat away from the lesion. Nonetheless, equilibrium is generally achieved within a few seconds and is maintained between 90 and 120 seconds; maximum lesion diameter is generally attained by 90 seconds of initiating the RF. The probe and introducer can then be removed, and the area dressed.

## Pain procedures utilizing radiofrequency and cryoablation

### Head and neck

The pain resulting from head and neck malignancy can be the result of multiple sources—direct stimulation or pressure on the nerve endings, infection and ulceration, and bone invasion.[3] Tumor can involve the brain, meninges, nerves, or skull and cause headache or facial pain.[3] Headaches can also be the result of metastatic disease to the posterior fossa and leptomeningeal disease. Inflammation, pressure or traction of individual nerves, such as the glossopharyngeal, trigeminal, or upper cervical nerves can also cause headaches. Tumors in the tonsillar fossa and the pharynx can lead to glossopharyngeal neuralgia. Pain can also be due to radiation induced nerve damage or neuritis. An initial block with local anesthetic serves as a diagnostic tool before radiofrequency or cryoablation.

### Trigeminal nerve and branches

Trigeminal neuralgia or "tic douloureux" is associated with lancinating pain in the distribution of the nerve or one of its branches. It can be debilitating and refractory to medical management. Percutaneous RFA of the gasserion ganglion was performed in 1931 by Kirschner; it has been considered a safe and relatively simple technique for the treatment of trigeminal neuralgia.[23] Careful review of scans should be done before the block in the cancer population, to avoid driving a needle through the tumor and evoking associated complications. The Gasserion ganglion is blocked by needle placement 3 cm lateral to the lateral margin of the mouth in the plane of the ipsilateral pupil at the level of the mandibular condyle. The needle is advanced until bone is contacted and then redirected posteriorly into the foramen ovale (Figure 1). Conventional RFA has demonstrated pain reduction in a majority of patients[23,24] with few long-term side effects. Complications associated with conventional RFA include masseter weakness and paralysis (4.1%), decreased corneal reflex (5.7%), and $\leq$ 1% of sensory changes in the distribution of the trigeminal nerve.[23] Pulsed RFA, theoretically should not cause the masseter weakness or sensory changes.

The V2 and V3 branches of the trigeminal nerve can be blocked peripherally at the coronoid notch. The needle is inserted below the zygomatic arch in the center of the coronoid notch and advanced in a perpendicular plane until the lateral pterygoid plate is encountered. For blockade of the maxillary nerve, the needle is withdrawn and redirected anteriorly and superiorly to slip of the pterygoid plate. The needle is directed inferiorly and posteriorly for selective blockade of the mandibular nerve. Paresthesias can be elicited with the radiofrequency probe to confirm needle position before neurolysis.

Supraorbital and infraorbital neuralgia present as pain in their respective distribution and can be due to tumor involvement of the area, radiation or surgery induced nerve injury. These nerves are the terminal branches of the first 2 divisions of the trigeminal nerve and can be blocked using cryoablation or RFA. The supraorbital nerve can be blocked at the supraorbital notch with a 1.4 mm cryoablation probe

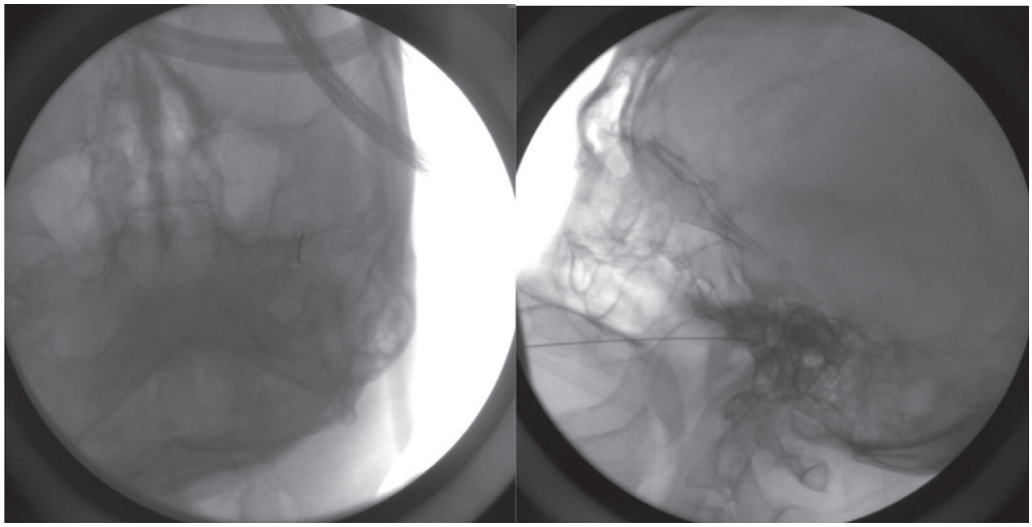

**Figure 1** Anteroposterior (AP) and lateral view of needle position for gasserion ganglion block.

for two, 2 minute cycles.[6] Open operative technique with exposure of the nerve after dissection and then cryoablation has been described. Cryoablation of the infraorbital nerve can be performed at the infraorbital foramen using a percutaneous approach or open surgical technique. Care with conventional RFA is necessary to avoid thermal damage to the skin or hair (eye brow) in this sensitive area.

The **glossopharyngeal nerve** relays sensory fibers to the posterior third of the tongue, soft palate and the mucous membranes of the mouth and pharynx. Tumors of the tonsillar fossa, posterior tongue, and hypopharynx can involve this nerve and cause pain that can be severe as the tumor progresses and involves the lateral pharyngeal wall. The block is performed with the patient in the supine position and intravenous access in place with routine monitors. The needle is inserted midway between the angle of the mandible and the mastoid process. The styloid process should be encountered at around 3 cm, the needle is withdrawn and walked off posterior just past the styloid process. Conventional RFA can be done but with caution as the vagus and spinal accessory nerve are in proximity and could be lysed. We have performed pulsed RFA in a series of patients with promising results.

This approach may not be ideal for cryoablation with 12-gauge introducer due to close proximity of the carotid artery. Cryoablation of the glossopharyngeal nerve can be performed at the tonsillar pillar.[6] After anesthetizing the mucosa with a topical spray, the tongue is retracted and a 12-gauge introducer advanced at the inferior portion of the tonsillar pillar. A 2 mm cryoprobe is advanced through the introducer catheter; paresthesia or sensory stimulation should be felt in the ear and throat.

**Occipital neuralgia** presents as pain in the occipital area with radiation to the parietofrontal area. The greater occipital nerve arises from the dorsal primary ramus of C2 and some fibers from C3. The lesser occipital nerve arises from the ventral primary rami of the second and third cervical nerves. The greater occipital nerve can be blocked medial to the artery at the nuchal ridge and the lesser occipital blocked by redirecting the needle laterally and inferiorly. Conventional RFA can be performed with care to avoid thermal injury of the skin and hair. Pulsed RFA at 42°C is a promising option with good results in our clinical practice.

### Trunk

Lung tumors invading the chest wall, metastatic disease involving the ribs, tumor involving the intercostals nerves, postmastectomy pain, and postthoracotomy pain syndrome are some of the common causes of chest wall pain. Blocking the intercostal nerve roots or dorsal root ganglia with local anesthetic serves as a diagnostic tool to identify the dermatomes involved in the patient's pain before performing an ablative procedure. There are abundance of published data on cryoneurolysis of the intercostal nerve; intraoperatively under direct vision and percutaneously with mixed results. Cryoanalgesia or RFA of the intercostal nerves for post thoracotomy pain gives incomplete pain relief.[8] Pain signals are also transmitted by the dorsal rami and the sympathetic fibers, which are not blocked by ablating the intercostal nerve.[8]

Ablating the nerve more proximally at the DRG was first attempted by Uemetsu and is a technique used frequently at our institute. Van Kleef found it to be less effective when more than 2 segmental levels were involved.[14] Conventional RFA carries the risk of deafferentation pain and neuritis. Pulsed RFA of the DRG was found superior to pharmacotherapy or pulsed RFA of the intercostal nerves.[25] Thoracic (T) DRG block is relatively simple at the lower thoracic levels but can be difficult at levels T6 and above. The fluoroscopy beam is tilted to align the endplates of the vertebral body and to discern the transverse process from the rib (Figure 2). A 10 cm, 5-mm active tip radiofrequency needle is advanced in a cephalomedial direction under the transverse process. Needle position is confirmed by anteroposterior and lateral fluoroscopy and spread of injected dye.

Concordant sensory stimulation is obtained at ≤0.4 V and motor stimulation at ≥0.8 V. Pulsed RFA of the thoracic DRG is a common procedure performed at our institute and usually done along with the initial diagnostic block. This has given pain relief outlasting the local anesthetic in

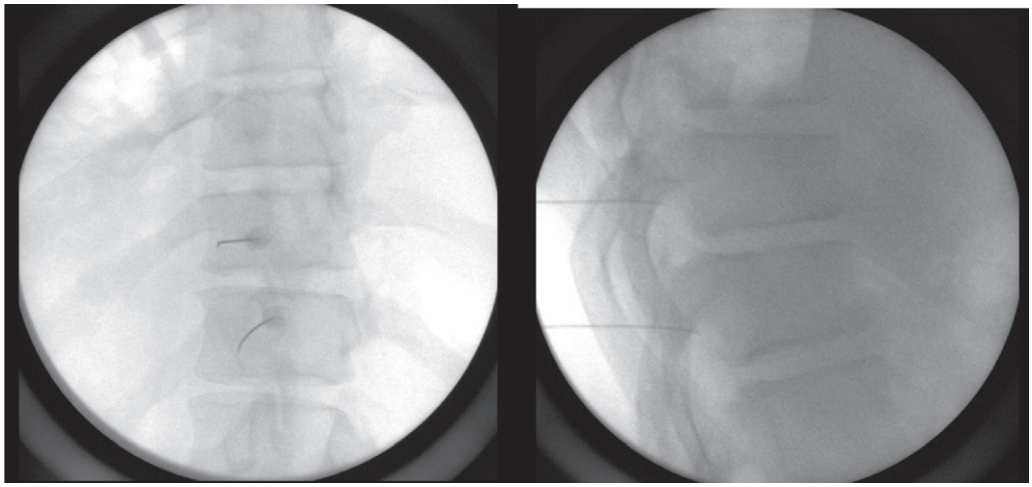

**Figure 2** AP and lateral views showing needle position for thoracic DRG block.

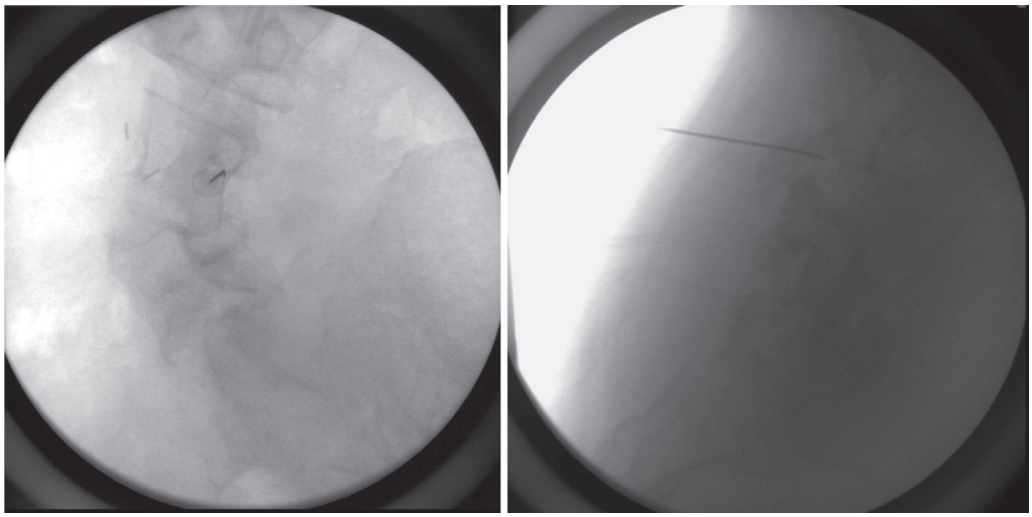

**Figure 3** AP and lateral views showing needle position for L4 DRG ablation.

a fair number of patients; clinically, although this is not reflected in the available published data. Zeldin et al[26] reported good pain relief with pulsed RFA of thoracic DRG in 2 patients with cancer pain. Conventional RFA can cause neuritis, requiring treatment with oral steroids and other neuropathic medications. Injection of nonparticulate steroid after the RFA is prudent to decrease the incidence of neuritis and prevent complications that have been reported with particulate steroids.

### Extermities

RFA of the cervical DRG has been described by Van Kleef et al.[27] The potential complication of deafferentation pain associated with cryoablation and conventional RFA has made pulsed RFA a desired option. Tumors involving the plexus, individual cervical or lumbosacral nerves, or involving the extremity itself can cause severe pain involving the limbs. If medical management does not provide optimal pain relief, neurolysis may be an option. Cryoablation or conventional RFA is not a good choice when a patient has full function involving the particular nerves. Pulsed RFA would be the initial mode of pain control if pharmacotherapy has failed. Zeldin et al[26] reported 1 case with pain relief after pulsed RFA of the lumbosacral nerves. As in the thoracic area, pulsed RFA with initial diagnostic block is an option rather than having the patient come for these procedures at 2 different times. Conventional RFA or cryoablation as an initial neurolysis can be done if a patient has loss of function of the limb or if pulsed RFA and pharmacotherapy has failed. Caution should be taken if steroids are injected after the DRG ablation since there has been evidence of spinal cord ischemia with particulate steroid use for transforaminal injections.[28]

The case in Figure 3 is a patient with metastatic sarcoma and significant kyphoscoliosis after a hemipelvectomy. The patient had 2 months of pain relief after a pulsed RFA of the DRG for recurrence of tumor involving the nerve root on the opposite side.

## Discussion

Conventional RFA is a commonly used technique to treat multiple chronic pain conditions, with published data to prove its efficacy. Pulsed RFA is a promising option with accumulating published data, mostly retrospective and case reports. Cryoablation has been extensively studied in the post-thoracotomy patient and has mostly fallen out of favor. Overall these are minimally invasive, target specific procedures that are extensively used for chronic pain conditions. There are very few published data on the use of either of these modalities in the setting of cancer pain. In this article, we have outlined some of the common cancer pain conditions that would benefit from these modalities, elaborating on the available evidence and our experience. There is a need for retrospective studies to look at effectiveness and outcomes of these modalities. Prospective randomized studies with sham treatment in this population would be difficult to justify.

## References

1. van den Beuken-van Everdingen MH, de Rijke JM, Kessels AG, et al: Prevalence of pain in patients with cancer: A systematic review of the past 40 years. Ann Oncol 18:1437-1449, 2007
2. Burton AW, Fanciullo GJ, Beasley RD, et al: Chronic pain in the cancer survivor: A new frontier. Pain Med 8:189-198, 2007
3. Mehio AK, Shah SK: Alleviating head and neck pain. Otolaryngol Clin North Am 42:143-159, x, 2009
4. Cahana A, Van Zundert J, Macrea L, et al: Pulsed radiofrequency: Current clinical and biological literature available. Pain Med 7:411-423, 2006
5. Raslan AM: Percutaneous computed tomography-guided radiofrequency ablation of upper spinal cord pain pathways for cancer-related pain. Neurosurgery 62:226-233, 2008; discussion 33-34
6. Trescot AM: Cryoanalgesia in interventional pain management. Pain Physician 6:345-360, 2003
7. Joucken K, Michel L, Schoevaerdts JC, et al: Cryoanalgesia for post-thoracotomy pain relief. Acta Anaesthesiol Belg 38:179-183, 1987
8. Moorjani N, Zhao F, Tian Y, et al: Effects of cryoanalgesia on post-thoracotomy pain and on the structure of intercostal nerves: A

human prospective randomized trial and a histological study. Eur J Cardiothorac Surg 20:502-507, 2001
9. Evans PJ, Lloyd JW, Green CJ: Cryoanalgesia: The response to alterations in freeze cycle and temperature. Br J Anaesth 53:1121-1127, 1981
10. Barnard D: The effects of extreme cold on sensory nerves. Ann R Coll Surg Engl 62:180-187, 1980
11. Conacher ID, Locke T, Hilton C: Neuralgia after cryoanalgesia for thoracotomy. Lancet 1:277, 1986
12. Kline M: Radiofrequency techniques in clinical practice, in Waldman S (ed): Interventional Pain Management, (ed 1). Philadelphia, PA, WB Saunders, 1996, pp 185-218
13. Lord SM, Bogduk N: Radiofrequency procedures in chronic pain. Best Pract Res Clin Anaesthesiol 16:597-617, 2002
14. van Kleef M, Barendse GA, Dingemans WA, et al: Effects of producing a radiofrequency lesion adjacent to the dorsal root ganglion in patients with thoracic segmental pain. Clin J Pain 11:325-332, 1995
15. Friedman M, Mikityansky I, Kam A, et al: Radiofrequency ablation of cancer. Cardiovasc Interv Radiol 27:427-434, 2004
16. Brodkey JS, Miyazaki Y, Ervin FR, et al: Reversible heat lesions with radiofrequency current. A method of stereotactic localization. J Neurosurg 21:49-53, 1964
17. Erdine S, Bilir A, Cosman ER, et al: Ultrastructural changes in axons following exposure to pulsed radiofrequency fields. Pain Pract 9:407-417, 2009
18. Gough JD, Williams AB, Vaughan RS, et al: The control of post-thoracotomy pain. A comparative evaluation of thoracic epidural fentanyl infusions and cryo-analgesia. Anaesthesia 43:780-783, 1988
19. Brichon PY, Pison C, Chaffanjon P, et al: Comparison of epidural analgesia and cryoanalgesia in thoracic surgery. Eur J Cardiothorac Surg 8:482-486, 1994
20. Orr IA, Keenan DJ, Dundee JW: Improved pain relief after thoracotomy: Use of cryoprobe and morphine infusion. BMJ (Clin Res Ed) 283:945-948, 1981
21. Bush DJ: Pre-emptive analgesia. BMJ 306:285-286, 1993
22. Jones MJ, Murrin KR: Intercostal block with cryotherapy. Ann R Coll Surg Engl 69:261-262, 1987
23. Wu CY, Meng FG, Xu SJ, et al: Selective percutaneous radiofrequency thermocoagulation in the treatment of trigeminal neuralgia: Report on 1860 cases. Chin Med J (Engl) 117:467-470, 2004
24. Shah RV, Racz GB: Long-term relief of posttraumatic headache by sphenopalatine ganglion pulsed radiofrequency lesioning: A case report. Arch Phys Med Rehabil 85:1013-1016, 2004
25. Cohen SP, Sireci A, Wu CL, et al: Pulsed radiofrequency of the dorsal root ganglia is superior to pharmacotherapy or pulsed radiofrequency of the intercostal nerves in the treatment of chronic postsurgical thoracic pain. Pain Physician 9:227-235, 2006
26. Zeldin A, Ioscovich A: Pulsed radiofrequency for metastatic pain treatment. Pain Physician 11:921-922, 2008
27. van Kleef M, Liem L, Lousberg R, et al: Radiofrequency lesion adjacent to the dorsal root ganglion for cervicobrachial pain: A prospective double blind randomized study. Neurosurgery 38:1127-1131, 1996; discussion 31-32
28. Kennedy DJ, Dreyfuss P, Aprill CN, et al: Paraplegia following image-guided transforaminal lumbar spine epidural steroid injection: Two case reports. Pain Med 10:1389-1394, 2009