Copyright © 2009

Skin Rejuvenation and Wrinkle Reduction Using a Fractional Radiofrequency System

George Hruza MD[a], Amy Forman Taub MD[b], Susannah L. Collier MD[c], Stephen Robert Mulholland MD[d]

a. Department of Dermatology and Otolaryngology, St. Louis University, St. Louis, MO
b. Advanced Dermatology, Skinfo, SKINQRI and Northwestern University Medical School, Department of Dermatology, Lincolnshire, IL
c. Laser and Dermatologic Surgery Center, Saint Louis, MO
d. SpaMedica Infinite Vitality Clinics, Toronto, ON

ABSTRACT

Introduction: Skin resurfacing has evolved rapidly over the past 15 years from ablative techniques to nonablative methods and most recently fractional ablative resurfacing. The purposes of this study were to analyze the degree of tissue ablation, coagulation, and heating; and to evaluate the clinical efficacy and safety of a fractional radiofrequency (RF) device, for the treatment of wrinkles with fractional skin ablation and coagulation.

Material and Methods: Individuals scheduled for abdominoplasty received fractional RF treatment to the abdomen area, using different tips at varying energy densities and coverage rates. Biopsies were performed *ex vivo* following abdominoplasty and tissue samples were routinely processed and stained, using hematoxylin and eosin). Another group of subjects received three facial treatments, scheduled at 3 to 4 week intervals. Clinical improvement and response to therapy were evaluated with standardized photography and clinical assessment by the subjects and investigators.

Results: Histological findings immediately posttreatment revealed demarcated zones of ablation/coagulation/necrosis and sub-necrosis up to a depth of 450 µm. Higher energy levels generated deeper effects. We noticed a tunable balance between ablation and coagulation/necrosis. These effects were coverage mode and energy density dependent. Subjects undergoing facial treatment had minimal pain, no permanent side effects or significant downtime. Investigators' assessment for improvement in skin texture correlated with subjects' evaluation and was greater than 40% for approximately 50% of subjects. Eighty percent of the subjects were satisfied with the results. Higher energy levels and lower coverage rates produced better aesthetic results along with less pain.

Conclusions: The clinical observations and histological findings suggest that fractionated ablative skin resurfacing using Matrix RF resulted in a safe, tolerable and effective improvement in skin texture and reduction of wrinkles. The depth of tissue ablation, coagulation and necrosis and the relative proportions of these phenomena were found to be controllable and could be modulated to optimize treatment of variable dermatologic conditions.

INTRODUCTION

Human skin aging is characterized by skin laxity, photodamage, appearance of visible lines and wrinkles, and an overall decline in skin texture.[1] Skin resurfacing refers to the achievement of a better organized and newer dermal matrix and epidermal normalization. Recently, the drive to attain aesthetic facial improvement with minimal adverse effects has inspired the field of nonsurgical skin resurfacing. Ablative and nonablative approaches that use lasers, intense pulse light (IPL) or radiofrequency (RF) based systems alone or in combination are the currently available solutions in aesthetic medicine.[2]

In both ablative and nonablative modalities, the goal is to create controlled thermal damage in the dermis to allow stimulation of wound healing via collagen remodeling. Laser assisted skin resurfacing achieves skin rejuvenation by precise ablation of the skin with subsequent new collagen formation and re-epithelialization. High-energy pulsed or scanned CO_2 or Er:YAG lasers as well as systems that combine both are the established choice.[3-5]; however, the prolonged recovery time and the associated complications[6] promoted the development of gentler nonablative procedures (eg, Nd:YAG or diode lasers, monopolar RF system and the combined infrared light and bipolar RF technology). Non ablative resurfacing produces thermal dermal injury to improve skin aging while protecting epidermal integrity through effective cooling. Each modality has its own clear advantages and disadvantages; with ablative systems, results are impressive since the epidermis is removed and replaced with a new epidermis and wound healing is significant, but recovery is long. With nonablative approaches, there is less social downtime (given that the epidermis is spared) but the overall net effect is modest. More recently, an intermediate approach using fractional energy delivery has been developed that seeks to overcome the limitations of both ablative and nonablative treatments.[7-9]

In fractional resurfacing, thermally ablated microscopic zones of epidermis and dermis are spaced in a grid over the skin surface; the nonablated zones in the uninjured surrounding tissue serves as a reservoir of cells that accelerate and promote safe and rapid healing. Overall, this technique increases efficacy as compared to nonablative resurfacing, and has faster recovery as compared to ablative resurfacing.

© 2009-Journal of Drugs in Dermatology. All Rights Reserved.
This document contains proprietary information, images and marks of Journal of Drugs in Dermatology (JDD).
No reproduction or use of any portion of the contents of these materials may be made without the express written consent of JDD.
If you feel you have obtained this copy illegally, please contact JDD immediately.

TABLE 1.

Morphological parameters and degree of ablation, coagulation and necrosis in relation to fractional RF treatment parameters.*

MxRF Program† (energy intensity in J)	Depth of Tissue Effect	Tissue effect
A - 2-10 J		
64 electrode pin (depth in µm) 144 electrode pin (depth in µm)	150 75	Coagulation, necrosis and sub-necrotic tissue heating; no or minimal ablation
B - 6-16 J		
64 electrode pin (depth in µm) 144 electrode pin (depth in µm)	250 150	Some ablation, coagulation, necrosis and heating.
C - 10-20J		
64 electrode pin (depth in µm) 144 electrode pin (depth in µm)	350 200	Ablation and some coagulation and necrosis, only residual heating

*The above represent average of maximal depth. For 5% coverage the depth of tissue effects may be up to 20% higher and for 10% coverage the depth of tissue effects may be up to 20% lower.
† Program specific to Matrix™ RF.

We hypothesized that the added value of delivering energy in a non-homogenous fractional form would apply to RF devices as well. Current RF technology selectively heats the dermis and is used for nonablative procedures only. The Matrix™ RF (Syneron Medical Ltd., Yokneam Illit, Israel) applicator is the first bipolar RF-based aesthetic device capable of delivering ablative tunable RF energy to the skin in a nonhomogenous fractional manner via an array of multielectrode-pins. This results in heating of areas which are directly targeted by the electrode-pins to temperatures leading to ablation and resurfacing of the skin directly in contact with and below the array, leaving intact or slightly affected zones in between the targeted areas. In the short term, the preserved tissue helps to maintain skin integrity. In the long term, it serves as a pool of cells that promote wound healing. In the current study, we morphologically analyzed the impact of the fractional RF applicator on skin tissue and evaluated its clinical performance for skin resurfacing and wrinkle reduction. Tissue and RF energy interactions as evident by histological findings and their associations with varying parameters of the fractional RF modality are also discussed.

METHODS

Device Description

The fractional RF is a hand-held applicator that is fitted with a square disposable tip at its distal end. The tip consists of parallel rows of bipolar arranged electrode-pins, forming an array of positively and negatively charged electrodes for multiple delivery of 1 MHz of RF energy. Energy up to 20 J can be delivered at a 5% or 10% coverage rate via 64 or 144 (according to the specific tip) equally spaced electrode-pins, each approximately 200 µm in diameter. Radiofrequency delivery via dry skin flows between each pair of positively and negatively charged electrode-pins such that part of the electrode-pins array forms a closed circuit of bipolar RF current that passes into the epidermis and deeper into the dermis.

Subjects

This was a prospective multicenter study involving 2 sites for the clinical portion and a third site for the histological portion. The 2 clinical sites (St. Louis, Mo; Lincolnshire, Ill) conducted clinical evaluation of the fractional RF for improvement in facial skin texture and wrinkles following a 3 treatment course with fractional RF. Subjects were eligible for entry into the study if they were healthy, at least 21 years of age, Fitzpatrick skin type 2 to 4 and with the presence of at least 2 facial subareas with visible lines/wrinkles and elastosis which correlated to a score of 2 to 6 on the Fitzpatrick Classification of Wrinkling and Degree of Elastosis. The study was approved by an Institutional Review Board and all participants signed an informed consent form. Subjects were free to discontinue their participation at any time during the study. For the histological portion of the study, subjects were eligible for entry into the study if they were healthy, at least 21 years of age, Fitzpatrick skin types 2 to 4, and planning to undergo an abdominoplasty.

Histology

One site (Toronto, Ontario) conducted histological evaluation of abdominal skin morphological changes induced by 1 treatment with the fractional RF applicator at different time points before sample excision. Human abdomen skin obtained from 7 subjects undergoing abdominoplasty was used to characterize the damage profile of different combinations of electrode-pins array densities and energies (Table 1). Six-mm diameter punch biopsies of treated and untreated control abdominal areas were obtained following abdominoplasty at fixed time points following the treatment including immediately, 2 hours, 6 hours, 24 hour, 2 days, 10 days, or 30 days after, in order to evaluate the *in vivo* impact of the fractional RF applicator at different time points during tissue response and wound healing. The samples were fixed in formaldehyde for serial

© 2009-Journal of Drugs in Dermatology. All Rights Reserved.
This document contains proprietary information, images and marks of Journal of Drugs in Dermatology (JDD).
No reproduction or use of any portion of the contents of these materials may be made without the express written consent of JDD.
If you feel you have obtained this copy illegally, please contact JDD immediately.

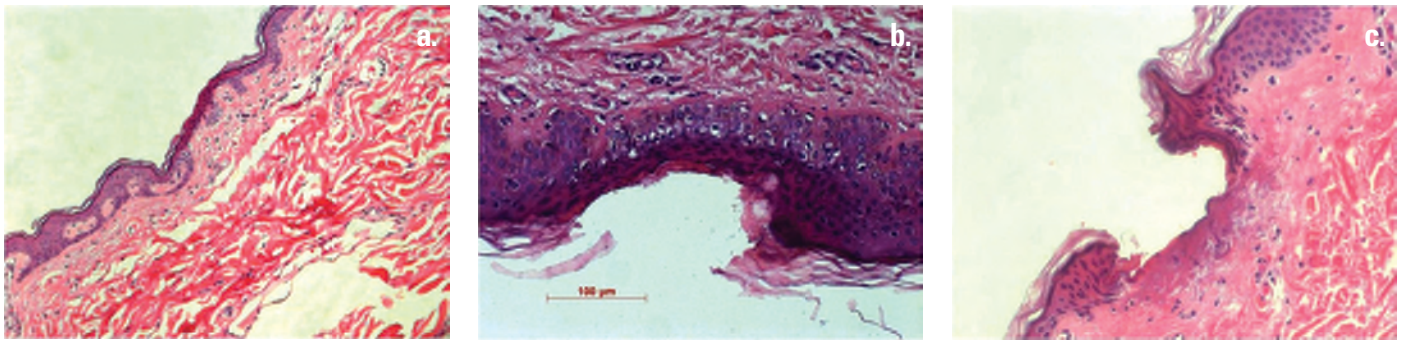

FIGURE 1. Histology of skin biopsies demonstrating tunable ablation and coagulation/necrosis effects immediately after fractional treatment using varying energy levels: **a)** Skin immediately posttreatment with the 64 electrode pin at a 8 J energy level and 5% coverage showing a predominant effect of heating and coagulation (original magnification X50); **b)** Skin (×200) posttreatment with the 144 electrode pin at a 14 J energy level and 5% coverage. Crater-shaped zones of ablation, coagulation and necrotic to subnecrotic skin tissue are apparent. Note that microvacuolization is visible in cells deeper to the coagulated zone (deeper keratinocytes) (original magnification X200); **c)** Tissue ablation with total epidermal removal posttreatment with the 64 electrode pin at a 20 J energy level and 5% coverage (original magnification X100).

sectioning and stained with hematoxylin and eosin (H&E) in preparation for histological analysis.

Clinical evaluation

Subjects received 3 treatments with the fractional RF applicator on their entire face or at least on 2 facial subareas at 3-week to 4-week intervals and were assessed 4 weeks after their last treatment. At baseline, subjects were classified according to their skin type as well as degree of wrinkling and elastosis based on the Fitzpatrick classification of wrinkling and degree of elastosis. Topical anesthesia (up to 30% lidocaine) was used for up to 1 hour prior to the procedure and the face was thoroughly washed with alcohol and dried prior to treatment. The choice of treatment parameters was made when taking into consideration the severity of the treated condition. Efficacy was assessed clinically by both the treating investigator and the subjects at the third treatment and at the 4-week follow up visit. Standardized high-quality digital photographs (Visia®; Canfield Scientific, Fairfield, NJ) were taken before the first treatment, before the third treatment and at the 4 week follow up visit after the third treatment. Side effects and complications were recorded for the safety evaluation. Improvements in skin texture and wrinkle appearance compared to baseline photographs and according to the Fitzpatrick wrinkle scale were rated by a nontreating investigator using a 5-point scale (0, 1-25%, 26-50%, 51-75%, 76-100%). Participants were asked to grade their own impression on the overall improvement and their satisfaction with the treatment. Subjects were also asked to rate their pain on a 0 to 4 scale (0=none, 1=slight, 2=moderate, 3=severe, 4=intolerable), and received instructions regarding reporting any possible complications of treatment as well as early posttreatment redness, swelling and pain.

RESULTS

Histological Findings

Histological evaluation of abdominal skin biopsies taken immediately after treatment with the fractional RF applicator demonstrated demarcated zones of ablation and coagulation/necrosis and sub-necrotic tissue (Figure 1). The overall effect was restricted to a depth of 100 µm to 450 µm. Crater-shaped ablation zones were restricted to the epidermis. Coagulation/necrosis predominated in the deeper keratinocyte layers and, with more aggressive settings, in the superficial dermis (Figure 1). Heat-related dermal alterations (darker H&E staining) up to 450 µm deep from the skin surface were noted. Microvacuolization was visible in cells deeper to the coagulated zones. No alterations were found in the subcutaneous zone. Higher energy levels (up to 20 J), lower electrode-pin density and 5% coverage mode had a greater impact on tissue as was evident by the deeper areas affected by ablation, coagulation/necrosis and subnecrosis (Figure 1 and Table 1). Moreover, there seemed to be a tunable balance between the relative ratio of tissue ablation and coagulation such that the lower energy level (2 J) produced more heating and coagulation/necrosis, while the leading impact of the higher energy level (up 20 J) was ablation. Table 1 summarizes the immediate typical morphological changes associated with RF delivery using different electrode-pins densities and energy levels.

The recovery phase was initiated by the appearance of a fine eschar in the majority of samples taken 24 hours after abdominoplasty, but could also be detected in biopsies taken as early as 2 to 6 hours posttreatment, especially when the higher energy level was used. Complete tissue healing was noted 2 days following treatment with no evidence of ablated tissue and only slight remnants of coagulation/necrosis. The immediate healing response was characterized by denser, more compact

© 2009-Journal of Drugs in Dermatology. All Rights Reserved.
This document contains proprietary information, images and marks of Journal of Drugs in Dermatology (JDD).
No reproduction or use of any portion of the contents of these materials may be made without the express written consent of JDD.
If you feel you have obtained this copy illegally, please contact JDD immediately.

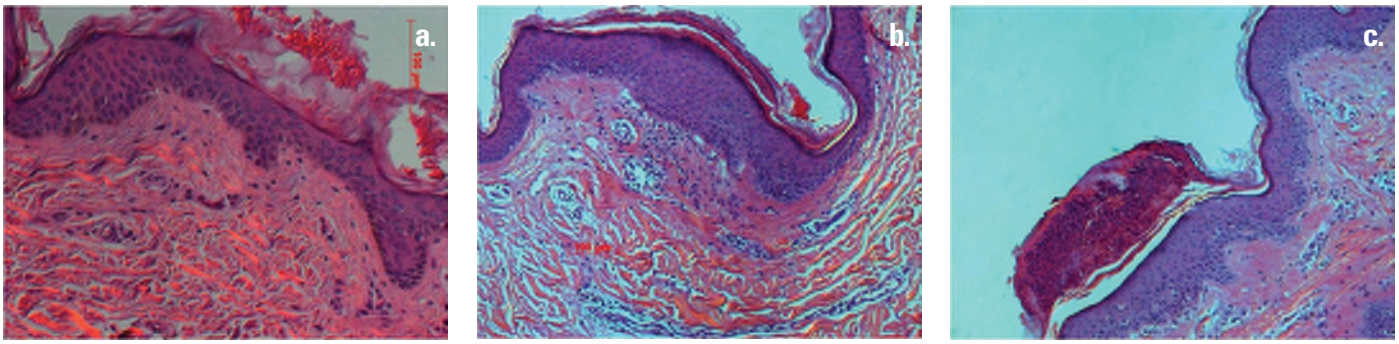

FIGURE 2. Histology of skin biopsies taken at 3 recovery time points posttreatment with fractional RF 64 electrode pin at a 8 J energy level with 5% coverage (hematoxylin and eosin stain): **a)** 6 hours posttreatment reveals partial re-epithelization of the epidermis with a significant inflammatory response (original magnification X200); **b)** Initial appearance of fine eschar and continuous re-epithialization of the skin surface at 12 hours posttreatment (original magnification X50). Note the appearance of compact and denser collagen fibers and leukocytic infiltrate; and **c)** At 24 hours posttreatment (original magnification X50), the epidermis has completely re-epithialized and necrotic debris (eschar) is observed at the skin surface (X50).

and better organized collagen fibers (Figure 2).

Clinical Evaluation

Thirty-five subjects (33 females, 2 males, mean age 52 ± 8 years) completed the study with the full 3 treatment course. Subjects had Fitzpatrick skin type 2 (17%), 3 (71%), and 4 (11%). Treatment areas included the cheeks (5 areas), forehead (13 areas), perioral (12 areas), periorbital (21 areas) and full face (11 subjects). All over, baseline elastosis scores were dependent on subjects' age such that older patients had higher grades of wrinkling (analysis of variance [ANOVA], $P < .0001$). The anatomic area to be treated had no effect on the choice of the treatment parameters (energy level, electrode pin number and % coverage mode). However, it seems that the physicians tend to use the higher coverage in older patients with more severe baseline elastosis scores (Spearman's rank correlation coefficient (Spearman's rho=.42; ANOVA, $P < .0001$ and Spearman's rho=.43; ANOVA, $P < .0001$, respectively). Treatment with 5% coverage was more common in subjects with darker skin (Spearman's rho=.43; ANOVA, $P < .0001$). The end points of therapy were mild to moderate erythema and edema at the site of treatment which usually appeared 1 to 2 minutes posttreatment, were most prominent 30 minutes posttreatment and usually did not last longer than a few hours and were not accompanied with any downtime. A fine eschar pattern was present for 2 to 3 days following treatment.

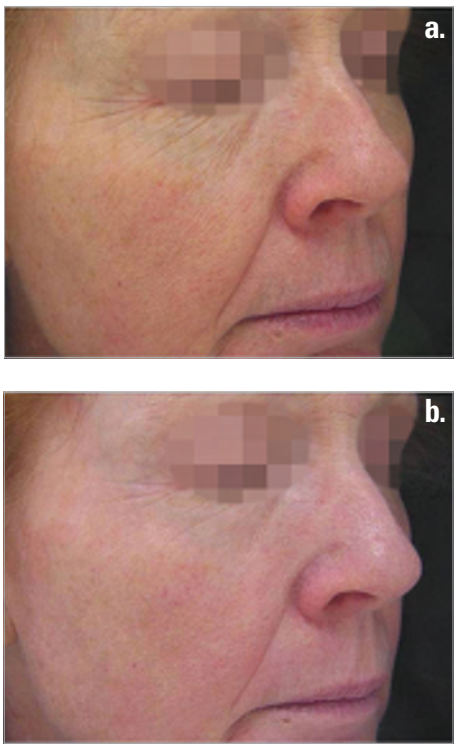

FIGURE 3. a) Before and **b)** 4 weeks after the third treatment of the periorbital and perioral areas with the fractional RF 64 electrode pin, 8-20J energy level at both 5% and 10% coverage rates. Note the appearance of flattened crow's feet wrinkles.

At the clinical assessment carried out by the physicians 1 month following the last treatment, improvement in the different facial parameters was noticed in most of the patients with 83% showing improvement in skin brightness, 87% in skin tightness and 90% in smoothness/wrinkling. Improvement of 40% or greater was noted in brightness, tightness and smoothness/wrinkling in 47%, 55% and 46% of the subjects, respectively. We also observed an overall tighter skin appearance (Figures 3 and 4). There was a trend toward a lesser degree of wrinkling and elastosis although the difference was not statistically significant. According to the investigators' assessment and the posttreatment elastosis scores, the best improvement was noted in the periorbital areas and the least in the perioral areas. This observation was statistically significant (ANOVA, $P=.0004$).

Subjects also perceived improvement in all facial parameters (Figure 5). Eighty percent of the subjects were satisfied with their treatment with 40% being somewhat satisfied, 17% being satisfied and 23% being very or extremely satisfied. The subjects' assessments for improvement in facial parameters correlated with the physicians' evaluations as well as with the posttreatment elastosis scores (Spearman's rho=.5 - 0.56 for

© 2009-Journal of Drugs in Dermatology. All Rights Reserved.
This document contains proprietary information, images and marks of Journal of Drugs in Dermatology (JDD).
No reproduction or use of any portion of the contents of these materials may be made without the express written consent of JDD.
If you feel you have obtained this copy illegally, please contact JDD immediately.

multiple parameters; ANOVA, $P < .0001$). Subjects tolerated the procedure well, reporting only minimal pain and discomfort during treatment (87% of patients) and no downtime. Four patients experienced moderate pain and only 1 subject felt severe pain in the periorbital area. Two cases of temporary adverse events occurred; 1 subject had prolonged edema; another had erythema, which was treated with an antibacterial ointment. Pain was found to be inversely correlated with energy level (Spearman's rho = -0.5; ANOVA, $P < .0001$) and subjects with a darker skin type perceived less pain than subjects having a lighter skin (type 2) (Spearman's rho = -0.4; ANOVA, $P = .007$).

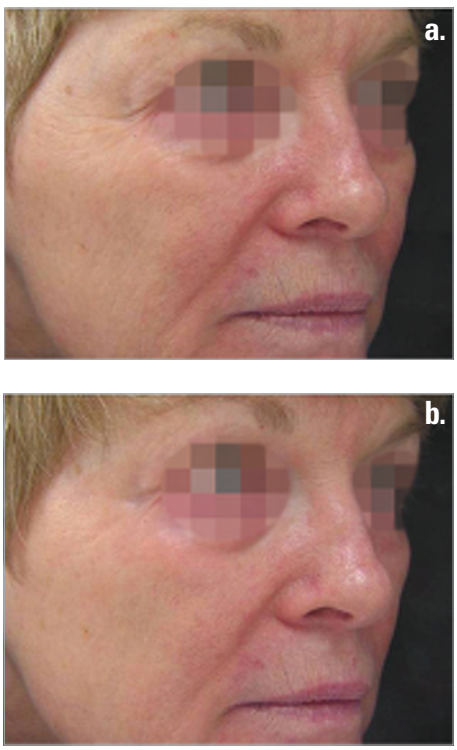

FIGURE 4. a) Before and **b)** 4 weeks after treatment of the periorbital and perioral areas with the fractional RF 64 electrode pin at a 10-16 J energy level at both 5% and 10% coverage rates. Note the improvement in skin texture around the crow's feet wrinkles.

With regard to treatment parameter correlation with the results, the pin electrode number (64 vs. 144) had no effect on the results, but energy level and coverage rate did. Higher energy levels were associated with better aesthetic results (objective and subjective evaluations of smoothness, brightness and tightness; Spearman's rho = 0.44; ANOVA, $P < .0001$) and higher satisfaction rates (ANOVA, $P = .0002$). The choice of coverage rate (5% versus 10%) was not as pronounced but still significant. Treatment with the 5% coverage mode gave better results ($P = .02$) with less pain ($P < 0.0001$),

DISCUSSION

The current study reports on a novel fractional ablative and coagulative resurfacing RF-based device designed for skin rejuvenation treatment. The device is tunable in the sense that the relative proportion of ablation/coagulation/necrosis as well as the depth of the ablated zones and the extent of the surrounding coagulated tissue may be controlled and customized to design procedures targeted for specific indications and treated areas. Current RF technology is used for nonablative skin tightening via volumetric heating of the dermis.[14] The fractional RF applicator is the first RF nonlaser nonlight-

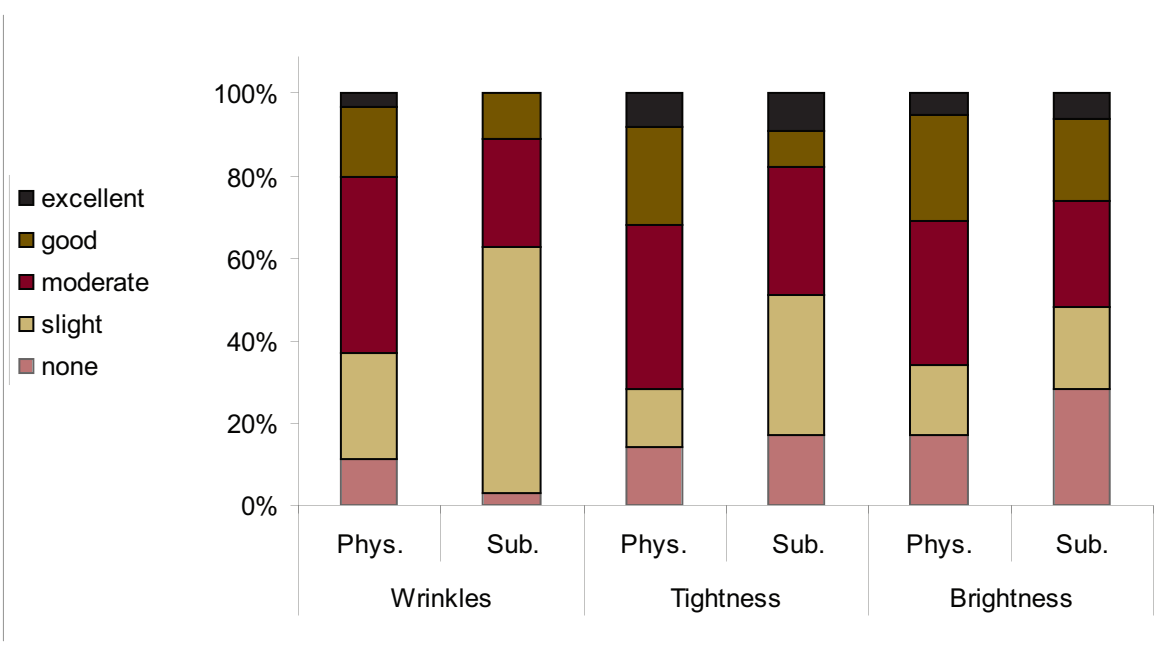

FIGURE 5. Investigators' (objective) and subjects' (subjective) assessment of improvement of different facial parameters (wrinkles, tightness, and brightness) 4 weeks following 3 fractional RF treatments. The Y axis represents the number of subjects (percent) for each degree of improvement in facial parameters.

© 2009-Journal of Drugs in Dermatology. All Rights Reserved.
This document contains proprietary information, images and marks of Journal of Drugs in Dermatology (JDD).
No reproduction or use of any portion of the contents of these materials may be made without the express written consent of JDD.
If you feel you have obtained this copy illegally, please contact JDD immediately.

based device capable of inducing skin ablation/coagulation/necrosis and resurfacing impacts. Two basic assumptions are being considered with regard to tissue-RF interaction. The first assumption is that tissue injury is thermally mediated. The second assumption is that heat transfer in tissue should be a predictable biophysical phenomenon. The relationship between cell injury and temperature is such that little damage occurs at temperatures below 45°C. At 45° to 50°C, there is a transition zone above which irreversible injury to tissue (coagulation/necrosis) occurs after a short hyperthermic exposure. Heating tissue to or above a threshold of 100°C will result in evaporation (ablation).[15] Additionally, the premise from a biological aspect requires that the ideal skin treatment mode applies resurfacing technology in a fractional manner, which is conceivable by creating islands of epidermal and dermal ablation and coagulation/necrosis and deeper thermal damage to the dermis but leaving out at least the same amount of intact skin zones in between to stimulate a robust wound healing response. The present study supports the concept that RF energy delivery via the fractional RF applicator can target the skin surface with fractional ablation of the epidermis and is capable of dermal coagulation/necrosis and sub-necrosis, leaving intervening areas of unaffected tissue to initiate healing and facilitate recovery. With regard to clinical perspective, the current report on the outcome of 35 patients treated with the fractional RF clearly supports the safety and efficacy of the applicator for use in skin rejuvenation therapy.

Mechanism of Action

The nonhomogenous fractional manner by which fractional RF operates and affects skin is formed by the arrangement of the multielectrode-pins array all together with the mode of application on a dry non-cooled surface. The RF current flows via the skin between the electrode-pin rows, having spatial and depth-related impact with the highest effect at the electrode-skin contact points. Diverse energy densities along the RF current's path create different impacts not only at varying tissue depths but also in between the electrode-pins themselves. Due to tissue physiological characteristics, at the upper skin surface (the dry stratum corneum) where the impedance is high, RF flows via each pin by its self (like monopolar), leading mostly to ablation.[10] Inside the tissue (deeper epidermis and dermis), the impedance is lower as the tissue is enriched with water and electrolytes and allowing RF flow between the electrode pins (true bipolar) creating a wider diffusible effect in the form of coagulation/necrosis with not as much tissue ablation. As opposed to skin zones under such irreversible RF impacts (eg, ablation or coagulation/necrosis), the RF energy density is further decreased deeper and occasionally lateral to the coagulated zone. This results in added areas of coagulated/necrotic, subnecrotic or just stimulated tissue. Additionally, a zone of heat-derived reversible impact is formed to a depth at which RF still travels but its density is below the threshold for causing any other biological impact.

Healing Response

The natural course of wound healing involves remodeling of dermal collagen and other matrix molecules.[16] This remodeling involves heat-related collagen shrinkage and an initial inflammatory phase characterized by massive high levels of matrix metalloproteinases (MMPs) that degrade the fragmented collagenous matrix followed by substantial and extended production of new undamaged collagen.[16] Thus, for effective resurfacing to occur, regeneration of the epidermis as well as portions of the dermis is required, thereby improving both the appearance and health of the aged skin.[17] The immediate interpretation of the histological findings is of a leading mechanism of demarcated degeneration of small tissue spots. These demarcated areas result in microeschars that will be shed off the skin and the remaining intact skin between affected zones will serve as a cellular reservoir which supports and protects the overall integrity of the skin, allowing relatively rapid re-epithelialization and neocollagenesis (Figure 2) of the treated zone with consequently little risk of infection and scarring. The irreversible tissue ablation, coagulation/necrosis and collagen shrinkage induced by the fractional RF spherical RF conductivity may eventually result in better clinical and aesthetic results (Figures 3 and 4).[1]

Histology

The authors found that RF impact on tissue was dependent on the actual energy density per electrode-pin. Morphologically, the affected zones tended to become deeper as the level of energy employed was increased (Table 1), either by increasing the energy level per electrode-pin array or by using a tip with a lower electrode-pins density, thereby increasing the energy density per electrode-pin. Additionally, the depth of impact depends largely on the distance between the electrode-pins of the tip. It is accepted that the effective impact of a bipolar RF electrode is approximately half the distance between the electrodes. Therefore, the 144 pin-electrode tips, having inter-pin distance of 1.0 mm, may theoretically reach a maximal penetration depth of 500 μm while the 64 pin-electrode, having inter-pin distance of 1.5 mm, may impact the tissue up to a depth of 750 μm. The histological findings strongly suggest a relationship between increased epidermal elimination, tissue coagulation/necrosis and sub-necrosis and tissue neocollagenesis. This supports the concept that by producing a stronger tissue reaction and dermal irritation, one might have better results in more severe cases. Of note, having more electrodes per square area results in a more homogenous and less fragmented impact whereas each fractional ablated and coagulated zone tends to become slightly wider with the higher coverage mode (10% versus 5%).

Clinical Evaluation

Our clinical findings correlate with the histological changes. We

© 2009-Journal of Drugs in Dermatology. All Rights Reserved.
This document contains proprietary information, images and marks of Journal of Drugs in Dermatology (JDD).
No reproduction or use of any portion of the contents of these materials may be made without the express written consent of JDD.
If you feel you have obtained this copy illegally, please contact JDD immediately.

found that both energy level and coverage mode had a major impact on the improvement in skin texture such that treatment at a higher energy level and/or lower coverage mode enhanced the aesthetic results. Clinically, the effects achieved contributed to rejuvenation of the skin and entailed minor adverse sequelae consisting of transient mild to moderate swelling, erythema, heat sensation and minimal discomfort. Interestingly, the use of a higher energy level and the lower 5% coverage mode produced significantly less pain. This phenomenon may be attributable to the predominant effect of ablation and less release of pain mediators as opposed to the release of pain mediators by tissue coagulation/necrosis/subnecrosis (Table 1). Alternatively, it is conceivable that during treatment at higher energy levels partial injury to nerve endings may have occurre.[18] Nevertheless, the technique is an improvement to any sort of homogenous full surface ablative technology (either laser or RF based) in which the entire skin tissue is affected thereby resulting in prolonged healing, recovery and patient downtime.[6] Based on our clinical experience, fractional RF delivery via Matrix RF can be used safely in most skin types, giving a significant objective improvement in skin smoothness, tightness, brightness and wrinkles.

The size, density and damage profile of the fractional zones that maximize efficacy with minimal downtime and a high margin of safety are still not known. This may vary for different dermatologic indications as well as from one individual to another. Additional studies are underway to further define these parameters for a variety of dermatologic conditions.

CONCLUSION

Fractional ablation and resurfacing with fractional RF can achieve effective skin rejuvenation with effects on both the epidermis and dermis. Tunable RF delivery can be accurately optimized to treat a wide range of clinical conditions by modulating the energy level and coverage rate with good correlation with histologic signs at the cellular level. This study demonstrated that fractional RF treatment is safe, easily tolerated and effective in reducing wrinkles with an overall improvement in skin texture

REFERENCES

1. Fisher GJ, Varani J, Voorhees JJ. Looking older: Fibroblast collapse and therapeutic implications. *Arch Dermatol.* 2008;144:666-672.
2. Alexiades-Armenakas MR, Dover JS, Arndt KA. The spectrum of laser skin resurfacing: nonablative, fractional, and ablative laser resurfacing. *J Am Acad Dermatol.* 2007;58:719-737.
3. McDaniel DH, Ash K, Lord J, Newman J. The erbium:YAG laser: A review and preliminary report on resurfacing of the face, neck and hands. *Aesthet Plast Surg* 1997;17:157-164.
4. Trelles MA, Gracia-Solana L, Calderhead RG. Skin resurfacing improved with a new dual wavelength ER:YAG/CO_2 laser system: A comparative study. *J Clin Laser Med Surg.* 1999;17:99-104.
5. Fitzpatrick RE, Goldman MP, Sriprachya-Anunt S. Resurfacing of photodamaged skin on the neck using the Ultrapulse carbon dioxide laser. *Lasers Surg Med.* 2001;28:145-149.
6. Trelles MA, Allones I, Luna R. One-pass resurfacing with a combined-mode erbium: ER:YAG/CO_2 laser system: A study in 102 patients. *Br J Dermatol.* 2002;146:473-480.
7. Geronemus RG. Fractional photothermolysis: current and future applications. *Laser Surg Med.* 2006;38:169-176.
8. Hantash BM, Mahmood MB. Fractional photothermolysis: a novel aesthetic laser surgery modality. *Dermatol Surg.* 2007;33:525-534.
9. Jih MH, Kimyai-Asadi. Fractional photothermolysis: a review and update. *Semin Cutan Med Surg.* 2008;27:63-71.
10. Gold MH. Fractional technology: a review and clinical approaches. *J Drugs Dermatol.* 2007;6:849-852.
11. Lapidoth M, Odo MEY, Odo LM. Novel use of Erbium:YAG (2,940-nm)laser for fractional ablative photothermolysis in the treatment of photodamaged facial skin: Apilot study. *Dermatol Surg.* 2008;34:1048-1053.
12. Trelles MA, Mordon S, Velez M, et al. Results of fractional ablative facial skin resurfacing with the erbium:yttrium-aluminium-garnet laser 1 week and 2 months after one single treatment in 30 patients. *Laser Med Sci.* 2008;Feb 19 [Epub ahead of print].
13. Trelles MA, Vélez M, Mordon S. Correlation of histological findings of single session Er:YAG skin fractional resurfacing with various passes and energies and the possible clinical implications. *Lasers Surg Med.* 2008;40:171-177.
14. Dierickx CC. The role of deep heating for noninvasive skin rejuvenation. *Lasers Surg Med.* 2006;38:700-807.
15. Lord SM, Barnsley L, Wallis BJ, et al. Percutaneous radio-frequency neurotomy for chronic cervical zygapophyseal-joint pain. *N Engl J Med.* 1996;335(23):1721-1726.
16. Orringer JS, Kang S, Johnson TM, et al. Connective tissue remodeling induced by carbon dioxide laser resurfacing of photodamaged skin. *Arch Dermatol.* 2004;140:1326-1332.
17. Orringer JS, Johnson TM, Kang S et al. Effect of carbon dioxide lase resurfacing on epidermal p53 immunostaining in photodamaged skin. *Arch Dermatol.* 2004;140:1073-1077.
18. Schramm W, Yang D, Haemmerich D. Contribution of direct heating, thermal conduction and perfusion during radiofrequency and microwave ablation. Conf Proc IEEE. *Eng Med Biol Soc.* 2006;1:5013-5016..

ADDRESS FOR CORRESPONDENCE

Amy Forman Taub MD
Director
Advanced Dermatology, Skinfo, SKINQRI
275 Parkway Drive Suite 521
Lincolnshire, IL 60069
Phone: ..... (847) 459-6400
Fax: ..... (847) 459-4610
e-mail: ..... drtaub@advdermatology.com

© 2009-Journal of Drugs in Dermatology. All Rights Reserved.
This document contains proprietary information, images and marks of Journal of Drugs in Dermatology (JDD).
No reproduction or use of any portion of the contents of these materials may be made without the express written consent of JDD.
If you feel you have obtained this copy illegally, please contact JDD immediately.

View publication stats

ILOODA EXHIBIT 1031 - 7/7