Archives of Cardiovascular Disease (2012) **105**, 153—159

Available online at
SciVerse ScienceDirect
www.sciencedirect.com

Elsevier Masson France
EM|consulte
www.em-consulte.com/en

REVIEW

Transcatheter aortic valve implantation: The evolution of prostheses, delivery systems and approaches

Implantation de valves aortiques par voie percutanée : évolutions technologiques

John G. Webb*, Ronald K. Binder

McLeod professor and British Columbia director structural heart intervention, University of British Columbia, St. Paul's Hospital, 1081, Burrard Street, Vancouver, BC, V6Z 1Y6, Canada

Received 20 January 2012; received in revised form 1st February 2012; accepted 2 February 2012
Available online 16 March 2012

KEYWORDS
Transcatheter aortic valve implantation (TAVI);
Aortic stenosis;
Medtronic CoreValve;
SAPIEN valves

Summary It is two decades since the first report of transcatheter implantation of a stented aortic valve in an animal. The first implantation of a transcatheter aortic valve in a human was accomplished just one decade ago dramatically demonstrating the promise and feasibility of this new therapy. Over the past 10 years, there have been rapid developments in valves, delivery systems and technical approaches. Today, transcatheter valve implantation is a technical possibility for the great majority of patients with aortic stenosis. The next 10 years may well see this become the dominant therapy for aortic stenosis.
© 2012 Elsevier Masson SAS. Open access under CC BY-NC-ND license.

MOTS CLÉS
Valve aortique ;
Transcatheter ;
Rétrécissement aortique ;
Remplacement valvulaire aortique

Résumé Deux décennies se sont écoulées depuis la première implantation d'une valve stentée chez l'animal. La première implantation d'une valve aortique percutanée chez l'homme a été réalisée, il y a juste dix ans, avec une faisabilité démontrée et des perspectives prometteuses. Ces dix dernières années ont connu un développement technologique rapide que ce soit sur les valves elles-mêmes, les dispositifs de délivrance ou les voies d'abord. Aujourd'hui, l'implantation de valves aortiques percutanées est techniquement accessible à une majorité de patients porteurs d'un rétrécissement aortique. Il est possible que dans les dix prochaines années, cette technique devienne le traitement prédominant du rétrécissement aortique.
© 2012 Elsevier Masson SAS. Cet article est publié en Open Access sous licence CC BY-NC-ND.

Abbreviations: TAVI, Transcatheter aortic valve implantation; THV, Transcatheter heart valve.

* Corresponding author.
E-mail address: john.webb@vch.ca (J.G. Webb).

1875-2136 © 2012 Elsevier Masson SAS. Open access under CC BY-NC-ND license.
doi:10.1016/j.acvd.2012.02.001

Edwards v. Aortic Innovations
U.S. Patent 11,497,634
Edwards Ex. 1023

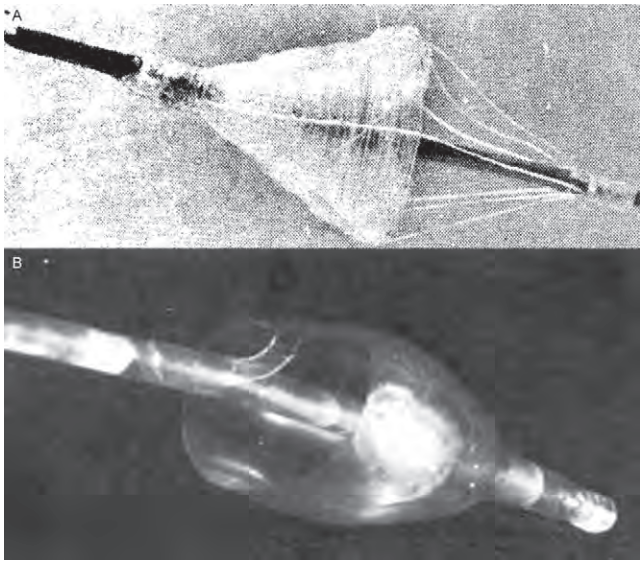

Figure 1. Early catheter-mounted valves. Parachute-like valves offered little resistance to the flow of blood in one direction, but obstructed the flow in the other. Animal studies suggested benefit in the setting of aortic regurgitation.
Reprinted with permission from Davies. 1965 [1] (A) and Phillips et al., 1976 [4] (B).

Background

Almost 50 years ago, in 1965, Hywel Davies placed a catheter-mounted valve via the femoral artery into the descending aorta of a dog [1]. The parachute-like valve was oriented so as to passively open in diastole and obstruct retrograde flow in the patients with aortic regurgitation. Over the subsequent few decades, a number of groups experimented with various catheter-mounted passive and active temporary valves (Fig. 1). These valve designs were intended as temporary palliation for aortic regurgitation and were never utilized in humans [2—4].

The first catheter intervention specifically targeted at the stenotic aortic valve was aortic balloon valvuloplasty; developed initially as a therapy for congenital aortic stenosis, and described for degenerative aortic stenosis in adults in 1986 by Alain Cribier [5]. The feasibility of dilation of the stenotic calcific valve provided the seed for future developments. In 1992, Henning Andersen described the first transcatheter aortic stent valve [6]. This was constructed of a handmade wire frame within which was sewn a porcine aortic valve (Fig. 2). The assembly was crimped onto a balloon catheter and implanted transarterially into a pig. Subsequently, a number of groups, including our own, pursued the development of a practical and reliable transcatheter stent-mounted valve suitable for implantation in humans [7]. In 2000, Philippe Bonhoeffer described a bovine jugular venous valve sewn within a large-diameter stent, which was implanted percutaneously in children with pulmonary conduits [8]; proving the feasibility of transcatheter valve implantation in humans.

However, it was in 2002, 10 years ago, that Alain Cribier accomplished the first transcatheter aortic valve implantation (TAVI) for aortic stenosis [9]; opening the door to a new age in the management of this relatively common disease.

Evolution of transcatheter valves

Balloon-expandable valves

The original Cribier-Edwards valve (Edwards Lifesciences Inc., CA, USA) was constructed from a laser-cut stainless steel tubular frame within which was sewn valve leaflets constructed from equine pericardium, with the inflow covered with a fabric sealing cuff (Fig. 3A). This valve was subsequently modified as the Edwards SAPIEN transcatheter heart valve (THV) (Fig. 3B), incorporating more durable bovine pericardium, and a higher sealing cuff to reduce paravalvular leaks [10].

The SAPIEN valve was subsequently superseded by the low-profile Edwards SAPIEN-XT valve (Fig. 3C); in which the stainless steel was replaced with a cobalt chromium alloy frame [10,11]. This alloy allows for a thinner, stronger, more open and compressible frame, while the reengineered leaflets ensure valve closure even when closing pressures are low, along with increased durability. Importantly, this valve was designed to allow the use of smaller diameter 18 French delivery systems. The SAPIEN-XT valve is currently manufactured with diameters of 20, 23, 26 and 29 mm. Next-generation SAPIEN valve systems are currently undergoing evaluation, and will incorporate additional leaflet, frame and sealing enhancements to further reduce delivery profile and paravalvular leaks.

CoreValve

In 2005, following initial implants in India, early German experience with the CoreValve (Fig. 4) was reported by Grube et al. [12]. The valve frame was constructed of nitinol; a nickel-titanium alloy that can be manufactured so as to be malleable when cool, but to become relatively rigid at body temperature. The valve leaflets and annular seal were constructed of porcine pericardium. The valve is cooled and compressed within a delivery catheter, which is then placed within the diseased valve. As a covering sheath is withdrawn, the valve is released and expands, returning to its preset shape. A long multi-staged frame is anchored within the aortic annulus as with the SAPIEN valves, but also extends superiorly to anchor in the supracoronary aorta. The supracoronary portion serves to self-centre the valve and provides an additional point of fixation. The CoreValve (Medtronic Inc., MN, USA) is currently available with diameters of 26, 29 and 31 mm.

Only limited non-randomized comparisons are available [13,14]. Deployment of the CoreValve device may be more intuitive, and does not require rapid pacing, while deployment of the SAPIEN device may be more targeted and clinical benefit is better documented. The CoreValve device can, up to a point, be repositioned or retrieved, although this process is not without complications [15]. Coronary obstruction is rare, but more of a concern with the SAPIEN-type valves. Atrioventricular block requiring pacemaker implantation is much more common with CoreValve. Both valves

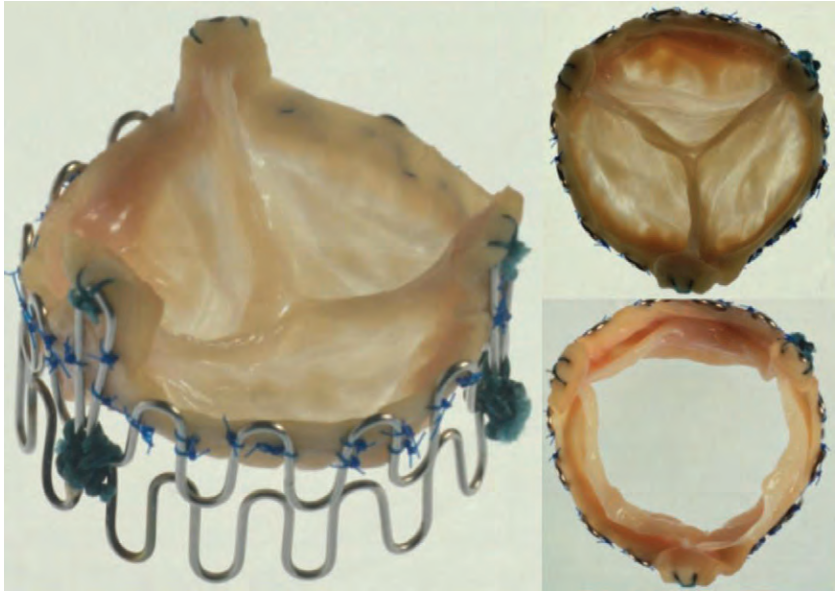

Figure 2. The Andersen valve. The valve was constructed of a handmade wire frame to which was sewn a porcine valve. Reprinted with permission from Dr. Henning Andersen.

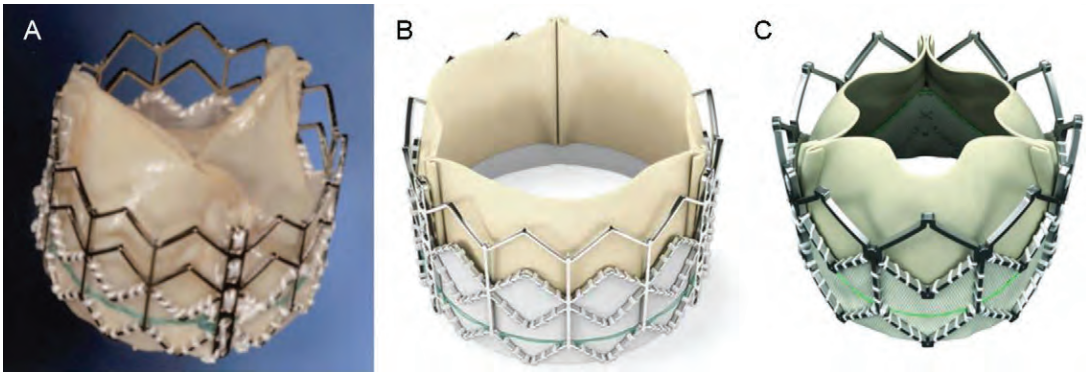

Figure 3. Balloon-expandable valves. The Cribier-Edwards (A), SAPIEN (B) and SAPIEN-XT (C) valves. Reprinted with permission.

can offer dramatic clinical benefit and both systems continue to improve.

Newer valves

Several newer transcatheter valves (Fig. 5) are in various stages of evaluation. Some are in clinical use, although experience remains very limited [16—18]. Generally, these newer valves attempt to improve on the widely available SAPIEN-XT and CoreValve devices by enhancing deliverability, positioning, sealing, or facilitating repositioning or removal.

Some valves have unique expansion mechanisms. The Lotus™ valve (Boston Scientific Inc., MN, USA) (Fig. 5A) frame is constructed of woven nitinol wires which, when tensioned, cause the valve to decrease in height while increasing in diameter and rigidity. The Direct Flow™ valve (Direct Flow Medical Inc., CA, USA) (Fig. 5B) has a tubular fabric frame that is inflated with a rapid-setting polymerizing agent. The CENTERA valve (Edwards Lifesciences Inc., CA, USA) (Fig. 5C) is released from its constrained state by



Figure 4. Medtronic CoreValve.

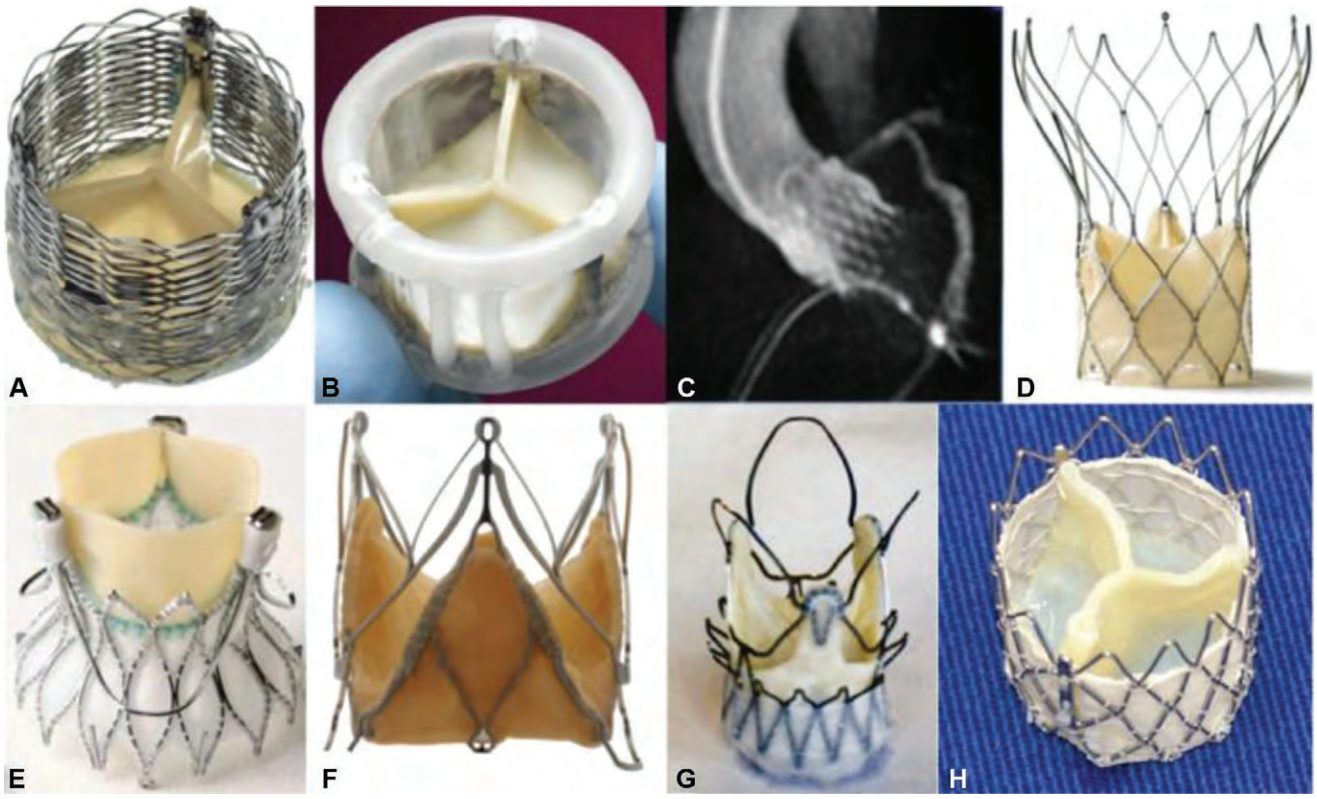

Figure 5. Newer valves: Lotus™ valve (Boston Scientific Inc., MN, USA) (A); Direct Flow™ valve (Direct Flow Medical Inc., CA, USA) (B); CENTERA™ valve (Edwards Lifesciences Inc., CA, USA) (C); Portico™ valve (St. Jude Medical Inc., MN, USA) (D); Engager™ valve (Medtronic Inc., MN, USA) (E); JenaClip™ valve (JenaValve Inc., Munich, Germany) (F); Acurate™ valve (Symetis, Ecublens, VD, Switzerland) (G); Braile valve (Braile Biomédica, Brazil) (H).

an electric motor. However, for the most part, these valves utilize self-expanding heat-set nitinol frames that facilitate thinner delivery systems and repositioning.

Some valves, such as the Portico™ (St. Jude Medical Inc., MN, USA) (Fig. 5D) and Acurate™ (Symetis, Ecublens, VD, Switzerland) (Fig. 5G) valves, are long and extend into the supracoronary aorta to assist with alignment and provide additional fixation, as does the CoreValve device. Some, such as the Engager™ (Medtronic Inc., MN, USA) (Fig. 5E), Acurate (Symetis, Ecublens, VD, Switzerland) (Fig. 5G), and JenaClip™ (JenaValve Inc., Munich, Germany) (Fig. 5F) valves, incorporate flexible arms that extend above the native leaflets to facilitate positioning and rotational orientation in relation to the native commissures and coronaries. These newer valves are generally aiming to match the 18 French diameter of current systems, although 16 French and even 14 French systems are very near. The Braile valve (Braile Biomédica, Brazil) is a balloon-expandable valve, perhaps representing a lower cost alternative.

We can expect two new systems from Edwards Lifesciences Inc. to undergo CE mark evaluation in the near future. The balloon-expandable SAPIEN 3™ valve will incorporate features to improve paravalvular sealing. The CENTERA™ valve (Fig. 5C) will offer a self-expandable alternative with an electric motor assisted release mechanism. Both will be compatible with 14 to 16 French expandable sheath delivery systems.

Evolution of approaches

Transvenous

The first TAVI procedures were performed with percutaneous femoral venous access, with transseptal access to the left atrium, mitral valve, left ventricle, and then antegrade through the aortic valve [9,19]. The femoral vein was easily able to accommodate the large sheath required for the bulky Cribier-Edwards valve crimped onto a standard valvuloplasty balloon. However, the procedure was complex, difficult to learn, and complications were common. Consequently this procedure was largely abandoned with the advent of the transarterial procedure in 2005.

Femoral arterial

The retrograde transarterial femoral procedure was developed concurrently by our group in Canada and Grube et al. in Germany [20,21]. Transfemoral arterial access resulted in a more reproducible and generalizable procedure, and was largely responsible for the rapid uptake of TAVI worldwide. The main initial limitation was the size of early generation systems, ranging from 22 to 25 French in diameter.

The large-diameter CoreValve delivery system was relatively well suited to a reduction in profile, and 18 French systems soon became available. Significant reductions in the diameter of the Edwards systems took longer due to the

Figure 6. Medtronic CoreValve and the Accutrak delivery system.

additional bulk of the deployment balloon. However, this problem was largely solved with the advent of the current low-profile Novaflex™ system, with which the valved stent was introduced into the sheath first and only later mounted on the balloon after both had been passed into the aorta.

Both delivery systems have undergone a number of iterative changes over the past 7 years. In addition to a reduction in profile, the CoreValve delivery system has incorporated the proprietary Accutrak stability layer™ technology (Fig. 6), which markedly reduced the forces required to retract the covering sheath, facilitating relatively more accurate placement of the valve.

The Edwards system evolved from a simple valvuloplasty balloon with a deflectable pusher RetroFlex™ catheter (Fig. 7A), to the RetroFlex 2 catheter that incorporated a tapered nosecone, then to the more refined RetroFlex 3 catheter (Fig. 7B). The nosecone greatly increased the ease of passage through the aortic arch and stenotic native valve. The Novaflex (Fig. 7C) and the, even newer and yet more refined, Novaflex plus (Fig. 7D) catheters incorporate mechanisms for aligning the SAPIEN-XT valve on the balloon, allowing insertion through smaller sheaths. Numerous other minor modifications allow more controlled and reliable passage through the aorta, positioning and valve deployment.

Both the Edwards and the Medtronic systems initially used large 22 to 25 French sheath introducers designed for the introduction of aortic endografts. The CoreValve system is currently reliant on off-the-shelf 18 French sheaths (Check-Flo™, Cook Medical Inc., IN, USA; Ultimum™, St. Jude Medical Inc., MN, USA; and DrySheath™, Gore Medical Inc., AZ, USA). Edwards Lifesciences developed its own line of sheath introducers and dilators specifically designed for this purpose. Recently, a 14 French expandable sheath has become available (SoloPath™, Onset Medical Corp., CA, USA). Once introduced into the artery, a balloon bonded to the obturator is used to dilate the stent-like frame of the sheath to over 18 French, minimizing the risk of



Figure 7. The Edwards delivery systems. Retroflex delivery catheter with the Cribier-Edwards valve (A); Retroflex 3 with the SAPIEN valve (B); Novaflex with the SAPIEN-XT valve (C); Novaflex plus (D).

arterial injury at the time of sheath insertion. Both CoreValve and SAPIEN versions are available. The Esheath™ (Edwards Lifesciences Inc., CA, USA) incorporates a fold that runs the length of the 14, 16 or 18 French sheath and dilates transiently as the SAPIEN-XT valve is passed through it.

With reduced sheath diameters and increased experience, open cutdown is progressively giving way to routine fully percutaneous access. Most operators currently use preclosure with either the Prostar™ or Proglide™ devices (Abbott Medical Inc., IL, USA). With lower-profile systems, improved screening and increased expertise, vascular complications are falling markedly in experienced, high volume centres [22]. Femoral transarterial access is currently the preferred default strategy in most centres.

Apical

The first transapical valve implantation in an animal model was performed utilizing an early self-expanding valve in Vancouver in 2000 [7]. Walther et al. implanted the Cribier-Edwards valve with the left ventricular apex exposed through a median sternotomy in Leipzig in 2006, although paravalvular regurgitation required conversion to conventional surgery in a case [23]. Successful off-pump implants using intercostal access were successfully accomplished by the Vancouver group shortly afterwards [24].

Initially, the transfemoral Retroflex system was utilized. However, the purpose-specific Ascendra delivery catheter was developed shortly afterwards. This has now been superseded by the Ascendra 2 system (Fig. 8), which is lower profile, easier to de-air, can accommodate the SAPIEN-XT valve, and facilitates use by a single operator.

Although a small number of CoreValve implants have been performed transapically, this system does not lend itself well to this approach [25]. More recently, several new self-expandable systems have been designed to take specific advantage of an apical approach; implanting the Engager, JenaValve, Acurate and Portico valves.

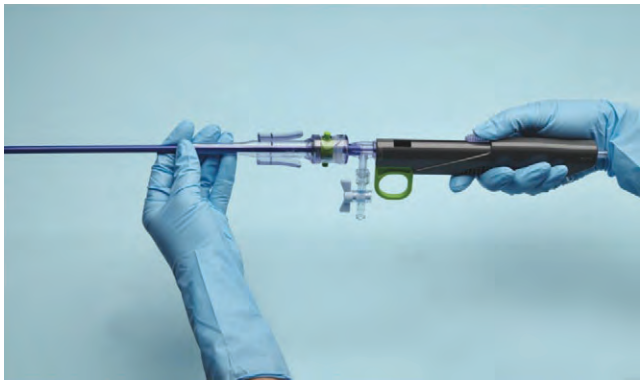

Figure 8. Ascendra 2 transapical valve delivery catheter.

Transaxillary/subclavian

Access to the axillary artery and passage through the subclavian artery often offers an appealing alternative in patients with iliofemoral disease [26,27]. The short distance and non-tortuous course to the aortic valve proved particularly advantageous for the CoreValve procedure. Initial concerns with respect to the Novaflex system, due to the need for valve alignment in a relatively straight segment of the aorta, seem to have been allayed.

Access to the axillary artery has generally been accomplished in an open fashion, due to the thin friable wall of this artery, although the feasibility of reliable percutaneous access and closure has been demonstrated. However, it is necessary to assure a fallback should initial attempts at haemostasis fail in this non-compressible artery, making this somewhat more complex than is the case with femoral access.

Transaortic

Direct access to the ascending aorta through a small parasternal incision is much more within the comfort zone of the cardiac surgeon uninitiated to left ventricular apical access [28,29]. Although this avoids the risk of apical or peripheral vascular injury, there are still concerns with respect to aortic injury or atheroembolism. Although the procedure has generally been performed with the standard Edwards or Medtronic transarterial delivery system, we can anticipate purpose-specific systems that are shorter and have lower profiles to facilitate transaortic retrograde crossing of the aortic valve. It seems likely that this approach will become increasingly popular in patients with compromised arterial access.

Conclusions

In the decade since transcatheter valve implantation was first accomplished in man, there have been tremendous advances. It is possible to speculate that the next 10 years may well see TAVI become the dominant therapy for aortic stenosis.

Disclosure of interest

John G. Webb: Consultant to Edwards Lifesciences.

Ronald K. Binder: Recipient of an unrestricted grant from the Swiss National Foundation.

References

[1] Davies H. Catheter-mounted valve for temporary relief of aortic insufficiency. Lancet 1965;285:250.
[2] Moulopoulos SD, Anthopoulos L, Stamatelopoulos S, Stefadouros M. Catheter-mounted aortic valves. Ann Thorac Surg 1971;11:423—30.
[3] Matsubara T, Yamazoe M, Tamura Y, et al. Balloon catheter with check valves for experimental relief of acute aortic regurgitation. Am Heart J 1992;124:1002—8.
[4] Phillips SJ, Ciborski M, Freed PS, Cascade PN, Jaron D. A temporary catheter-tip aortic valve: hemodynamic effects on experimental acute aortic insufficiency. Ann Thorac Surg 1976;21:134—7.
[5] Cribier A, Savin T, Saoudi N, Rocha P, Berland J, Letac B. Percutaneous transluminal valvuloplasty of acquired aortic stenosis in elderly patients: an alternative to valve replacement? Lancet 1986;1:63—7.
[6] Andersen HR, Knudsen LL, Hasenkam JM. Transluminal implantation of artificial heart valves. Description of a new expandable aortic valve and initial results with implantation by catheter technique in closed chest pigs. Eur Heart J 1992;13:704—8.
[7] Webb JG, Munt B, Makkar RR, Naqvi TZ, Dang N. Percutaneous stent-mounted valve for treatment of aortic or pulmonary valve disease. Catheter Cardiovasc Interv 2004;63:89—93.
[8] Bonhoeffer P, Boudjemline Y, Saliba Z, et al. Percutaneous replacement of pulmonary valve in a right-ventricle to pulmonary-artery prosthetic conduit with valve dysfunction. Lancet 2000;356:1403—5.
[9] Cribier A, Eltchaninoff H, Bash A, et al. Percutaneous transcatheter implantation of an aortic valve prosthesis for calcific aortic stenosis: first human case description. Circulation 2002;106:3006—8.
[10] Webb JG, Altwegg L, Masson JB, Al Bugami S, Al Ali A, Boone RA. A new transcatheter aortic valve and percutaneous valve delivery system. J Am Coll Cardiol 2009;53:1855—8.
[11] Nietlispach F, Wijesinghe N, Wood D, Carere RG, Webb JG. Current balloon-expandable transcatheter heart valve and delivery systems. Catheter Cardiovasc Interv 2010;75:295—300.
[12] Grube E, Laborde JC, Zickmann B, et al. First report on a human percutaneous transluminal implantation of a self-expanding valve prosthesis for interventional treatment of aortic valve stenosis. Catheter Cardiovasc Interv 2005;66:465—9.
[13] Moat NE, Ludman P, de Belder MA, et al. Long-term outcomes after transcatheter aortic valve implantation in high-risk patients with severe aortic stenosis: the UK TAVI (United Kingdom Transcatheter Aortic Valve Implantation) Registry. J Am Coll Cardiol 2011;58:2130—8.
[14] Eltchaninoff H, Prat A, Gilard M, et al. Transcatheter aortic valve implantation: early results of the FRANCE (FRench Aortic National CoreValve and Edwards) registry. Eur Heart J 2011;32:191—7.
[15] Geisbusch S, Bleiziffer S, Mazzitelli D, Ruge H, Bauernschmitt R, Lange R. Incidence and management of CoreValve dislocation during transcatheter aortic valve implantation. Circ Cardiovasc Interv 2010;3:531—6.
[16] Falk V, Schwammenthal EE, Kempfert J, et al. New anatomically oriented transapical aortic valve implantation. Ann Thorac Surg 2009;87:925—6.

[17] Treede H, Tubler T, Reichenspurner H, et al. Six-month results of a repositionable and retrievable pericardial valve for transcatheter aortic valve replacement: the Direct Flow Medical aortic valve. J Thorac Cardiovasc Surg 2010;140: 897—903.
[18] Schofer J, Schluter M, Treede H, et al. Retrograde transarterial implantation of a nonmetallic aortic valve prosthesis in high-surgical-risk patients with severe aortic stenosis: a first-in-man feasibility and safety study. Circ Cardiovasc Interv 2008;1:126—33.
[19] Cribier A, Eltchaninoff H, Tron C, et al. Early experience with percutaneous transcatheter implantation of heart valve prosthesis for the treatment of end-stage inoperable patients with calcific aortic stenosis. J Am Coll Cardiol 2004;43: 698—703.
[20] Webb JG, Chandavimol M, Thompson CR, et al. Percutaneous aortic valve implantation retrograde from the femoral artery. Circulation 2006;113:842—50.
[21] Grube E, Laborde JC, Gerckens U, et al. Percutaneous implantation of the CoreValve self-expanding valve prosthesis in high-risk patients with aortic valve disease: the Siegburg first-in-man study. Circulation 2006;114:1616—24.
[22] Toggweiler S, Gurvitch R, Leipsic J, et al. Percutaneous aortic valve replacement vascular outcomes with a fully percutaneous procedure. J Am Coll Cardiol 2012;59:113—8.
[23] Walther T, Falk V, Borger MA, et al. Minimally invasive transapical beating heart aortic valve implantation — proof of concept. Eur J Cardiothorac Surg 2007;31:9—15.
[24] Ye J, Cheung A, Lichtenstein SV, et al. Transapical aortic valve implantation in humans. J Thorac Cardiovasc Surg 2006;131:1194—6.
[25] Lange R, Schreiber C, Gotz W, et al. First successful transapical aortic valve implantation with the CoreValve Revalving system: a case report. Heart Surg Forum 2007;10:E478—9.
[26] Petronio AS, De Carlo M, Bedogni F, et al. Safety and efficacy of the subclavian approach for transcatheter aortic valve implantation with the CoreValve revalving system. Circ Cardiovasc Interv 2010;3:359—66.
[27] Modine T, Obadia JF, Choukroun E, et al. Transcutaneous aortic valve implantation using the axillary/subclavian access: feasibility and early clinical outcomes. J Thorac Cardiovasc Surg 2011;141:487—91.
[28] Bapat V, Khawaja MZ, Attia R, et al. Transaortic transcatheter aortic valve implantation using Edwards Sapien valve: a novel approach. Catheter Cardiovasc Interv 2011, doi:10.1002/ccd.23276. Epub ahead of print.
[29] Etienne PY, Papadatos S, El Khoury E, Pieters D, Price J, Glineur D. Transaortic transcatheter aortic valve implantation with the Edwards SAPIEN valve: feasibility, technical considerations, and clinical advantages. Ann Thorac Surg 2011;92:746—8.