Anatomy of the Aortic Valvar Complex and Its Implications for Transcatheter Implantation of the Aortic Valve

Nicoló Piazza, MD; Peter de Jaegere, MD, PhD; Carl Schultz, MD; Anton E. Becker, MD, PhD; Patrick W. Serruys, MD, PhD; Robert H. Anderson, MD, FRCPath

Abstract—The books and articles devoted to the anatomy of the aortic valvar complex are numerous. Until now, however, little consideration has been given to understanding the anatomy with percutaneous valvar replacement in mind. It is axiomatic that knowledge of the anatomy of the valve is fundamental in understanding key principles involved in valvar replacement. Such an appreciation of the anatomy helps better understand the optimal positioning for the prosthetic valve within the root of the aorta with respect to the coronary arteries, mitral valve, and the conduction system and may circumvent complications that can arise during its implantation. In this review, therefore, we describe the anatomy of the trifoliate aortic valvar complex and its implications for percutaneous valvar replacement. **(*Circ Cardiovasc Intervent.* 2008;1:74-81.)**

Key Words: anatomy ■ aorta ■ catheters ■ stenosis ■ valves

The realization that it is now possible to replace the aortic valve percutaneously has created awareness among cardiologists of the importance in the anatomy of the aortic valvar complex. The earliest documented interest in the anatomy of the aortic valvar complex stems from the Renaissance, with the description and drawings by Leonardo da Vinci (1513). The books and articles devoted to this topic are numerous.[1-4]. Until now, however, little consideration has been given to understanding the anatomy with percutaneous valvar replacement in mind. There are a number of designs for valves that can be inserted percutaneously in aortic position, but thus far most experience has been gained using the Edwards SAPIEN prosthetic heart valve or the CoreValve ReValving System.[5-7] Implantation is achieved by either a transfemoral or transapical approach. Generally speaking, the prosthesis is positioned within the aortic root and, once deployed, crushes the leaflets of the native valve against the wall. It is axiomatic that knowledge of the anatomy of the valve is fundamental in understanding key principles involved in valvar replacement. Such an appreciation of the anatomy helps better to understand the optimal positioning for the prosthetic valve within the aortic root with respect to the coronary arteries, mitral valve, and the conduction system, and may circumvent complications that can arise during its implantation. In addition, the need for accurate knowledge of the aortic valvar complex is imperative, not only as percutaneous therapies of the aortic valve become clinically established but also in the new design and refinements of current valvar technology. In this review, therefore, we describe the anatomy of the trifoliate aortic valvar complex and its implications for percutaneous valvar replacement. The presence of an aortic valve with 2 leaflets is currently considered a contraindication to transcatheter implantation of the aortic valve. This topic, therefore, although of unequivocal importance, has been omitted, in the interest of brevity, from our discussion of the anatomy of the aortic valvar complex.

Description of the Type of Transcatheter Aortic Valve Bioprostheses

Before we embark on a detailed discussion of the anatomy of the aortic valvar complex and its importance with regard to transcatheter valve therapy, a description of the 2 most commonly implanted prostheses is provided.

The Edwards SAPIEN prosthesis consists of a balloon-expandable, cylindrical frame composed of stainless steel to which is attached a trifoliate, equine pericardium heart valve.[5,7] A fabric skirt is sewn to the frame and functions to mitigate paravalvular aortic regurgitation. The anchoring of the prosthesis and function of the valve are both intra-annular. This valve is currently available in 2 sizes (Figure 1).

The CoreValve ReValving System consists of a self-expandable, trilevel frame composed of nitinol to which is attached a trifoliate, porcine pericardium heart valve.[6] The upper third of the frame (ie, outflow portion) exerts low radial force and sits within the ascending aorta and functions to orient the prosthesis in the direction of the aortic root and blood flow. The middle third of the frame is constrained to

From the Department of Cardiology, Thoraxcenter, Erasmus Medical Center, Rotterdam, the Netherlands (N.P., P.d.J., C.S., P.W.S.); Department of Pathology, University of Amsterdam, Academic Medical Center, Amsterdam, the Netherlands (A.E.B.); and Cardiac Unit, Institute of Child Health, University College, London, UK (R.H.A.).

Correspondence to Patrick W. Serruys, MD, PhD, Department of Cardiology, Erasmus Medical Center, Thoraxcenter, Ba583a, 's-Gravendijkwal 230, 3015 CE Rotterdam, The Netherlands. E-mail p.w.j.c.serruys@erasmusmc.nl

© 2008 American Heart Association, Inc.

Circ Cardiovasc Intervent **is available at http://circinterventions.ahajournals.org** **DOI: 10.1161/CIRCINTERVENTIONS.108.780858**

Edwards v. Aortic Innovations U.S. Patent 11,497,634
Edwards Ex. 1047

Downloaded from http://ahajournals.org by on September 14, 2021

	Size (width x height)	For annulus diameter	Height of skirt
Edward SAPIEN™	23 x 14.5 mm	18-22 mm	10.1 and 7.74 mm
	26 x 16 mm	21-25 mm	11.4 and 8.67 mm
CoreValve Revalving™	26 x 53 mm	20-23 mm	12 mm
	29 x 55 mm	23-27 mm	12 mm

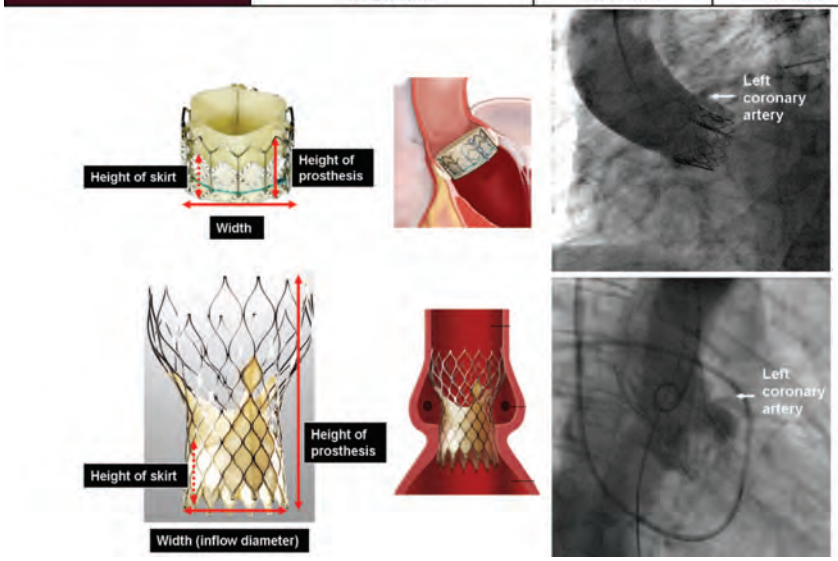

Figure 1. Description of the Edwards SAPIEN prosthesis and the CoreValve ReValving System prosthesis. Various dimensions of the valve prostheses are summarized in the table. The top and bottom rows of figures depict the Edwards SAPIEN prosthesis and the CoreValve ReValving System prosthesis, respectively. Drawings demonstrate the approximate "seating" of the prostheses within the aortic root, and corresponding cine angiograms are provided.

avoid jailing of the coronary arteries. In addition, this portion of the prosthesis hosts the valve leaflets and has high hoop force to resist deformation and thus maintain normal leaflet function. The lower third of the frame (ie, inflow portion) sits within the left ventricular outflow tract/annulus of the native aortic valve and exerts high radial force. A skirt of pericardium borders the lower portion of the valve and, in tandem with the inflow portion of the valve, acts to create a seal and prevent paravalvular aortic regurgitation. Although the prosthesis is anchored within the annulus, its function is supra-annular. This valve is currently available in 2 sizes (Figure 1).

Aortic Root

The aortic root is the direct continuation of the left ventricular outflow tract. It is located to the right and posterior, relative to the subpulmonary infundibulum, with its posterior margin wedged between the orifice of the mitral valve and the muscular ventricular septum (Figure 2). It extends from the basal attachment of the aortic valvar leaflets within the left ventricle to their peripheral attachment at the level of the sinutubular junction.[8] Approximately two thirds of the circumference of the lower part of the aortic root is connected to the muscular ventricular septum, with the remaining one third in fibrous continuity with the aortic leaflet of the mitral valve. Its components are the sinuses of Valsalva, the fibrous interleaflet triangles, and the valvar leaflets themselves. The leaflets have a core of fibrous tissue, with endothelial linings on their arterial and ventricular aspects. Their origin from the supporting left ventricular structures, where the ventricular components give rise to the fibroelastic walls of the aortic valvar sinuses, marks the anatomic ventriculoarterial junction. Significantly, in those areas where the leaflets arise from the ventricular myocardium, their basal attachments are well below the level of the anatomic ventriculoarterial junction (Figure 3).

"Rings" Within the Aortic Root

When defined literally, an "annulus" is no more than a little ring. There are several such rings to be found within the aortic

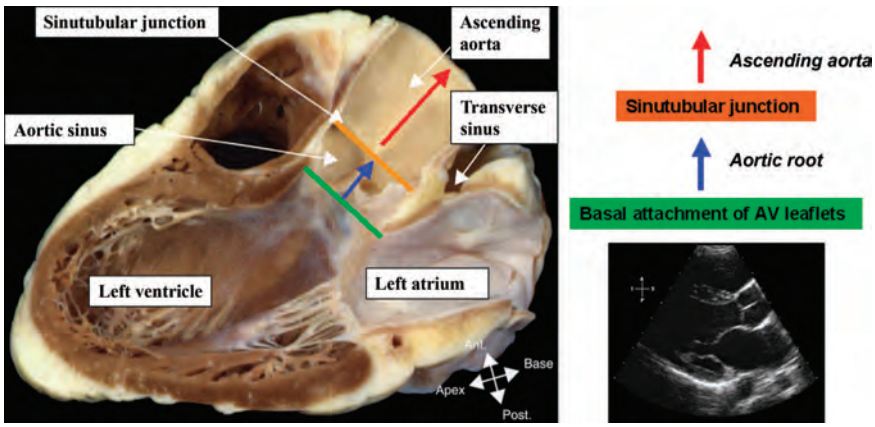

Figure 2. The long-axis view of the left ventricle corresponding with the echocardiographic parasternal long-axis view, demonstrating the extent of the aortic root. AV indicates aortic valve.

Downloaded from http://ahajournals.org by on September 14, 2021

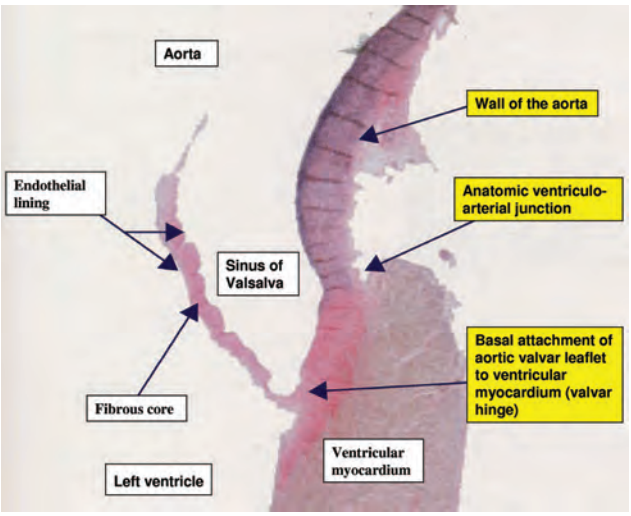

Figure 3. Histology of the aortic valvar complex shows the anatomic ventriculoarterial junction. Also note that the basal attachment of the aortic valvar leaflets to the ventricular myocardium is proximal relative to the anatomic junction.

root, not all corresponding to discrete anatomic structures. Furthermore, the annulus described by surgeons is usually the semilunar crown-like structure demarcated by the hinges of the leaflets. Thus, the aortic root contains at least 3 circular rings and 1 crown-like ring.[8] The valvar leaflets, of course, are attached throughout the length of the root (Figure 2). Seen in 3 dimensions, therefore, the leaflets take the form of a 3-pronged coronet, with the hinges from the supporting ventricular structures forming the crown-like ring (Figure 4). The base of the crown is a virtual ring, formed by joining the

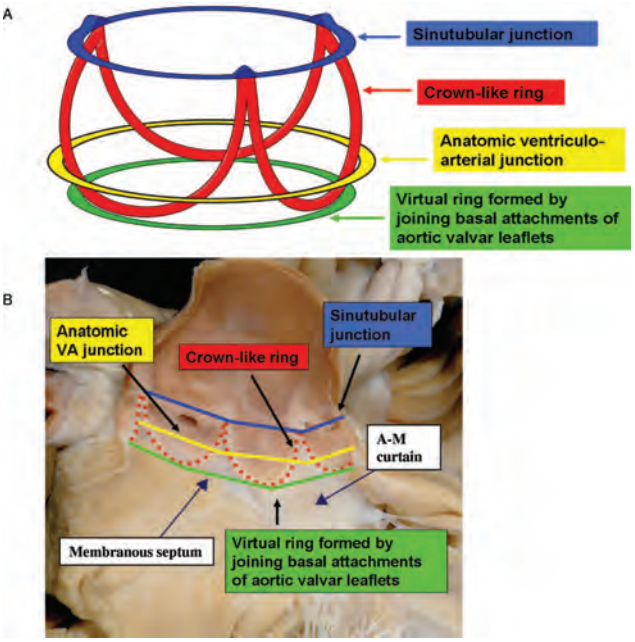

Figure 4. A, Three-dimensional arrangement of the aortic root, which contains 3 circular "rings," but with the leaflets suspended within the root in crown-like fashion. B, The leaflets have been removed from this specimen of the aortic root, showing the location of the 3 rings relative to the crown-like hinges of the leaflets. VA indicates ventriculoarterial; A-M, aortic-mitral.

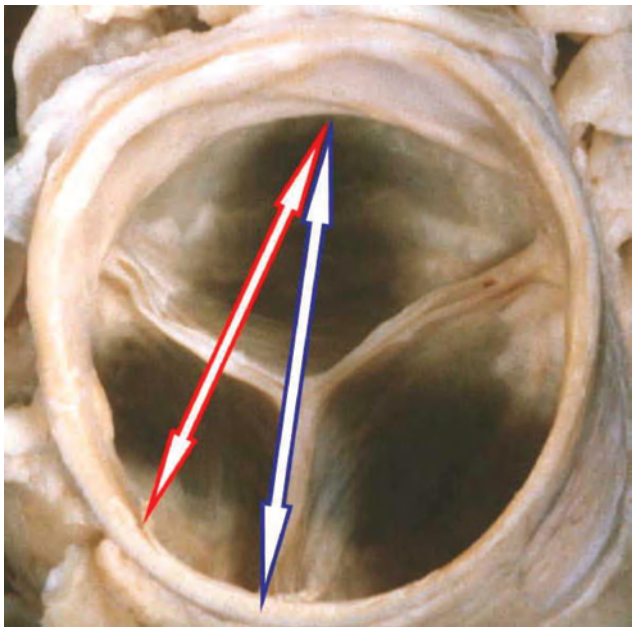

Figure 5. This basal short-axis view shows the closed aortic valve. The arrows demonstrate the potential hazard of 2-dimensional imaging techniques (echocardiography, contrast aortography) for measuring the "aortic valve annulus." Measurements made using the basal attachment of the leaflets do not transect the full diameter of the outflow tract but instead a tangent cut across the root.

basal attachment points of the leaflets within the left ventricle. This plane represents the inlet from the left ventricular outflow tract into the aortic root. The top of the crown is a true ring, the sinutubular junction, demarcated by the sinus ridge and the related sites of attachment of the peripheral zones of apposition between the aortic valve leaflets. It forms the outlet of the aortic root into the ascending aorta. The semilunar hinges then cross another true ring, the anatomic ventriculoarterial junction, as shown in Figure 3. The overall arrangement is well seen when the aortic root is opened subsequent to removal of the valvar leaflets (Figure 4B). This preparation also shows that the leaflets arise from ventricular muscle only over part of their circumference. The larger part of the noncoronary leaflet of the valve, along with part of the left coronary leaflet, is in fibrous continuity with the aortic or anterior leaflet of the mitral valve, with the ends of this area of fibrous continuity being thickened to form the so-called fibrous trigones. It is these trigones that anchor the aortic-mitral valvar unit to the roof of the left ventricle. It will be evident from our description that, although it is traditional to describe an annulus for the aortic valve, the understanding of this term will vary markedly depending on which of the various rings within the root is selected to represent the annulus. In our opinion, continued use of this term will serve only to perpetuate disagreement, particularly for those wishing to replace the valve percutaneously.[9-14] We prefer to describe the various components of the valve and describe the variable diameter of the root at its different parts rather than nominating any single component as the annulus. The essence of the anatomic arrangement, nonetheless, is that the leaflets are supported in crown-like fashion within the cylindrical root.

Downloaded from http://ahajournals.org by on September 14, 2021

The normal aortic root has a consistent shape with varying size, and studies have demonstrated a definable mathematical relationship between root diameter and clinically measurable leaflet dimensions.[15] In general, measurements of the human aortic root have revealed that the diameter at the level of the sinutubular junction exceeds that at the level of the virtual ring formed by joining together the basal attachments of the leaflets by up to one fifth.[15,16] When studying fixed human hearts, Reid[16] calculated a ratio of the diameters of the inlet to the outlet of 1 to 1.34. The diameters of inlet and outlet, when expressed as a percentage of the largest diameter at the level of the expanded aortic sinuses, have been calculated as 97% and 81%, respectively. It is for these reasons that the aortic root is sometimes described as a truncated cone.[16] It is also the case that the valvar complex is a dynamic structure, with the geometric parameters changing continuously during the phases of the cardiac cycle and in relation to changes in pressure within the aortic root.[17] From diastole to systole, the change in the diameter at the level of the outlet and at the base of the valve has been noted to increase by 12% and decrease by 16%, respectively.[18,19]

Echocardiographic studies have demonstrated that at the level of the sinutubular junction, the aortic root is significantly larger (ie, defined as 2 standard deviations above the mean normal values) in patients with aortic stenosis than in normal patients.[20] However, there are purportedly no differences in the diameters of the annulus or sinuses of Valsalva between patients with and without aortic stenosis. Furthermore, approximately one fourth of patients with aortic stenosis are reported to have sinutubular aortic root diameters greater than normal, and large diameters at the sinus or "annular" level occur in <10% of cases. There is a paucity of literature clearly describing the dimensions of the aortic root in patients with aortic stenosis compared with patients without aortic stenosis. From a bioengineering point of view, the modeling of valve prostheses may require consideration of these changes in aortic root geometry.

For purposes of design of aortic valvar prostheses, geometric principles based on ratios of "normal" aortic root dimensions need to be respected for their normal function and durability.[19] These design principles may be compromised during the selection (ie, patient-prosthetic mismatch) or implantation process and lead to nonstructural dysfunction of the prosthetic valve.[21] For instance, an oversized prosthetic valve relative to the dimensions of the patient's aortic root can result in redundancy of leaflet tissue, thus creating folds. These folds will generate regions of compressive and tensile stresses and may alter the function or reduce the durability of the valve.[19] On the contrary, if the valvar prosthesis is too small for the patient, the inserted prosthesis will prove to be stenotic. Accurate measurement of the components of the aortic root and selection of the appropriate sized prothesis may circumvent these potential issues. On occasion, after percutaneous implantation of the prosthesis, repeat balloon dilation of the frame of the prosthesis is performed to reduce the amount of paravalvar leakage. Until now, significant adverse effects associated with such practice have not been observed, although repeat dilation may lead to alterations in the well-defined geometry of the frame of the prosthesis and affect the long-term function of the leaflets.

Anatomic Versus Hemodynamic Ventriculoarterial Junction

As we have shown (Figures 4 and 5), there is a marked discrepancy between the circular anatomic junction and the semilunar hemodynamic junction.[8] The hemodynamic junction separates the root into those compartments exposed to aortic as opposed to left ventricular pressures. By virtue of the semilunar attachments of the leaflets, portions of the fibrous aortic root are exposed to ventricular pressures, these being the superior portions of the interleaflet triangles, whereas portions of the left ventricle are exposed to aortic pressures, these being the most basal portions within the sinus of Valsalva. Of note, when necropsied hearts are examined subsequent to surgical replacement of the aortic valve, the circular sewing ring is usually found to be located at the level of the anatomic ventriculoarterial junction.[16]

Aortic Valvar Leaflets

The normal aortic valve is trifoliate, and their semilunar attachments have already been described. Proper functioning of the valve depends on the proper relationship between the leaflets within the aortic root. Not only do variations exist among individuals in the dimensions of the root, but in the same individual, marked variations can exist in all aspects of the dimensions of the individual leaflets, including the height, width, surface area, and volume of each of the supporting sinuses of Valsalva. A study of 200 normal hearts revealed that the average width, measured between the peripheral zones of attachment along the sinus ridge, for the right, the noncoronary, and the left coronary leaflets was 25.9, 25.5, and 25.0 mm, respectively.[22] Important variations were found when the absolute width of each leaflet was expressed as a percentage of the width of adjacent leaflets. Comparisons of the right coronary and left coronary leaflets, noncoronary and right coronary leaflets, and left coronary and noncoronary leaflets varied between 76% and 159%, 62% and 162%, and 62% and 150%, respectively. Comparable variations were observed for the height. The average height, measured from the base of the center of the leaflet to its free edge, for the right coronary, noncoronary, and left coronary cusps was 14.1, 14.1, and 14.2 mm, respectively. When the height of each individual leaflet was expressed as a percentage of its width, the right coronary, noncoronary, and left coronary leaflets varied between 39% and 82%, 34% and 87%, and 34% and 113%, respectively. Of the 200 hearts studied, only 5 hearts were found to have leaflets of equal size. In the same study, the evaluation of 16 hearts with aortic stenosis revealed similar findings with respect to the width, height, and surface area of the leaflets. Other studies have also noted impressive interindividual and intraindividual variations in geometry of the leaflets of the valve.[23,24]

Such individual variations in geometry need to be taken into account during measurement of the aortic root aimed at sizing the prosthesis. Such inequalities in the size of the leaflets can contribute to inaccurate measurements of the aortic annulus when the definition is based on the distance

Downloaded from http://ahajournals.org by on September 14, 2021

between 2 valvar hinge points on a 2-dimensional image (Figure 5). Variations in size (ie, height and width) of the leaflets and the location of the coronary arteries also require special consideration.

Location of the Coronary Arteries

In the majority of cases, the orifices of the coronary arteries arise within the 2 anterior sinuses of Valsalva, usually positioned just below the sinutubular junction.[16,25,26] It is not unusual, however, for the arteries to be positioned superior relative to the sinutubular junction. In a study of 51 normal postmortem hearts, the mean distance measured from the orifice of the left coronary artery to the basal attachment of the corresponding leaflet was 12.6±2.61 mm, and for the right coronary artery it was 13.2±2.64 mm.[27]

In a recent study examining the aortic root with multislice computed tomography in 169 patients (ie, 150 patients with no or mild aortic stenosis and 19 patients with moderate or severe aortic stenosis), the mean distance from the level of the basal attachment point of the aortic valvar leaflets to the ostium of the left coronary and right coronary artery was 14.4±2.9 mm and 17.2±3.3 mm, respectively.[28] There were no significant differences in the mean distances between patients with or without severe aortic stenosis.

Knowledge of the location of the coronary arteries, of course, is essential for appropriate percutaneous replacement of the aortic valve. The valvar prostheses are designed such that a skirt of fabric or tissue is sewn within the stent or frame to help to create a seal and prevent paravalvar leakage. In situations in which the coronary arteries take their origin low within the sinus of Valsalva and/or the prosthesis is placed too high, the skirt may obstruct their orifices and thus impede coronary arterial flow. Furthermore, when the valve is deployed, it crushes the leaflets of the native valve against the aortic wall. The combination of a relatively low-lying coronary artery ostium and a large native aortic valvar leaflet therefore can obstruct the flow into the coronary arteries during valvar deployment.[29] Thus, measurement of the height of the takeoff of the coronary arteries is important before valvar implantation. The width of the sinuses of Valsalva also needs to meet minimum requirements if the valvar prosthesis is to be properly accommodated without impinging on the orifices of the coronary arteries.

Relationship Between the Left Ventricular Outflow Tract and the Aortic Root

The left ventricular outflow tract is composed of a muscular component (ie, the muscular ventricular septum) and fibrous component (ie, the area of fibrous continuity between the leaflets of the aortic and mitral valves), with the former being more extensive. The orientation of the outflow tract is known to change with aging. This change in geometry was examined in a series of normal human hearts, comparing findings in individuals aged <20 years with those aged >60 years.[30]

Several aspects are of note. First, examination of the angle between the outlet and apical trabecular parts of the ventricular septum showed significant differences. In hearts from individuals aged >60 years, the angle varied between 90 and 120 degrees. In those from individuals aged ≤20 years, the angle varied between 135 and 180 degrees. In these younger patients, the left ventricular outflow tract represented a more direct and straight extension into the aortic root. This would also seem to explain the additional observation that in all of the elderly hearts, the majority of the circumference of the aortic inlet projected to the right of a line drawn through the outlet part of the muscular ventricular septum. In contrast, in the younger individuals, the majority of the circumference of the inlet projected either to the right or to the left. Thus, we can infer that, in elderly patients, the left ventricular outflow tract may not extend in straight fashion into the aortic root but rather may show a rightward "dog" leg.

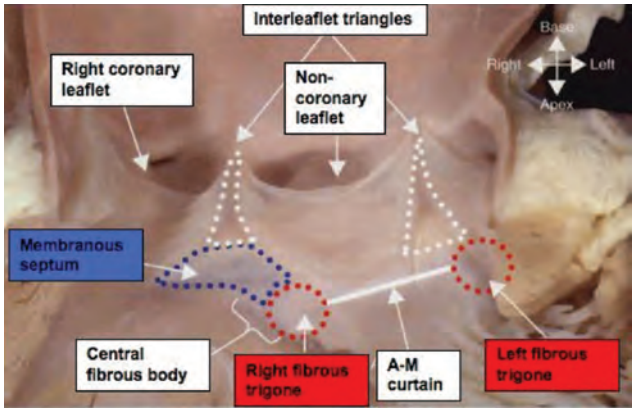

Figure 6. This image of the aortic root opened from the left ventricle shows the fibrous continuities between the interleaflet triangles, the fibrous trigones, and the membranous septum. A-M indicates aortic-mitral.

The presence of a subaortic septal bulge and an extension of this producing asymmetrical septal hypertrophy may create an obstacle to proper seating of the aortic prosthesis within the left ventricular outflow tract. The presence of a significant subaortic bulge or a hypertrophied septum has been considered by some to be a relative contraindication to the implantation of a certain type of aortic prostheses.

Interleaflet Triangles and Their Relationship to the Mitral Valve and Membranous Septum

As a result of the semilunar attachment of the aortic valvar leaflets, there are 3 triangular extensions of the left ventricular outflow tract that reach to the level of the sinutubular junction.[31] These triangles, however, are formed not of ventricular myocardium but of the thinned fibrous walls of the aorta between the expanded sinuses of Valsalva. Their most apical regions represent areas of potential communication with the pericardial space or, in the case of the triangle between the right and left coronary aortic leaflets, with the plane of tissue interposed between the aorta and anteriorly located sleeve-like subpulmonary infundibulum. The 2 interleaflet triangles bordering the noncoronary leaflet are also in fibrous continuity with the fibrous trigones, the mitral valve, and the membranous septum (Figure 6).

Fibrous Trigones

The aortic valve is the cardiac centerpiece. Relative to the aorta, the mitral valve is located posterior and to the left, the tricuspid valve is located inferiorly and to the right, and both

Downloaded from http://ahajournals.org by on September 14, 2021

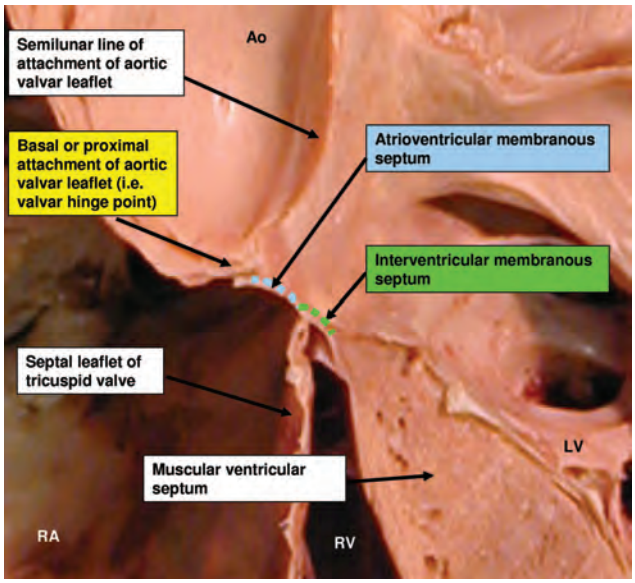

Figure 7. This close-up view of the membranous septum demonstrates its separation into atrioventricular and interventricular components by the septal leaflet of the tricuspid valve. Note the close proximity of the subaortic outflow region, the membranous septum, and the right atrium, where the atrioventricular node is located. Ao indicates aorta; RA, right atrium; RV, right ventricle; and LV, left ventricle.

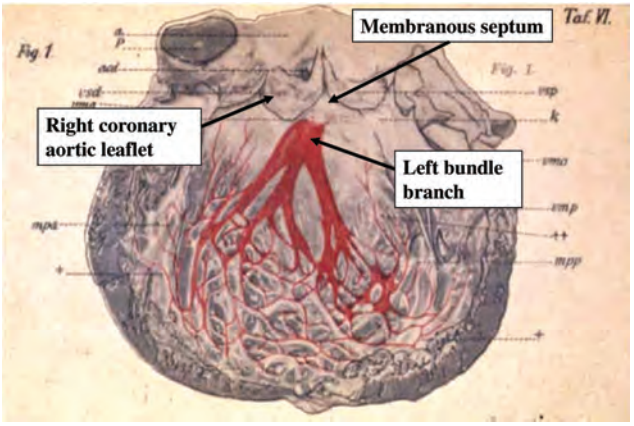

Figure 8. This original monograph from Tawara (1906)[32] shows the left bundle branch exiting below the base of the interleaflet triangle separating the noncoronary and right coronary leaflets of the aortic valve and fanning out to descend along the septal surface of the left ventricular myocardium.

valves abut on the posteroinferior margins of the aortic root, albeit with the atrioventricular separating structures interposing between the root and the tricuspid valve. The mural (or posterior) annulus of the mitral valve is C-shaped, whereas the aortic (anterior) part of the annulus is relatively straight. The ends of the area of fibrous continuity, as already emphasized, are thickened to form the left and right fibrous trigones (Figure 6). The interleaflet triangle between the noncoronary and left coronary leaflet is part of the area of fibrous continuity because the aortic-mitral curtain seen from within the left ventricular outflow tract represents the equivalent of the anterior mitral valvar annulus. Inadvertent placement of the aortic valvar prosthesis too low within the left ventricular outflow tract may impinge on this leaflet of the mitral valve and impair its function. The interleaflet triangle located between the right coronary and noncoronary aortic leaflets is confluent with the membranous septum. Together, the membranous septum and the right fibrous trigone form the central fibrous body of the heart. This is the area within the heart where the membranous septum, the atrioventricular valves, and the aortic valve join in fibrous continuity.

The hinge of the septal leaflet of the tricuspid valve separates the membranous septum into its atrioventricular and interventricular components (Figure 7). This relationship is key to understanding the relationship between the aortic valve and the conduction system.

Relationship Between the Aortic Valve and the Conduction System

Within the right atrium, the atrioventricular node is located within the triangle of Koch. This important triangle is demarcated by the tendon of Todaro, the attachment of the septal leaflet of the tricuspid valve, and the orifice of the coronary sinus. The apex of this triangle is occupied by the atrioventricular component of the membranous septum. The atrioventricular node is located just inferior to the apex of the triangle adjacent to the membranous septum, and therefore the atrioventricular node is in fact in close proximity to the subaortic region and membranous septum of the left ventricular outflow tract. It is this relationship that allows us to understand why pathologies involving the aortic valve can lead to complete heart block or intraventricular conduction abnormalities. The atrioventricular node continues as the bundle of His, piercing the membranous septum and penetrating to the left through the central fibrous body. On the left side, the conduction axis exits immediately beneath the membranous septum and runs superficially along the crest of the ventricular septum, giving rise to the fascicles of the left bundle branch. When viewed from the left, the bundle is intimately related to the base of the interleaflet triangle separating the noncoronary and right coronary leaflets of the aortic valve, with the superior part of the bundle intimately related to the right coronary aortic leaflet, as shown exquisitely in the reconstruction made by Tawara in his stellar monograph (Figure 8).[32] This has important implications with the potential to induce abnormalities of conduction after percutaneous insertion of a new aortic valve.

Location of Percutaneously Inserted Valvar Prostheses

Recommendations on the optimal positioning of the prostheses within the aortic root vary according to the design of the valve and have changed over time with increasing operator experience. Depending on the design, the prosthesis is positioned with its ventricular end ≈2 to 6 mm below the basal attachment of the aortic valvar leaflets. If the left bundle branch exits within 2 to 3 mm below these points, the potential exists for the prosthesis to overlap and crush the conduction tissues. Indeed, in a recent report from our center of 40 patients undergoing transcatheter implantation with the CoreValve ReValving System, 40% of patients developed new-onset left bundle branch block.[33] Furthermore, the mean

Downloaded from http://ahajournals.org by on September 14, 2021

distance from the proximal (or ventricular end) of the frame of the valve prosthesis to the lower edge of the noncoronary cusp was significantly greater in patients with new-onset left bundle branch block than in patients without new-onset left bundle branch block (10.3 mm [±2.7] versus 5.5 mm [±3.4], respectively). It was suggested that a more superior positioning of the valve prosthesis within the left ventricular outflow tract may prevent these conduction problems.

What Imaging of the Aortic Valvar Complex Is Required Before Transcatheter Valvar Implantation?

A detailed discussion of the requirements for imaging before transcatheter implantation of the aortic valve is beyond the scope of this review. The major utility of imaging before the procedure lies in the measurement of the dimensions of the aortic valvar complex. The goals, therefore, are to select the appropriate size of the valve prosthesis and avoid the complications discussed previously in this review.

The following dimensions should be measured before implantation: (1) diameter of the ascending aorta; (2) diameter of the sinutubular junction; (3) diameter of the aortic root at midsinusal level; (4) diameter of the aortic root at the level of the basal attachment of the aortic valvar leaflets; (5) diameter of the left ventricular outflow tract; (6) the height and width of the sinus of Valsalva; (7) the height of takeoff of the coronary artery ostia with respect to the level of the basal attachment of the aortic valvar leaflets; and (8) thickness of the ventricular septum.

From the clinical standpoint, the diameters of the root measured by echocardiography, contrast aortography, multislice computed tomography, or magnetic resonance imaging can vary markedly. The measurements of the aortic root obtained by 2 of the most frequently used imaging modalities, echocardiography and contrast angiography, are limited by their 2-dimensional nature.

As shown in Figure 3, when seen in long axis, the diameter of the root varies significantly along its short length. The root is much wider at the midpoint of the sinuses than at either the sinutubular junction or the basal attachment of the leaflets. These differences become relevant when it is remembered that the attachment of the leaflets extends through all of these levels. It should also be noted that measurements taken by echocardiographers from the basal attachment of 1 leaflet to the comparable point of an adjacent leaflet in the parasternal long-axis view do not transect the full diameter of the outflow tract but instead cut a tangent across the root (Figure 5). In terms of percutaneous replacement, irrespective of the type of valve inserted, it is this echocardiographic measurement that has played a crucial role in the selection of the size of prosthesis to be inserted. Whether or not this is correct is open for debate, although the clinical outcomes thus far have been very good.

In contrast, newer modalities such as multislice computed tomography, 3-dimensional echocardiography, and magnetic resonance imaging are emerging as attractive modalities for imaging because they permit precise measurement of the aortic root at any desired level or plane, and thus they may provide more accurate measurements of the true dimensions of the different components of the aortic valvar complex. Of note, the diameter from the basal attachment of one leaflet to the basal attachment of an adjacent leaflet can vary depending on the view or projection used for measurement.

Indeed, in a study of 150 patients with no or mild aortic stenosis and 19 patients with moderate or severe aortic stenosis undergoing evaluation of the aortic root with multislice computed tomography, the mean distance from the basal attachment of one leaflet to the basal attachment of an adjacent leaflet was 26.3±2.8 and 23.5±2.7 mm on the coronal and sagittal views, respectively, indicating an oval shape of the aortic root at this level.[28] There were no significant differences in the diameters of the aortic annulus or sinus of Valsalva between patients with or without severe aortic stenosis.

The "gold standard" imaging modality to employ before transcatheter valvar implantation is currently under debate, and studies examining this issue are lacking. Nonetheless, it is recommended to perform, at a minimum, transthoracic echocardiography and contrast aortography. Although multislice computed tomography is not absolutely indicated, there is a growing community advocating its routine implementation, obviously taking into consideration renal insufficiency and contrast media requirements.

Conclusion

Anatomic knowledge of the aortic valvar complex can be fundamental in understanding the key principles of its percutaneous replacement. First, appreciating the exact origin of the coronary arteries and the location of the left bundle branch in relation to the positioning of the prosthesis may help to minimize the risks of coronary ischemia and abnormalities of conduction that can occur during valvar implantation. Second, knowledge of the limitations of measuring the so-called annulus by echocardiography, angiography, or multislice computed tomography may decrease the possibility of patient-prosthesis mismatch. Finally, an understanding of the intraindividual and interindividual variations that may exist in the anatomy of the aortic valvar complex can lead to refinements in current designs of valvar prostheses.

Acknowledgments

Some of the illustrations used for this review (Figures 2, 3, and 4) are modified from those appearing in Wilcox BR, Cook AC, Anderson RH. *Surgical Anatomy of the Heart,* 3rd ed. Cambridge, UK: Cambridge University Press: 2005. In addition, Figure 5 was modified from an original image prepared by Professor Nigel Brown and Dr. Sandra Webb from St. George's Hospital Medical University, London, United Kingdom.

Disclosures

None.

References

1. Yacoub MH, Kilner PJ, Birks EJ, Misfeld M. The aortic outflow and root: a tale of dynamism and crosstalk. *Ann Thorac Surg*. 1999;68(suppl): S37–S43.
2. Becker AE. Surgical and pathological anatomy of the aortic valve and root. *Oper Tech Cardiac Thorac Surg* 1996:1:3–14.
3. Wilcox BR, Cook AC, Anderson RH. *Surgical Anatomy of the Heart.* 3rd ed Cambridge, UK: Cambridge University Press: 2005.

Downloaded from http://ahajournals.org by on September 14, 2021

4. Anderson RH, Razavi R, Taylor AM. Cardiac anatomy revisited. *J Anat*.. 2004;205:159–177.
5. Webb JG, Pasupati S, Humphries K, Thompson C, Altwegg L, Moss R, Sinhal A, Carere RG, Munt B, Ricci D, Ye J, Cheung A, Lichtenstein SV. Percutaneous transarterial aortic valve replacement in selected high-risk patients with aortic stenosis. *Circulation*. 2007;116:755–763.
6. Grube E, Schuler G, Buellesfeld L, Gerckens U, Linke A, Wenaweser P, Sauren B, Mohr FW, Walther T, Zickmann B, Iversen S, Felderhoff T, Cartier R, Bonan R. Percutaneous aortic valve replacement for severe aortic stenosis in high-risk patients using the second- and current third-generation self-expanding CoreValve prosthesis: device success and 30-day clinical outcome. *J Am Coll Cardiol*. 2007;50:69–76.
7. Cribier A, Eltchaninoff H, Tron C, Bauer F, Agatiello C, Nercolini D, Tapiero S, Litzler PY, Bessou JP, Babaliaros V. Treatment of calcific aortic stenosis with the percutaneous heart valve: mid-term follow-up from the initial feasibility studies: the French experience. *J Am Coll Cardiol*. 2006;47:1214-1223.
8. Anderson RH. Clinical anatomy of the aortic root. *Heart*. 2000;84: 670–673.
9. Weinert L, Karp R, Vignon P, Bales A, Lang RM. Feasibility of aortic diameter measurement by multiplane transesophageal echocardiography for preoperative selection and preparation of homograft aortic valves. *J Thorac Cardiovasc Surg*. 1996;112:954–961.
10. Thubrikar MJ, Labrosse MR, Zehr KJ, Robicsek F, Gong GG, Fowler BL. Aortic root dilation may alter the dimensions of the valve leaflets. *Eur J Cardiothorac Surg*. 2005;28:850–855.
11. Antunes MJ. The aortic valve: an everlasting mystery to surgeons. *Eur J Cardiothorac Surg*. 2005;28:855–856.
12. Anderson RH, Devine WA, Ho SY, Smith A, McKay R. The myth of the aortic annulus: the anatomy of the subaortic outflow tract. *Ann Thorac Surg*. 1991;52:640–646.
13. Anderson RH. Demystifying the anatomic arrangement of the aortic valve. *Eur J Cardiothorac Surg*. 2006;29:1006–1007.
14. Anderson RH. Measurement of aortic diameter. *J Thorac Cardiovasc Surg*. 1997;114:146.
15. Kunzelman KS, Grande KJ, David TE, Cochran RP, Verrier ED. Aortic root and valve relationships: impact on surgical repair. *J Thorac Cardiovasc Surg*. 1994;107:162–170.
16. Reid K. The anatomy of the sinus of Valsalva. *Thorax*. 1970;25:79–85.
17. Swanson M, Clark RE. Dimensions and geometric relationships of the human aortic valve as a function of pressure. *Circ Res*. 1974;35:871–882.
18. Brewer RJ, Deck JD, Capati B, Nolan SP. The dynamic aortic root: its role in aortic valve function. *J Thorac Cardiovasc Surg*. 1976;72: 413–417.
19. Thubrikar MPW, Shaner TW, Nolan SP. The design of the normal aortic valve. *Am J Physiol*. 1981;10:H795–-H801.
20. Crawford MH, Roldan CA. Prevalence of aortic root dilatation and small aortic roots in valvular aortic stenosis. *Am J Cardiol*. 2001;87:1311–1313.
21. Akins CW, Miller DC, Turina MI, Kouchoukos NT, Blackstone EH, Grunkemeier GL, Takkenberg JJ, David TE, Butchart EG, Adams DH, Shahian DM, Hagl S, Mayer JE, Lytle BW; Councils of the American Association for Thoracic Surgery; Society of Thoracic Surgeons; European Association for Cardio-Thoracic Surgery; Ad Hoc Liaison Committee for Standardizing Definitions of Prosthetic Heart Valve Morbidity. Guidelines for reporting mortality and morbidity after cardiac valve interventions. *J Thorac Cardiovasc Surg*. 2008;135:732–738.
22. Vollebergh FE, Becker AE. Minor congenital variations of cusp size in tricuspid aortic valves: possible link with isolated aortic stenosis. *Br Heart J*. 1977;39:1006–1011.
23. Silver MA, Roberts WC. Detailed anatomy of the normally functioning aortic valve in hearts of normal and increased weight. *Am J Cardiol*. 1985;55:454–461.
24. Roberts WC. The structure of the aortic valve in clinically isolated aortic stenosis: an autopsy study of 162 patients over 15 years of age. *Circulation*. 1970;42:91–97.
25. Turner K, Navartnam V. The positions of coronary arterial ostia. *Clin Anat*. 1996;9:376–380.
26. Muriago M, Sheppard MN, Ho SY, Anderson RH. Location of the coronary arterial orifices in the normal heart. *Clin Anat*. 1997;10: 297–302.
27. Cavalcanti JS, de Melo MN, de Vasconcelos RS. Morphometric and topographic study of coronary ostia. *Arq Bras Cardio*. 2003;81:359–362, 355–358.
28. Tops LF, Wood DA, Delgado V, Schuijf JD, Mayo JR, Pasupati S, Lamers FPL, van der Wall EE, Schalij MJ, Webb JG, Bax JJ. Noninvasive evaluation of the aortic root with multi-slice computed tomography: implications for transcatheter aortic valve replacement. *J Am Coll Cardiol Img*. 2008;1:321–330.
29. Webb JG, Chandavimol M, Thompson CR, Ricci DR, Carere RG, Munt BI, Buller CE, Pasupati S, Lichtenstein S. Percutaneous aortic valve implantation retrograde from the femoral artery. *Circulation*. 2006;113: 842–850.
30. Middelhof CJFM, Becker AE. Ventricular septal geometry: a spectrum with clinical relevance. In: Wenink ACG, et al, eds. *The Ventricular Septum of the Heart*. The Hague, Netherlands: Martinus Nijhoff Publishers; 1981.
31. Sutton JP III, Ho SY, Anderson RH. The forgotten interleaflet triangles: a review of the surgical anatomy of the aortic valve. *Ann Thorac Surg*. 1995;59:419–427.
32. Tawara S. *Das Reizleitungssystem de Saugetierherzens: Eine Anatomich-hisologische Studie uber das Atrioventricularbundel und die Purkinjeschen Faden*. Jena, Germany: Verlag von Gustav Fischer; 1906.
33. Piazza N, Onuma Y, Jesserun E, Kint PP, Maugenest AM, Anderson RH, de Jaegere P, Serruys PW. Early and persistent intraventricular conduction abnormalities and requirements for pacemaking following percutaneous replacement of the aortic valve. *J Am Coll Cardiol Intv*. 2008;1: 310–316.

Downloaded from http://ahajournals.org by on September 14, 2021