J. BIOMED. MATER. RES. VOL. 1, PP. 179–196 (1967)

Velour Fabrics Applied to Medicine

C. WILLIAM HALL, M.D., DOMINGO LIOTTA, M.D., JOHN J. GHIDONI, M.D., and MICHAEL E. DE BAKEY, M.D., *Cora and Webb Mading Department of Surgery, Baylor University College of Medicine, Houston, Texas 77025,* and DONALD P. DRESSLER, M.D., *Department of Surgery, Tufts University School of Medicine and the New England Medical Center, Boston, Massachusetts*

Summary

Warp-knitted velour fabrics of Dacron, nylon, polypropylene, and Rayon have been backed with Silastic to form a laminate. Prior to heat curing, the composite can be molded into many shapes and has been successfully used to line the luminal side of blood pumps and vascular grafts. Prosthetic heart valves are being covered with velour in an attempt to promote a more compatible surface. Velour suture rings are being evaluated as a more efficient anchor for prosthetic heart valves. Silastic tubes with velour bonded to the outer wall have been used to inhibit infection and sinus tract formation where percutaneous lead wires and conduits are necessary. As a flat sheet, the Silastic–velour laminate has been used experimentally as an artificial skin, but the most noteworthy experimental results have been obtained in rats using a double layer of nylon velour, separated by an impermeable layer of poly(vinyl fluoride). Future application will include attempts to anchor artificial limbs via a velour interface and made functional by tendinous attachment.

Velour fabrics are warp-knitted cloths or felts resembling velvet which have been used in the clothing industry for many years. Velour cloths are knitted in such a manner that loops of the yarn extend almost perpendicularly from the fabric surface, and they may be cut or left uncut. When the uncut loops are viewed with a microscope, they resemble croquet wickets (Fig. 1).

Application of this material to line blood pumps, blood conduits, and artificial skin was initiated by a search for a better blood interfacing material for implantable blood pumps. The most perplexing problem faced by workers in the artificial heart field is the blood–

Edwards v. Aortic Innovations
U.S. Patent 11,497,634
Edwards Ex. 1107

10974636, 1967, 2, Downloaded from https://onlinelibrary.wiley.com/doi/10.1002/jbm.820010202 by Rosalie Beard , Wiley Online Library on [13/02/2023]. See the Terms and Conditions (https://onlinelibrary.wiley.com/terms-and-conditions) on Wiley Online Library for rules of use; OA articles are governed by the applicable Creative Commons License

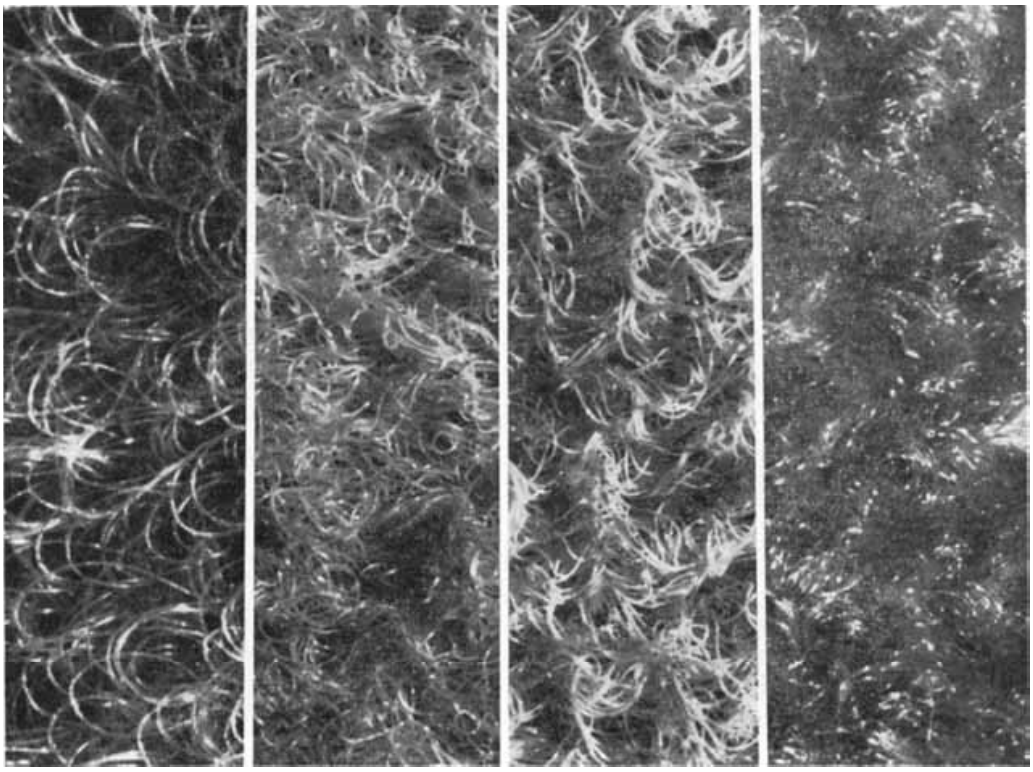

Fig. 1. Warp-knitted velour fabrics. Nylon velour (extreme left) from Webco Mills, Inc. Remainder are experimental weaves of Dacron velour furnished by Professor Thomas Edman, Philadelphia College of Textiles.

foreign material interface, which is by no means a new problem, nor is it unique to the field of artificial heart research. So important is this problem, that the National Heart Institute recently sponsored an international symposium devoted specifically to this area.[1]

Most artificial hearts that have been designed have a rubber or plastic material interfacing with the blood. A common phenomenon found on the surface in contact with the blood has been the appearance of a deposit of protein. By measuring the fall in the zeta potential,[2] observers have determined that this protein layer is adsorbed in a matter of seconds. The magnitude and sign of the zeta potential depend upon the relation between the particular plastic and liquid used in a given case.[3] This protein deposit is well known, having been observed by Lister[4] a century ago on the surface of rubber tubes used to replace arterial segments in sheep.

It is generally accepted that arterial grafts should be fashioned of a porous material in order to obtain a well-anchored, healthy inner

10974636, 1967, 2, Downloaded from https://onlinelibrary.wiley.com/doi/10.1002/jbm.820010202 by Rosalie Beard , Wiley Online Library on [13/02/2023]. See the Terms and Conditions (https://onlinelibrary.wiley.com/terms-and-conditions) on Wiley Online Library for rules of use; OA articles are governed by the applicable Creative Commons License

lining. Such material permits the organization of the internal lining and invasion by surrounding connective tissue with further vascularization. The primary base upon which the pseudointima is constructed is the fibrin deposit evident immediately after the graft has been in contact with blood. Two distinct layers have been differentiated in the inner lining of Dacron arterial grafts in human subjects examined after several years' implantation.[5,6] A fine layer of connective tissue has been found to permeate the interstices of the fabric, and between this layer and the blood a second layer was formed by fibrin and trapped cells. A true neo-intima could be demonstrated only a short distance (1.5–2 cm) from both anastomotic sites.

An impervious material used as an arterial substitute has no means to anchor the fibrin deposit and as a consequence embolization occurs. Sharp et al.[7] have sprayed the inner surface with Dacron and Teflon flock in order to anchor this fibrin lining to impervious arterial substitutes. Simmons et al.[8] have demonstrated excellent fibroplasia in nonporous, Teflon weave with a terry cloth inner surface implanted in the arterial system of mongrel dogs.

Artificial Heart Lining

The present design of artificial hearts requires the use of impervious materials. Sawyer[9] has stated that efforts to construct mechanical blood pumps of this type will be sterile until there is a plastic available which will react to blood in a manner similar to the normal vascular system. Unfortunately, such a polymer is not yet available. Gott et al.[10] have been able to obtain an antithrombogenic surface to certain plastics by bonding heparin to a graphite-coated surface using benzalkonium chloride as the intermediary. Leininger[11] has used quaternary ammonium compounds as the intermediary.

Three years ago, we began using a loose-knitted Dacron fabric liner backed with Silastic (Dow Corning, Midland, Michigan) in an attempt to anchor the fibrin film in prototype artificial hearts. During the past 18 months, we have changed in favor of nylon and Dacron velour fabrics backed with Silastic.[12] The velour surface permits a strong mechanical bond with the fibrin deposit (Fig. 2). This bond is so tenacious that chances of dissection and embolization are nil. Once this coagulum has been formed and entrapped by the velour, the blood is protected from further contact with a foreign interface.

10974636, 1967, 2, Downloaded from https://onlinelibrary.wiley.com/doi/10.1002/jbm.820010202 by Rosalie Beard , Wiley Online Library on [13/02/2023]. See the Terms and Conditions (https://onlinelibrary.wiley.com/terms-and-conditions) on Wiley Online Library for rules of use; OA articles are governed by the applicable Creative Commons License

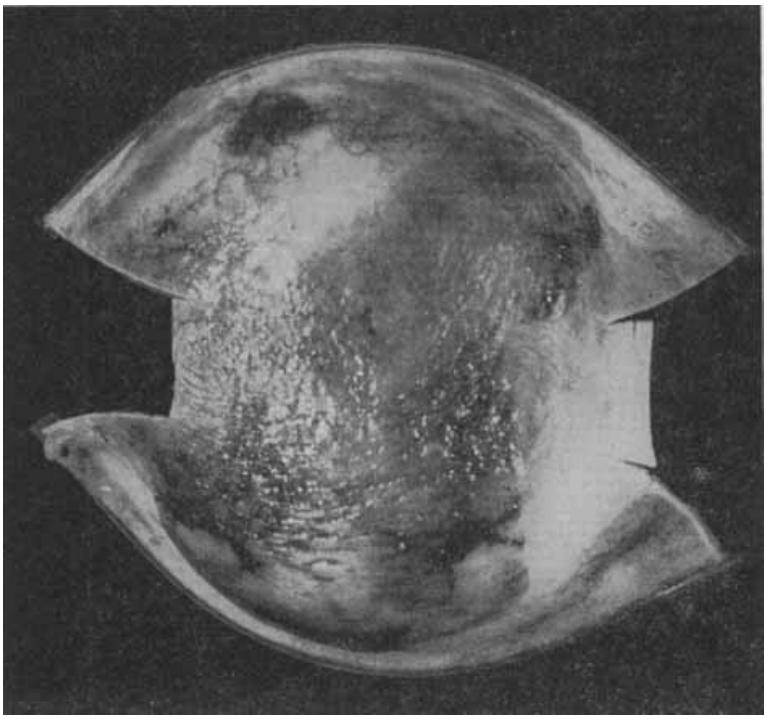

Fig. 2. Appearance of the inner surface of a velour–Silastic pump diaphragm after 11 days of continuous pumpings. Cuts were made for histological studies. The smooth fibrin coagulum is firmly held by the velour.

The laminated Silastic–velour lining has given excellent results in blood pumps, not only in solving the embolic problem but also in maintaining plasma hemoglobin levels in preoperative values.

Various velour fabrics [Dacron (Dacron velour, prepared by Prof. Thomas Edman, Philadelphia College of Textiles and Sciences, Philadelphia, Pennsylvania), nylon (nylon velour Islon #W-882, Webco Mills of New York, Inc., New York, N.Y.), Teflon (Teflon style #17918, U.S. Catheter and Inst. Corp., Glens Falls, N.Y.), polypropylene (polypropylene velour, Fiber Division of Alamo Industries, Inc., Port Jervis, N.Y.), and Rayon (Rayon velour, Foley's, Houston, Texas)] were evaluated as to their ability to form and hold a pseudo-intima when made impervious by a Silastic backing. A rapid screening procedure was used in which laminated tubes of the Silastic and the test velour fabric were fabricated and inserted in mongrel dogs as an arterial substitute (Figs. 3 and 4). Under these experimental conditions, Dacron and nylon produced the best and most constant results. In previous papers[13,14] we have reported our

10974636, 1967, 2, Downloaded from https://onlinelibrary.wiley.com/doi/10.1002/jbm.820010202 by Rosalie Beard , Wiley Online Library on [13/02/2023]. See the Terms and Conditions (https://onlinelibrary.wiley.com/terms-and-conditions) on Wiley Online Library for rules of use; OA articles are governed by the applicable Creative Commons License

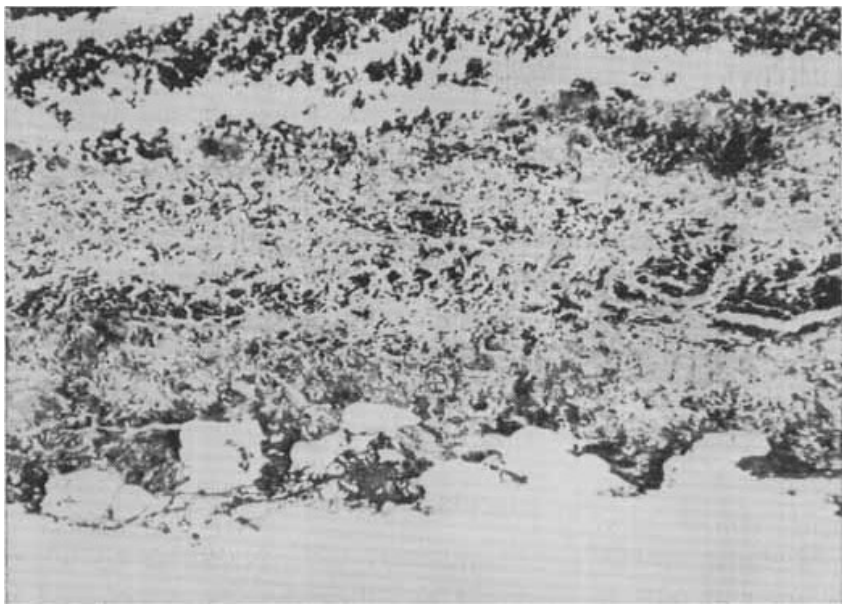

Fig. 3. Section of pseudointima taken from an area near the central portion of a Dacron velour vascular prosthesis after 1 week of implantation. Alternate layers of fibrin and trapped erythrocytes are evident. The luminal surface can be identified by the mass of erythrocytes. No endothelial tissue is present in this region. Hematoxylin and eosin, 580×.

Fig. 4. Section of pseudointima taken from an area adjacent to the suture line in a 2-week-old implant of a Dacron velour vascular prosthesis. Note dense population of plump spindle cells distributed throughout the full thickness of the coagulum. Flattened endothelial cells are present along the luminal border. Hematoxylin and esodin, 580×.

10974636, 1967, 2, Downloaded from https://onlinelibrary.wiley.com/doi/10.1002/jbm.820010202 by Rosalie Beard , Wiley Online Library on [13/02/2023]. See the Terms and Conditions (https://onlinelibrary.wiley.com/terms-and-conditions) on Wiley Online Library for rules of use; OA articles are governed by the applicable Creative Commons License

experience with implantable blood pumps lined with velour. Pumps lined with nylon velour demonstrated the best fibrin attachment. Next, in terms of attachment, were the pumps lined with Dacron velour. A nearly unattached fibrin deposit has been observed during the use of polypropylene velour and Teflon velour. These data suggest that both a chemical as well as a mechanical attachment may have been achieved in the more hydrophilic polymers.

Incorrect pump design yielded gross accumulation of fibrin in areas of stagnation. Pump configuration, proper location of valves, and controlled blood flow are factors which play an important role if a thin, uniform lining deposition is to be achieved.

Vascular Grafts

Our screening procedure stimulated an interest as to whether a superior arterial substitute might be fabricated using velour,* rather than the standard woven Dacron. Tubes of Dacron velour were fashioned in 8, 10, and 12 mm diameters so that the velour made up the internal surface. These tubes have been implanted in dogs for 8 months. So far the grafts have performed well but no conclusion can be drawn at this early date as to its superiority over the standard weaves.

Valve Covering

It would appear that the velour might be applicable in fabricating a more tenacious sewing ring for prosthetic cardiac valves. Better tissue attachment could be attained but whether the extra tissue build-up on the velour surface would counterbalance that asset is difficult to predict.

We have covered our own experimental valve leaflet and seat with velour and those of the standard weave in an attempt to promote a more compatible surface (Fig. 5). Both types are to be evaluated through animal implant studies.

Penetrating Conduits

Tubes and lead wires are commonly brought through the skin and function satisfactorily for extended periods. These devices include

* Velour is a specific term used to describe the velvet surface obtained by warp knitting. A weft knit, which would be used in a seamless graft, is more properly called "plush."

10974636, 1967, 2, Downloaded from https://onlinelibrary.wiley.com/doi/10.1002/jbm.820010202 by Rosalie Beard , Wiley Online Library on [13/02/2023]. See the Terms and Conditions (https://onlinelibrary.wiley.com/terms-and-conditions) on Wiley Online Library for rules of use; OA articles are governed by the applicable Creative Commons License

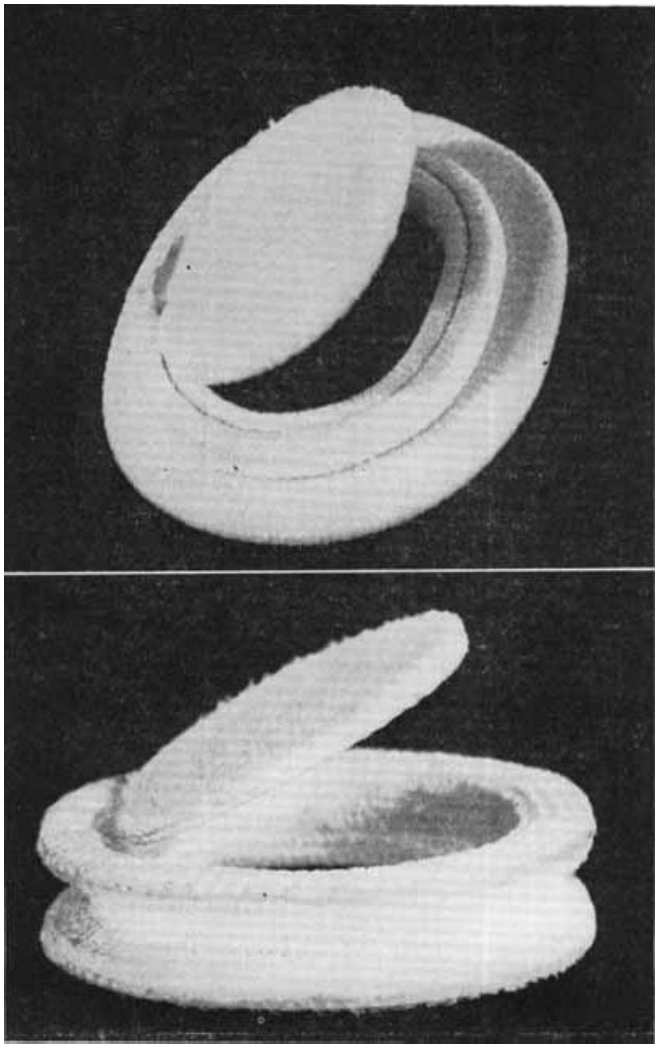

Fig. 5. Two experimental Baylor mitral valves covered with Dacron velour. Top valve fabricated by Surgitool, Inc. Bottom valve fabricated by Statham Instruments, Inc. Leaflet and hinge of both valves are of injected-molded polypropylene.

such things as physiologic monitoring equipment, dialysis units, suction and drainage tubes. There is, however, the ever-present threat of infection progressing along the sinus tract. A serious problem occurs when such penetration must be maintained for prolonged periods.

Our basic interest in this area was stimulated by a search for a means to couple an implanted artificial heart to the external power source. Ultimately, we are seeking the solution of implantable power

10974636, 1967, 2, Downloaded from https://onlinelibrary.wiley.com/doi/10.1002/jbm.820010202 by Rosalie Beard , Wiley Online Library on [13/02/2023]. See the Terms and Conditions (https://onlinelibrary.wiley.com/terms-and-conditions) on Wiley Online Library for rules of use; OA articles are governed by the applicable Creative Commons License

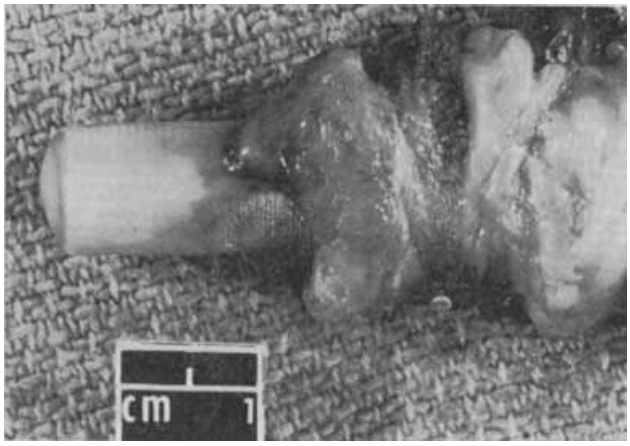

Fig. 6. Silastic rod covered with Dacron velour after 3 months implantation. These test rods penetrated the thorax and communicated with the outside. Strong tissue attachment is evident. There was no sinus tract or infection present.

but so far none of the attempted methods have been reduced to practicality.

From the experience gained with fabrics in blood interfacing, it seemed logical to try other types of tissue for ingrowth and anchorage. Solid Silastic rods covered on the outside with woven and velour fabrics were inserted through the skin and into the pleural space of mongrel dogs. A solid Silastic rod without a fabric coating served as a control. These were left in place for 3 months with no local skin care. A total of 101 implants were made. Each implant became infected, leaving the control rod lying in a draining sinus. The sleeve construction, however, healed except for a few superficial infections which never penetrated more than 1 cm. Tissue ingrowth into the interstices of the weave and loops of this velour obliterated any chance for a major sinus tract formation. Substantial ingrowth was confirmed as early as 1 week and by the end of 2 weeks, the implants were firmly attached to surrounding tissue (Fig. 6). These results indicate that it is possible to leave penetrating lead wires and conduits through the skin for long periods of time without danger of sinus tract formation.

Artificial Skin

Interest in an artificial skin was stimulated from experience gained in artificial heart liners and percutaneous conduits. Since the velour

10974636, 1967, 2, Downloaded from https://onlinelibrary.wiley.com/doi/10.1002/jbm.820010202 by Rosalie Beard , Wiley Online Library on [13/02/2023]. See the Terms and Conditions (https://onlinelibrary.wiley.com/terms-and-conditions) on Wiley Online Library for rules of use; OA articles are governed by the applicable Creative Commons License

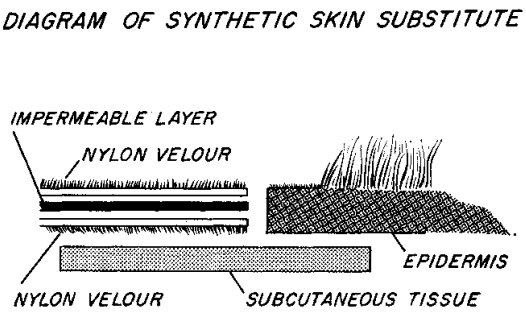

Fig. 7. Schematic diagram of velour laminate used as artificial skin.

fabrics had been successfully bonded to Silastic and since good tissue ingrowth had been demonstrated, it appeared feasible to use similar technics for a temporary skin substitute.

Skin is needed in the treatment of burns to overcome problems including burn wound sepsis, fluid loss, and the shock of early wound excision. The search for an acceptable prosthetic skin substitute has long been stimulated by the fact that sufficient autograft is not always available; both homograft and heterograft when available, are rejected early, and synthetic materials, functioning more as a dressing than an integral part of the body, tend to separate early and fail to overcome burn problems and reduce mortality. In looking toward the future, there also exists the possibility that permanently attached

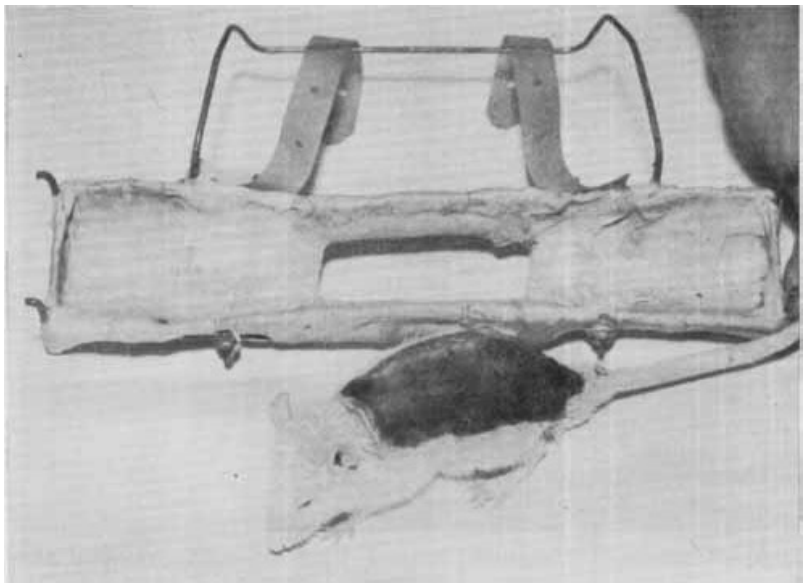

Fig. 8. Rat burn model and shield used in defining burn area.

10974636, 1967, 2, Downloaded from https://onlinelibrary.wiley.com/doi/10.1002/jbm.820010202 by Rosalie Beard , Wiley Online Library on [13/02/2023]. See the Terms and Conditions (https://onlinelibrary.wiley.com/terms-and-conditions) on Wiley Online Library for rules of use; OA articles are governed by the applicable Creative Commons License

artificial limbs—made functional by actual tendinous coupling—could become a reality.

As early as 1961, Dr. William Chardack[15] and his associates reported on a skin substitute made of poly(vinyl alcohol) sponge coated



Fig. 9. Nylon velour–Saran Wrap laminate used to cover 3° burn of a rat 101 days postburn. Burn was seeded with pseudomonus and aerobacter prior to applying the synthetic skin.

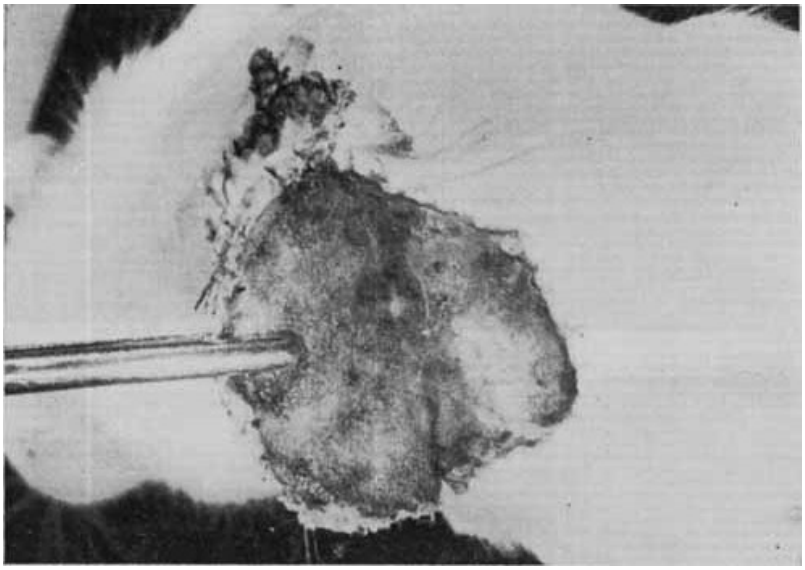

Fig. 10. Appearance of postburn wound covered with artificial skin. Note healthy tissue beneath velour surface, absence of infection, and strong attachment.

10974636, 1967, 2, Downloaded from https://onlinelibrary.wiley.com/doi/10.1002/jbm.820010202 by Rosalie Beard , Wiley Online Library on [13/02/2023]. See the Terms and Conditions (https://onlinelibrary.wiley.com/terms-and-conditions) on Wiley Online Library for rules of use; OA articles are governed by the applicable Creative Commons License

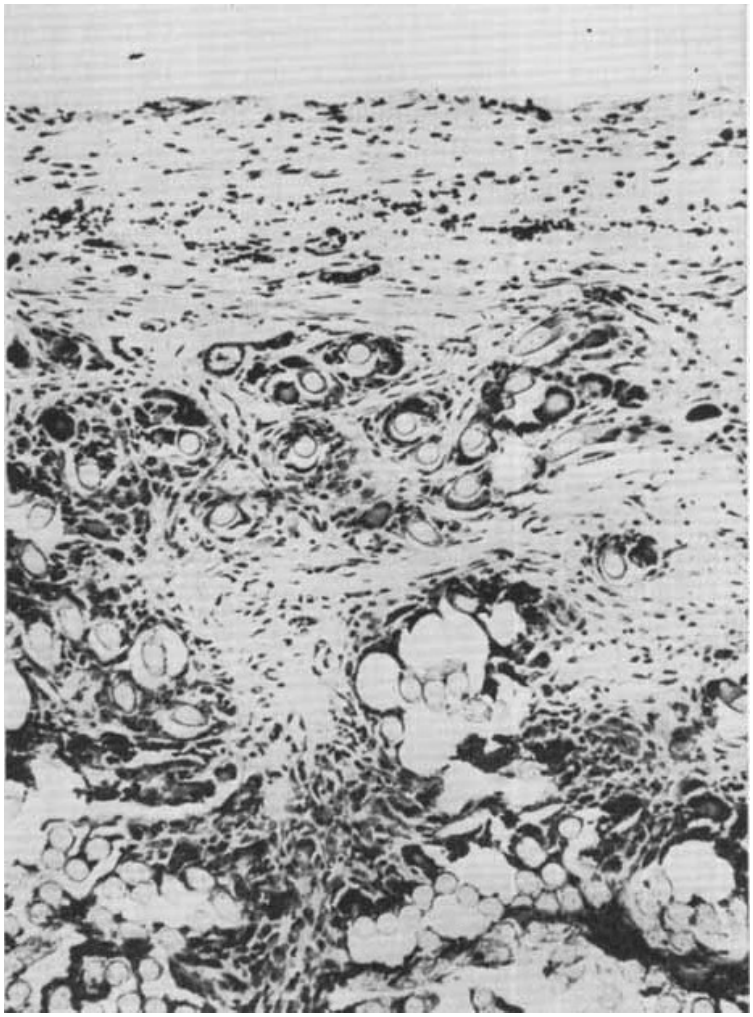

Fig. 11. Cross-section of synthetic skin after 8 months implantation. Fibrous tissue and collagen intertwine velour loops. Although foreign body giant cells are prominent, there is no evidence of acute or chronic infection.

with an RTV Silastic. Their original work on dogs and pigs also raised the question as to whether a completely impervious material is necessary. In our own hands, velour fabrics backed with Silastic 372 or Medical Grade Silastic Adhesive have proven quite satisfactory as a skin substitute. Results of this work have been reported elsewhere.[16]

Dressler et al.[17] used a synthetic skin composed of a double layer of nylon velour with an impermeable layer of poly(vinyl fluoride) (Saran Wrap) in between (Fig. 7) in a study of male Sprague-Dawley rats weighing 180 g (early in the study, use of velour synthetic skin

10974636, 1967, 2, Downloaded from https://onlinelibrary.wiley.com/doi/10.1002/jbm.820010202 by Rosalie Beard , Wiley Online Library on [13/02/2023]. See the Terms and Conditions (https://onlinelibrary.wiley.com/terms-and-conditions) on Wiley Online Library for rules of use; OA articles are governed by the applicable Creative Commons License

without an impermeable layer was abandoned since it was not retained more than a week). After scalding (Fig. 8), each burned area was seeded by a topical application of 1 mm of an 18-hr trypticase soy broth containing 1×10^8 organisms of *Pseudomonas aeruginosa*.

Burned rats were randomly assigned to one of three groups. One control group was not treated. In a second control group, the burned area was excised at 2, 24, or 48 hr postburn. In the treatment group, excision at 2, 24, or 48 hr postburn was followed by application of the synthetic skin (Fig. 9).

Shortly after application, the velour synthetic skin began to adhere, retaining its white appearance with several areas of hematoma. These hematomas gradually disappeared and within 5 to 6 days the velour appeared white with some pink areas. Within 10 to 12 days the prosthetic skin was entirely pink and the graft had become an

TABLE I
Mortality Rate of Infected Animals

	Treatment hours postburn				
	2		24		48
	Area burn		Area burn		Area burn
	20%	40%	20%	40%	20%
No treatment	61% (10.4)[a]	100% (3.2)	—	—	—
Excision only	50% (11)	100% (2.2)	30% (4)	100% (2.6)	100% (4.5)
Excision and synthetic skin	0%	10% (6)	20% (5)	20% (6)	50% (10.3)

[a] Average day of death.

integral part of the wound (Fig. 10). Excellent adherence was maintained even when an animal rubbed against the side of a cage, and the prosthetic skin has remained in place as long as 8 months without evidence of sepsis or rejection (Fig. 11).

The mortality rates of the test animals were closely related to the application of the synthetic skin, as shown in Table I. For example, when the skin substitute was applied to 20% burns 2 hr postburn, mortality was 20%; and when it was applied 48 hr postburn, mortality was 50%.

10974636, 1967, 2, Downloaded from https://onlinelibrary.wiley.com/doi/10.1002/jbm.820010202 by Rosalie Beard , Wiley Online Library on [13/02/2023]. See the Terms and Conditions (https://onlinelibrary.wiley.com/terms-and-conditions) on Wiley Online Library for rules of use; OA articles are governed by the applicable Creative Commons License

Bacteriology counts were carried out on the sub-eschar tissues, heart blood, and on liver cultures of both survivors and nonsurvivors. The use of synthetic skin substitute significantly controlled sepsis in the survivors. All deaths in the nonsurvivors group were due to sepsis.

The insensible water loss of the three groups of animals is shown in Figure 12. The unburned animals lost an average of 11.2 g of water

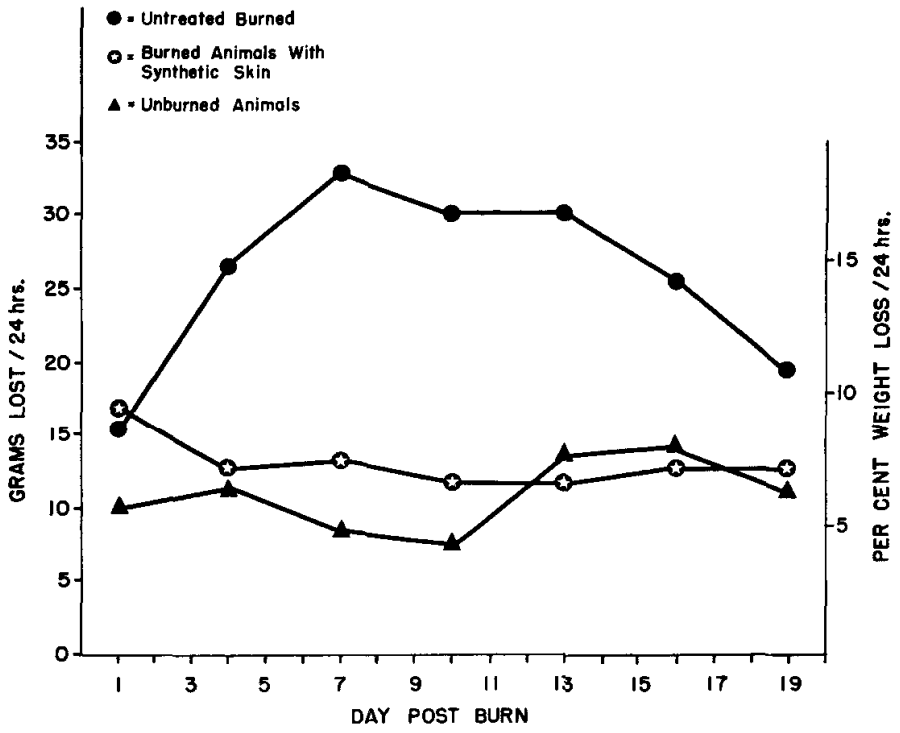

Fig. 12. Average daily water vapor loss in 180-g animal with a 20% body surface area burn.

per day, while the untreated animals with 20% surface area burns lost an average of 25.7 g daily. The burned animals treated with a skin substitute had an average daily loss of 12.7 g.

The impermeable velour, then, has demonstrated a significant ability to reduce mortality. Demonstrable reasons for this effectiveness are: (*1*) the velour is rapidly incorporated into wound tissue; (*2*) there is neither fluid collection nor loss of fluid through the area; (*3*) the impermeable layer prevents recurrent infection; (*4*) the soft outer layer of velour protects the integrity of the material; and (*5*)

10974636, 1967, 2, Downloaded from https://onlinelibrary.wiley.com/doi/10.1002/jbm.820010202 by Rosalie Beard , Wiley Online Library on [13/02/2023]. See the Terms and Conditions (https://onlinelibrary.wiley.com/terms-and-conditions) on Wiley Online Library for rules of use; OA articles are governed by the applicable Creative Commons License

the normal body processes are allowed to control a limited infection with an organism of relatively low virulence.

Currently, investigation as to the feasibility of incorporating antibiotic or bacteriostatic drugs into the composite artificial skin is being conducted. Sylfamylon acetate has been milled into raw Silastic backings, but heat curing causes some degeneration of the drug. Infection around the graft site in dogs has not been a problem but presumably this may be a problem in humans.



Fig. 13. Biopsy from the mid portion of 50-cm² wound once covered with artificial skin (Silastic–velour laminate). Artificial skin was gradually replaced by cornified squamous epithelium growing in from wound edge.

Best results on incorporating drug agents have been obtained with Dacron, nylon, and Rayon velours backed with Silastic 372. It has been interesting to observe that many of the implants have become loosened at the periphery and this small wound is then bridged by epithelial cells growing from the wound edge. This process has continued until the artificial skin has been completely replaced by epithelial extension across the wound—at which point the artificial skin drops off (Fig. 13). Whether or not human skin would react in a similar manner or whether or not a larger wound could be handled in this way is unknown.

10974636, 1967, 2, Downloaded from https://onlinelibrary.wiley.com/doi/10.1002/jbm.820010202 by Rosalie Beard , Wiley Online Library on [13/02/2023]. See the Terms and Conditions (https://onlinelibrary.wiley.com/terms-and-conditions) on Wiley Online Library for rules of use; OA articles are governed by the applicable Creative Commons License

Addendum

Since submitting this manuscript for publication, the senior author has conducted experiments in the permanent attachment of artificial limbs to six canines and one filly.[19] Velour was used as the interfacing material between the biologic tissue and the prosthesis. None



Fig. 14. Vitallium intramedullary rod with incorporated polypropylene cone covered with nylon velour surface.

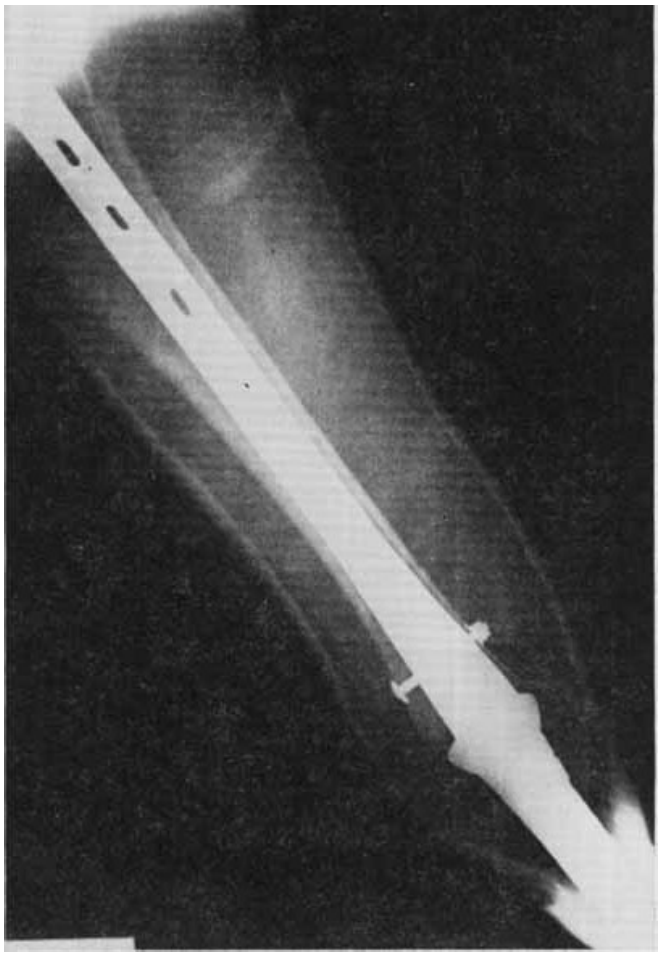

Fig. 15. X-ray of intramedullary rod, through plaster cast and bandages, just after operation.

10974636, 1967, 2, Downloaded from https://onlinelibrary.wiley.com/doi/10.1002/jbm.820010202 by Rosalie Beard , Wiley Online Library on [13/02/2023]. See the Terms and Conditions (https://onlinelibrary.wiley.com/terms-and-conditions) on Wiley Online Library for rules of use; OA articles are governed by the applicable Creative Commons License

Fig. 16. Appearance of artificial limb with the aluminum extension bolted to the Vitallium rod; 1 week postoperative.

of the pilot studies done on canines were successful due to our inability to keep them from destroying the interface by chewing, scratching, and rubbing against the cage.

Following the disheartening experiences with canines, we were presented with an opportunity to salvage a young thoroughbred mare who had been amputated above the hock for traumatically induced osteomyelitis. Since the stainless steel intramedullary rod had proven to be unsatisfactory in the canine implants, a specially made Vitallium intramedullary rod* (Fig. 14) was used in the horse. In this experiment, a longer polypropylene cone completely covered

* Howmet Corporation Medical Division, 224 East 39th Street, New York, N.Y. 10016.

10974636, 1967, 2, Downloaded from https://onlinelibrary.wiley.com/doi/10.1002/jbm.820010202 by Rosalie Beard , Wiley Online Library on [13/02/2023]. See the Terms and Conditions (https://onlinelibrary.wiley.com/terms-and-conditions) on Wiley Online Library for rules of use; OA articles are governed by the applicable Creative Commons License

with nylon velour was used and no attempt was made to make tendenous attachments. After reamputation above the ankle, the intramedullary rod was driven into the tibial canal (Fig. 15) and the skin was brought down loosely over the cone and tailored to fit the interfacing cone's contour. The wound was bandaged and a plaster cast was fashioned over the wound to maintain a clean environment.

Six days later the plaster cast and dressings were removed, revealing a wound healing by primary intent with no evidence of infection. An extension was bolted to the extruding, distal end of the intramedullary rod and the filly immediately started bearing weight on the prosthesis with no evidence of pain or hesitancy. Within 10 min she started walking on the artificial leg, and has now been using it as her own for 1 month (Fig. 16). Except for a superficial infection of *Pseudomonas aeruginosa* (controlled with 0.5% solution of silver nitrate), the wound has shown no evidence of infection. The skin–velour interface appears intact and is functioning as a bacterial barrier.

This encouraging avenue of experimentation will be followed using donkeys, goats, sheep, and pigs in an effort to find the ideal experimental animal for this project. Future designs will include an attempt to bring artificial tendons to the exterior through a velour interface. This would give the wearer of such a device primary muscular control over the prosthesis. Even though the artificial tendons may prove to be impractical, a superior weight-bearing device does appear feasible.

Supported in part by the U.S. Public Health Service Grant HE-09252-03, GM-13510-02, and the Sterling-Winthrop Research Institute, Rensselaer, New York.

References

1. P. N. Sawyer, *Biophysical Mechanisms in Vascular Homeostasis and Intravascular Thrombosis*, Appleton-Century-Crofts, New York, 1965.
2. R. I. Leininger, V. Mirkovitch, R. E. Beck, P. G. Andrus, and W. J. Kolff, *Trans. Am. Soc. Art. Int. Organs*, **10**, 237 (1964).
3. R. E. Beck, V. Mirkovitch, P. G. Andrus, and R. I. Leininger, *J. Appl. Physiol.*, **18**, 1263 (1963).
4. J. Lister, *Croonian Lecture*, cited by Dr. Copley: Discussion, *Biophysical Mechanisms in Vascular Homeostasis*, Appleton-Century-Crofts, New York, 1965, p. 335.
5. M. E. De Bakey, J. P. Abbott, R. M. O'Neal, G. Adams, and G. L. Jordan, Jr., *Cardiov. Res. Center Bull.*, **3**, 7 (1964).

10974636, 1967, 2, Downloaded from https://onlinelibrary.wiley.com/doi/10.1002/jbm.820010202 by Rosalie Beard , Wiley Online Library on [13/02/2023]. See the Terms and Conditions (https://onlinelibrary.wiley.com/terms-and-conditions) on Wiley Online Library for rules of use; OA articles are governed by the applicable Creative Commons License

6. M. E. De Bakey, G. L. Jordan, Jr., J. P. Abbott, B. Halpert, and R. M. O'Neal, *Arch. Surg.*, **89,** 757 (1964).
7. W. V. Sharp, A. F. Finelli, W. H. Falor, and J. W. Ferraro, *Latex vascular prosthesis,* Circulation 29 (supplement), 1964, p. 165.
8. R. L. Simmons, R. C. Bonnabeau, R. M. Ferlis, D. M. Long, and C. W. Lillehei, *Surg. Forum.*, **16,** 128 (1965).
9. P. N. Sawyer, *Trans. Am. Soc. Art. Int. Organs,* **11,** 270 (1965).
10. V. L. Gott, J. D. Whiffen, and R. C. Dutton, *Science,* **142,** 1297 (1963).
11. R. I. Leininger, M. M. Epstein, and R. C. Falb, Nonthrombogenic plastic surface, Sixth International Conference on Medical Electronics and Biologic Engineering, Tokyo, Japan, 1965.
12. C. W. Hall, Discussion of Dr. Kantrowitz's paper, Eighteenth Annual Conference on Engineering in Medicine and Biology, Philadelphia, Pennsylvania.
13. D. Liotta, C. W. Hall, A. Villanueva, R. M. O'Neal, and M. E. De Bakey, *Cardiov. Res. Cent. Bull.*, **4,** 69 (1966).
14. D. Liotta, C. W. Hall, W. W. Akers, A. Villanueva, R. M. O'Neal, and M. E. De Bakey, *Trans. Am. Soc. Art. Int. Organs,* **12,** 129 (1966).
15. W. M. Chardack, C. E. Day, G. Fazekas, and N. Minsley, *J. Trauma,* **1,** 54 (1961).
16. C. W. Hall, D. Liotta, and M. E. De Bakey, *Trans. Am. Soc. Art. Int. Organs,* **12,** 340 (1966).
17. D. P. Dressler, R. R. Rozin, W. A. Skornik, H. N. Harrison, and H. S. Soroff, Prosthetic skin in control of experimental burn wound sepsis, N.Y. Acad. Science Symposium, *Early Treatment of Burns,* 1966.
18. M. M. Chardack, D. A. Brueske, A. P. Santamauro, and G. Fazekas, *Ann. Surg.*, **155,** 127 (1962).
19. C. William Hall, R. H. Eppright, T. Engen, and D. Liotta, *Trans. Am. Soc. Int. Organs,* **13** (1967), in press.

Received December 28, 1966

10974636, 1967, 2, Downloaded from https://onlinelibrary.wiley.com/doi/10.1002/jbm.820010202 by Rosalie Beard , Wiley Online Library on [13/02/2023]. See the Terms and Conditions (https://onlinelibrary.wiley.com/terms-and-conditions) on Wiley Online Library for rules of use; OA articles are governed by the applicable Creative Commons License