Biological Sealants and Knitted Dacron: Porosity and Histological Comparisons of Vascular Graft Materials with and without Collagen and Fibrin Glue Pretreatments

Richard A. Jonas, M.D., Frederick J. Schoen, M.D., Ph.D., Robert J. Levy, M.D., and Aldo R. Castaneda, M.D., Ph.D.

ABSTRACT **Woven Dacron used in extracardiac conduits tends to form a poorly adherent, obstructing layer of pseudointima. Knitted high-porosity conduits allow fibrous and vascular ingrowth and more secure anchoring of the pseudointima. However, at the time of insertion, the porosity rate must be sufficiently low to prevent excessive bleeding in the heparinized patient. Pretreatments with biological sealants are available to temporarily reduce the porosity of knitted Dacron at the time of implantation with subsequent resorption of the sealant. We compared in vitro water porosity rates of knitted Dacron pretreated with conventional techniques, fibrin glue, and collagen impregnation. Only the collagen-impregnated and fibrin glue–treated grafts decreased the porosity of knitted Dacron to an acceptable level.**

To assess the biocompatibility and resorption of biomaterials used in sealing conduits, pretreated Dacron was implanted subcutaneously in weanling rats. Foreign-body response of untreated Dacron was unchanged by conventional techniques. Fibrin glue also resulted in good capillary ingrowth as well as occasional punctate multifocal deposits of calcium phosphate. The collagen-impregnated grafts differed in the intensity of the inflammatory response and tissue adhesion, possibly related to the degree of collagen cross-linking. This may have important implications regarding structure of the pseudointima in vascular grafts sealed with these materials.

One of the major problems facing the pediatric cardiovascular surgeon is the choice of graft material for conduit reconstruction of the heart and great vessels. The limited size of the patient dictates that relatively small-diameter conduits be used, and somatic growth fosters inevitable conduit stenosis. Thus, accumulation of what might be an insignificant amount of obstructing pseudointima in the adult can result in early conduit failure in a child. Although cryopreservation of the antibiotic-treated homograft will improve the availability of this biological alternative [1], synthetic conduits continue to be required.

Tightly woven low-porosity Dacron has proven unsatisfactory for use in right heart conduits [2]. This rigid material is difficult to manipulate, particularly in the small child with fragile pulmonary arteries, and it rapidly develops a thick, poorly adherent layer of pseudointima. Dissection of the pseudointima may cause catastrophic failure [3]. The only advantage of the tightly woven Dacron is its very low porosity; for example, Cooley LoPor has a water porosity of 50 ml/min/cm^2 at 120 mm Hg pressure. In contrast, knitted Dacron has an extremely high porosity, for example, USCI Bionit with 1,500 ml/min/cm^2. This material is supple, allowing more accurate hemostatic anastomoses than woven Dacron. However, control of porosity during insertion is essential.

Recently, several new techniques have become available for controlling conduit porosity using biological materials. These techniques include collagen impregnation and fibrin glue pretreatment. The objectives of the present study were to compare standard Dacron graft materials in terms of porosity control and histological response to biological sealants.

Material and Methods

Porosity Study

Water porosity was determined using the device pictured in Figure 1 as originally described by Wesolowski and associates [4]. An area of test material 1 cm^2 in size is sealed circumferentially by a pneumatic device. Water flow is adjusted through the test material until the desired pressure is maintained (in this case, 100 mm Hg). Tests for leakage around the test material using a nonporous material consistently achieved a porosity of 0. Four segments of each conduit were tested. The mean water porosity ± the standard deviation in milliliters per minute per square centimeter was calculated.

GROUP 1: PRETREATED KNITTED DACRON. Approximately 15-cm lengths of double-velour knitted Dacron 12 mm in diameter (Bionit, USCI, Billerica, MA) were treated by the following techniques.

1. Autoclaved 5% albumin. The conduit was thoroughly soaked in 5% human albumin (Immuno AG, Vienna,

From the Departments of Cardiac Surgery and Pediatric Cardiology, The Children's Hospital, the Department of Pathology, Brigham and Women's Hospital, and the Departments of Pediatrics, Pathology, and Surgery, Harvard Medical School, Boston, MA.

Accepted for publication Oct 12, 1985.

Address reprint requests to Dr. Jonas, Department of Cardiovascular Surgery, The Children's Hospital, 300 Longwood Ave, Boston, MA 02115.

Edwards v. Aortic Innovations
U.S. Patent 11,497,634
Edwards Ex. 1108

Fig 1. Porosity testing device. Graft material is fixed and sealed by pneumatic head. Water flow is adjusted by calibrated flowmeter until pressure is stable.

Austria), the excess was drained off, and the conduit was baked at 133°C for three minutes.

2. Preclotting. Approximately 20 ml of freshly drawn human blood was massaged into the graft until it clotted. Free clots were picked off.
3. Autoclaved heparinized blood. The conduit was soaked in human blood treated with heparin, 3 mg per kilogram of body weight, followed by autoclaving at 133°C for three minutes.
4. Fibrin glue (Immuno AG, Vienna, Austria). The two components of the glue were reconstituted. The sealant/fibrinolysin inhibitor was massaged into the Dacron. The calcium/thrombin component was then carefully dripped over the complete surface of the conduit.
5. Strongly cross-linked collagen treatment. This knitted double-velour conduit (Tascon Medical Technology Corp., Irvine, CA) is commercially sealed on its luminal surface with strongly cross-linked bovine collagen. The untreated porosity is 1,500 ml/min/cm^2. The graft is supplied sterile in a weak aldehyde solution.
6. Weakly cross-linked collagen treatment. This double-velour knitted Dacron (Microvel with Hemashield, Meadox Medicals, Inc., Newark, NJ) is commercially impregnated with weakly cross-linked bovine collagen. The untreated porosity is 1,900 ml/min/cm^2. The graft is supplied dry and sterile.

GROUP 2: PHYSICALLY MANIPULATED PRETREATED KNITTED DACRON. Both the fibrin glue–sealed and collagen-treated conduits were manipulated by placing a vascular clamp obliquely five times along the full length of the conduit and by making two 360-degree twists in opposite directions.

GROUP 3: PRETREATED KNITTED DACRON WITH HEPARINIZED BLOOD AGITATION. Identical segments of conduit as treated in Group 1 were agitated in fully heparinized human blood (3 mg/kg) for two hours (at 37°C) prior to the porosity study.

GROUP 4: PRETREATED WOVEN DACRON AND POLYTETRAFLUOROETHYLENE. Conduit segments of Cooley Veri-Soft and LoPor (Meadox Medicals, Inc.) were tested following preclotting with fresh blood and baking with 5% human albumin. The porosity of untreated polytetrafluoroethylene (PTFE) (Gore-tex, W. L. Gore, Elkton, MD) was tested also.

Histological Study

One-centimeter squares of knitted Dacron (Bionit) were treated similarly to those for the porosity determination. To avoid immunological effects, 5% rat albumin (Sigma, St. Louis, MO) and rat blood were used. However, fibrin glue was human and bovine derived (Immuno AG, Vienna, Austria). The collagen-impregnated Tascon and Meadox Hemashield grafts were also implanted.

Samples of material 1-cm square were inserted subcutaneously in ether-anesthetized week-old male weanling rats weighing 60 to 80 gm (Sprague-Dawley derived [CD strain]). The samples were placed in subcutaneous pouches dissected in the midabdominal wall and separated by at least 2 cm. Wounds were closed with surgical staples. Graft specimens were retrieved following death by ether anesthetic overdose following 3 and 6 weeks of implantation. Specimens were fixed in 10% neutral buffered formalin or 2.5% glutaraldehyde and in 2% paraformaldehyde in cacodylate buffer (pH 7.2) [5], dehydrated, and embedded in glycolmethacrylate medium (JB-4, Polysciences, Warrington, PA). Sections 2 to 3 μ thick were stained with hematoxylin and eosin (for overall morphology), Masson trichrome (for collagen), and von Kossa stain (for calcium phosphates). Collagen-pretreated explants were analyzed for elemental calcium by atomic absorption spectroscopy of six NHCl hydrolysates [6].

Results

Porosity

Clinical experience suggests that a measured water porosity greater than 50 ml/min/cm^2 results in unacceptable bleeding in the fully heparinized patient. By this criterion, the only acceptable materials are PTFE, LoPor woven Dacron, Veri-Soft woven Dacron albumin baked or preclotted, or knitted Dacron treated with fibrin glue

Mean Water Porosity at 100 mm Hg[a]

Treatment	Group 1 (Knitted Dacron)	Group 2 (Manipulated Knitted Dacron)	Group 3 (Knitted Dacron + Blood Agitation)	Group 4		
				Lo-Por	Veri-Soft	Gore-Tex
Control, untreated	1,613 ± 41	...	...	46 ± 8	101 ± 16	0
Baked 5% albumin	495 ± 32	...	410 ± 90	25 ± 11	25 ± 3	...
Preclotting	319 ± 49	...	223 ± 53	10 ± 1	11 ± 4	...
Baked heparinized blood	56 ± 4	...	67 ± 31	...	...	...
Fibrin glue	5 ± 2	5 ± 2	2 ± 0.8	...	...	...
Tascon collagen treated	9 ± 5	74 ± 2	18 ± 18	...	...	...
Meadox collagen treated	< 1	13 ± 8	13 ± 8	...	...	...

[a]Data are shown in milliliters per minute per square centimeter and ± the standard deviation.

or collagen impregnation (Table). However, following manipulation, the strongly cross-linked collagen-treated graft (Tascon Medical) has an unacceptable porosity, probably because of cracking of the collagen lining. Agitation of the sealed grafts in heparinized blood did not result in a substantial increase in porosity with any of the techniques. In fact, there was a trend toward lower porosity, presumably caused by progressive thrombus formation in the interstices of the graft.

Histological Study

Host tissue reactions to all implants were virtually identical at 3 and 6 weeks.

Untreated Dacron evoked an intense, well-vascularized granulomatous foreign-body inflammatory response characterized by numerous macrophages and multinucleated giant cells infiltrating through the fabric interstices (Fig 2). Inflammatory cells were infiltrating equally from both surfaces with symmetrical adhesion of surrounding tissue to the graft. Dacron pretreated with autoclaved 5% rat albumin, clotted rat blood, or autoclaved heparinized rat blood had an identical host response to that elicited from the untreated fabric without apparent remaining sealant material. Dacron sealed with fibrin glue evoked essentially the same response, but occasional pools of fibrin had punctate multifocal deposits of calcium phosphate adjacent to Dacron fibrils (Fig 3).

Commercially fabricated collagen-pretreated grafts caused generally similar reactions, except in the areas containing the collagenous matrix (Figs 4, 5). The Meadox microvel with Hemashield, which initially has a collagenous layer on both surfaces, showed partial inflammatory resorption of collagen with little additional modification of the foreign-body response seen to untreated Dacron (see Fig 4). Despite only partial resorption of the collagen coating by mononuclear phagocytes, the surrounding host tissue adhered to the graft throughout most of both graft surfaces.

In contrast, the Tascon graft collagen, which, as prepared, coated the inside surface only, was minimally absorbed and, following implantation, remained visible as a distinct layer on the inside surface of the Dacron

Fig 2. Histological response to untreated Dacron following implantation for 6 weeks subcutaneously in the rat. There is a diffuse, intense granulomatous foreign-body inflammatory response throughout the tissue. Abundant multinucleated giant cells are present. Many capillary-sized blood vessels permeate the Dacron mesh (arrow). *(H&E; A, ×150, and B, ×375, both before 20% reduction.)*

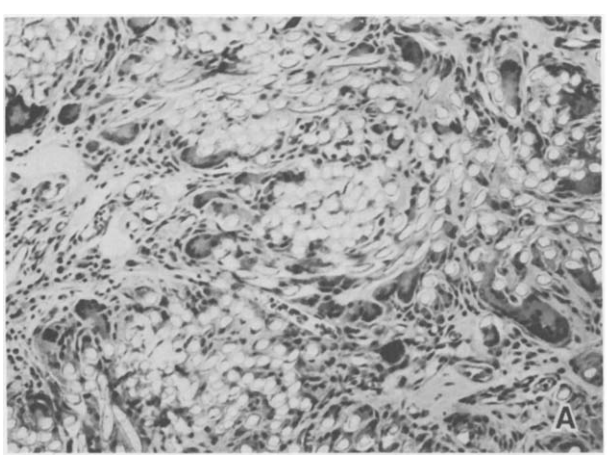

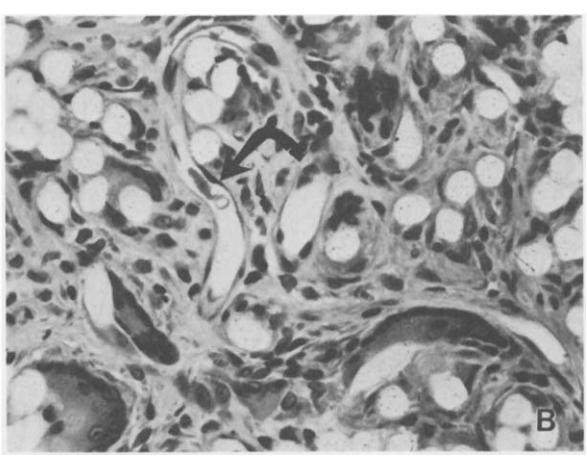

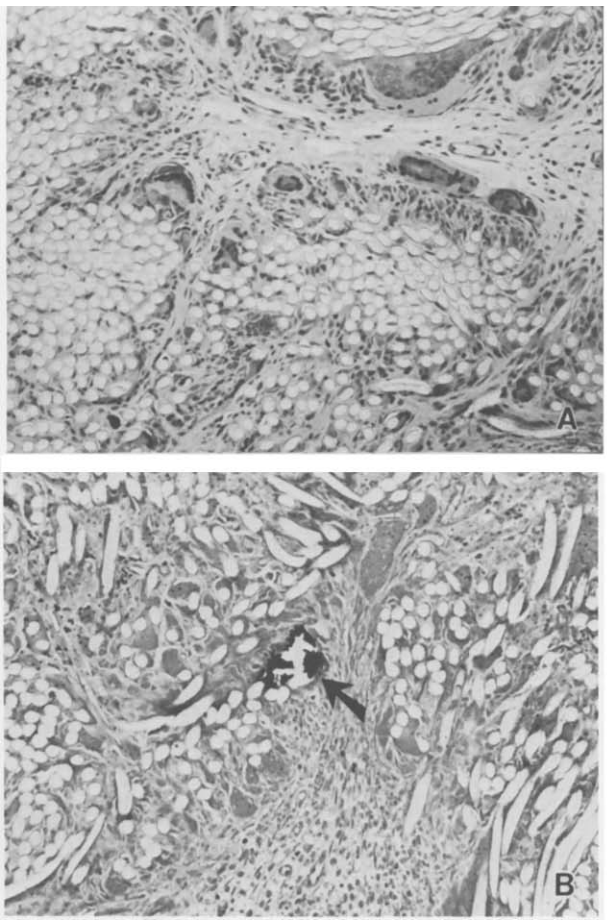

Fig 3. Histological response of fibrin glue–sealed Dacron graft following 6 weeks of subcutaneous implantation in the rat. The inflammatory response is similar in all respects to that shown in Figure 2 for untreated Dacron save for the presence of multifocal calcium phosphate deposits (arrow). *A, H&E, and B, von Kossa stain; both ×150 before 20% reduction.)*

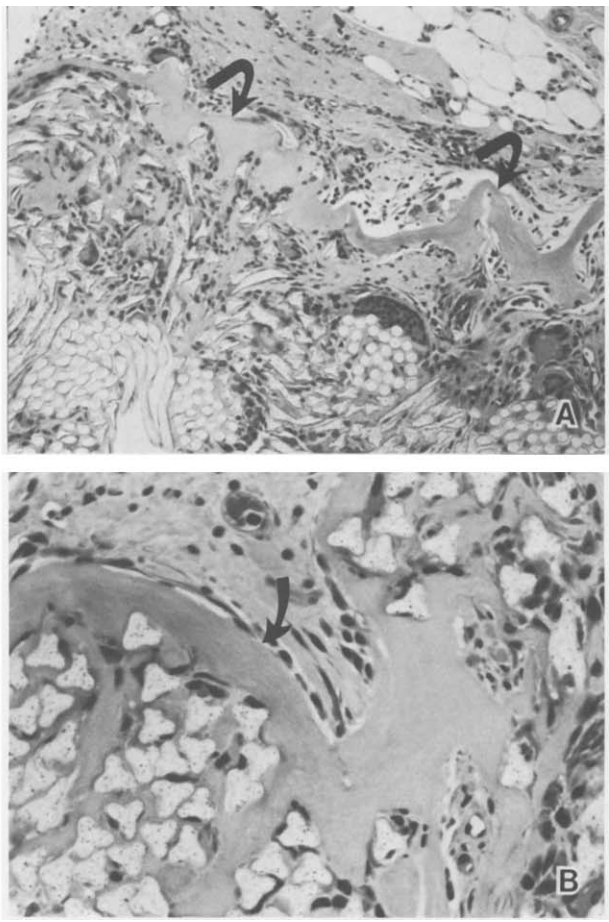

Fig 4. Histological response to Meadox collagen-coated graft (Microvel with Hemashield) 6 weeks after subcutaneous implantation in the rat. The response to the graft fibrils is similar to that seen in Figures 2 and 3 for untreated and fibrin glue–treated Dacron, but there is, in addition, an inflammatory response centered on the collagenous coating (arrows). *The surrounding inflammatory reaction is adherent to the collagen throughout, and there is evidence of some resorption. (H&E; A, ×150, and B, ×375, both before 20% reduction.)*

graft. Fibrous ingrowth and neovascularization extended from the opposite surface through the interstices of the graft up to the collagen layer. The collagen-coated surface, at its contact with surrounding tissue, had a diminished inflammatory response with a smooth, minimally cellular fibrous capsule, which was poorly adherent to the collagen itself. This layer of fibrous encapsulation resembled the tissue reaction to a smooth, inert synthetic implant [7]. Focal adhesion was noted at points where the collagen coating was either breached or resorbed. Macrophages and foreign-body giant cells with evidence of active resorption were seen focally between the collagen layer and the Dacron graft substrate. No mineralization was noted in the collagen-treated grafts.

Comment

The present study examined the effects of biological sealants on the water porosity and histological response to conventional Dacron vascular graft material. The results of our study suggest that conventional preclotting techniques do not modify capillary ingrowth and other histological features of the standard inflammatory response to Dacron, but that they also do not safely decrease porosity of knitted Dacron. Collagen impregnation can produce satisfactory control of porosity, though the specific methods of cross-linking and impregnation are important in determining porosity following graft manipulation. The method of collagen impregnation and cross-linking is probably also important in determining the histological reaction, particularly the adhesion of the host inflammatory reactive tissue, and probably the rate of collagen resorption. Failure of the collagen to resorb because of excessive cross-linking effectively may produce a conduit analogous to those of impervious materials such as tightly woven Dacron. Pretreatment with fibrin glue yields reliable porosity control without inhibiting capillary and fibrous ingrowth.

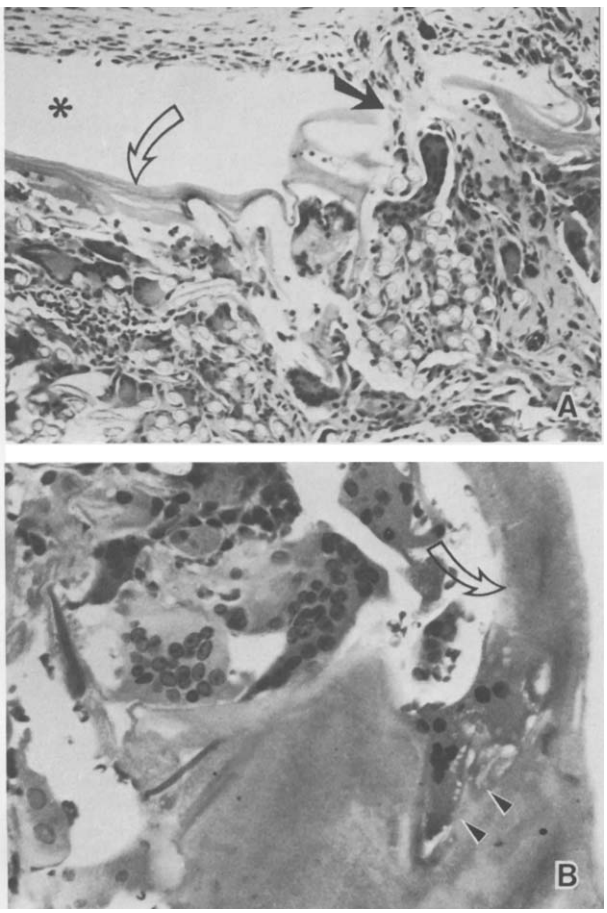

Fig 5. Histological reaction to Tascon collagen-coated graft 6 weeks following subcutaneous implantation in the rat. The diffuse granulomatous inflammatory response throughout most of the graft is characteristic of the untreated Dacron graft. However, the collagen coating on the graft (open arrows) *is only focally adhered to by the surrounding inflammatory response* (arrow), *thereby leaving areas of separation between the fibrous encapsulation and the implant. An area of such separation is demarcated by the* asterisk. *An area of focal resorption of the collagenous matrix by macrophage giant cells is marked by* arrowheads. *(H&E; A, ×150, and B, ×375, both before 20% reduction.)*

The results reported verify that the porosity of untreated knitted Dacron is high, but that this permeability may be reduced substantially by various pretreatments. The critical importance of porosity in determining the long-term performance of synthetic conduits has been repeatedly emphasized since the pioneering studies by Edwards [8], Wesolowski and colleagues [4], and others [9] in the late 1950s and early 1960s. Wesolowski and coworkers [4] suggested that low porosity prevented capillary ingrowth and led to a degeneration of the deepest layer of fibrin laid down on the luminal surface of the conduit. Areas of pseudointima can slough, thereby causing both distal embolism and mural thrombus formation. Such thrombus often forms a stenosing septum, which shows progression to complete obstruction. Calcification may also occur in the degenerating inner layer of pseudointima [4].

Wesolowski and associates [4] constructed a curve of porosity against calcification index, which suggested that a water porosity of 5,000 ml/min/cm^2 was ideal. However, at the time of implantation in the fully heparinized patient, porosity must be controlled to less than 50 ml/min/cm^2 to avoid massive hemorrhage. Cardiovascular surgeons soon become aware of the lack of reliable porosity control using simple preclotting of knitted Dacron prostheses with water porosities in the range of 2,000 ml/min/cm^2. Reluctantly, they turned to the very low porosity woven Dacron.

Our study confirms that very low levels of porosity can be achieved with woven Dacron using conventional preclotting or baking techniques. Although this material has produced relatively satisfactory results for aortic replacement in adult patients with dilated or aneurysmal vessels, it has become increasingly apparent that the material is unsatisfactory for use in the pediatric population. There is often massive accumulation of poorly adherent pseudointima. A recent study [2] at this hospital revealed a 0% actuarial freedom from replacement of right heart valved woven Dacron conduits after ten years and 53% at eight years. Acute fatal obstruction due to separation of pseudointima has also been reported [3].

The present study emphasizes that collagen coating may be a useful approach to porosity control, but that the details of the preparation technique are critical to performance. Shortly after the first reports appeared emphasizing the importance of high-porosity conduits, numerous studies examined the feasibility of temporarily sealing highly porous conduits with an absorbable biological material. Denatured collagen (gelatin) was one of the first materials used and appeared to be rapidly resorbed with minimal influence on subsequent healing [10–12]. However, these grafts were brittle and porosity control was variable.

Our study has confirmed that with some techniques of collagen preparation and impregnation, manipulation of the graft can cause an unacceptable increase in porosity. Jordan and co-workers [11] found that gelatin-impregnated knitted Dacron conduits inserted in growing pigs continued to accumulate a thick pseudointima despite resorption of the gelatin and formation of a complete endothelial covering. Human beings, of course, differ from both pigs and dogs in that complete endothelialization of a prosthesis is never seen [13].

In 1963, Wesolowski and colleagues [14] reported an extensive animal investigation of compound prosthetic conduits temporarily sealed with 24 different biologically degradable materials. Of particular relevance to our study was that one of the worst results was obtained with tanned (aldehyde cross-linked) collagen. Its use resulted in a high degree of calcification, septum formation with obstruction, and occasionally sloughing of portions of the pseudointima. Most of these problems were attributed to delayed resorption of the collagen. Al-

though the results of our histological study rationalize some of this poor adhesion behavior, no calcification of the collagen coatings was noted. Wesolowski and coworkers concluded that their studies supported the concept of a conduit with an absorbable component that should preferably resorb at a rapid rate similar to fibrin.

Despite this early enthusiasm, widespread application of biological sealants with knitted conduits did not occur. An albumin-coated knitted conduit was marketed briefly [15, 16] but was soon withdrawn because of manufacturing inconsistencies in the porosity and problems with dissection and embolism of the albumin layer. Currently, two knitted conduits sealed with collagen are under clinical investigation in the United States. The Tascon conduit has an internal coating of strongly cross-linked aldehyde-treated purified bovine collagen. The rate of resorption of the collagen is not specified by the manufacturer though it is probably in excess of 6 to 12 months. The Meadox Microvel conduit with Hemashield is impregnated with loosely cross-linked collagen, which the manufacturer specifies is totally resorbed within 12 weeks. Both the Microvel and the untreated Tascon conduits have a water porosity that ranges between 1,500 and 2,000 ml/min/cm^2 prior to collagen treatment.

In Europe there has been considerable enthusiasm for the use of fibrin glue to seal knitted conduits [17–19]. A direct comparison between fibrin glue–sealed knitted conduits and woven Dacron conduits placed between the right ventricle and pulmonary artery in dogs revealed a significantly thinner pseudointima in the knitted conduit at 6, 12, and 24 weeks [20].

Our water porosity studies confirmed that both Meadox and Tascon collagen treatments and the fibrin glue treatment decrease the porosity of knitted Dacron to a safe level. However, manipulation of the Tascon conduit resulted in a marked increase in porosity. This may have been due to cracking of the internal collagen coating.

Numerous other techniques have been described for presealing conduits other than simple preclotting [21–28]. These techniques are predominantly applied to the moderate low-porosity woven Dacron conduits, which range in untreated water porosity from 100 to 250 ml/min/cm^2. To our knowledge, a direct comparison of the water porosity achieved in knitted conduits using these techniques has not previously been reported. Our data suggest that none of the preclotting or soaking plus autoclaving techniques are sufficiently reliable for clinical use in knitted conduits in the heparinized patient, because they do not consistently decrease the porosity to less than 50 ml/min/cm^2.

Subcutaneous implantation of glutaraldehyde-treated bioprosthetic heart valves in the weanling rat model has been helpful in elucidating mechanisms of their calcification [29]. In the present study, the identical rat model confirmed that the different degree of cross-linking of collagen induced in the Tascon and Meadox grafts results in a marked difference in histological response, probably due to different absorption rates. Persistence of the collagen layer in the Tascon graft was associated with a diminished inflammatory response and poor tissue adhesion to the collagen-coated Dacron. The collagen layer also prevents capillary growth through the Dacron, thus negating one of the important potential advantages of the higher porosity Dacron. Preliminary results from a study in progress at Children's Hospital in which different collagen-treated conduits were placed between the right ventricle and pulmonary artery of sheep tend to confirm that persistence of the collagen lining is associated with poor pseudointima adhesion.

Neither the cause nor the importance of the focal punctate calcification in the fibrin glue–treated Dacron is known. It may result simply from the highly concentrated calcium/thrombin mixture used to activate the fibrinogen/plasmin component.

In conclusion, fibrin glue and collagen pretreatment allow sufficient control of the porosity of knitted Dacron to allow its implantation in the heparinized patient. However, there are major differences in the fate of these absorbable biomaterials according to their exact method of preparation. This may have important implications in the long-term performance of conduits constructed from knitted Dacron and pretreated with these materials.

The authors acknowledge the assistance of Immuno AG, Meadox Medicals, Inc., Tascon Medical Technology, and USCI, that supplied the materials used in this study.

References

1. Fontan F, Choussat A, Deville C, et al: Aortic valve homografts in the surgical treatment of complex cardiac malformations. J Thorac Cardiovasc Surg 87:649, 1984
2. Jonas RA, Freed MD, Mayer JE, Castaneda AR: Long-term follow-up of synthetic right heart conduits. Circulation 72: Suppl II:77, 1985
3. Ben-Shachar G, Nicoloff DM, Edwards JE: Separation of neointima from Dacron graft causing obstruction. J Thorac Cardiovasc Surg 82:268, 1981
4. Wesolowski SA, Fries CC, Karlson KE, et al: Porosity: primary determinant of ultimate fate of synthetic vascular grafts. Surgery 50:91, 1961
5. Karnovsky MJ: A formaldehyde-glutaraldehyde fixative of high osmolality for use in electron microscopy. J Cell Biol 27:137A, 1965
6. Schoen FJ, Levy RJ, Nelson AC, et al: Onset and progression of experimental bio-prosthetic heart valve calcification. Lab Invest 52:523, 1985
7. Andrade JD: Interfacial phenomena and biomaterials. Med Instrum 7:110, 1973
8. Edwards WS: The effect of porosity in solid plastic artery grafts. Surg Forum 8:446, 1957
9. Fry WJ, DeWeese MS, Kraft RO, Ernst CB: Importance of porosity in arterial prostheses. Arch Surg 88:836, 1964
10. Bascom JU: Gelatin sealing to prevent blood loss from knitted arterial grafts. Surgery 50:504, 1961
11. Jordan GL, Stump MM, Allen J, et al: Gelatin-impregnated prosthesis implanted into porcine thoracic aorta. Surgery 53:45, 1963

12. Humphries AW, Hawk WA, Cuthbertson AM: Arterial prosthesis of collagen-impregnated Dacron tulle. Surgery 50:947, 1961
13. Berger K, Sauvage LR, Rao AM, Wood SJ: Healing of arterial prostheses in man: its incompleteness. Ann Surg 175:118, 1972
14. Wesolowski SA, Fries CC, Domingo RT, et al: The compound prosthetic vascular graft: a pathologic survey. Surgery 53:19, 1963
15. Domurado D, Guidoin R, Marois M, et al: Albuminated Dacron prostheses as improved blood vessel substitutes. J Bioeng 2:79, 1978
16. Guidoin R, Snyder R, Martin L, et al: Albumin coating of a knitted polyester arterial prosthesis: an alternative to preclotting. Ann Thorac Surg 37:457, 1984
17. Haverich A, Walterbusch G, Borst HG: The use of fibrin glue for sealing vascular prostheses of high porosity. Thorac Cardiovasc Surg 29:252, 1981
18. Borst HG, Haverich A, Walterbusch G, Maatz W: Fibrin adhesive: an important hemostatic adjunct in cardiovascular operations. J Thorac Cardiovasc Surg 84:548, 1982
19. Stark J, de Leval M: Experience with fibrin seal (Tisseel) in operations for congenital heart defects. Ann Thorac Surg 38:411, 1984
20. Haverich A, Oelert H, Maatz W, Borst HG: Histopathological evaluation of woven and knitted Dacron grafts for right ventricular conduits: a comparative experimental study. Ann Thorac Surg 37:404, 1984
21. Wuerflein RD, Campbell GS: Analysis of preclotting technics for prosthetic arterial grafts. Am Surg 29:179, 1963
22. Bethea MC, Reemtsma K: Graft hemostasis: an alternative to preclotting. Ann Thorac Surg 27:374, 1979
23. Gloviczki P, Hollier LH, Hoffman EA, et al: The effect of preclotting on surface thrombogenicity and thromboembolic complications of Dacron grafts in the canine thoracic aorta. J Thorac Cardiovasc Surg 88:253, 1984
24. Glynn MFX, Williams WG: A technique for preclotting vascular grafts. Ann Thorac Surg 29:182, 1980
25. Cooley DA, Romagnoli A, Milam JD, Bossart MI: A method of preparing woven Dacron aortic grafts to prevent interstitial hemorrhage. Cardiovasc Dis (Bull Tex Heart Inst) 8:48, 1981
26. Weeks DL Jr: Preclotting grafts (correspondence). Ann Thorac Surg 31:97, 1981
27. Moore JWP: Preclotting vascular grafts (correspondence). Ann Thorac Surg 32:320, 1981
28. Thurer RL, Hauer JM, Weintraub RM: A comparison of preclotting techniques for prosthetic aortic replacement. Circulation 66:Suppl 1:143, 1982
29. Levy RJ, Schoen FJ, Levy JT, et al: Biologic determinants of dystrophic calcification and osteocalcin deposition in glutaraldehyde preserved porcine aortic valve leaflets implanted subcutaneously in rats. Am J Physiol 113:143, 1983