11
H677

The Thoracic and Cardiovascular Surgeon

No. 1 Vol. 34 February 1986 Page 1–70 E 20292 F

Editor:
H. G. Borst, Hannover, FRG
Assistant Editors:
A. Haverich, Hannover, FRG
J. Laas, Hannover, FRG
G. Ziemer, Boston, MA, USA
Administrative Assistant:
R. Bösche, Hannover, FRG
Editor from 1953 to 1978:
K. Vossschulte, Giessen, FRG

Editorial Board:
W. Bircks, Düsseldorf, FRG
M. Braimbridge, London, UK
C. M. Gomez Durán, Santander, Spain
R. Hetzer, Berlin, FRG
J. N. Homan van der Heide, Groningen, The Netherlands
H. A. Huysmans, Leiden, The Netherlands
W. Maassen, Essen, FRG
B. J. Messmer, Aachen, FRG
H. Rahbek Sørensen, Copenhagen, Denmark
G. Rodewald, Hamburg, FRG
P. A. Sánchez, Madrid, Spain
A. Senning, Zürich, Switzerland
E. Wolner, Wien, Austria

Editorial Consultants:
R. Arcas, Pamplona, Spain
A. E. Becker, Amsterdam, The Netherlands
H.-M. Becker, München, FRG
G. von Bernuth, Aachen, FRG
D. Birnbaum, Bad Krozingen, FRG
P. Blondeau, Paris, France
H. J. Bretschneider, Göttingen, FRG
P. Brücke, Linz, Austria
A. Castaneda, Boston, MA, USA
F. A. Diaz, Madrid, Spain
H. Dittrich, Münster, FRG
I. Gallo, Santander, Spain
F. W. Hehrlein, Giessen, FRG
P. Lichtlen, Hannover, FRG
B. Rigler, Graz, Austria
S. Skotnicki, Nijmegen, The Netherlands
G. Thiene, Padova, Italy
F. Vermeulen, Utrecht, The Netherlands
I. Vogt-Moykopf, Heidelberg, FRG

Contents

Messmer, B.J., R. von Essen, C. Minale, P. Bardos, R. Übis, R. Dörr, and *S. Effert,* Aachen, FRG: Intracoronary Thrombolysis and Early Bypass Surgery for Acute Myocardial Infarct: Five Years' Experience 1

von der Emde, J., F. Köckerling, J. Rein, and *A. Hertlein,* Erlangen, FRG: Measures of Prevention and Technical Problems during Reoperations in Cardiac Surgery 5

de Bruin, M.J., L.K. Lacquet, S.H. Skotnicki, J.G. Vincent, and *J.J. van der Meer,* Nijmegen, The Netherlands: Reoperation for Prosthetic Heart Valve Replacement 12

Mostefa Kara, M., F. Langlet, D. Blin, A. Mouly, Ch. Avierinos, A. Goudard, and *J.R. Monties,* Marseille, France: Triple Valve Procedures: An Analysis of Early and Late Results 17

Lange, P.E., W. Pulss, H.H. Sievers, A. Wessel, D.G.W. Onnasch, A. Bernhard, M.H. Yacoub, and *P.H. Heintzen,* Kiel, FRG, and Harefield, UK: Cardiac Rhythm and Conduction after Two-stage Anatomic Correction of Simple Transposition of the Great Arteries 22

Guvendik, L., M. Davies, and *D.J. Parker,* London, UK: Oral Beta-blockade with Hypothermic Potassium Cardioplegia in Cardiac Surgery: Is There an Additive Protective Effect? 25

van Niekerk, J.L.M., F.M.J. Heijstraten, R.J.A. Goris, F.G.M. Buskens, A. Eijgelaar, and *L.K. Lacquet,* Nijmegen, The Netherlands: Spinal Cord Injury following Surgery for Acute Traumatic Rupture of the Thoracic Aorta 30

Segesser, L.v., J. Cox, and *B. Faidutti,* Geneva, Switzerland: Equine Pericardial Xenograft in Orthotopic Position: Early Results 35

Merkle, N.M., G.H. Mickisch, K. Kayser, P. Drings, and *I. Vogt-Moykopf,* Heidelberg, FRG: Surgical Resection and Adjuvant Chemotherapy for Small Cell Carcinoma 39

Rahlf, G., P. Urban, and *R.M. Bohle,* Münster, FRG: Morphology of Healing in Vascular Prostheses 43

Köveker, G.B., K.H. Petzke, M. Borg, and *K. Nebendahl,* Göttingen, FRG: Reduction of Thrombogenicity in Small-diameter Vascular Prostheses Seeded with Autologous Endothelial Cells 49

Haverich, A., W. Maatz, Th. Stegmann, H. Oelert, and *H.G. Borst,* Hannover, FRG: Experimental and Clinical Experiences with Double-velour Woven Dacron Prostheses 52

Stegmann, Th., A. Haverich, and *H.G. Borst,* Hannover, FRG: Clinical Experience with a New Collagen-coated Dacron Double-velour Prosthesis 54

Friedrich, H., J. Laas, G. Walterbusch, and *E. Rickels,* Hannover, FRG: Extra-intracranial Bypass Procedure with Saphenous Vein Grafts 57

Wollenek, G., G. Laufer, R. Fasol, P. Zilla, and *E. Wolner,* Vienna, Austria: Laser-induced Vascular Lesion by cw-NdYAG or Pulsed UV Lasers during Angioplastic Procedures 63

Erdman, S., L. Levinsky, E. Deviri, and *M.J. Levy,* Tel Aviv, Israel: Closed Pericardial Drainage for Relief of Pericardial Tamponade 66

Angelini, G.D., A.G. Fraser, and *I.M. Breckenridge,* Cardiff, UK: Malfunction of a Lillehei-Kaster Aortic Valve Presenting as Loss of the Normal Valve Click 68

Announcements 70

This journal is regularly listed in Current Contents, Science Citation Index and Index Medicus

100 Years 1886–1986 Thieme Stuttgart · New York

Thieme Georg Thieme Verlag, Stuttgart · New York
Thieme Inc., New York

Thorac. cardiovasc. Surgeon ISSN 0171-6425

Edwards v. Aortic Innovations
U.S. Patent 11,497,634
Edwards Ex. 1112

Thorac. cardiovasc. Surgeon 34 (1986) 54–56
© Georg Thieme Verlag Stuttgart · New York

Clinical Experience with a New Collagen-coated Dacron Double-velour Prosthesis

Th. Stegmann, A. Haverich, and H.G. Borst

Division of Thoracic and Cardiovascular Surgery, Surgical Center, Hannover Medical School, Hannover, FRG

Summary

Vascular grafts with primary zero porosity are desirable in surgery for aortic aneurysms with intraoperative partial or total systemic heparinization of the patient. The present study describes the clinical application and results of a new knitted Dacron double-velour prosthesis (primary porosity: 1,400 cc/min/cm^2), coated with cross-linked bovine collagen; the resulting porosity for implantation is 0 cc/min/cm^2.

Such grafts were implanted in 111 patients between 12/83 and 11/84: for replacement of the infrarenal aorta in 74 aneurysms, for replacement of the thoraco-abdominal aorta in 4 instances, and for replacement of 13 aneurysms of the descending aorta. In 20 patients with arterial occlusive disease, the prosthesis was employed as bifurcation graft. In 43 cases (38 %) the underlying disease was a ruptured (26) or symptomatic aortic aneurysm requiring emergency operation.

There was no leakage from any of the implanted grafts regardless of whether partial (100 units/kg BW) or total (300 units/kg BW) systemic heparinization was administered. The overall mortality rate was 11.7 % (13/111). For cases of ruptured abdominal aortic aneurysm the mortality rate was 22.7 % (5/22). There was no graft-related complication either in the early postoperative course or during the follow-up period (1 to 10 months, mean: 6.2 months).

It is concluded that this new type of graft combines the advantages of knitted Dacron prostheses in respect to healing and incorporation with primary zero porosity, and is therefore the graft of choice in surgery for ruptured aortic aneurysm.

Key words: Vascular graft – Collagen coating – Aortic aneurysm

High porosity knitted Dacron prostheses, compared to woven Dacron grafts, have shown better healing into the surrounding tissue and development of a thin and strongly attached inner capsule (1, 6, 7). In general, the main disadvantage of high porosity vascular grafts lies in their high permeability for blood which, during implantation, may result in severe bleeding from the graft's interstices. Preclotting of these grafts is time-consuming and may lead to increased usage of donor blood. Woven Dacron material, by contrast, can be preclotted more easily as a result of its lower porosity. There have been reports on long-term complications with this type of graft, however, with respect to both poor healing into the surrounding tissue and complications of the inner capsule, such as increasing thickness (1), tuft rhexis (2) and calcification (3). A graft of low porosity has been mandatory until now in spite of its disadvantages under certain clinical conditions requiring partial or total heparinization of the patient or in primary coagulopathies. Following our extensive experience with fibrin-sealed high porosity Dacron grafts in the presence of abnormal coagulation (2, 3, 4) we investigated a new collagen-coated knitted Dacron double-velour prosthesis[1]. This graft is coated with absorbable, cross-linked collagen, which has a zero porosity at the time of insertion. Following digestion of the collagen, healing properties supposedly should be identical to non-coated grafts due to its "healing porosity" of 1,400 cc/min/cm^2. The implantation of this type of graft seems to be indicated in any situation where coagulation disturbances are present.

Read at the 14th Annual Meeting of the German Society for Thoracic and Cardiovascular Surgery, Bad Nauheim 1985

Material and methods

Over a period of 12 months (12/1983 to 11/1984), collagen-coated double-velour knitted grafts were employed in 111 patients for aortic replacement (Table 1). The ages of the patients ranged between 30 and 88 years. Infrarenal aortic replacement for aneurysm was performed in 74 patients. Thirty-six patients underwent elective, and 38 patients emergency, operation. The graft was implanted in 4 cases of thoraco-abdominal aneurysm. Replacement of the descending thoracic aorta was performed in 13 patients. Indications included ruptured or symptomatic aortic aneurysm in 4 cases, elective replacement for descending aortic aneurysm in 6 cases, and treatment for type B aortic dissection in 3 cases. In the remaining 20 patients, the graft was used for occlusive arterial disease and/or aneurysmatic disease of the infrarenal aorta and iliac arteries as an aorto-femoral bifurcation graft (Table 1). In all but 2 cases, the operation was performed without the use of extracorporeal circulation, and partial heparinization (100 I.E./kg BW) was induced. Following completion of the proximal and distal anastomosis, protamin (1:1) was administered. Two patients operated on with the use of extracorporeal circulation were fully heparinized (300 I.E./kg BW). The graft inclusion technique as reported by *Crawford* (7) was employed in all cases with aortic aneurysms or dissection of the aorta. Anastomoses were performed using 4-0 or 3-0 polypropylene sutures (Fig. 1).

Postoperative follow-up was obtained 6 to 8 weeks after discharge from the hospital. Thereafter, follow-up studies were carried out every 6 months. The mean follow-up period was 6.2 months (range: 1 to 10 months).

Results

No problems were encountered when using the collagen graft with respect to technique of insertion and intraoperative handling although the graft is somewhat stiffer than the non-coated variety. Following declamping of the aorta or coming off cardiopulmonary bypass, all prostheses proved

[1] Hemashield®, Meadox Medical, Inc., Oakland, NY 07436, USA

Table 1 Diagnosis, age, and operative treatment in 111 patients with collagen-coated grafts

Diagnosis/Operation	No. of patients	Mean age (years)
Infrarenal aortic aneurysm	74	
– elective/symptomatic	52	64.4 (30–83)
– ruptured	22	68.4 (47–88)
Thoraco-abd. aortic aneurysm	4	63.7 (39–77)
Aneurysm of descending aorta	13	62.0 (45–73)
Bifurcation graft	20	56.2 (40–72)
Total	111	

Table 2 Mean aortic cross-clamp time, blood use during implantation, and hospital mortality in patients with replacement of infrarenal/thoracic aorta and with aortic bifurcation graft

Operation	No. of patients	Mean aortic cross-clamp time (min.)	Mean blood use (cc)	Mortality
Elective/semi-urgent replacement of infrarenal aorta	52	40	1,496	2 (3.8 %)
Emergency replacement of infrarenal aorta (rupture)	22	55	3,900	5 (22.7 %)
Replacement of descending aorta	13	32	1,520	4 (30.7 %)
Bifurcation graft	20	51	1,330	0

to be completely blood thight. In a few cases, minor stitch-hole bleeding could be observed but this always ceased spontaneously following administration of protamin.

The mean *aortic cross-clamp time* (Table 2) was 40 minutes for elective replacement of the infrarenal aorta, 55 minutes for replacement of ruptured infrarenal aortic aneurysms, 51 minutes for insertion of aortic bi-iliac/bi-femoral prostheses, and 32 minutes for replacement of the descending thoracic aorta (elective and emergency). *Blood use* was 1,496 ml for elective infrarenal aortic replacement and 3,900 ml for emergency replacement of the infrarenal aorta for ruptured aneurysm. Patients with implantation of aorto-bi-iliac bifurcation grafts had to be transfused with 1,330 ml blood, and 1,520 ml for both elective and emergency replacement of the descending aorta (Table 2).

Hospital mortality of all patients in this study (Table 2) was 11.7 % (13/111); elective aortic replacement for infrarenal aortic aneurysms had a zero mortality (0/36). The mortality of emergency replacement of ruptured (22.7 %), or symptomatic (12.5 %) aortic aneurysm was 18.4 % (7/38). There was no hospital mortality in patients with implantation of bifurcation grafts in arterial occlusive or aneurysmatic disease (0/20). The hospital mortality in patients with replacement of the descending aorta was 30.7 % (4/13) whereas 2 of the 4 patients with thoraco-abdominal aneurysms died. Causes of death were mainly related to cardiac and renal

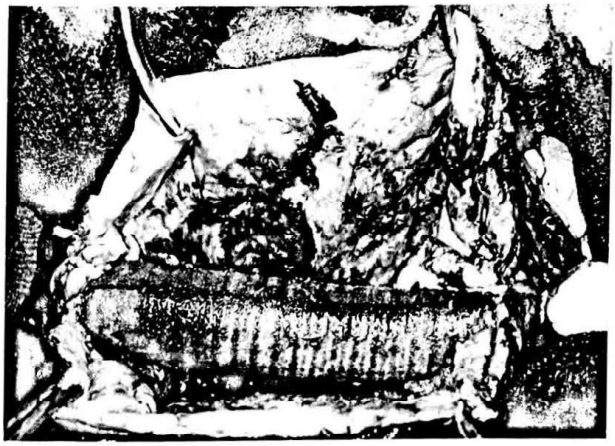

Fig. 1 Intraoperative view of a patient following replacement of infrarenal aorta for aortic aneurysm: the collagen-coated graft in situ

failure, or postoperative respiratory insufficiency. There was no evidence of bleeding or periprosthetic hematoma in any of the patients early or late following surgery; no re-intervention because of bleeding was necessary. Moreover, postoperative wound infection or prosthetic graft infection was not observed. Postoperative complications not related to the graft were observed in 2 cases: ventricular fibrillation occurred on postoperative day 5 which could be successfully treated in a 73-year-old patient, and a femoro-femoral bypass had to be inserted in the presence of occlusion of the left iliac artery following infrarenal aortic replacement in another case. In all surviving patients, the vascular grafts have proven to be patent and all patients are enjoying a normal life style.

Discussion

With the advent of fibrin adhesive for pre-treating high porosity vascular prostheses, the implantation of such grafts has become possible in situations where previously the use of low porosity woven material had been mandatory. This clinical trial was undertaken to study the early and long-term performance of collagen-coated double-velour knitted grafts. This high porosity knitted graft material has been coated with absorbable cross-linked bovine collagen resulting in zero porosity at the time of implantation. Experimental evidence has indicated that the collagen is absorbed during a 6- to 8-week period (5). Thereafter, the advantages of high porosity with respect to both incorporation into the surrounding tissue and its thin and well adhering inner capsule have become manifest. In view of these favorable results in animals, we performed this clinical study utilizing a patient population where systemic heparinization was employed or where coagulopathies had to be expected. Our preliminary experiences with this type of graft demonstrate its safe clinical application even under extracorporeal circulation and full heparinization. No blood loss was encountered in any of the patients following release of the cross-clamps. Moreover, operative handling of the material seems to be comparable to that of other grafts of similar fabrication and porosity.

Although no histological data have been obtained from our patient as yet, the clinical follow-up does not indicate graft complications such as occlusion, early or late bleeding, or impaired healing.

We conclude that collagen-coated knitted vascular grafts can be implanted safely in situations where woven grafts or knitted grafts presealed with fibrin adhesive have previously been employed. There was no evidence of short- or long-term complications. The use of this graft can be recommended for implantation even under extracorporeal circulation and/or full or partial heparinization. One disadvantage is seen in the fact that the presently manufactured grafts are of luxurious length. Excess graft cannot be resterilized which obviously adds to the price.

References

1 *Agarwal, K.C., W.D. Edwards, R.H. Feldt, G.K. Danielson, F. Puge,* and *D.C. McGoon:* Clinicopathological Correlates of Obstructed Rightsided Porcine-valved Extracardiac Conduits. J. Thorac. Cardiovasc. Surg. 81 (1981) 591

2 *Borst, H.G., A. Haverich, G. Walterbusch,* and *W. Maatz:* Fibrin Adhesive: An Important Hemostatic Adjunct in Cardiovascular Operations. J. Thorac. Cardiovasc. Surg. 84 (1982) 548

3 *Haverich, A., G. Walterbusch,* and *H.G. Borst:* The Use of Fibrin Glue for Sealing Vascular Prostheses of High Porosity. Thorac. cardiovasc. Surgeon 29 (1981) 252

4 *Haverich, A., W. Maatz,* and *G. Walterbusch:* Evaluation of Fibrin Seal in Animal Experiments. Thorac. Cardiovasc. Surgeon 30 (1982) 215

5 *Moore, W.S., M. Chvapil, G. Seiffert,* and *K. Keown:* Development of an Infection-resistant Vascular Prosthesis. Arch. Surg. 116 (1981) 1403

6 *Wesolowski, S.A., C.C. Fries, K.E. Karlson, M.E. DeBakey,* and *P.N. Sawyer:* Porosity: Primary Determinant of Ultimate Fate of Synthetic Vascular Grafts. Surg. 50 (1961) 91

7 *Wesolowski, S.A.:* Performance of Materials as Prosthetic Blood Vessels. Bul. N. Y. Acad. Med., Second Series 48 (1972) 331

Priv.-Doz. Dr. Thomas Stegmann, Klinik für Thorax-, Herz- und Gefäßchirurgie, Städtische Kliniken Fulda, Pacelliallee 4, D-6400 Fulda, FRG