Patent Owner's Ex. 2015, Page 1

N. Schoofs
J. Devière
A. Van Gossum

PillCam colon capsule endoscopy compared with colonoscopy for colorectal tumor diagnosis: a prospective pilot study

Background and aims: Colonoscopy is regarded as the gold standard for colorectal cancer (CRC) screening. PillCam capsule endoscopy could be an alternative approach for screening large populations. We report a pilot evaluation in humans of the safety, feasibility, and performance of colon capsule endoscopy compared with colonoscopy.

Patients and methods: Patients included in this single-center comparative study had presented for screening colonoscopy or there was suspicion of polyps or CRC. The capsule was ingested in the morning. After excretion, colonoscopy was performed. Significant findings were defined either as polyps > 6 mm, or three or more polyps of any size. Colonoscopy and colon capsule endoscopy (CCE) review were performed by independent physicians.

Results: 41 patients (26 women), mean age 56 years (range 26–75) were included, and all had complete colonoscopies. Four patients were excluded due to technical problems and one could not swallow the capsule; thus, 36 patients were considered in the analysis. In six the capsule had not been expelled at 10 hours and was retrieved endoscopically. CCE identified 19 of the 25 patients (76%) with positive findings and 10 of the 13 (77%) with significant lesions detected by colonoscopy. CCE detected seven lesions not seen at colonoscopy and two tumors were detected by both examinations. Overall sensitivity of CCE to detect significant lesions was 77%, specificity was 70%, positive predictive value was 59%, and negative predictive value was 84%. No adverse events occurred.

Conclusion: CCE showed promising accuracy compared with colonoscopy. This new noninvasive technique deserves further evaluation as a potential CRC screening tool.

Introduction

Colorectal cancer (CRC) is the leading cause of cancer-related mortality in the western world [1]. There is a compelling evidence that early diagnosis and treatment of adenomas and cancer reduces the disease-specific mortality [2]. Colonoscopy is currently considered to be the gold standard procedure for CRC screening. Unfortunately, many patients are reluctant to undergo this examination because of its perceived inconvenience and the discomfort [3,4]. Although the cost-effectiveness of any screening program is still debated, awareness of CRC is growing and novel screening modalities such as computed tomographic colonography, or "virtual colonoscopy", and fecal DNA testing are emerging [5]. Self-propelling visualization devices are currently under investigation with the aim of reducing operator dependence and complications as well as improving acceptance [6]. The ideal screening method for CRC should be noninvasive, safe, well accepted by the target population, cost-effective, and with a high diagnostic accuracy.

Following the success of video capsule endoscopy for exploring the small bowel, colon capsule endoscopy could be an attractive approach to mass CRC screening.

Indeed, capsule endoscopy of the small bowel has already been established as the initial diagnostic investigation of choice in patients with obscure gastrointestinal bleeding [7,8] and in patients with suspected small-bowel lesions. At this stage, sufficient

Institution
Department of Gastroenterology, Erasme University Hospital, Brussels, Belgium

Corresponding author
N. Schoofs, M.D. · Department of Gastroenterology · Erasme University Hospital · 1070 Brussels · Belgium · Fax: +32-2-555-4697 · E-mail: nschoofs@ulb.ac.be

Submitted 21 August 2006 · **Accepted after revision** 4 September 2006

Bibliography
Endoscopy 2006; 38 (10): 971–977 © Georg Thieme Verlag KG Stuttgart · New York · DOI 10.1055/s-2006-944835 · ISSN 0013-726X

screening yield cannot be achieved in the colon by the standard small-bowel capsule because of the anatomical and physiological properties of the colon. The PillCam Colon capsule (Given Imaging, Yoqneam, Israel) was designed specially for colon exploration and differs from the standard small-bowel capsule in three ways. First, it has two imagers that enable the device to acquire video images from both ends. Secondly, it has the same diameter as the PillCam SB capsule but is approximately 6 mm longer; this increased capsule length is dictated by the need to achieve a specific weight-to-volume ratio which allows the capsule to progress into the colon within the desired time frame (up to approximately 10 hours from ingestion). Thirdly, the PillCam Colon capsule can work at a higher frame rate (4 frames per second) and is able to operate with a pre-programmed delay mode in order to save energy until it reaches the colon.

The aims of the present pilot study were to provide preliminary evaluation of the performance and accuracy parameters of the PillCam Colon capsule compared with traditional colonoscopy, and to evaluate the efficacy of colon preparation for colon capsule endoscopy (CCE).

Patients and methods

Patient population

Patients were considered for the study if they were scheduled to undergo colonoscopy, for CRC screening with or without a personal or family history of colorectal polyps or cancer (41 %; n = 17), or for unexplained abdominal pain or alarm symptoms (including rectal bleeding and altered bowel transit time) (59 %; n = 24). They were included between January 12 2006 and June 1 2006, all having been referred to the endoscopy department of our institution.

Exclusion criteria were as follows: age younger than 18 years; presence of dysphagia, congestive heart failure, renal insufficiency, intestinal obstruction, or pacemaker or other implanted electromedical device; pregnancy; abdominal surgery in the past 6 months; inability to understand patient information and/or give informed consent; presence of a life-threatening condition; and current participation in another clinical study.

The medical ethics committee of our institution approved the study and all patients provided written informed consent.

Colon preparation

Patients underwent a 24-hour colon preparation that consisted of a clear liquid diet after a light breakfast the day before CCE. Between 18.00 and 21.00 in the evening before capsule ingestion, patients received 3 l of an oral preparation of polyethylene glycol osmotic solution (Colopeg; Roche Laboratories, Gaillard, France), and another litre of this solution between 06.00 and 07.00 on the day of the examination. After 2 hours and 15 minutes following capsule ingestion patients drank a first boost dose of 45 ml of Sodium phosphate solution (Fleet Phospho Soda®, Wolf, Fleet, Lynchburg; Virginia, USA), only if the capsule was shown to have exited the stomach, as assessed with real time viewing system performed with Rapid Access Real Time Tablet PC (by Given Imaging Inc.) If the capsule was not excreted following the first boost dose of sodium phosphate a second boost dose of 30 ml sodium phosphate solution was administered at 14.00 (3 hours and 45 minutes after the first one), at 15.00 patients had a small low fiber snack and energy drink (e.g. Red Bull®). By 15.30, if the capsule was still not excreted, a suppository of bisacodyl (Dulcolax®, Boehringer Ingelheim, Scherer, Aprilia, Italy) was administered. The preparatory steps are summarized in Figure **1**.

Diagnostic procedures

Colon capsule endoscopy (CCE). The PillCam Colon capsule has two imagers that enable the device to acquire video images from both ends. It is 31 × 11 mm in size, and acquires pictures at a rate of 4 frames per second. The pre-programmed delay mode allows recording of images from the esophagus and the stomach for 5 minutes before the capsule switches into sleep mode for 2 hours to save energy. (A 2-hour delay was observed to be the most appropriate for the PillCam Colon capsule for it to reactivate in the terminal ileum in human volunteers.) The envelope of the PillCam Colon capsule is made of biocompatible materials, sealed with biocompatible adhesives, and produced according to similar procedures and guidelines as the standard PillCam SB and PillCam ESO capsules. Data were recorded in an external recording unit that receives the information transmitted by the ingested capsule. The portable recorder consists of an antenna array which is attached to the body, a receiver, and memory for data recording during the examination. Upon completion of the examination, the physician or the study nurse downloads the data from the recorder to the RAPID workstation for processing. The data transmission are transmitted via a high capacity digital link.

Interpretation of the data was always done by a different physician from the one who performed the colonoscopy. Reading of the colon capsule data was always done in two steps, first examining the images taken from one side of the device and then the images taken from the other side. The selected reading speed was around 7 – 12 frames per second.

The location of polyps within the colon was done with the help of the rapid localization feature. Polyps were classified with respect to the following: size (greater than or equal to 6 mm, or smaller than 6 mm); confidence rate (high or low); morphology (pedunculated, sessile, or flat); colon segment location (rectum, sigmoid, descending colon, transverse colon, ascending colon, or cecum); colour (pale, mucosal, reddish, or yellow); position (between folds, on fold, proximal side of fold, distal side of fold, or unknown); and surface (smooth, nodular, or ulcerated). All this information was entered into a case report form by the physician who read the CCE images.

All detected polyps were recorded as positive findings. CCE findings were considered significant if there was a polyp greater than 6 mm in size, and/or more than three polyps, and/or a suspected tumor. Other lesions such as angiomas, diverticuli, lipomas, proctitis, and hemorrhoids were also noted but not considered as significant findings.

Occasionally, real-time viewing was done during the CCE procedure to determine the location (stomach, small bowel, or colon) of the capsule, thus avoiding fluoroscopy during the procedure. A real-time display platform based on a laptop was connected to

Patent Owner's Ex. 2015, Page 3

Time	Action
Day –1	
All day	Clear liquids only
18:00 – 21:00	3 Liters Colopeg® solution (1 cup every 10–15 minutes)
Exam Day[1)]	
06:00 – 07:00	1 Liter Colopeg® (1 cup every 10–15 minutes)
07:00	Fast until Boost #1 (with the exception of Domperidone (Motilium®) and PillCam™ COLON ingestions)
07:45	20mg Domperidone (Motilium®) (with a cup of water)
08:00	PillCam™ COLON ingestion (with a cup of water)
10:00	Boost #1[2)]: 45 ml oral sodium phosphate (Fleet Phospho-Soda®) + 1 Liter water
14:00	Boost #2: 30ml oral sodium phosphate (Fleet Phospho-Soda®) + 1 Liter water
15:00	Optional light snack (low fiber) Fast until conventional colonoscopy procedure
16:30	10mg Bisacodyl (Dulcolax®) rectal suppository
19:00	Conventional colonoscopy performed

1) Colon preparation and procedure on day of PillCam™ COLON examination was performed on-site. When PillCam™ COLON was excreted early, the regimen was discontinued and patient was prepared for conventional colonoscopy.

2) The timing of Boost #1 was delayed if PillCam™ COLON was delayed in the stomach for longer than 2 hours post ingestion as detected with real-time viewing performed with Rapid Access Real Time Tablet PC (by Given Imaging Inc.).
– If PillCam™ COLON had moved out of the stomach, the colon regimen was continued as describe above.
– If PillCam™ COLON was delayed in the stomach, Boost #1 was administered only when PillCam™ COLON was found by real-time viewing to have moved out of the stomach and the regimen related to Boost #2 and Bisacodyl suppository changed forward as follows:

If Boost #1 was administered during the time period indicated below	Then Boost #2 was administered at the time indicated below	And Bisacodyl suppository was administered at the time indicated below
10:00–11:00	14:00	16:30
11:00–12:00	Time of 1st boost + 3 hours	16:30
12:00–13:00	Time of 1st boost + 3 hours	17:00
13:00–14:00	Time of 1st boost + 3 hours	No suppository
14:00–16:00	No Boost #2	No suppository
No boosts and suppository if PillCam™ COLON stayed in stomach after 16:00		

Figure **1** PillCam® COLON preparation and procedure regimen.

the data recorder that was carried by the patient. In this way, the video images that were transmitted by the device were displayed in real time on the screen.

Colonoscopy. Patients underwent colonoscopy with a standard colonoscope (CF-160; Olympus, Tokyo, Japan) at the endoscopy department in the one-day clinic at our institution. The endoscopic procedure was done after expulsion of the capsule or when the battery was exhausted. All colonoscopies were performed by an experienced endoscopist, with the patient under general anesthesia with propofol (Diprivan; Astra Zeneca, Sweden) and without endotracheal intubation. All examinations were recorded on videotape and still pictures were taken and recorded on the Endobase system (Olympus, Tokyo, Japan).

During colonoscopy the endoscopist classified polyps, if present, with respect to size; distance from the anal margin; morphology (pedunculated, sessile, flat); location (rectum, sigmoid, descending colon, transverse, ascending colon, or cecum); colour (pale, mucosal, reddish, or yellow); position (between folds, on fold, proximal side of fold, distal side of fold, or unknown); and surface (smooth, nodular, or ulcerated). All this information was entered into a case report form by the physician who performed the examination.

Further data. At the end of the colonoscopy patients were questioned about comfort and possible inconvenience regarding each technique. Adverse events for both procedures were documented. In the case of positive CCE with negative colonoscopy, the study protocol did not envisage a second colonoscopy.

Data analysis

The CCE and colonoscopy examinations were carried out by two independent physicians, each of whom was blinded to the results of the other procedure. The potential role of a noninvasive screening method is to select patients with polyps who might benefit from therapeutic endoscopy. Although some experts recommend that only polyps that are 10 mm or more in size should be removed, we defined as a "significant finding" the presence of either a polyp greater than 6 mm or of three or more lesions of any size, or a tumor. In addition, all polyps of any size were noted as positive findings.

For all the defined lesions we calculated the "per patient" sensitivity, the specificity, and the positive predictive value (PPV) and negative predictive value (NPV) of CCE in comparison with colonoscopy.

Other lesions such as angiomas, diverticula, lipomas, proctitis and hemorrhoids were also noted but not considered in the anal-

ysis. The colon cleansing level was rated for the CCE and for colonoscopy, using a scale of 1 to 4 (poor, fair, good, and excellent) for each section of the colon, according to the Minimal Standard Terminology of digestive endoscopy [9]. An interobserver agreement study was done by two independent physicians.

Although it was not regarded as an initial aim of this study, the description of the lower esophagus and the Z line was done for all patients.

Statistical analysis

Descriptive statistics were expressed as the median and range values for continuous variables. Percentage values are rounded off to the nearest whole number. We considered the colonoscopy to be the gold standard against which CCE was compared. The diagnostic yield of CCE was assessed, and sensitivity, specificity, positive and negative predictive values (PPV and NPV) per patient were calculated. Statistical analyses were done with SPSS software, version 11.0 (SPSS Inc., Chicago, Illinois, USA) and CIA (Confidence Interval Analysis) software, version 2.0.0 (Trevor N. Bryant 2000, Southampton, UK).

Interobserver agreement analysis was carried out by two independent reviewers for each detected lesion. We assessed the presence and the number of significant findings. Reviewers were considered to agree on a finding according to the size, location, and timing of reviewing of the recordings. Kappa statistics with 95% confidence intervals were calculated.

Results

Baseline characteristics

Between January 12 2006 and June 1 2006, 41 patients (26 women; mean age 56 years, range 26–75) agreed to participate in the study and were referred to the endoscopy unit for colonoscopy preceded by CCE. Three patients out of the first five in the series were excluded from the data analysis due to technical problems: re-activation of the capsule occurred late or not at all, so less than 30% of the colon was visualized. One patient could not swallow the capsule because of excessive anxiety; this patient underwent only colonoscopy. Finally, another patient underwent both examinations, but reading of the CCE images was hindered by technical problems in the data transmission from the recorder to the workstation. Therefore, 36 patients were finally included in the study.

CCE findings

No adverse events were documented. In six patients (16%) the capsule was not expelled at the end of the recording time (10 hours); at that time, the capsule was located in the cecum in one patient, the transverse colon in one patient, the sigmoid in three, and the rectum in one patient. In these patients the capsule was retrieved using a snare during colonoscopy.

The mean time taken to read the CCE images was 62 minutes (range 45–90 minutes), with a speed range of 7–12 frames per second. All the PillCam Colon capsules passed the stomach, and 35 of them (97%) re-activated in time, before reaching the ileocecal valve. The overall preparation was evaluated as excellent in 30% of cases, as good in 58%, as fair in 6%, and as poor in 3%.

Table **1** Findings of PillCam Colon capsule endoscopy and colonoscopy in the study population (n = 36)

	Positive colonoscopy, n	*Negative colonoscopy, n*
Any findings		
CCE positive	19	4
CCE negative	6	7
Polyps > 6 mm		
CCE positive	6	7
CCE negative	4	19
≥ 3polyps		
CCE positive	5	9
CCE negative	3	19
Polyp > 6 mm or ≥ 3 polyps		
CCE positive	10	7
CCE negative	3	16

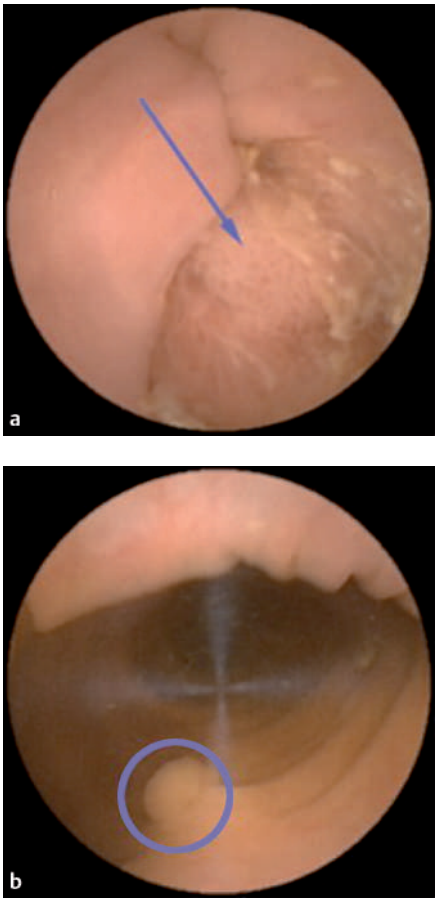

Figure **2** PillCam Colon capsule endoscopy images: **a** a tumor; and **b** a polyp.

CCE findings were positive in 23 patients and negative in 13 patients (details are provided in Table **1**). Apart from polyps (Figure **2**), several types of lesions were observed and documented, such as angiomas (n = 1), melanosis coli (n = 3), diverticuli (n = 25), proctitis (n = 1) and the India-ink injection site from a previous polypectomy (n = 1), but these were not considered when reporting the results of this study (Figure **3**).

Interobserver agreement with regard to significant lesions was 80.5%.

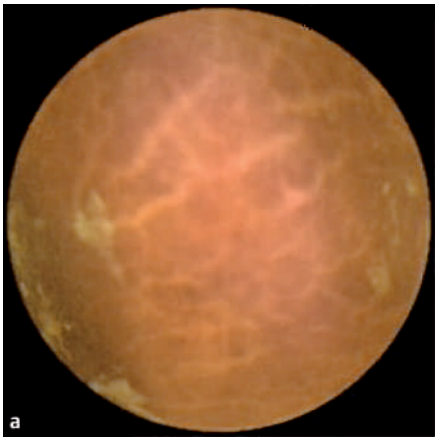

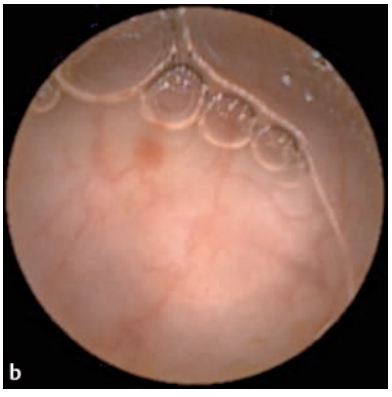

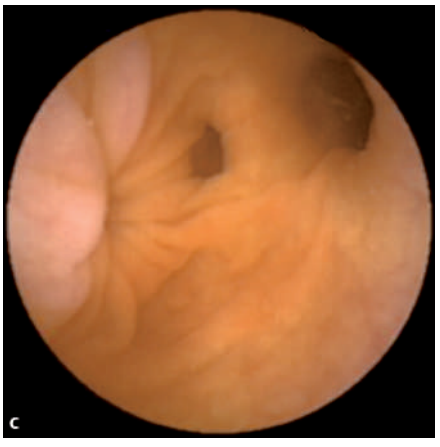

Figure **3** Colon capsule endoscopy (CCE) images: **a** melanosis coli; **b** angioma; and **c** diverticuli.

Figure **4** CCE image of the Z-line.

Colonoscopy

Complete colonoscopy, including examination of the cecum, was achieved in all cases. All procedures were successfully performed with all the patients under general anesthesia without intubation, except for one who had severe chronic obstructive lung disease. There were no adverse events. Each colonoscopy was performed the same day as the CCE, after excretion of the capsule or when recording of images had stopped.

Colonoscopy showed positive findings in 25 patients, and was negative in 11 patients (details are provided in Table **1**).

A subjective assessment questionnaire was given to each patient after colonoscopy and complete resposes were obtained from 33 patients. Three patients (9 %) described colonoscopy under general anesthesia as more comfortable than CCE.

Comparison of PCCE and colonoscopy

CCE was negative in six out of 25 patients with positive colonoscopic findings, but was positive in four patients with negative colonoscopy.

Regarding the presence of a polyp greater than 6 mm in size, CCE was negative in four out of 10 patients with positive findings and was positive in seven out of 26 patients with negative findings at colonoscopy. A second reading of the recordings of the false-negative CCEs allowed identification of a bigger than 6 mm polyp in only one of the four patients; the size of this polyp was initially considered to be less than 6 mm.

Concerning detection of at least three polyps, CCE was negative in three out of eight patients with positive colonoscopy findings, and positive in nine out of 28 patients with negative colonoscopy. The patient sensitivity, specificity, and the positive and negative predictive values for the CCE regarding positive findings and the significant finding are detailed in Tables **2–4**. Interestingly, for polyps larger than 6 mm in size, the positive predictive value and the negative predictive value were 46 % and 83 %, respectively.

Esophageal data

The lower esophagus as well as the Z-line were well visualized in 60 % of the 36 patients (Figure **4**).

Discussion

The main message to be taken from this study is that CCE with the PillCam Colon capsule is feasible, and can provide good quality images of the entire colon and can detect polyps and tumors in the majority of cases. This was achieved by both technical development of the capsule itself and adaptations of the bowel preparation. The presence of two imagers undoubtedly enhances the capabilities for detection, since some of the polyps we observed were visible only on one side of the recorder. The pre-programmed delay mode was a partial solution to the problem of battery life duration, and it appeared that the 2-hour inactive period, calculated on the basis of data collected in previous studies with healthy participants, was adequate for patients since all but one colon capsule re-activated before reaching the cecum. Complete visualization of the colon was not achieved before the

Table 2 Diagnostic discrimination, with 95% confidence interval (95% CI), of PillCam Colon capsule endoscopy, for detecting three polyps or more in the study population (n = 36)

	%	95% CI, %
Sensitivity	63	29 – 96
Specificity	68	51 – 85
Positive predictive value	36	11 – 61
Negative predictive value	86	72 – 101

Table 3 Diagnostic discrimination of colon capsule endoscopy (CCE), for any findings* in the study population (n = 36)

	%	95% CI, %
Sensitivity	76	59 – 93
Specificity	64	35 – 92
Positive predictive value	83	67 – 98
Negative predictive value	54	27 – 81

* Any findings, i.e. all kinds of polyps.

Table 4 Diagnostic discrimination of CCE, for polyps larger than 6 mm in size in the study population

	%	95% CI, %
Sensitivity	60	30 – 90
Specificity	73	56 – 90
Positive predictive value	46	19 – 73
Negative predictive value	83	67 – 98

end of battery life in 16% of the patients, however, underlining the need for further improvement.

The colonic preparation was adapted not only to clean the colon but also to facilitate the progression of the capsule, with the administration of one or two boosts of sodium phosphate. Excellent or good preparation for CCE was achieved in 90% of cases. All the patients tolerated the preparation without any significant complaint. The present study was notable in that all the patients underwent the same preparation for both examinations, which were performed on the same day. This was an important point for assuring uniformity and comparability of the two techniques. Some additional fine tuning of the preparation might help to avoid the presence of opaque liquid that compromises complete visualization during CCE.

Standard colonoscopy was regarded as the gold standard in our study. Despite this being a pilot study, and given our lack of previous experience in reading colon capsule images, significant lesions (an indication for therapeutic colonoscopy) were detected with high levels of sensitivity and specificity (77% and 70%). The negative predictive value (84%) is the highest and this is potentially important since one of the aims of such an examination would be to obviate the need for additional examination by standard colonoscopy. These values have to be put alongside those of colonoscopy itself, when performed two times. A recent review of six studies reporting two same-day colonoscopies reported miss rates of 13% and 26% for adenomas of 5 – 10 mm and 1 – 5 mm, respectively [10]. Also CCE identified lesions which were not seen at colonoscopy (in four patients who had no findings at all at colonoscopy). The PillCam Colon capsule takes images from both its ends, perhaps improving visualization of lesions located "behind the folds", which are easily missed during colonoscopy. Even polyps larger than 6 mm in size were detected in seven patients in whom colonoscopy had failed to detect them. These discrepancies could also be due to a difference in size assessment at colonoscopy and CCE, with a possible overestimation associated with the latter. An accurate evaluation of missed lesions, either by colonoscopy or CCE, would imply the need to repeat colonoscopy (after analysis of the CCE) in every patient having any findings seen only by CCE.

The interobserver agreement for PCCE was 80%, suggesting that there is still room for improvement and that a learning curve will be mandatory. The current levels of sensitivity and specificity are encouraging when compared with those of virtual computed tomography (CT) colonoscopy (in two major series the reported negative predictive values were 98% and 91% [11,12]), or those of colonoscopy itself (a tandem colonoscopy study by Rex et al. showed that the first colonoscopy has a negative predictive value of only 84% for detecting adenomas of any size) [13]. Two multicentric studies are planned in order to further evaluate the accuracy of CCE compared with colonoscopy for screening CRC.

Compared with other techniques of virtual colonoscopy, such as CT or magnetic resonance imaging (MRI), CCE is different in that size is not a limitation for detection since very small lesions are clearly visible. After having carried out these examinations we realized that among all the screening techniques currently available, CCE is the only one that could be performed by patients themselves without the intervention of a physician, provided that clear explanation could be offered. This could therefore be proposed as a test to be carried out at home, and improve the acceptance for mass screening.

Finally, although we did not ask the patients to swallow the capsule while in the decubitus position as is done in PillCam esophageal studies, the Z-line was clearly visualized in 60% of cases. The investigation of this finding in further studies is obviously justified, since the population who may benefit from CRC screening may coincide to some extent with the population for whom detection of Barrett's esophagus might be useful [14].

In conclusion, this pilot study evaluating CCE done on the same day as colonoscopy shows that it is feasible, allows the examination of the entire colon in the majority of cases, and provides encouraging sensitivity and negative predictive values for detection of significant lesions. Further studies are needed to confirm this accuracy, the technique being potentially also useful for detection of Barrett's esophagus.

Acknowledgments

This study was supported by Given Imaging.

In brief
Colon capsule pilot trial from a single center on 36 cases (5 excluded due to technical reasons) with 77% sensitivity and 70% specificity when compared to colonoscopy performed the same day with the same colon preparation. Further progress can be awaited.

The authors thank Erik Francois for critical review of the manuscript, Marianna Arvanitaki for helpful discussions, Philippe Golstein for recruiting patients and performing endoscopies, Nele Dustin and Marianne Defevrimont for the general anesthesia of the patients during colonoscopy, and Sabine Luyckx, Valerie Wambacq, Graziella Viste, and Martine Mahieu for their nursing of the patients during endoscopy and recovery.

Competing interests: The study was supported by Given Imaging.

References

[1] Steward BW, Kleihues P. Colorectal cancer. World Cancer Report. Lyon: IARC Press, 2003: 198 – 202
[2] Pignone M, Rich M, Teutsch SM et al. Screening for colorectal cancer in adults at average risk: a summary of the evidence for the US Preventive Services Task Force. Ann Intern Med 2002; 137: 132 – 141
[3] Rex DK, Johnson DA, Lieberman DA et al. Colorectal cancer prevention 2000: Screening recommendations of the American College of Gastroenterology. Am J Gastroenterol 2000; 95: 868 – 877
[4] Levin TR, Conell C, Shapiro JA et al. Complications of screening flexible sigmoidoscopy. Gastroenterology 2002; 123: 1786 – 1792
[5] Ladabaum U, Song K. Projected national impact of colorectal cancer screening on clinical and economic outcomes and health services demand. Gastroenterology 2005; 129: 1151 – 1162
[6] Vucelic B, Rex D, Pulanic R et al. The Aer-O-Scope: proof of concept of a pneumatic, skill-independent, self-propelling, self-navigating colonoscope. Gastroenterology 2006; 130: 672 – 677
[7] Hartmann D, Schmidt H, Bolz G et al. A prospective two-center study comparing wireless capsule endoscopy with intraoperative enteroscopy in patients with obscure GI bleeding. Gastrointest Endosc 2005; 61: 826 – 832
[8] Van Gossum A, Hittelet A, Schmit A et al. A prospective comparative study of push and wireless capsule enteroscopy in patients with obscure digestive bleeding. Acta Gastroenterol Belg 2003; 66: 199 – 125
[9] Delvaux M, Korman L. Minimal Standard Terminology in digestive endoscopy. Endoscopy 2000; 32: 162 – 188
[10] van Rijn JC, Reitsma JB, Stoker J et al. Polyp miss rate determined by tandem colonoscopy: a systematic review. Am J Gastroenterol 2006; 101: 343 – 350
[11] Iannaconne R, Catalano C, Mangiapane F et al. Colorectal polyps: detection with low-dose multi-detection row helical CT colonography versus two sequential colonoscopies. Radiology 2005; 237: 327 – 337
[12] Van Gelder RE, Nio CY, Florie J et al. Computed tomographic colonography compared with colonoscopy in patients at increased risk for colorectal cancer. Gastroenterology 2004; 127: 41 – 48
[13] Rex DK, Cutler CS, Lemmel GT et al. Colonoscopy miss rates of adenomas determined by back-to-back colonoscopy. Gastroenterology 1997; 112: 292 – 294
[14] Gerson LB, Shetler K, Triadafilopoulos G. Prevalence of Barrett's oesophagus in asymptomatic individuals. Gastroenterology 2002; 123: 461 – 457