National Comprehensive Cancer Network®

NCCN Clinical Practice Guidelines in Oncology (NCCN Guidelines®)

Occult Primary

(Cancer of Unknown Primary [CUP])

Version 2.2025 — September 11, 2024

NCCN.org

NCCN recognizes the importance of clinical trials and encourages participation when applicable and available. Trials should be designed to maximize inclusiveness and broad representative enrollment.

Continue

Version 2.2025, 09/11/2024 © 2024 National Comprehensive Cancer Network® (NCCN®), All rights reserved. NCCN Guidelines® and this illustration may not be reproduced in any form without the express written permission of NCCN.

MERCK EX1276
Merck Sharp & Dohme LLC v. The Johns Hopkins University
IPR2024-00622

Printed by Elizabeth Moore on 4/30/2025 10:21:39 AM. For personal use only. Not approved for distribution. Copyright © 2025 National Comprehensive Cancer Network, Inc., All Rights Reserved.

***Marvaretta M. Stevenson, MD/Chair †**
Duke Cancer Institute

***Daniel W. Bowles, MD/Vice Chair †**
University of Colorado Cancer Center

Omar Abughanimeh, MBBS Þ † ‡
Fred & Pamela Buffett Cancer Center

Daniel Ahn, DO ‡
Mayo Clinic Comprehensive Cancer Center

Salwan Al Mutar, MD, MS †
UT Southwestern Simmons Comprehensive Cancer Center

David Bajor, MD †
Case Comprehensive Cancer Center/ University Hospitals Seidman Cancer Center and Cleveland Clinic Taussig Cancer Institute

Sam Brondfield, MD, MA †
UCSF Helen Diller Family Comprehensive Cancer Center

Julie Bykowski, MD ϕ
UC San Diego Moores Cancer Center

Keith D. Eaton, MD, PhD † Þ
Fred Hutchinson Cancer Center

David Gierada, MD ϕ
Siteman Cancer Center at Barnes-Jewish Hospital and Washington University School of Medicine

Angela Jain, MD †
Fox Chase Cancer Center

Aparna Kalyan, MD †
Robert H. Lurie Comprehensive Cancer Center of Northwestern University

Zachary Kohutek, MD, PhD §
Vanderbilt-Ingram Cancer Center

Christina Kong, MD ≠
Stanford Cancer Institute

Jeremy Kortmansky, MD †
Yale Cancer Center/Smilow Cancer Hospital

John Kosteva, MD †
Abramson Cancer Center at the University of Pennsylvania

Anuradha Krishnamurthy, MD †
Roswell Park Comprehensive Cancer Center

Richard T. Lee, MD † £
City of Hope National Medical Center

Renato Lenzi, MD ‡
The University of Texas MD Anderson Cancer Center

Sam Lubner, MD †
University of Wisconsin Carbone Cancer Center

Alyssa Marr, MD †
Fred & Pamela Buffett Cancer Center

Nicholas McAndrew, MD, MSCE †
UCLA Jonsson Comprehensive Cancer Center

Mateusz Opyrchal, MD, PhD †
Indiana University Melvin and Bren Simon Comprehensive Cancer Center

Darryl Outlaw, MD ‡ †
O'Neal Comprehensive Cancer Center at UAB

Anuj Patel, MD †
Dana-Farber/Brigham and Women's Cancer Center | Mass General Cancer Center

John Phay, MD ¶
The Ohio State University Comprehensive Cancer Center - James Cancer Hospital and Solove Research Institute

Asif Rashid, MD ≠
The University of Texas MD Anderson Cancer Center

Kerry Reynolds, MD ‡
Mass General Cancer Center

Stephen Rosenberg, MD, MS §
Moffitt Cancer Center

Jeffery Russell, MD, PhD, MBA †
Huntsman Cancer Institute at the University of Utah

Leonard Saltz, MD † Þ ‡
Memorial Sloan Kettering Cancer Center

Namrata Setia, MD ≠
University of Chicago Medicine Comprehensive Cancer Center

Jeffrey B. Smerage, MD, PhD ‡ †
University of Michigan Rogel Cancer Center

Siao-Yi Wang, MD, PhD †
UC Davis Comprehensive Cancer Center

NCCN
Emily Kovach
Megan Lyons, MS

Continue

ϕ Diagnostic/Interventional radiology
‡ Hematology/Hematology oncology
Þ Internal medicine
† Medical oncology
≠ Pathology
§ Radiotherapy/Radiation oncology
£ Supportive care including palliative, pain management, pastoral care, and oncology social work
¶ Surgery/Surgical oncology
* Discussion section committee member

NCCN Guidelines Panel Disclosures

Version 2.2025, 09/11/2024 © 2024 National Comprehensive Cancer Network® (NCCN®), All rights reserved. NCCN Guidelines® and this illustration may not be reproduced in any form without the express written permission of NCCN.

Printed by Elizabeth Moore on 4/30/2025 10:21:39 AM. For personal use only. Not approved for distribution. Copyright © 2025 National Comprehensive Cancer Network, Inc., All Rights Reserved.

NCCN Occult Primary Panel Members
Summary of the Guidelines Updates

Initial Evaluation (OCC-1)

Epithelial Occult Primaries (OCC-2)

Adenocarcinoma or Carcinoma Not Otherwise Specified (OCC-3)

Squamous Cell Carcinoma (OCC-11)

Follow-up for All Occult Primaries (OCC-15)

Immunohistochemistry/In Situ Hybridization Markers for Unknown Primary Cancers (OCC-A)

Principles of Systemic Therapy (OCC-B)

Principles of Radiation Therapy (OCC-C)

Principles of Genetic/Familial Cancer Risk Assessment and Counseling (OCC-D)

Abbreviations (ABBR-1)

Find an NCCN Member Institution: https://www.nccn.org/home/member-institutions.

NCCN Categories of Evidence and Consensus: All recommendations are category 2A unless otherwise indicated.

See NCCN Categories of Evidence and Consensus.

NCCN Categories of Preference: All recommendations are considered appropriate.

See NCCN Categories of Preference.

The NCCN Guidelines® are a statement of evidence and consensus of the authors regarding their views of currently accepted approaches to treatment. Any clinician seeking to apply or consult the NCCN Guidelines is expected to use independent medical judgment in the context of individual clinical circumstances to determine any patient's care or treatment. The National Comprehensive Cancer Network® (NCCN®) makes no representations or warranties of any kind regarding their content, use or application and disclaims any responsibility for their application or use in any way. The NCCN Guidelines are copyrighted by National Comprehensive Cancer Network®. All rights reserved. The NCCN Guidelines and the illustrations herein may not be reproduced in any form without the express written permission of NCCN. ©2024.

Printed by Elizabeth Moore on 4/30/2025 10:21:39 AM. For personal use only. Not approved for distribution. Copyright © 2025 National Comprehensive Cancer Network, Inc., All Rights Reserved.

Updates in Version 2.2025 of the NCCN Guidelines for Occult Primary from Version 1.2025 include:

MS-1
• The discussion section has been updated to reflect the changes in the algorithm.

Updates in Version 1.2025 of the NCCN Guidelines for Occult Primary from Version 2.2024 include:

Global
• References updated throughout document.
OCC-1
• Initial evaluation, bullet 1: Complete H&P, including breast, genitourinary, pelvic, ~~and~~ rectal*, skin, and/or oral cavity* exam *as appropriate,* with attention to...
• Workup:
  ▸ Bullet removed: Gene sequencing to predict tissue of origin is not recommended.
  ▸ Bullet added: Tissue of origin studies are not recommended.
OCC-1A
• Footnote d, references added.
OCC-3
• Header added: Histologic Diagnosis. (also for OCC-4, OCC-5, OCC-6, OCC-8, OCC-9, OCC-10, OCC-11, OCC-13, and OCC-14)
• Footnote k modified: Symptom-directed endoscopy, ~~such as endoscopy,~~ can be considered... (also for OCC-4, OCC-5, OCC-6, and OCC-11)
OCC-8
• Mediastinum algorithm text removed:
  ▸ Consider additional consultation with pathologist to determine if further analysis would be helpful.
OCC-11
• Supraclavicular nodes, additional workup, bullet added: Endoscopy as indicated.
OCC-A (1 of 5)
• Header modified: Potential Immunohistochemistry*/In Situ Hybridization* Markers for Unknown Primary Cancers
• Subheading modified: *Communication between the clinician and the pathologist is essential for the workup to direct the staining pattern to the clinical differential diagnosis. The pathologist should select a focused panel of IHC or ISH markers, and avoid a large series of markers. IHC and ISH* markers for unknown primary cancers are provided as a resource to assist in localizing a primary but are not uniformly specific or sensitive. ~~Avoid a large series of immunohistochemistry markers. Communication with the pathologist is essential to workup.~~
OCC-A (4 of 5)
• Neuroendocrine carcinoma, other positive markers: CD56 removed.
OCC-B (all)
• Pages extensively revised.
OCC-B (2 of 14)
• Repotrectinib added as a Useful in Certain Circumstances regimen for NTRK gene fusion-positive tumors. (Also for OCC-B [8 of 14])
OCC-C
• General principles, dosing regimen modified: (48-60 Gy */-in* 4–5 fractions).

Version 2.2025, 09/11/2024 © 2024 National Comprehensive Cancer Network® (NCCN®), All rights reserved. NCCN Guidelines® and this illustration may not be reproduced in any form without the express written permission of NCCN.

Printed by Elizabeth Moore on 4/30/2025 10:21:39 AM. For personal use only. Not approved for distribution. Copyright © 2025 National Comprehensive Cancer Network, Inc., All Rights Reserved.

INITIAL EVALUATION[b]

Suspected metastatic malignancy[a]

- Complete history and physical (H&P), including breast, genitourinary, pelvic, rectal, skin, and/or oral cavity exam as appropriate, with attention to and review of:
- Past biopsies or malignancies
- Removed lesions
- Spontaneously regressing lesions
- Existing imaging studies
- Calcium
- Complete blood count (CBC)
- Creatinine
- Electrolytes
- Hemoccult test as indicated
- Lactate dehydrogenase (LDH) as indicated
- Liver function tests (LFTs)
- Urinalysis as indicated
- Chest/abdomen/pelvis CT[c] scan
- Clinically directed endoscopy, as indicated

WORKUP

Biopsy[d]:
- Core needle biopsy (preferred) and/or fine-needle aspiration (FNA) with cell block of most accessible site
- Consult pathologist for adequacy of specimen and additional studies including immunohistochemical (IHC) stains[e]
- Tumor mutational burden (TMB) determination by a validated and/or FDA-approved assay (category 2B)[f]
- Microsatellite instability (MSI)/mismatch repair (MMR) testing[g]
- Molecular profiling of tumor tissue using next-generation sequencing (NGS) (or other technique to identify gene fusions) can be considered after an initial determination of histology has been made[h]
- Tissue of origin studies are not recommended[i]

PATHOLOGIC DIAGNOSIS

- Epithelial; not site specific or poorly differentiated neoplasm → Clinical Presentation (OCC-2)
- Lymphoma and other hematologic malignancies → See NCCN Guidelines Treatment by Cancer Type
- Thyroid carcinoma → See NCCN Guidelines for Thyroid Carcinoma
- Melanoma → See NCCN Guidelines for Melanoma: Cutaneous
- Sarcoma → See NCCN Guidelines for Soft Tissue Sarcoma
- Germ cell tumor → See NCCN Guidelines for Testicular Cancer
- Nonmalignant diagnosis → Further evaluation and Appropriate follow-up

Note: All recommendations are category 2A unless otherwise indicated.

Footnotes on OCC-1A

Version 2.2025, 09/11/2024 © 2024 National Comprehensive Cancer Network® (NCCN®), All rights reserved. NCCN Guidelines® and this illustration may not be reproduced in any form without the express written permission of NCCN.

Printed by Elizabeth Moore on 4/30/2025 10:21:39 AM. For personal use only. Not approved for distribution. Copyright © 2025 National Comprehensive Cancer Network, Inc., All Rights Reserved.

FOOTNOTES

[a] For many patients the apparent uncertainties surrounding the diagnosis of an unknown primary cancer may result in significant psychosocial distress and increased difficulty in accepting treatment options. Empathetic discussion about the natural history of these types of cancer and their prognosis, and the provision of support and counseling both by the primary oncology team and specialized services may help to alleviate this distress. See NCCN Guidelines for Distress Management.

[b] Testing for some tumor markers such as serum CA-125, CA 19-9, and CA 15-3 may be useful in certain circumstances, but are not diagnostic and caution must be exercised in their interpretation.

[c] CT should be performed with contrast and MRI should be performed with and without IV contrast unless contraindicated. FDG-PET/CT is an alternative in patients with a contraindication to contrast enhancement.

[d] If available, the pathologist should be involved with the biopsy to provide rapid on-site evaluation (ROSE) to confirm adequate sampling of the lesion and to perform specimen triage including cell block with immediate formalin fixation, flow cytometry, and other ancillary studies as needed. Sauter JL, et al. J Am Soc Cytopathol 2020;9:570-578; VanderLaan PA, et al. J Am Soc Cytopathol 2019;8:333-341.

[e] Immunohistochemistry/In Situ Hybridization Markers for Unknown Primary Cancers (OCC-A).

[f] Merino DM, et al. J Immunother Cancer 2020;8:e000147.

[g] The population of patients with MSI-high/MMR-deficient (MSI-H/dMMR) occult primary tumors is low. Use IHC for MMR or polymerase chain reaction (PCR) for MSI, which are different assays measuring the same biological effect.

[h] Consider tumor/somatic molecular profiling for patients who are candidates for anti-cancer therapy to identify uncommon mutations (ie, *RET* fusions). Testing on tumor tissue is preferred; however, cell-free DNA testing can be considered if tumor tissue testing is not feasible.

[i] Hayashi H, et al. J Clin Oncol 2019;37:570-579.

Note: All recommendations are category 2A unless otherwise indicated.

Version 2.2025, 09/11/2024 © 2024 National Comprehensive Cancer Network® (NCCN®), All rights reserved. NCCN Guidelines® and this illustration may not be reproduced in any form without the express written permission of NCCN.

Printed by Elizabeth Moore on 4/30/2025 10:21:39 AM. For personal use only. Not approved for distribution. Copyright © 2025 National Comprehensive Cancer Network, Inc., All Rights Reserved.

PATHOLOGIC DIAGNOSIS | **CLINICAL PRESENTATION[j]**

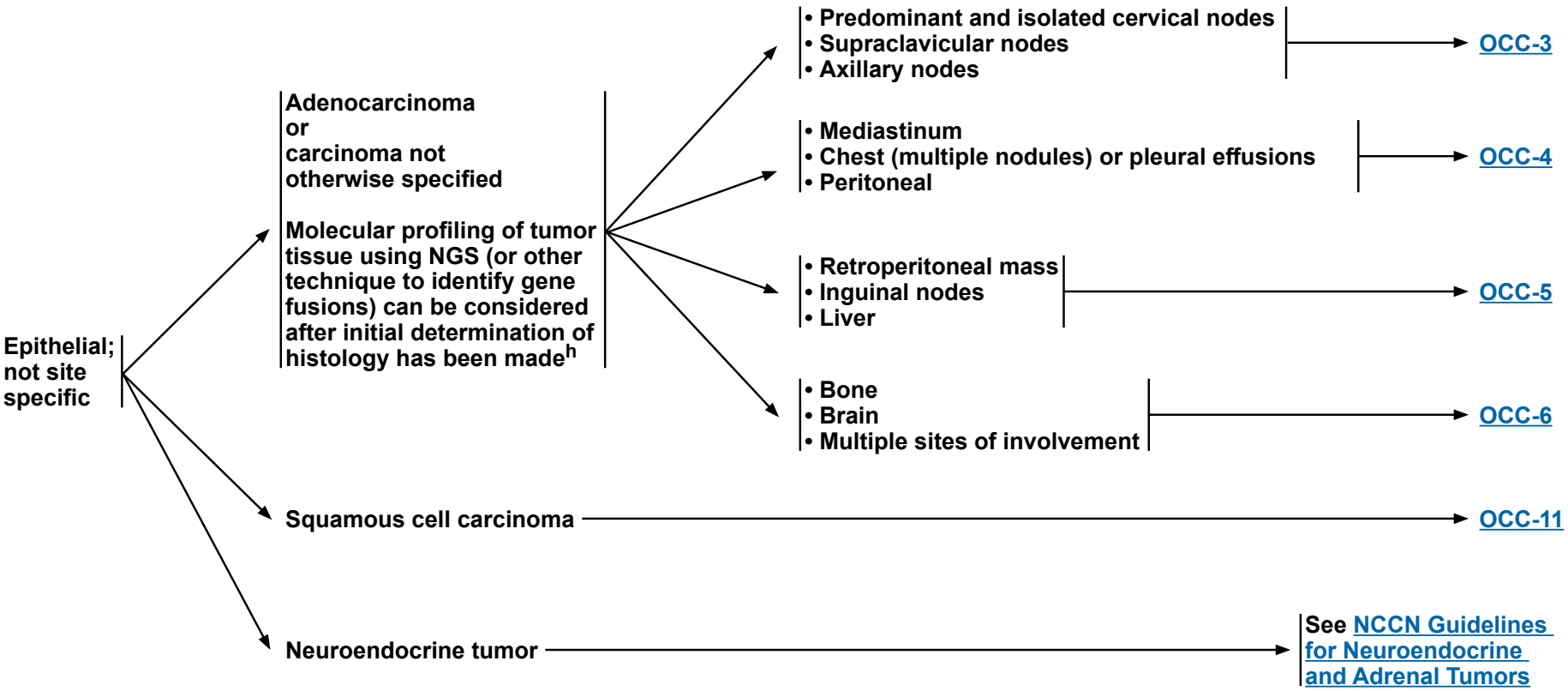

[h] Consider tumor/somatic molecular profiling for patients who are candidates for anti-cancer therapy to identify uncommon mutations (ie, *RET* fusions). Testing on tumor tissue is preferred; however, cell-free DNA testing can be considered if tumor tissue testing is not feasible.
[j] If carcinoma is present in more than one of these anatomic distributions, follow the workup indicated for the predominately involved anatomic site.

Note: All recommendations are category 2A unless otherwise indicated.

Version 2.2025, 09/11/2024 © 2024 National Comprehensive Cancer Network® (NCCN®), All rights reserved. NCCN Guidelines® and this illustration may not be reproduced in any form without the express written permission of NCCN.

Printed by Elizabeth Moore on 4/30/2025 10:21:39 AM. For personal use only. Not approved for distribution. Copyright © 2025 National Comprehensive Cancer Network, Inc., All Rights Reserved.

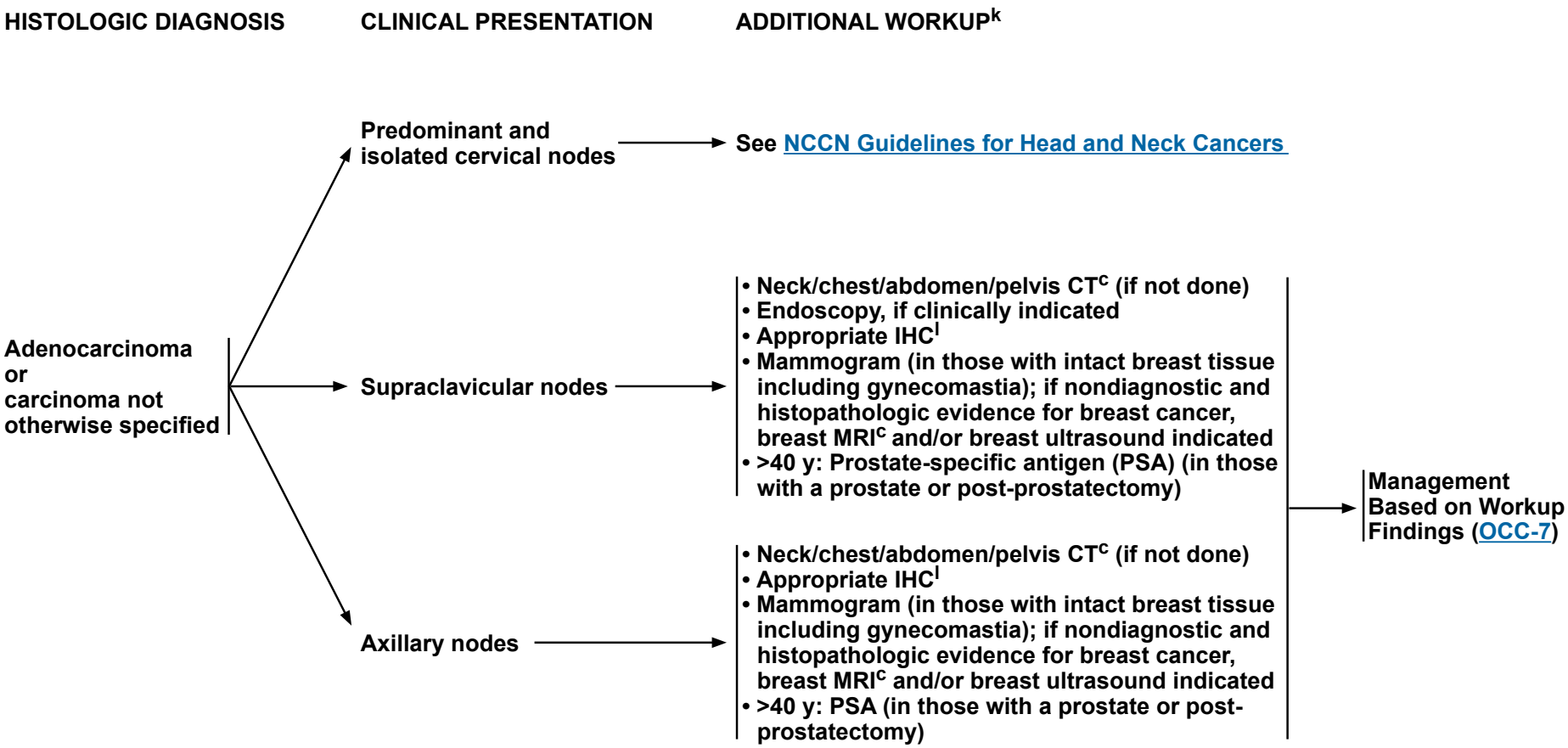

[c] CT should be performed with contrast and MRI should be performed with and without IV contrast unless contraindicated. FDG-PET/CT is an alternative in patients with a contraindication to contrast enhancement.
[k] Symptom-directed endoscopy can be considered for individual patients based on clinical findings and IHC markers.
[l] An expanded panel of IHC markers may be used as appropriate. See Immunohistochemistry/In Situ Hybridization Markers for Unknown Primary Cancers (OCC-A).

Note: All recommendations are category 2A unless otherwise indicated.

Version 2.2025, 09/11/2024 © 2024 National Comprehensive Cancer Network® (NCCN®), All rights reserved. NCCN Guidelines® and this illustration may not be reproduced in any form without the express written permission of NCCN.

Printed by Elizabeth Moore on 4/30/2025 10:21:39 AM. For personal use only. Not approved for distribution. Copyright © 2025 National Comprehensive Cancer Network, Inc., All Rights Reserved.

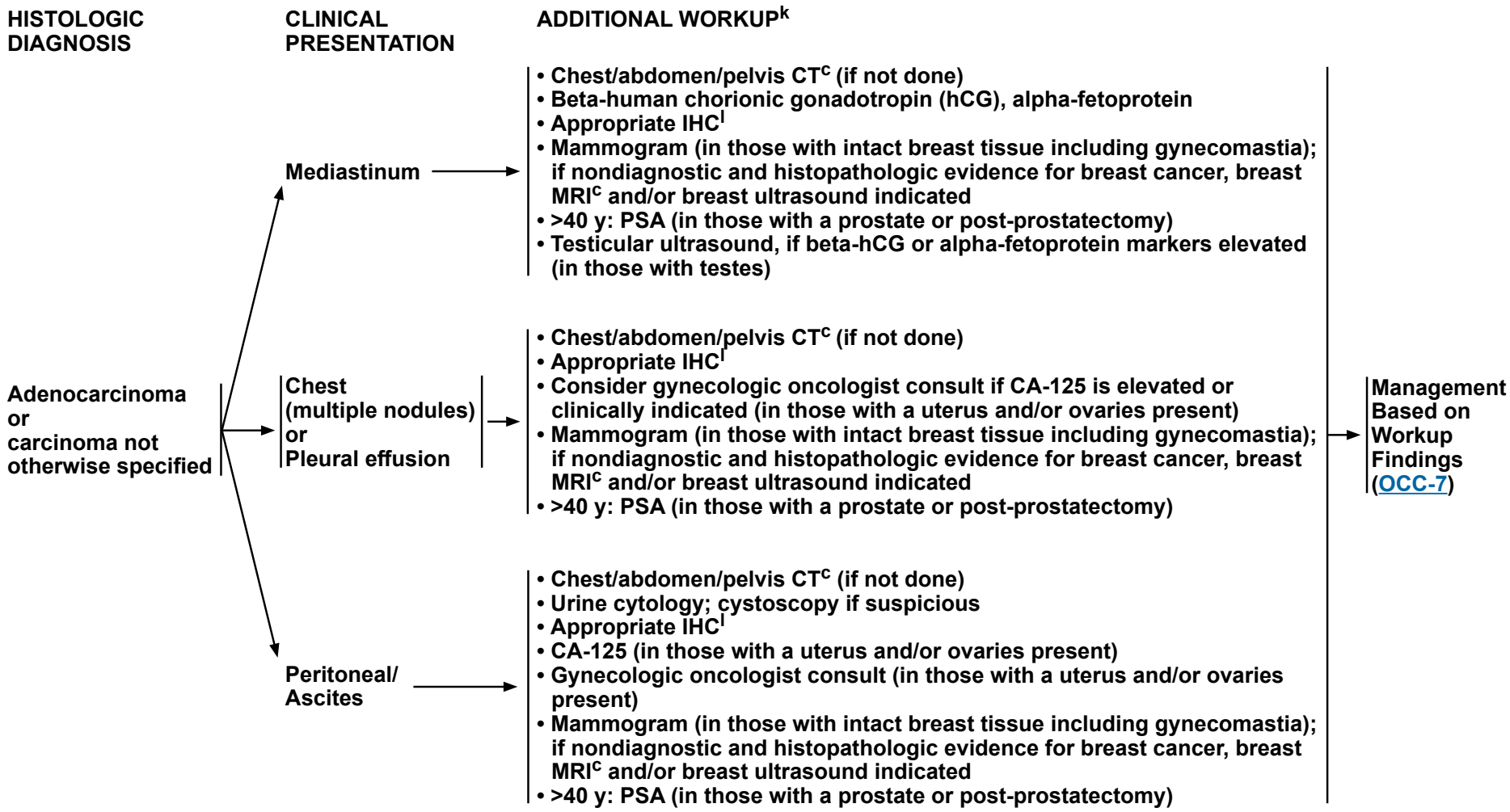

[c] CT should be performed with contrast and MRI should be performed with and without IV contrast unless contraindicated. FDG-PET/CT is an alternative in patients with a contraindication to contrast enhancement.
[k] Symptom-directed endoscopy can be considered for individual patients based on clinical findings and IHC markers.
[l] An expanded panel of IHC markers may be used as appropriate. See Immunohistochemistry/In Situ HybridizationMarkers for Unknown Primary Cancers (OCC-A).

Note: All recommendations are category 2A unless otherwise indicated.

Version 2.2025, 09/11/2024 © 2024 National Comprehensive Cancer Network® (NCCN®), All rights reserved. NCCN Guidelines® and this illustration may not be reproduced in any form without the express written permission of NCCN.

Printed by Elizabeth Moore on 4/30/2025 10:21:39 AM. For personal use only. Not approved for distribution. Copyright © 2025 National Comprehensive Cancer Network, Inc., All Rights Reserved.

HISTOLOGIC DIAGNOSIS

Adenocarcinoma or carcinoma not otherwise specified

CLINICAL PRESENTATION / **ADDITIONAL WORKUP[k]**

Retroperitoneal mass →

- Chest/abdomen/pelvis CT[c] (if not done)
- Urine cytology; consider cystoscopy if suspicious
- Appropriate IHC[l]
- Gynecologic oncologist consult if CA-125 is elevated or clinically indicated (in those with a uterus and/or ovaries present)
- Mammogram (in those with intact breast tissue including gynecomastia); if nondiagnostic and histopathologic evidence for breast cancer, breast MRI[c] and/or breast ultrasound indicated
- >40 y: PSA (in those with a prostate or post-prostatectomy)
- <65 y: Beta-hCG, alpha-fetoprotein, testicular ultrasound (in those with testes)

Inguinal nodes →

- Chest/abdomen/pelvis CT[c] (if not done)
- Proctoscopy if clinically indicated
- CA-125 (in those with a uterus and/or ovaries present)
- Gynecologic oncologist consult (in those with a uterus and/or ovaries present)
- >40 y: PSA (in those with a prostate or post-prostatectomy)

Liver →

- Chest/abdomen/pelvis CT[c] (if not done)
- Endoscopic evaluation
- Alpha-fetoprotein
- Appropriate IHC[l]
- Mammogram (in those with intact breast tissue including gynecomastia); if nondiagnostic and histopathologic evidence for breast cancer, breast MRI[c] and/or breast ultrasound indicated
- Consider further liver-directed imaging (see NCCN Guidelines for Hepatocellular Carcinoma and NCCN Guidelines for Biliary Tract Cancers)

→ **Management Based on Workup Findings (OCC-7)**

[c] CT should be performed with contrast and MRI should be performed with and without IV contrast unless contraindicated. FDG-PET/CT is an alternative in patients with a contraindication to contrast enhancement.
[k] Symptom-directed endoscopy can be considered for individual patients based on clinical findings and IHC markers.
[l] An expanded panel of IHC markers may be used as appropriate. See Immunohistochemistry/In Situ Hybridization Markers for Unknown Primary Cancers (OCC-A).

Note: All recommendations are category 2A unless otherwise indicated.

Version 2.2025, 09/11/2024 © 2024 National Comprehensive Cancer Network® (NCCN®), All rights reserved. NCCN Guidelines® and this illustration may not be reproduced in any form without the express written permission of NCCN.

Printed by Elizabeth Moore on 4/30/2025 10:21:39 AM. For personal use only. Not approved for distribution. Copyright © 2025 National Comprehensive Cancer Network, Inc., All Rights Reserved.

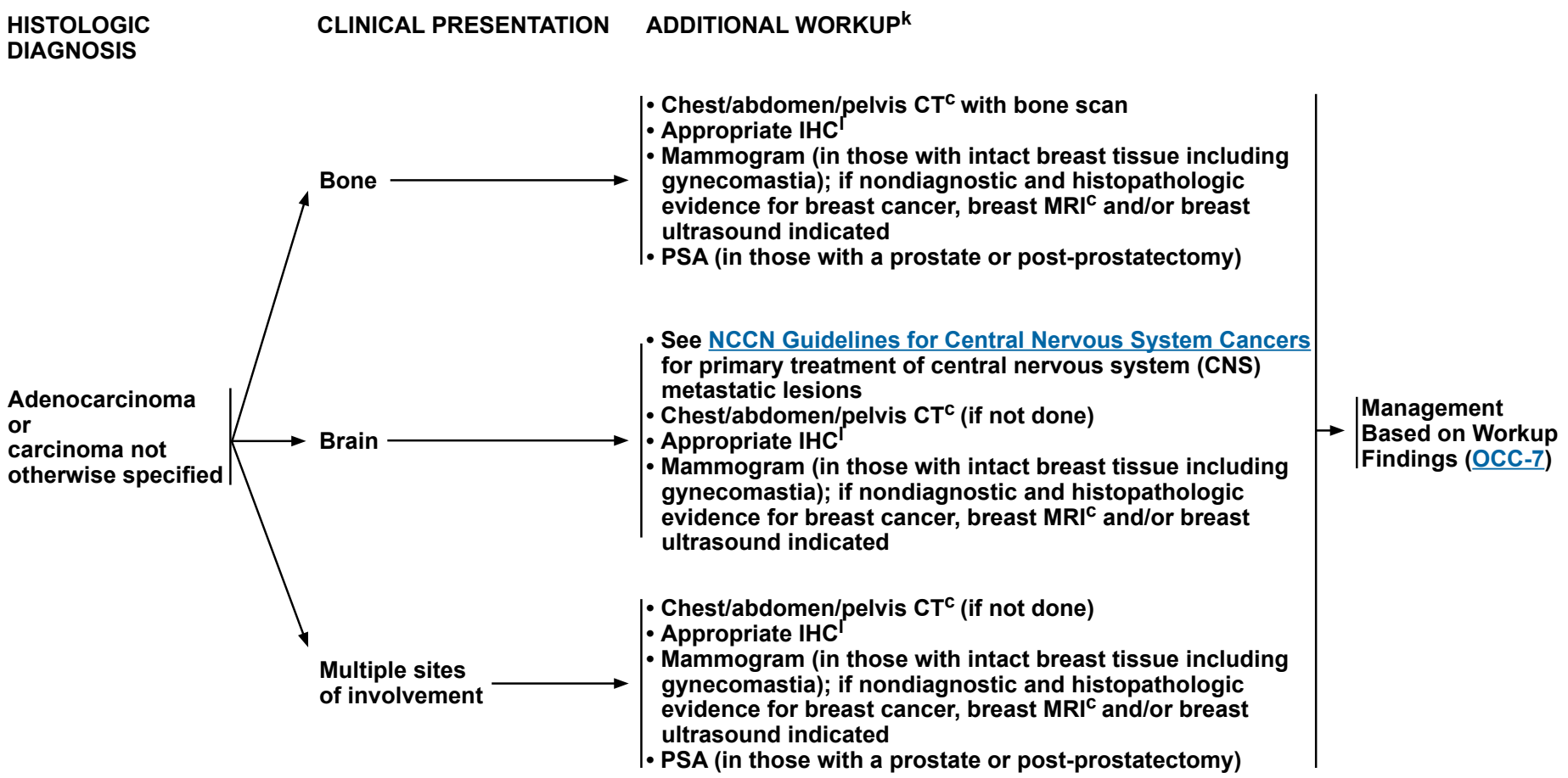

[c] CT should be performed with contrast and MRI should be performed with and without IV contrast unless contraindicated. FDG-PET/CT is an alternative in patients with a contraindication to contrast enhancement.
[k] Symptom-directed endoscopy can be considered for individual patients based on clinical findings and IHC markers.
[l] An expanded panel of IHC markers may be used as appropriate. See Immunohistochemistry/In Situ Hybridization Markers for Unknown Primary Cancers (OCC-A).

Note: All recommendations are category 2A unless otherwise indicated.

Version 2.2025, 09/11/2024 © 2024 National Comprehensive Cancer Network® (NCCN®), All rights reserved. NCCN Guidelines® and this illustration may not be reproduced in any form without the express written permission of NCCN.

Printed by Elizabeth Moore on 4/30/2025 10:21:39 AM. For personal use only. Not approved for distribution. Copyright © 2025 National Comprehensive Cancer Network, Inc., All Rights Reserved.

WORKUP FINDINGS | **MANAGEMENT BASED ON WORKUP FINDINGS**

Primary found → **Treat per NCCN disease-specific guidelines**
NCCN Guidelines Treatment by Cancer Type

Adenocarcinoma or carcinoma not otherwise specified[a]

- → **• Head and neck • Supraclavicular • Axillary • Mediastinum** → **OCC-8**
- → **• Lung nodules • Pleural effusion • Peritoneal • Retroperitoneal mass** → **OCC-9**
- → **• Inguinal node • Liver • Bone • Brain** → **OCC-10**

Disseminated metastases[a] →
- **Symptom control**
- **Clinical trial preferred**
- **Consider systemic therapy on an individual basis**[m]
- **Specialized approaches**[n]

[a] For many patients the apparent uncertainties surrounding the diagnosis of an unknown primary cancer may result in significant psychosocial distress and increased difficulty in accepting treatment options. Empathetic discussion about the natural history of these types of cancer and their prognosis, and the provision of support and counseling both by the primary oncology team and specialized services may help to alleviate this distress. See NCCN Guidelines for Distress Management.
[m] Principles of Systemic Therapy (OCC-B).
[n] For specialized approaches that are therapeutic in nature, see Discussion.

Follow-up (OCC-15)

Note: All recommendations are category 2A unless otherwise indicated.

Version 2.2025, 09/11/2024 © 2024 National Comprehensive Cancer Network® (NCCN®), All rights reserved. NCCN Guidelines® and this illustration may not be reproduced in any form without the express written permission of NCCN.

Printed by Elizabeth Moore on 4/30/2025 10:21:39 AM. For personal use only. Not approved for distribution. Copyright © 2025 National Comprehensive Cancer Network, Inc., All Rights Reserved.

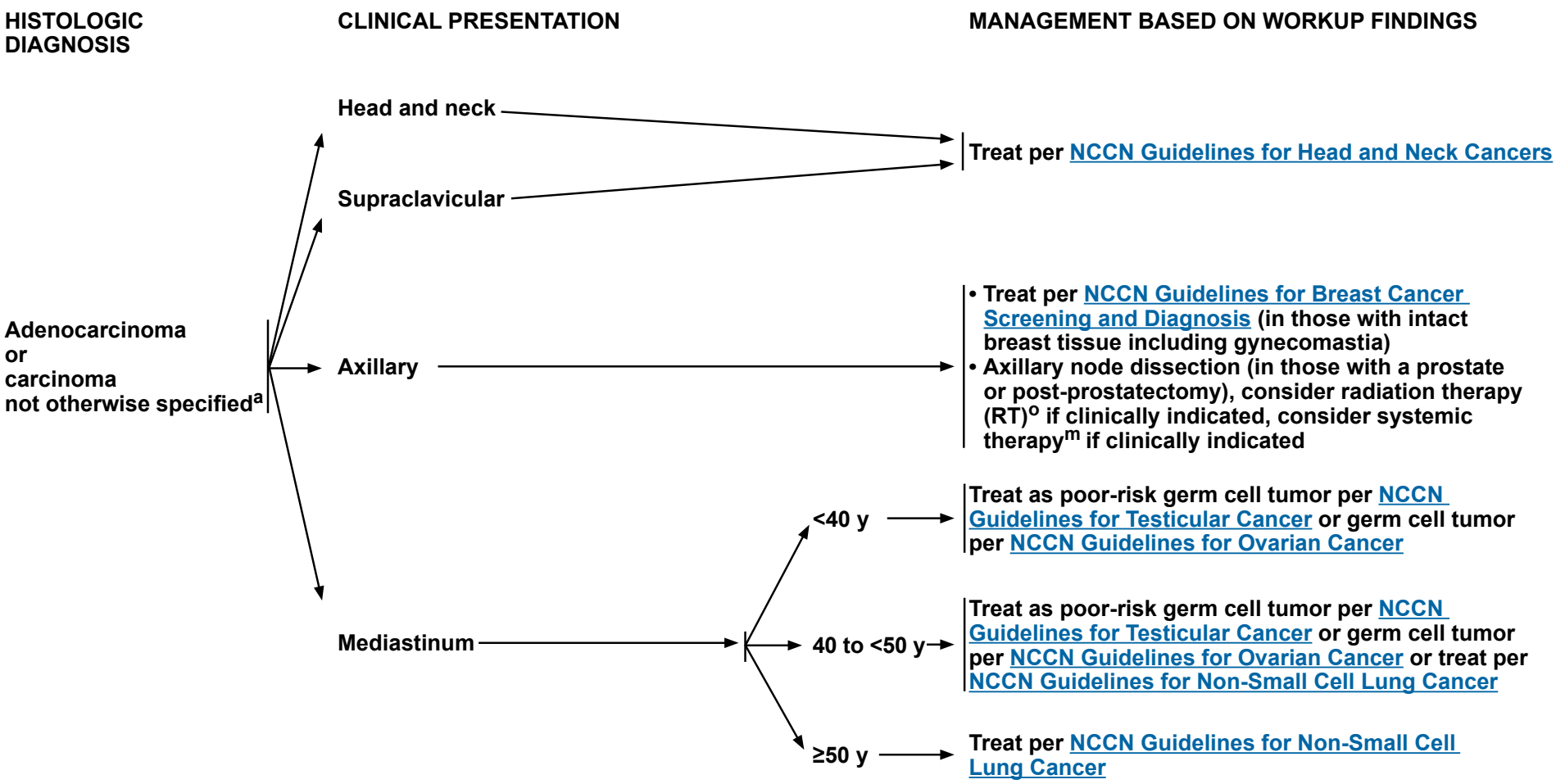

[a] For many patients the apparent uncertainties surrounding the diagnosis of an unknown primary cancer may result in significant psychosocial distress and increased difficulty in accepting treatment options. Empathetic discussion about the natural history of these types of cancer and their prognosis, and the provision of support and counseling both by the primary oncology team and specialized services may help to alleviate this distress. See NCCN Guidelines for Distress Management.
[m] Principles of Systemic Therapy (OCC-B).
[o] Principles of Radiation Therapy (OCC-C).

Follow-up (OCC-15)

Note: All recommendations are category 2A unless otherwise indicated.

Version 2.2025, 09/11/2024 © 2024 National Comprehensive Cancer Network® (NCCN®), All rights reserved. NCCN Guidelines® and this illustration may not be reproduced in any form without the express written permission of NCCN.

Printed by Elizabeth Moore on 4/30/2025 10:21:39 AM. For personal use only. Not approved for distribution. Copyright © 2025 National Comprehensive Cancer Network, Inc., All Rights Reserved.

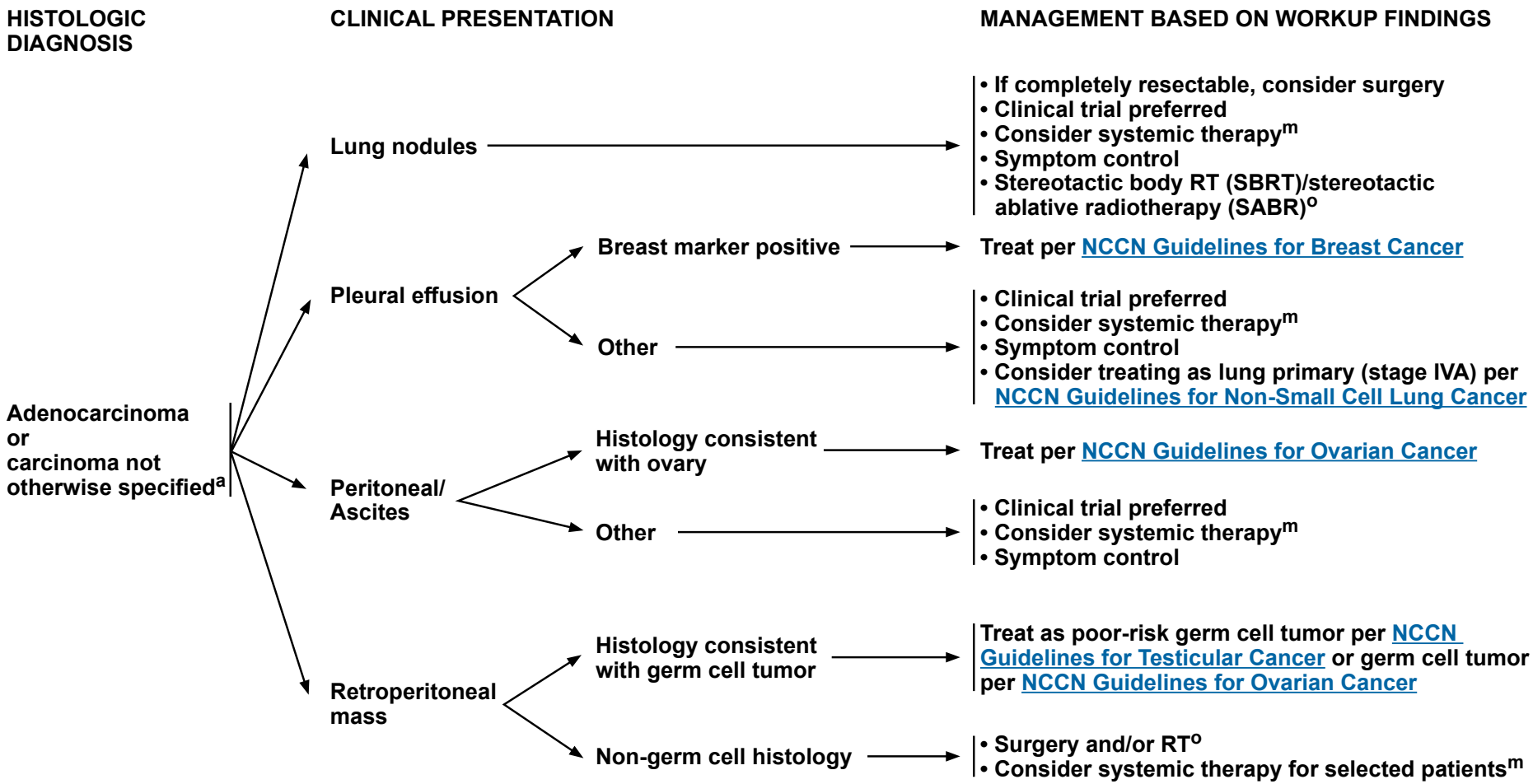

[a] For many patients the apparent uncertainties surrounding the diagnosis of an unknown primary cancer may result in significant psychosocial distress and increased difficulty in accepting treatment options. Empathetic discussion about the natural history of these types of cancer and their prognosis, and the provision of support and counseling both by the primary oncology team and specialized services may help to alleviate this distress. See NCCN Guidelines for Distress Management.
[m] Principles of Systemic Therapy (OCC-B).
[o] Principles of Radiation Therapy (OCC-C).

Follow-up (OCC-15)

Note: All recommendations are category 2A unless otherwise indicated.

Version 2.2025, 09/11/2024 © 2024 National Comprehensive Cancer Network® (NCCN®), All rights reserved. NCCN Guidelines® and this illustration may not be reproduced in any form without the express written permission of NCCN.

Printed by Elizabeth Moore on 4/30/2025 10:21:39 AM. For personal use only. Not approved for distribution. Copyright © 2025 National Comprehensive Cancer Network, Inc., All Rights Reserved.

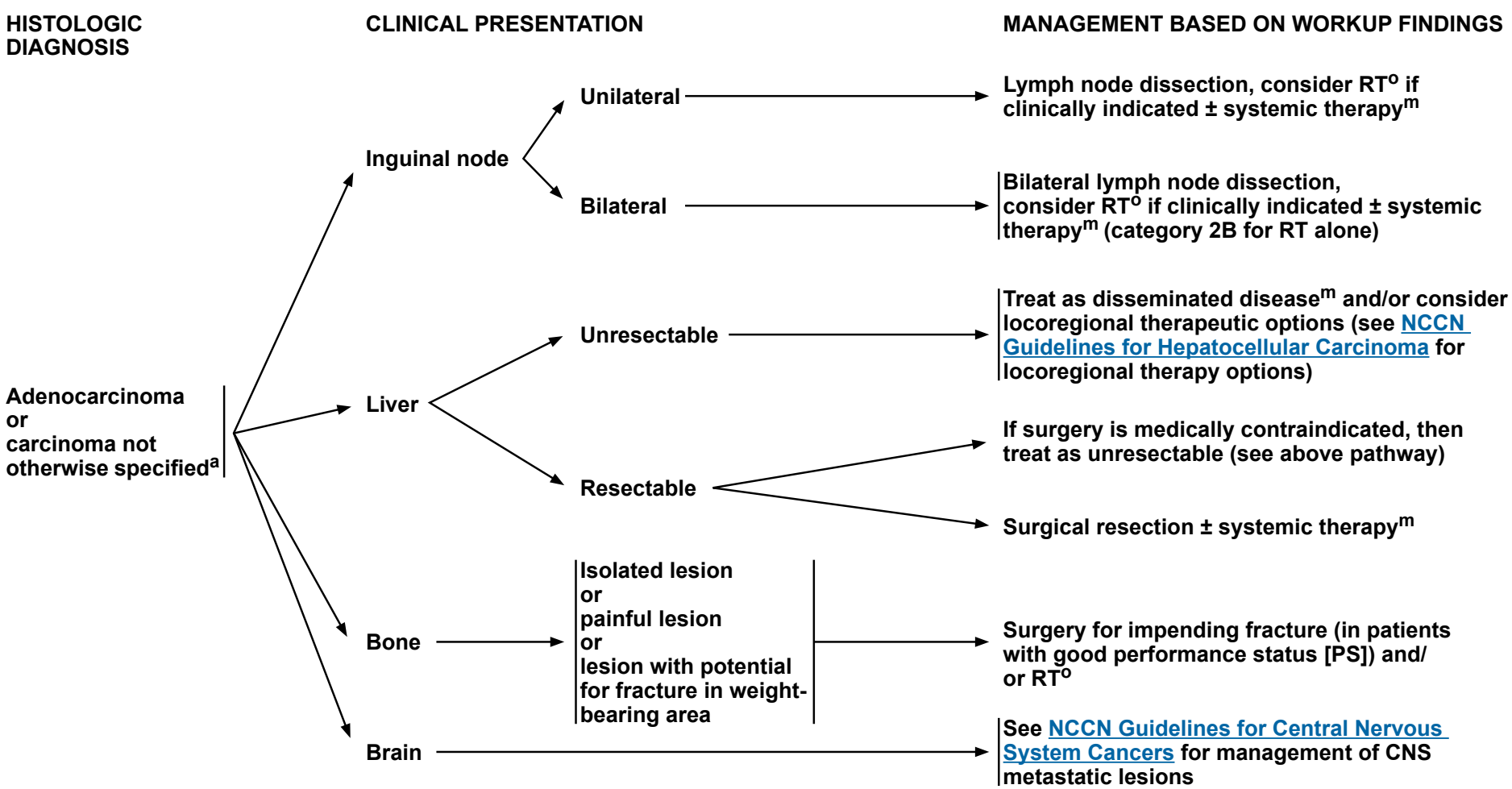

[a] For many patients the apparent uncertainties surrounding the diagnosis of an unknown primary cancer may result in significant psychosocial distress and increased difficulty in accepting treatment options. Empathetic discussion about the natural history of these types of cancer and their prognosis, and the provision of support and counseling both by the primary oncology team and specialized services may help to alleviate this distress. See NCCN Guidelines for Distress Management.
[m] Principles of Systemic Therapy (OCC-B).
[o] Principles of Radiation Therapy (OCC-C).

Follow-up (OCC-15)

Note: All recommendations are category 2A unless otherwise indicated.

Version 2.2025, 09/11/2024 © 2024 National Comprehensive Cancer Network® (NCCN®), All rights reserved. NCCN Guidelines® and this illustration may not be reproduced in any form without the express written permission of NCCN.

Printed by Elizabeth Moore on 4/30/2025 10:21:39 AM. For personal use only. Not approved for distribution. Copyright © 2025 National Comprehensive Cancer Network, Inc., All Rights Reserved.

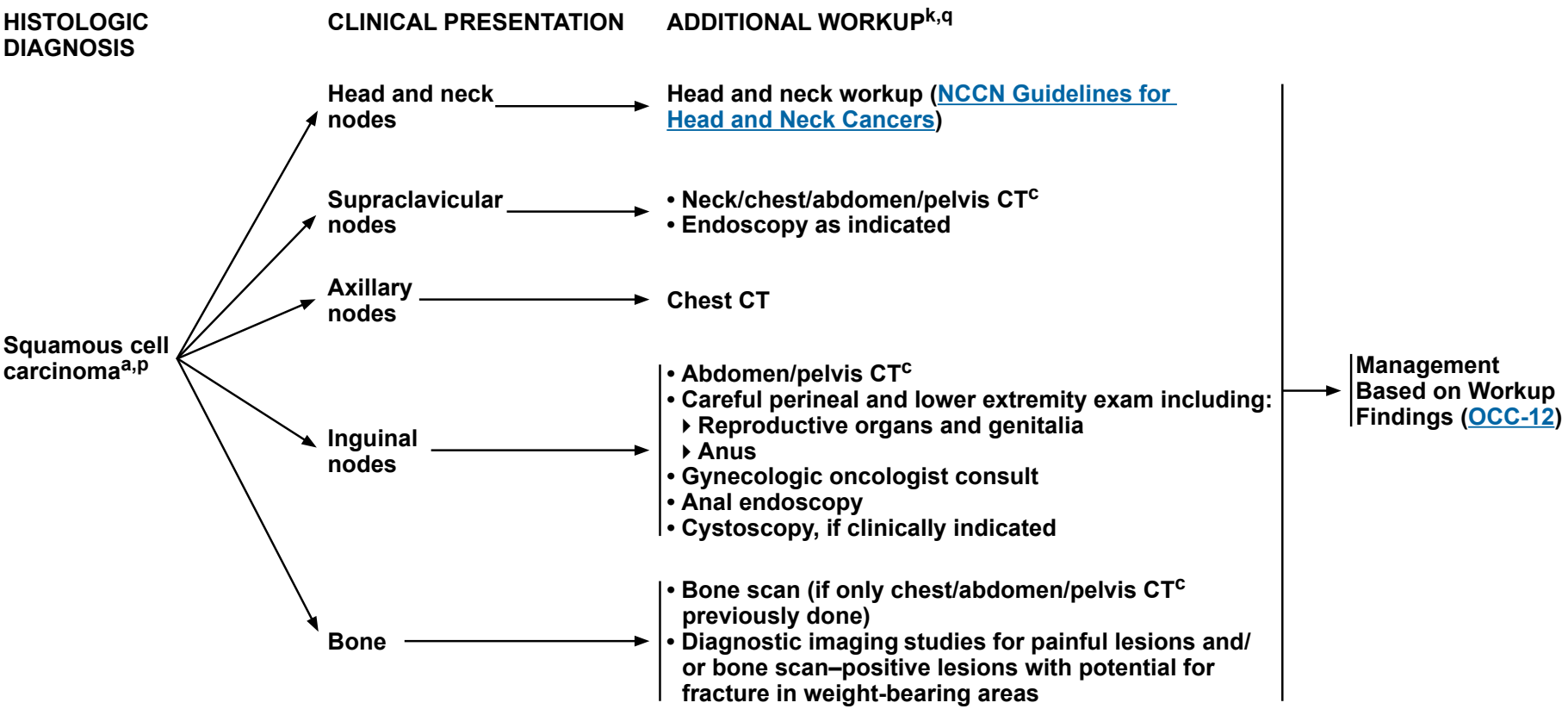

[a] For many patients the apparent uncertainties surrounding the diagnosis of an unknown primary cancer may result in significant psychosocial distress and increased difficulty in accepting treatment options. Empathetic discussion about the natural history of these types of cancer and their prognosis, and the provision of support and counseling both by the primary oncology team and specialized services may help to alleviate this distress. See NCCN Guidelines for Distress Management.
[c] CT should be performed with contrast and MRI should be performed with and without IV contrast unless contraindicated. FDG-PET/CT is an alternative in patients with a contraindication to contrast enhancement.
[k] Symptom-directed endoscopy can be considered for individual patients based on clinical findings and IHC markers.
[p] Include a complete skin exam with focus on the cutaneous areas.
[q] Check results of p16 IHC/human papillomavirus (HPV) in situ hybridization (ISH) and Epstein-Barr virus (EBV) ISH; positive results can help localize primary site.

Note: All recommendations are category 2A unless otherwise indicated.

Version 2.2025, 09/11/2024 © 2024 National Comprehensive Cancer Network® (NCCN®), All rights reserved. NCCN Guidelines® and this illustration may not be reproduced in any form without the express written permission of NCCN.

Printed by Elizabeth Moore on 4/30/2025 10:21:39 AM. For personal use only. Not approved for distribution. Copyright © 2025 National Comprehensive Cancer Network, Inc., All Rights Reserved.

WORKUP FINDINGS | **MANAGEMENT BASED ON WORKUP FINDINGS**

Primary found → **Treat per NCCN disease-specific guidelines**
NCCN Guidelines Treatment by Cancer Type

Site-specific squamous cell carcinoma[a]

- → **• Head and neck • Supraclavicular • Axillary**
- → **• Mediastinum • Multiple lung nodules • Pleural effusion**

→ **OCC-13**

- → **• Inguinal • Bone • Brain** → **OCC-14**

Disseminated metastases[a] → **• Symptom control • Clinical trial preferred • Consider systemic therapy on an individual basis[m]**

[a] For many patients the apparent uncertainties surrounding the diagnosis of an unknown primary cancer may result in significant psychosocial distress and increased difficulty in accepting treatment options. Empathetic discussion about the natural history of these types of cancer and their prognosis, and the provision of support and counseling both by the primary oncology team and specialized services may help to alleviate this distress. See NCCN Guidelines for Distress Management.
[m] Principles of Systemic Therapy (OCC-B).

Follow-up (OCC-15)

Note: All recommendations are category 2A unless otherwise indicated.

Version 2.2025, 09/11/2024 © 2024 National Comprehensive Cancer Network® (NCCN®), All rights reserved. NCCN Guidelines® and this illustration may not be reproduced in any form without the express written permission of NCCN.

Printed by Elizabeth Moore on 4/30/2025 10:21:39 AM. For personal use only. Not approved for distribution. Copyright © 2025 National Comprehensive Cancer Network, Inc., All Rights Reserved.

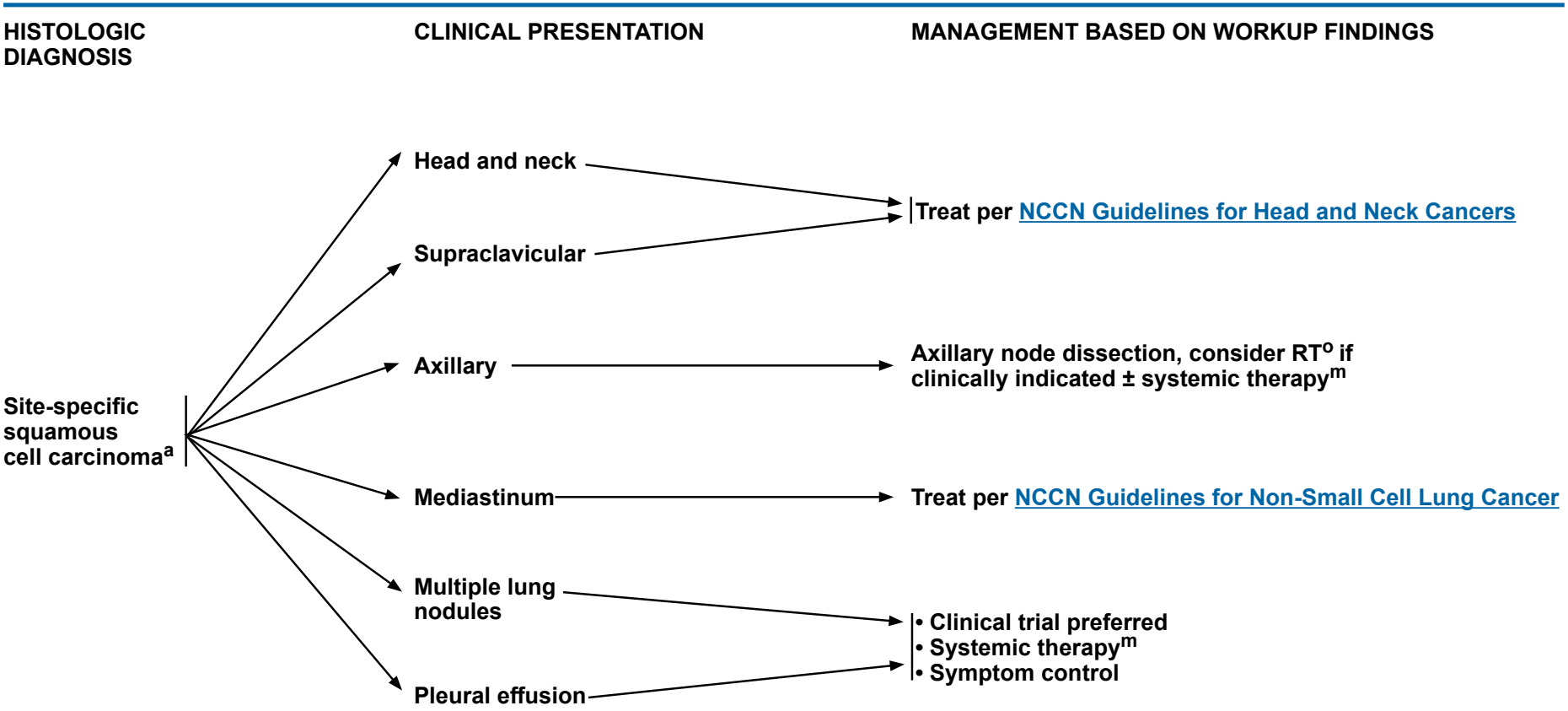

[a] For many patients the apparent uncertainties surrounding the diagnosis of an unknown primary cancer may result in significant psychosocial distress and increased difficulty in accepting treatment options. Empathetic discussion about the natural history of these types of cancer and their prognosis, and the provision of support and counseling both by the primary oncology team and specialized services may help to alleviate this distress. See NCCN Guidelines for Distress Management.
[m] Principles of Systemic Therapy (OCC-B).
[o] Principles of Radiation Therapy (OCC-C).

Follow-up (OCC-15)

Note: All recommendations are category 2A unless otherwise indicated.

Version 2.2025, 09/11/2024 © 2024 National Comprehensive Cancer Network® (NCCN®), All rights reserved. NCCN Guidelines® and this illustration may not be reproduced in any form without the express written permission of NCCN.

Printed by Elizabeth Moore on 4/30/2025 10:21:39 AM. For personal use only. Not approved for distribution. Copyright © 2025 National Comprehensive Cancer Network, Inc., All Rights Reserved.

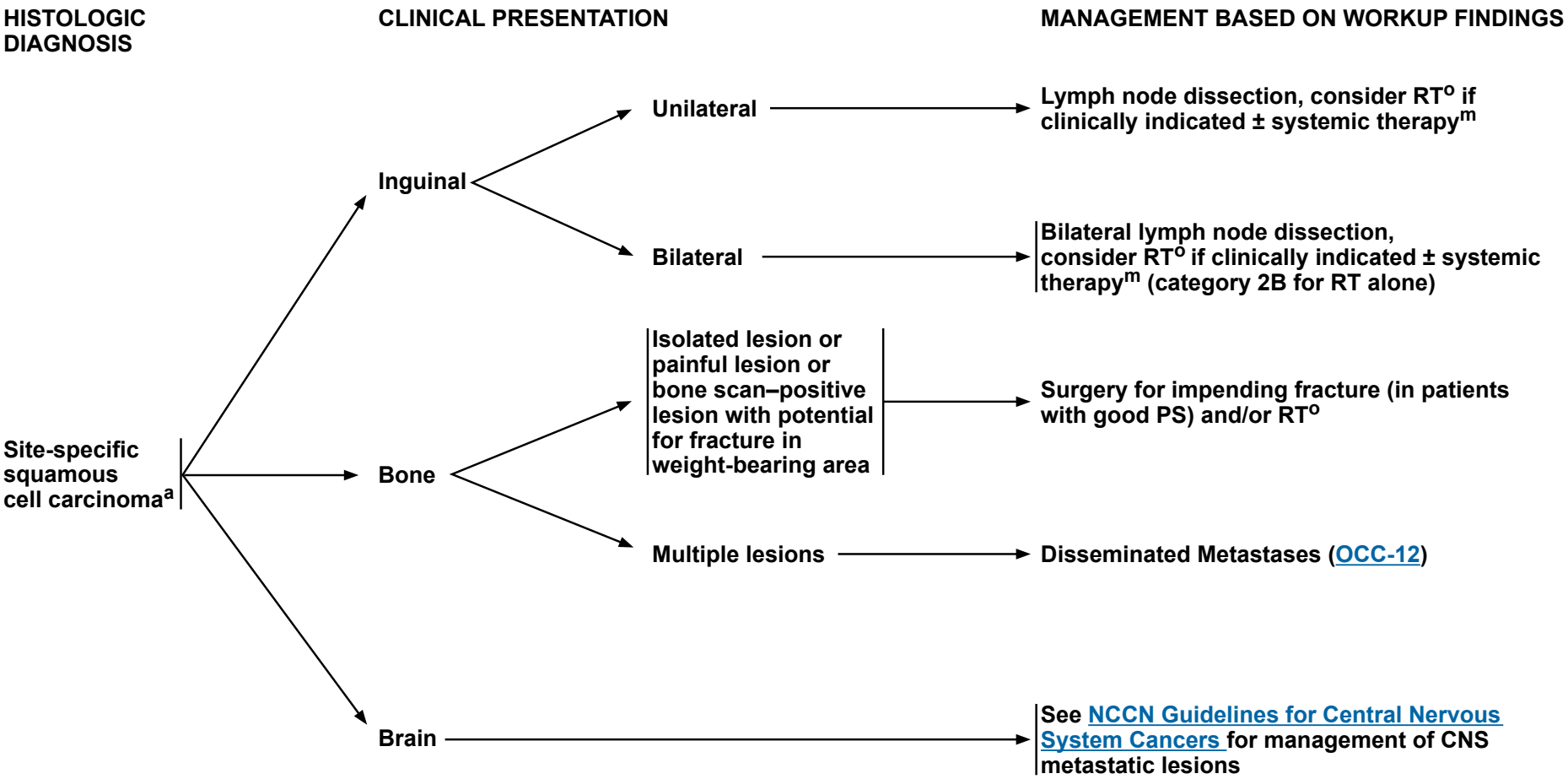

[a] For many patients the apparent uncertainties surrounding the diagnosis of an unknown primary cancer may result in significant psychosocial distress and increased difficulty in accepting treatment options. Empathetic discussion about the natural history of these types of cancer and their prognosis, and the provision of support and counseling both by the primary oncology team and specialized services may help to alleviate this distress. See NCCN Guidelines for Distress Management.
[m] Principles of Systemic Therapy (OCC-B).
[o] Principles of Radiation Therapy (OCC-C).

Follow-up (OCC-15)

Note: All recommendations are category 2A unless otherwise indicated.

Version 2.2025, 09/11/2024 © 2024 National Comprehensive Cancer Network® (NCCN®), All rights reserved. NCCN Guidelines® and this illustration may not be reproduced in any form without the express written permission of NCCN.

Printed by Elizabeth Moore on 4/30/2025 10:21:39 AM. For personal use only. Not approved for distribution. Copyright © 2025 National Comprehensive Cancer Network, Inc., All Rights Reserved.

FOLLOW-UP FOR ALL OCCULT PRIMARIES (NO ACTIVE TREATMENT)

- **For patients with active disease or disease in remission, follow-up frequency should be determined by clinical need.**
  - **H&P**
  - **Diagnostic tests based on symptomatology**
- **For patients with active and incurable disease, psychosocial support, symptom management, end-of-life discussions, palliative care interventions, and hospice care should all be considered and utilized as appropriate.**
- **See NCCN Guidelines for Palliative Care, NCCN Guidelines for Distress Management, and NCCN Guidelines for Survivorship.**

Note: All recommendations are category 2A unless otherwise indicated.

Version 2.2025, 09/11/2024 © 2024 National Comprehensive Cancer Network® (NCCN®), All rights reserved. NCCN Guidelines® and this illustration may not be reproduced in any form without the express written permission of NCCN.

Printed by Elizabeth Moore on 4/30/2025 10:21:39 AM. For personal use only. Not approved for distribution. Copyright © 2025 National Comprehensive Cancer Network, Inc., All Rights Reserved.

POTENTIAL IMMUNOHISTOCHEMISTRY/IN SITU HYBRIDIZATION MARKERS FOR UNKNOWN PRIMARY CANCERS

Communication between the clinician and the pathologist is essential for the workup to direct the staining pattern to the clinical differential diagnosis. The pathologist should select a focused panel of IHC or ISH markers, and avoid a large series of markers. IHC and ISH markers for unknown primary cancers are provided as a resource to assist in localizing a primary but are not uniformly specific or sensitive.

TUMOR-SPECIFIC MARKERS AND THEIR STAINING PATTERN[1,2]

Marker	Tumor	Staining Pattern
Arginase-1	Hepatocellular	Nuclear/cytoplasmic
Calretinin	Mesothelioma, sex cord–stromal, adrenocortical	Nuclear/cytoplasmic
CDX2	Colorectal, other gastrointestinal, pancreaticobiliary tract	Nuclear
D2-40	Mesothelioma, lymphatic endothelial cell marker	Membranous
EBV	Nasopharynx	Nuclear
ER/PR	Breast, ovary, endometrium	Nuclear
GATA3	Breast, urinary bladder, salivary gland	Nuclear
Glypican-3	Hepatocellular	Cytoplasmic
HepPar-1	Hepatocellular	Cytoplasmic
HPV	Cervix, vulva, vagina, penis, anal, oropharynx	Nuclear (DNA ISH); nuclear/cytoplasmic (RNA ISH)
Inhibin	Sex cord–stromal, adrenocortical	Cytoplasmic
Melan-A	Adrenocortical, melanoma	Nuclear
Napsin A	Lung	Cytoplasmic
NKX3-1	Prostate	Nuclear
PAP	Prostate	Membranous
PAX8	Thyroid, renal, ovary, endometrium, cervix, thymus	Nuclear
PSA	Prostate	Cytoplasmic
RCC marker	Renal	Membranous
SF-1	Adrenocortical, sex–cord stromal	Nuclear
SATB2	Colorectal, osteosarcoma, and other gastrointestinal tract	Nuclear
Thyroglobulin	Thyroid	Cytoplasmic
TTF-1	Lung, thyroid	Nuclear
Uroplakin III	Urothelial	Membranous
Villin	Gastrointestinal (epithelia with brush border)	Apical
WT1	Ovarian serous, mesothelioma, Wilms	Nuclear

[1] ER/PR, estrogen receptor/progesterone receptor; gross cystic disease fluid protein 15; HepPar-1, hepatocyte paraffin 1; PAP, prostatic acid phosphatase; PSA, prostate-specific antigen; RCC, renal cell carcinoma; SF-1, steroidogenic factor-1; TTF-1, thyroid transcription factor 1. Reprinted from Bahrami A, Truong LD, Ro JY. Undifferentiated tumor: true identity by immunohistochemistry. Arch Pathol Lab Med 2008;132:326-348 with permission from Archives of Pathology & Laboratory Medicine. Copyright 2008 College of American Pathologists.

[2] Per physician discretion, TRK protein testing can be considered as part of broad immunohistochemistry testing (a positive test should then be confirmed with NGS).
Drilon A, Laetsch TW, Kummar S, et al. Efficacy of larotrectinib in TRK fusion-positive cancers in adults and children. N Engl J Med 2018;378:731-739; Doebele RC, Drilon A, Paz-Ares L, et al. Entrectinib in patients with advanced or metastatic NTRK fusion-positive solid tumours: integrated analysis of three phase 1-2 trials. Lancet Oncol 2020;21:271-282.

Note: All recommendations are category 2A unless otherwise indicated.

Version 2.2025, 09/11/2024 © 2024 National Comprehensive Cancer Network® (NCCN®), All rights reserved. NCCN Guidelines® and this illustration may not be reproduced in any form without the express written permission of NCCN.

Printed by Elizabeth Moore on 4/30/2025 10:21:39 AM. For personal use only. Not approved for distribution. Copyright © 2025 National Comprehensive Cancer Network, Inc., All Rights Reserved.

POTENTIAL IMMUNOHISTOCHEMISTRY/IN SITU HYBRIDIZATION MARKERS FOR UNKNOWN PRIMARY CANCERS
Undifferentiated Panel: For Determining Most Likely Cell Lineage[3]

Markers*	Most Likely Cell Lineage
Pan-keratin (AE1/AE3 & CAM5.2)	Carcinoma
CK5/6, p63/p40	Squamous cell carcinoma
S100, SOX10	Melanoma and sarcoma
LCA± CD20± CD3±	Lymphoma
OCT3/4± SALL4±	Germ cell tumor
WT1, calretinin, mesothelin, D2-40	Mesothelial tumor

***These markers are not uniformly specific or sensitive and can be present on other tumors.**

[3] Conner JR, Hornick JL. Metastatic carcinoma of unknown primary: diagnostic approach using immunohistochemistry. Adv Anat Pathol 2015;22:149-167.

Note: All recommendations are category 2A unless otherwise indicated.

Version 2.2025, 09/11/2024 © 2024 National Comprehensive Cancer Network® (NCCN®), All rights reserved. NCCN Guidelines® and this illustration may not be reproduced in any form without the express written permission of NCCN.

Printed by Elizabeth Moore on 4/30/2025 10:21:39 AM. For personal use only. Not approved for distribution. Copyright © 2025 National Comprehensive Cancer Network, Inc., All Rights Reserved.

COMMONLY USED IMMUNOHISTOCHEMISTRY/IN SITU HYBRIDIZATION MARKERS FOR UNKNOWN PRIMARY CANCERS[3]

Tumor Site or Type	Cytokeratin 7 (CK7) and Cytokeratin 20 (CK20)	Other Positive Markers	Other Useful Markers
Adrenocortical carcinoma	CK7-/CK20-	SF-1 Melan A Inhibin	
Breast carcinoma	CK7+/CK20-	GATA3 GCDFP-15 (BRST2)± Mammagloblin±	ER/PR±
Endocervical adenocarcinoma	CK7+/CK20-	p16+ (strong diffuse staining) PAX8±	Vimentin- ER/PR± Human papillomavirus in situ hybridization
Endometrial adenocarcinoma	CK7+/CK20-	Vimentin PAX8	ER/PR± p16- (to distinguish from endocervical and uterine serous carcinoma)
Hepatocellular carcinoma	CK7-/CK20-	Arginase-1 HepPar-1 Glypican-3 CD10 and polyclonal CEA± (peri-canalicular pattern)	MOC31- (to distinguish from intrahepatic cholangiocarcinoma) Albumin in situ hybridization - (also for intrahepatic cholangiocarcinoma)
Lower gastrointestinal carcinoma, including small intestinal, appendiceal, and colorectal	CK7-/CK20+	CDX2 Villin SATB2	

[3] Conner JR, Hornick JL. Metastatic carcinoma of unknown primary: diagnostic approach using immunohistochemistry. Adv Anat Pathol 2015;22:149-167.

Note: All recommendations are category 2A unless otherwise indicated.

Version 2.2025, 09/11/2024 © 2024 National Comprehensive Cancer Network® (NCCN®), All rights reserved. NCCN Guidelines® and this illustration may not be reproduced in any form without the express written permission of NCCN.

Printed by Elizabeth Moore on 4/30/2025 10:21:39 AM. For personal use only. Not approved for distribution. Copyright © 2025 National Comprehensive Cancer Network, Inc., All Rights Reserved.

COMMONLY USED IMMUNOHISTOCHEMISTRY/IN SITU HYBRIDIZATION MARKERS FOR UNKNOWN PRIMARY CANCERS[3]

Tumor Site or Type	Cytokeratin 7 (CK7) and Cytokeratin 20 (CK20)	Other Positive Markers	Other Useful Markers
Lung adenocarcinoma	CK7+/CK20-	TTF-1 NapsinA	
Mesothelioma	CK7+/CK20-	Calretinin WT1 CK5/6 D2-40 Mesothelin	p63- CEA- MOC31- BerEP4- TTF-1- (to distinguish from pulmonary adenocarcinoma)
Neuroendocrine carcinoma, including small cell carcinoma	CK7±/CK20± ("dot-like" pattern in Merkel cell carcinoma)	Chromogranin Synaptophysin	TTF-1± CDX-2± Mitotic rate and/or Ki-67 (for grade)
Non-seminomatous germ cell tumor	CK7-/CK20-	SALL4 OCT3/4±	CD30 Glypican-3 PLAP (for further subtyping)
Ovarian mucinous carcinoma	CK7+/CK20±	PAX8± CDX2±	SATB2-
Ovarian serous carcinoma	CK7+/CK20-	PAX8 WT1	p53 (abnormal) p16 (diffuse, strong)
Pancreaticobiliary carcinoma, including intrahepatic cholangiocarcinoma	CK7+/CK20±	CDX2± CK19	SMAD4 loss ± (pancreas, extrahepatic cholangiocarcinoma, and colorectal carcinomas) Albumin in situ hybridization - (also for intrahepatic cholangiocarcinoma)
Prostate carcinoma	CK7-/CK20-	PSA PSAP NKX3-1 P501S (prostein) ERG±	

[3] Conner JR, Hornick JL. Metastatic carcinoma of unknown primary: diagnostic approach using immunohistochemistry. Adv Anat Pathol 2015;22:149-167.

Note: All recommendations are category 2A unless otherwise indicated.

Version 2.2025, 09/11/2024 © 2024 National Comprehensive Cancer Network® (NCCN®), All rights reserved. NCCN Guidelines® and this illustration may not be reproduced in any form without the express written permission of NCCN.

Printed by Elizabeth Moore on 4/30/2025 10:21:39 AM. For personal use only. Not approved for distribution. Copyright © 2025 National Comprehensive Cancer Network, Inc., All Rights Reserved.

COMMONLY USED IMMUNOHISTOCHEMISTRY/IN SITU HYBRIDIZATION MARKERS FOR UNKNOWN PRIMARY CANCERS[3]

Tumor Site or Type	Cytokeratin 7 (CK7) and Cytokeratin 20 (CK20)	Other Positive Markers	Other Useful Markers
Renal cell carcinoma	CK7±/CK20-	PAX2 PAX8 Carbonic anhydrase IX (CA9)± EMA± Vimentin± CD10± (membranous)	
Salivary gland carcinoma	CK7+/CK20-	CK5/6 p63	GATA3 AR HER2
Squamous cell carcinoma	CK7-/CK20-	CK5/6 p63 or p40 34βE12	p16 (strong diffuse staining) and/ or human papillomavirus in situ hybridization (HPV-associated carcinoma)
Thyroid carcinoma (follicular or papillary carcinomas)	CK7+/CK20-	TTF-1 PAX8 CK19±	Thyroglobulin
Thyroid carcinoma (medullary carcinoma)	CK7+/CK20-	TTF-1 PAX8 CK19±	Calcitonin, synaptophysin, chromogranin, and monoclonal CEA
Urothelial carcinoma	CK7+/CK20±	GATA3 p63 or p40 CK5/6± 34βE12 S100P Uroplakin II	
Upper gastrointestinal tract carcinoma, including esophagus and stomach	CK7+/CK20±	CDX-2± Villin±	

[3] Conner JR, Hornick JL. Metastatic carcinoma of unknown primary: diagnostic approach using immunohistochemistry. Adv Anat Pathol 2015;22:149-167.

Note: All recommendations are category 2A unless otherwise indicated.

Version 2.2025, 09/11/2024 © 2024 National Comprehensive Cancer Network® (NCCN®), All rights reserved. NCCN Guidelines® and this illustration may not be reproduced in any form without the express written permission of NCCN.

Printed by Elizabeth Moore on 4/30/2025 10:21:39 AM. For personal use only. Not approved for distribution. Copyright © 2025 National Comprehensive Cancer Network, Inc., All Rights Reserved.

PRINCIPLES OF SYSTEMIC THERAPY

- **Consider systemic therapy in symptomatic patients (PS 1–2) or asymptomatic patients (PS 0) with an aggressive cancer.**
- **Base the systemic therapy regimen (listed on the following pages and others) to be used on the histologic cancer type.**

Neuroendocrine Tumors
For poorly differentiated (high-grade or anaplastic) or small cell subtype, see NCCN Guidelines for Small Cell Lung Cancer
For well-differentiated neuroendocrine tumors, see NCCN Guidelines for Neuroendocrine and Adrenal Tumors - Carcinoid Tumors

Note: All recommendations are category 2A unless otherwise indicated.

Version 2.2025, 09/11/2024 © 2024 National Comprehensive Cancer Network® (NCCN®), All rights reserved. NCCN Guidelines® and this illustration may not be reproduced in any form without the express written permission of NCCN.

Printed by Elizabeth Moore on 4/30/2025 10:21:39 AM. For personal use only. Not approved for distribution. Copyright © 2025 National Comprehensive Cancer Network, Inc., All Rights Reserved.

PRINCIPLES OF SYSTEMIC THERAPY

Selected Systemic Therapy for Occult Primaries: Adenocarcinoma[a]

Regimens are listed in alphabetical order by category of preference.

Preferred Regimens	Other Recommended Regimens	Useful in Certain Circumstances
• Carboplatin and paclitaxel[1,2] • Cisplatin and gemcitabine[3] **Preferred Regimens for Presumed GI Primary Site** • CapeOX[4] • FOLFIRI[b,5-9] • mFOLFOX6[b,4,10]	• Capecitabine[c,d,11,12] • Docetaxel and carboplatin[13] • Docetaxel and cisplatin[14] • Fluorouracil[b,c,d,15-18] • Gemcitabine and carboplatin[19] • Gemcitabine and docetaxel[20] • Irinotecan and carboplatin[21]	**Biomarker-Driven Therapy** ***BRAF* V600E mutation-positive tumors** • Dabrafenib + trametinib[e,22] **dMMR/MSI-H tumors** • Dostarlimab-gxly[f,g,23] • Pembrolizumab[f,24-26] ***NTRK* gene fusion-positive tumors** • Entrectinib[h,27] • Larotrectinib[h,28] • Repotrectinib[h,29] **TMB-high (TMB-H) (≥10 mut/Mb) tumors** • Pembrolizumab[f,24-26,30] **HER2-positive (IHC 3+) tumors** • Fam-trastuzumab deruxtecan-nxki[i,31] ***RET* gene fusion-positive tumors** • Selpercatinib[j,32] **Cytotoxic Chemotherapy** • FOLFIRINOX [b,c,k,33] • Irinotecan and gemcitabine[l,34] • mFOLFIRINOX[b,c,k,35,36] • Paclitaxel, carboplatin, and etoposide[k,37]

[a] Consider programmed death ligand 1 (PD-L1) testing for patients with recurrent, progressive, or metastatic disease.
[b] Leucovorin is indicated with certain fluorouracil-based regimens. Depending on availability, these regimens may be used with or without leucovorin.
[c] For patients with presumed gastrointestinal (GI) primary site.
[d] These regimens can be given with concurrent radiation.
[e] For patients with *BRAF* V600E mutation-positive unresectable or metastatic solid tumors that have progressed following prior treatment and have no satisfactory alternative treatment options.
[f] NCCN Guidelines for Management of Immunotherapy-Related Toxicities.
[g] For patients with recurrent or advanced tumors that have progressed on or following prior treatment and who have no satisfactory alternative treatment options. Note, patients who had received prior immune checkpoint inhibitor therapy were excluded from the dostarlimab-gxly clinical trial.
[h] For patients with *NTRK* gene fusion-positive tumors without a known acquired resistance mutation, that are metastatic or where surgical resection is likely to result in severe morbidity, and that have no satisfactory alternative treatments or that have progressed following treatment.
[i] For patients with advanced or metastatic solid tumors that progressed on or following prior systemic treatment and who have no satisfactory alternative treatment options.
[j] For patients with advanced or metastatic solid tumors that progressed on or following prior systemic treatment or who have no satisfactory alternative treatment options.
[k] Only for patients with PS ECOG 0–1.
[l] For patients ineligible to receive platinum-based chemotherapy.

For Squamous Cell Carcinoma see OCC-B 8 of 14

References on OCC-B 13 of 14

Note: All recommendations are category 2A unless otherwise indicated.

Version 2.2025, 09/11/2024 © 2024 National Comprehensive Cancer Network® (NCCN®), All rights reserved. NCCN Guidelines® and this illustration may not be reproduced in any form without the express written permission of NCCN.

Printed by Elizabeth Moore on 4/30/2025 10:21:39 AM. For personal use only. Not approved for distribution. Copyright © 2025 National Comprehensive Cancer Network, Inc., All Rights Reserved.

PRINCIPLES OF SYSTEMIC THERAPY

DOSING SCHEDULES FOR OCCULT PRIMARIES: ADENOCARCINOMA

Preferred Regimens

Carboplatin and paclitaxel
Paclitaxel 175–200 mg/m² IV Day 1
Carboplatin AUC 5–6 IV Day 1
Repeat every 3 weeks[1]
OR
Paclitaxel 80 mg/m² IV Days 1, 8, and 15
Carboplatin AUC 2 IV Days 1, 8, and 15
Repeat every 4 weeks[2]

Cisplatin and gemcitabine
Gemcitabine 1000–1250 mg/m² IV Days 1 and 8
Cisplatin 75 mg/m² IV Day 1
Repeat every 3 weeks[3]

Preferred Regimens for Presumed GI Primary Site

CapeOX
Oxaliplatin 130 mg/m² IV Day 1
Capecitabine 850–1000 mg/m² PO twice daily Days 1–14
Repeat every 3 weeks[4]

FOLFIRI[b]
Irinotecan 180 mg/m² IV Day 1
Leucovorin 400 mg/m² IV infusion to match duration of irinotecan infusion Day 1
Fluorouracil 400 mg/m² IV bolus Day 1, then
Fluorouracil 1200 mg/m²/day IV continuous infusion x 2 days (total 2400 mg/m² over 46–48 hours)
Repeat every 2 weeks[5-9]

mFOLFOX6[b]
Oxaliplatin 85 mg/m² IV Day 1
Leucovorin 400 mg/m² IV Day 1
Fluorouracil 400 mg/m² IV bolus Day 1, then
Fluorouracil 1200 mg/m²/day IV continuous infusion x 2 days (total 2400 mg/m² over 46–48 hours)
Repeat every 2 weeks[4,10]

[b] Leucovorin is indicated with certain fluorouracil-based regimens. Depending on availability, these regimens may be used with or without leucovorin.

Note: All recommendations are category 2A unless otherwise indicated.

Continued on OCC-B 4 of 14
References on OCC-B 13 of 14

Version 2.2025, 09/11/2024 © 2024 National Comprehensive Cancer Network® (NCCN®), All rights reserved. NCCN Guidelines® and this illustration may not be reproduced in any form without the express written permission of NCCN.

Printed by Elizabeth Moore on 4/30/2025 10:21:39 AM. For personal use only. Not approved for distribution. Copyright © 2025 National Comprehensive Cancer Network, Inc., All Rights Reserved.

PRINCIPLES OF SYSTEMIC THERAPY

DOSING SCHEDULES FOR OCCULT PRIMARIES: ADENOCARCINOMA

Other Recommended Regimens

Capecitabine[c]
Capecitabine 850–1250 mg/m² PO twice daily Days 1–14
Repeat every 3 weeks[11]

Docetaxel and carboplatin
Docetaxel 65 mg/m² IV Day 1
Carboplatin AUC 5–6 IV Day 1
Repeat every 3 weeks[13]

Docetaxel and cisplatin
Docetaxel 60–75 mg/m² IV Day 1
Cisplatin 75 mg/m² IV Day 1
Repeat every 3 weeks[14]

Gemcitabine and carboplatin
Gemcitabine 1000 mg/m² IV Days 1 and 8
Carboplatin AUC 5 IV Day 8
Repeat every 3 weeks[19]

Gemcitabine and docetaxel
Gemcitabine 1000 mg/m² IV Days 1 and 8
Docetaxel 75 mg/m² IV Day 8
Repeat every 3 weeks[20]

Irinotecan and carboplatin
Irinotecan 60 mg/m² IV Days 1, 8, and 15
Carboplatin AUC 5–6 IV Day 1
Repeat every 4 weeks[21]

Bolus or infusional fluorouracil[c]/leucovorin[b] Roswell Park regimen
Leucovorin 500 mg/m² IV Days 1, 8, 15, 22, 29, and 36
Fluorouracil 500 mg/m² IV bolus 1 hour after start of leucovorin
Days 1, 8, 15, 22, 29, and 36
Repeat every 8 weeks[15]

Simplified biweekly infusional fluorouracil[c]/leucovorin[b] (sLV5FU2)
Leucovorin 400 mg/m² IV Day 1, followed by
Fluorouracil 400 mg/m² IV bolus, then
Fluorouracil 1200 mg/m²/day IV continuous infusion x 2 days
(total 2400 mg/m² over 46–48 hours)
Repeat every 2 weeks[16]

Weekly fluorouracil[c] and leucovorin[b] regimens
Leucovorin 20 mg/m² IV Day 1,
Fluorouracil 500 mg/m² IV bolus injection 1 hour after the start of leucovorin
Repeat every week[17]
OR
Fluorouracil 2600 mg/m² by 24-hour infusion plus leucovorin 500 mg/m² IV Day 1
Repeat every week[17]

[b] Leucovorin is indicated with certain fluorouracil-based regimens. Depending on availability, these regimens may be used with or without leucovorin.
[c] For patients with presumed GI primary site.

Continued on OCC-B 5 of 14
References on OCC-B 13 of 14

Note: All recommendations are category 2A unless otherwise indicated.

Version 2.2025, 09/11/2024 © 2024 National Comprehensive Cancer Network® (NCCN®), All rights reserved. NCCN Guidelines® and this illustration may not be reproduced in any form without the express written permission of NCCN.

Printed by Elizabeth Moore on 4/30/2025 10:21:39 AM. For personal use only. Not approved for distribution. Copyright © 2025 National Comprehensive Cancer Network, Inc., All Rights Reserved.

PRINCIPLES OF SYSTEMIC THERAPY

DOSING SCHEDULES FOR OCCULT PRIMARIES: ADENOCARCINOMA

Other Recommended Regimens

Chemotherapy with Concurrent Radiation[c]

Capecitabine with radiation
Capecitabine 625–825 mg/m^2 PO twice daily Days 1–5
Repeat every week for 5 weeks with radiation[12]

Fluorouracil with radiation
Fluorouracil 200–250 mg/m^2 IV continuous infusion over 24 hours daily Days 1–5
Repeat every week for 5 weeks with radiation[18]

[c] For patients with presumed GI primary site.

Continued on OCC-B 6 of 14

References on OCC-B 13 of 14

Note: All recommendations are category 2A unless otherwise indicated.

Version 2.2025, 09/11/2024 © 2024 National Comprehensive Cancer Network® (NCCN®), All rights reserved. NCCN Guidelines® and this illustration may not be reproduced in any form without the express written permission of NCCN.

Printed by Elizabeth Moore on 4/30/2025 10:21:39 AM. For personal use only. Not approved for distribution. Copyright © 2025 National Comprehensive Cancer Network, Inc., All Rights Reserved.

PRINCIPLES OF SYSTEMIC THERAPY

DOSING SCHEDULES FOR OCCULT PRIMARIES: ADENOCARCINOMA

Useful in Certain Circumstances

FOLFIRINOX[b,c,k]
Oxaliplatin 85 mg/m² IV Day 1
Irinotecan 180 mg/m² IV Day 1
Leucovorin 400 mg/m² IV Day 1
Fluorouracil 400 mg/m² IV push Day 1
Fluorouracil 1200 mg/m² over 24 hours IV continuous infusion X 2 days (total 2400 mg/m² over 46–48 hours) starting Day 1
Repeat every 2 weeks[33]

Irinotecan and gemcitabine[l]
Irinotecan 100 mg/m² IV Days 1 and 8
Gemcitabine 1000 mg/m² IV Days 1 and 8
Repeat every 3 weeks[34]

mFOLFIRINOX[b,c,k]
Oxaliplatin 85 mg/m² IV Day 1
Irinotecan 150 mg/m² IV Day 1
Leucovorin 400 mg/m² IV Day 1
Fluorouracil 1200 mg/m² over 24 hours IV continuous infusion x 2 days (total 2400 mg/m² over 46–48 hours) starting Day 1
Repeat every 2 weeks[35,36]

Paclitaxel, carboplatin, and etoposide[k]
Paclitaxel 175–200 mg/m² IV Day 1
Carboplatin AUC 5–6 IV Day 1
Etoposide 50 mg/day PO alternating with 100 mg/day Days 1–10
Repeat every 3 weeks[37]

Continued on OCC-B 7 of 14
Footnotes on OCC-B 7A of 14

References on OCC-B 13 of 14

Note: All recommendations are category 2A unless otherwise indicated.

Version 2.2025, 09/11/2024 © 2024 National Comprehensive Cancer Network® (NCCN®), All rights reserved. NCCN Guidelines® and this illustration may not be reproduced in any form without the express written permission of NCCN.

Printed by Elizabeth Moore on 4/30/2025 10:21:39 AM. For personal use only. Not approved for distribution. Copyright © 2025 National Comprehensive Cancer Network, Inc., All Rights Reserved.

PRINCIPLES OF SYSTEMIC THERAPY

DOSING SCHEDULES FOR OCCULT PRIMARIES: ADENOCARCINOMA

Useful in Certain Circumstances: Biomarker-Driven Therapy

***BRAF* V600E Mutation-Positive Tumors**
Dabrafenib + trametinib[e]
Dabrafenib 150 mg PO twice daily
Trametinib 2 mg PO daily
Repeat every 4 weeks[22]

dMMR/MSI-H Tumors
Dostarlimab-gxly[f,g]
500 mg IV Day 1
Repeat every 3 weeks for 4 doses followed by 1000 mg IV Day 1
Repeat every 6 weeks[23]

Pembrolizumab[f]
200 mg IV Day 1
Repeat every 3 weeks[24-26]
OR
400 mg IV Day 1
Repeat every 6 weeks[24-26]

***NTRK* Gene Fusion-Positive Tumors**
Entrectinib[h]
600 mg PO daily
Repeat every 4 weeks[27]

Larotrectinib[h]
100 mg PO twice daily
Repeat every 4 weeks[28]

Repotrectinib[h]
160 mg PO once daily for 14 days,
then increase to 160 mg PO twice daily[29]

TMB-H (≥10 mut/Mb) Tumors
Pembrolizumab[f]
200 mg IV Day 1
Repeat every 3 weeks[24-26,30]
OR
400 mg IV Day 1
Repeat every 6 weeks[24-26,30]

***RET* Gene Fusion-Positive Tumors**
Selpercatinib[j]
<50 kg: 120 mg PO twice daily[32]
≥50 kg: 160 mg PO twice daily[32]

HER2-Positive (IHC 3+) Tumors
Fam-trastuzumab deruxtecan-nxki[i]
5.4 mg/kg IV Day 1
Repeat every 21 days[31]

Note: All recommendations are category 2A unless otherwise indicated.

Footnotes on OCC-B 7A of 14

References on OCC-B 13 of 14

Version 2.2025, 09/11/2024 © 2024 National Comprehensive Cancer Network® (NCCN®), All rights reserved. NCCN Guidelines® and this illustration may not be reproduced in any form without the express written permission of NCCN.

Printed by Elizabeth Moore on 4/30/2025 10:21:39 AM. For personal use only. Not approved for distribution. Copyright © 2025 National Comprehensive Cancer Network, Inc., All Rights Reserved.

PRINCIPLES OF SYSTEMIC THERAPY

FOOTNOTES

[a] Consider programmed death ligand 1 (PD-L1) testing for patients with recurrent, progressive, or metastatic disease.
[b] Leucovorin is indicated with certain fluorouracil-based regimens. Depending on availability, these regimens may be used with or without leucovorin.
[c] For patients with presumed gastrointestinal (GI) primary site.
[d] These regimens can be given with concurrent radiation.
[e] For patients with *BRAF* V600E mutation-positive unresectable or metastatic solid tumors that have progressed following prior treatment and have no satisfactory alternative treatment options.
[f] NCCN Guidelines for Management of Immunotherapy-Related Toxicities.
[g] For patients with recurrent or advanced tumors that have progressed on or following prior treatment and who have no satisfactory alternative treatment options. Note, patients who had received prior immune checkpoint inhibitor therapy were excluded from the dostarlimab-gxly clinical trial.
[h] For patients with *NTRK* gene fusion-positive tumors without a known acquired resistance mutation, that are metastatic or where surgical resection is likely to result in severe morbidity, and that have no satisfactory alternative treatments or that have progressed following treatment.
[i] For patients with advanced or metastatic solid tumors that progressed on or following prior systemic treatment and who have no satisfactory alternative treatment options.
[j] For patients with advanced or metastatic solid tumors that progressed on or following prior systemic treatment or who have no satisfactory alternative treatment options.
[k] Only for patients with PS ECOG 0–1.
[l] For patients ineligible to receive platinum-based chemotherapy.

Continued on OCC-B 8 of 14

References on OCC-B 13 of 14

Note: All recommendations are category 2A unless otherwise indicated.

Version 2.2025, 09/11/2024 © 2024 National Comprehensive Cancer Network® (NCCN®), All rights reserved. NCCN Guidelines® and this illustration may not be reproduced in any form without the express written permission of NCCN.

Printed by Elizabeth Moore on 4/30/2025 10:21:39 AM. For personal use only. Not approved for distribution. Copyright © 2025 National Comprehensive Cancer Network, Inc., All Rights Reserved.

PRINCIPLES OF SYSTEMIC THERAPY

Selected Systemic Therapy for Occult Primaries: Squamous Cell Carcinoma[a]

Regimens are listed in alphabetical order by category of preference.

Preferred Regimens	Other Recommended Regimens	Useful in Certain Circumstances
• Carboplatin and paclitaxel[1,2] • mFOLFOX6[b,4,10]	• Capecitabine[d,11,12] • Cisplatin and fluorouracil[d,38-40] • Docetaxel and carboplatin[41] • Docetaxel and cisplatin[14,42] • Fluorouracil[b,d,15-18] • Gemcitabine and carboplatin[19] • Gemcitabine and cisplatin[3] • Paclitaxel and cisplatin[43]	**Biomarker-Driven Therapy** ***BRAF* V600E mutation-positive tumors** • Dabrafenib + trametinib[e,22] ***NTRK* gene fusion-positive tumors** • Entrectinib[h,27] • Larotrectinib[h,28] • Repotrectinib[h,29] **HER2-positive (IHC 3+) tumors** • Fam-trastuzumab deruxtecan-nxki[i,31] ***RET* gene fusion-positive tumors** • Selpercatinib (category 2B)[j,32] **dMMR/MSI-H tumors or TMB-H (≥10 mut/Mb) tumors** • Pembrolizumab[f,24-26,30] **Cytotoxic Chemotherapy** • Docetaxel, cisplatin, and fluorouracil[k,44]

[a] Consider programmed death ligand 1 (PD-L1) testing for patients with recurrent, progressive, or metastatic disease.
[b] Leucovorin is indicated with certain fluorouracil-based regimens. Depending on availability, these regimens may be used with or without leucovorin.
[d] These regimens can be given with concurrent radiation.
[e] For patients with *BRAF* V600E mutation-positive unresectable or metastatic solid tumors that have progressed following prior treatment and have no satisfactory alternative treatment options.
[f] NCCN Guidelines for Management of Immunotherapy-Related Toxicities.
[h] For patients with *NTRK* gene fusion-positive tumors without a known acquired resistance mutation, that are metastatic or where surgical resection is likely to result in severe morbidity, and that have no satisfactory alternative treatments or that have progressed following treatment.
[i] For patients with advanced or metastatic solid tumors that progressed on or following prior systemic treatment and who have no satisfactory alternative treatment options.
[j] For patients with advanced or metastatic solid tumors that progressed on or following prior systemic treatment or who have no satisfactory alternative treatment options.
[k] Only for patients with PS ECOG 0–1.
[l] For patients ineligible to receive platinum-based chemotherapy.

Note: All recommendations are category 2A unless otherwise indicated.

Continued on OCC-B 9 of 14

References on OCC-B 13 of 14

Version 2.2025, 09/11/2024 © 2024 National Comprehensive Cancer Network® (NCCN®), All rights reserved. NCCN Guidelines® and this illustration may not be reproduced in any form without the express written permission of NCCN.

Printed by Elizabeth Moore on 4/30/2025 10:21:39 AM. For personal use only. Not approved for distribution. Copyright © 2025 National Comprehensive Cancer Network, Inc., All Rights Reserved.

PRINCIPLES OF SYSTEMIC THERAPY

DOSING SCHEDULES FOR OCCULT PRIMARIES: SQUAMOUS CELL CARCINOMA

Preferred Regimens

Carboplatin and paclitaxel
Paclitaxel 175–200 mg/m² IV Day 1
Carboplatin AUC 5–6 IV Day 1
Repeat every 3 weeks[1]
OR
Paclitaxel 80 mg/m² IV Days 1, 8, and 15
Carboplatin AUC 2 IV Days 1, 8, and 15
Repeat every 4 weeks[2]

mFOLFOX6[b]
Oxaliplatin 85 mg/m² IV Day 1
Leucovorin 400 mg/m² IV Day 1
Fluorouracil 400 mg/m² IV bolus Day 1, then
Fluorouracil 1200 mg/m²/day IV continuous infusion x 2 days
(total 2400 mg/m² over 46–48 hours)
Repeat every 2 weeks[4,10]

[b] Leucovorin is indicated with certain fluorouracil-based regimens. Depending on availability, these regimens may be used with or without leucovorin.

Continued on OCC-B 10 of 14

References on OCC-B 13 of 14

Note: All recommendations are category 2A unless otherwise indicated.

Version 2.2025, 09/11/2024 © 2024 National Comprehensive Cancer Network® (NCCN®), All rights reserved. NCCN Guidelines® and this illustration may not be reproduced in any form without the express written permission of NCCN.

Printed by Elizabeth Moore on 4/30/2025 10:21:39 AM. For personal use only. Not approved for distribution. Copyright © 2025 National Comprehensive Cancer Network, Inc., All Rights Reserved.

PRINCIPLES OF SYSTEMIC THERAPY

DOSING SCHEDULES FOR OCCULT PRIMARIES: SQUAMOUS CELL CARCINOMA

Other Recommended Regimens

Capecitabine
Capecitabine 850–1250 mg/m² PO twice daily Days 1–14
Repeat every 3 weeks[11]

Cisplatin and fluorouracil
Cisplatin 20 mg/m² IV Days 1–5
Fluorouracil 700 mg/m²/day IV continuous infusion Days 1–5
Repeat every 4 weeks[38]

Docetaxel and carboplatin
Docetaxel 75 mg/m² IV Day 1
Carboplatin AUC 5–6 IV Day 1
Repeat every 3 weeks[41]

Docetaxel and cisplatin
Docetaxel 60–75 mg/m² IV Day 1
Cisplatin 75 mg/m² IV Day 1
Repeat every 3 weeks[14,42]

Gemcitabine and carboplatin
Gemcitabine 1000 mg/m² IV Days 1 and 8
Carboplatin AUC 5 IV Day 8
Repeat every 3 weeks[19]

Gemcitabine and cisplatin
Cisplatin 75 mg/m² IV Day 1
Gemcitabine 1000–1250 mg/m² IV Days 1 and 8
Repeat every 3 weeks[3]

Bolus or infusional fluorouracil/leucovorin[b] Roswell Park regimen
Leucovorin 500 mg/m² IV Days 1, 8, 15, 22, 29, and 36
Fluorouracil 500 mg/m² IV bolus 1 hour after start of leucovorin Days 1, 8, 15, 22, 29, and 36
Repeat every 8 weeks[15]

Simplified biweekly infusional fluorouracil/leucovorin[b] (sLV5FU2)
Leucovorin 400 mg/m² IV Day 1, followed by
Fluorouracil 400 mg/m² IV bolus and then
Fluorouracil 1200 mg/m²/day IV continuous infusion x 2 days
(total 2400 mg/m² over 46–48 hours)
Repeat every 2 weeks[16]

Weekly fluorouracil and leucovorin[b] regimens
Leucovorin 20 mg/m² IV Day 1,
Fluorouracil 500 mg/m² IV bolus injection 1 hour after the start of leucovorin
Repeat every week[17]
OR
Fluorouracil 2600 mg/m² by 24-hour infusion plus
leucovorin 500 mg/m² IV Day 1
Repeat every week[17]

Paclitaxel and cisplatin
Paclitaxel 175 mg/m² IV Day 1
Cisplatin 60 mg/m² IV Day 1
Repeat every 3 weeks[43]

[b] Leucovorin is indicated with certain fluorouracil-based regimens. Depending on availability, these regimens may be used with or without leucovorin.

Continued on OCC-B 11 of 14

References on OCC-B 13 of 14

Note: All recommendations are category 2A unless otherwise indicated.

Version 2.2025, 09/11/2024 © 2024 National Comprehensive Cancer Network® (NCCN®), All rights reserved. NCCN Guidelines® and this illustration may not be reproduced in any form without the express written permission of NCCN.

Printed by Elizabeth Moore on 4/30/2025 10:21:39 AM. For personal use only. Not approved for distribution. Copyright © 2025 National Comprehensive Cancer Network, Inc., All Rights Reserved.

PRINCIPLES OF SYSTEMIC THERAPY

DOSING SCHEDULES FOR OCCULT PRIMARIES: SQUAMOUS CELL CARCINOMA

Other Recommended Regimens

Chemotherapy with Concurrent Radiation

Capecitabine with radiation
Capecitabine 625–825 mg/m^2 PO twice daily Days 1–5
Repeat every week for 5 weeks[12]

Fluorouracil with radiation
Fluorouracil 200–250 mg/m^2 IV continuous infusion over 24 hours daily Days 1–5
Repeat every week for 5 weeks with radiation[18]

Fluorouracil and cisplatin with radiation
Cisplatin 75–100 mg/m^2 IV Days 1 and 29
Fluorouracil 750–1000 mg/m^2 IV continuous infusion over 24 hours daily Days 1–4 and 29–32
35-day cycle with radiation[39]
or
Cisplatin 15 mg/m^2 IV Days 1–5
Fluorouracil 800 mg/m^2 IV continuous infusion over 24 hours daily Days 1–5
21-day cycle for 2 cycles with radiation[40]

Useful in Certain Circumstances

Cytotoxic Chemotherapy

Docetaxel, cisplatin, and fluorouracil[k]
Docetaxel 75 mg/m^2 IV Day 1
Cisplatin 75 mg/m^2 IV Day 1
Fluorouracil 750 mg/m^2/day IV continuous infusion Days 1–5
Repeat every 3 weeks[44]

[k] Only for patients with PS ECOG 0–1.

Continued on OCC-B 12 of 14

References on OCC-B 13 of 14

Note: All recommendations are category 2A unless otherwise indicated.

Version 2.2025, 09/11/2024 © 2024 National Comprehensive Cancer Network® (NCCN®), All rights reserved. NCCN Guidelines® and this illustration may not be reproduced in any form without the express written permission of NCCN.

Printed by Elizabeth Moore on 4/30/2025 10:21:39 AM. For personal use only. Not approved for distribution. Copyright © 2025 National Comprehensive Cancer Network, Inc., All Rights Reserved.

PRINCIPLES OF SYSTEMIC THERAPY

DOSING SCHEDULES FOR OCCULT PRIMARIES: SQUAMOUS CELL CARCINOMA

Useful in Certain Circumstances: Biomarker-Driven Therapy

***BRAF* V600E Mutation-Positive Tumors**
Dabrafenib + trametinib[e]
Dabrafenib 150 mg PO twice daily
Trametinib 2 mg PO daily
Repeat every 4 weeks[22]

***NTRK* Gene Fusion-Positive Tumors**
Entrectinib[h]
600 mg PO daily
Repeat every 4 weeks[27]

Larotrectinib[h]
100 mg PO twice daily
Repeat every 4 weeks[28]

Repotrectinib[h]
160 mg PO once daily for 14 days,
then increase to 160 mg PO twice daily[29]

dMMR/MSI-H Tumors or TMB-H (≥10 mut/Mb) Tumors
Pembrolizumab[f,24-26,30]
200 mg IV Day 1
Repeat every 3 weeks[26]
OR
400 mg IV Day 1
Repeat every 6 weeks[25]

HER2-Positive (IHC 3+) Tumors
Fam-trastuzumab deruxtecan-nxki[i]
5.4 mg/kg IV Day 1
Repeat every 21 days[31]

***RET* Gene Fusion-Positive Tumors**
Selpercatinib[j]
<50 kg: 120 mg PO twice daily[32]
≥50 kg: 160 mg PO twice daily[32]

[e] For patients with *BRAF* V600E mutation-positive unresectable or metastatic solid tumors that have progressed following prior treatment and have no satisfactory alternative treatment options.
[f] NCCN Guidelines for Management of Immunotherapy-Related Toxicities.
[h] For patients with *NTRK* gene fusion-positive tumors without a known acquired resistance mutation, that are metastatic or where surgical resection is likely to result in severe morbidity, and that have no satisfactory alternative treatments or that have progressed following treatment.
[i] For patients with advanced or metastatic solid tumors that progressed on or following prior systemic treatment and who have no satisfactory alternative treatment options.
[j] For patients with locally advanced or metastatic solid tumors that progressed on or following prior systemic treatment or who have no satisfactory alternative treatment options.

Note: All recommendations are category 2A unless otherwise indicated.

References on OCC-B 13 of 14

Version 2.2025, 09/11/2024 © 2024 National Comprehensive Cancer Network® (NCCN®), All rights reserved. NCCN Guidelines® and this illustration may not be reproduced in any form without the express written permission of NCCN.

Printed by Elizabeth Moore on 4/30/2025 10:21:39 AM. For personal use only. Not approved for distribution. Copyright © 2025 National Comprehensive Cancer Network, Inc., All Rights Reserved.

PRINCIPLES OF SYSTEMIC THERAPY

REFERENCES

[1] Briasoulis E, Kalofonos H, Bafaloukos D, et al. Carboplatin plus paclitaxel in unknown primary carcinoma: A phase II Hellenic Cooperative Oncology Group Study. J Clin Oncol 2000;18:3101-3107.
[2] Berry W, Elkordy M, O'Rourke M, et al. Results of a phase II study of weekly paclitaxel plus carboplatin in advanced carcinoma of unknown primary origin: a reasonable regimen for the community-based clinic? Cancer Invest 2007;25:27-31.
[3] Gross-Goupil M, Fourcade A, Blot E, et al. Cisplatin alone or combined with gemcitabine in carcinomas of unknown primary: Results of the randomised GEFCAPI 02 trial. Eur J Cancer 2012;48:721-727.
[4] Cassidy J, Clarke S, Diaz-Rubio E, et al. Randomized phase III study of capecitabine plus oxaliplatin compared with fluorouracil/folinic acid plus oxaliplatin as first-line therapy for metastatic colorectal cancer. J Clin Oncol 2008;26:2006-2012.
[5] Guimbaud R, Louvet C, Ries P, et al. Prospective, randomized, multicenter, phase III study of fluorouracil, leucovorin, and irinotecan versus epirubicin, cisplatin, and capecitabine in advanced gastric adenocarcinoma: a french intergroup (Fédération Francophone de Cancérologie Digestive, Fédération Nationale des Centres de Lutte Contre le Cancer, and Groupe Coopérateur Multidisciplinaire en Oncologie) study. J Clin Oncol 2014;32:3520-3526.
[6] Sebbagh S, Roux J, Dreyer C, et al. Efficacy of a sequential treatment strategy with GEMOX-based followed by FOLFIRI-based chemotherapy in advanced biliary tract cancers. Acta Oncol 2016;55:1168-1174.
[7] Zaniboni A, Aitini E, Barni S, et al. FOLFIRI as second-line chemotherapy for advanced pancreatic cancer: a GISCAD multicenter phase II study. Cancer Chemother Pharmacol 2012;69:1641-1645.
[8] Fuchs CS, Marshall J, Mitchell E, et al. Randomized, controlled trial of irinotecan plus infusional, bolus, or oral fluoropyrimidines in first-line treatment of metastatic colorectal cancer: results from the BICC-C Study. J Clin Oncol 2007;25:4779-4786.
[9] Hainsworth JD, Schnabel CA, Erlander MG, et al. A retrospective study of treatment outcomes in patients with carcinoma of unknown primary site and a colorectal cancer molecular profile. Clin Colorectal Cancer 2012;11:112-118.
[10] Cheeseman SL, Joel SP, Chester JD, et al. A 'modified de Gramont' regimen of fluorouracil, alone and with oxaliplatin, for advanced colorectal cancer. Br J Cancer 2002;87:393-399.
[11] Twelves C, Wong A, Nowacki MP, et al. Capecitabine as adjuvant treatment for stage III colon cancer. N Engl J Med 2005;352:2696-2704.
[12] Lee HS, Choi Y, Hur WJ, et al. Pilot study of postoperative adjuvant chemoradiation for advanced gastric cancer: adjuvant 5-FU/cisplatin and chemoradiation with capecitabine. World J Gastroenterol 2006;12:603-607.
[13] Greco FA, Erland JB, Morrissey LH, et al. Carcinoma of unknown primary site: phase II trials with docetaxel plus cisplatin or carboplatin. Ann Oncol 2000;11:211-215.
[14] Demirci U, Coskun U, Karaca H, et al. Docetaxel and cisplatin in first line treatment of patients with unknown primary cancer: a multicenter study of the Anatolian Society of Medical Oncology. Asian Pac J Cancer Prev 2014;15:1581-1584.
[15] Wolmark N, Rockette H, Fisher B, et al. The benefit of leucovorin-modulated fluorouracil as postoperative adjuvant therapy for primary colon cancer: results from National Surgical Adjuvant Breast and Bowel protocol C-03. J Clin Oncol 1993;11:1879-1887.
[16] Andre T, Louvet C, Maindrault-Goebel F, et al. CPT-11 (irinotecan) addition to bimonthly, high-dose leucovorin and bolus and continuous-infusion 5-fluorouracil (FOLFIRI) for pretreated metastatic colorectal cancer. GERCOR. Eur J Cancer 1999;35:1343-1347.
[17] Jäger E, Heike M, Bernhard H, et al. Weekly high-dose leucovorin versus low-dose leucovorin combined with fluorouracil in advanced colorectal cancer: results of a randomized multicenter trial. J Clin Oncol 1996;14:2274-2279.
[18] Leong T, Joon DL, Willis D, et al. Adjuvant chemoradiation for gastric cancer using epirubicin, cisplatin, and 5-fluorouracil before and after three-dimensional conformal radiotherapy with concurrent infusional 5-fluorouracil: a multicenter study of the Trans-Tasman Radiation Oncology Group. Int J Radiat Oncol Biol Phys 2011;79:690-695.
[19] Pittman KB, Olver IN, Koczwara B, et al. Gemcitabine and carboplatin in carcinoma of unknown primary site: a phase 2 Adelaide Cancer Trials and Education Collaborative study. Br J Cancer 2006;95:1309-1313.
[20] Pouessel D, Culine S, Becht C, et al. Gemcitabine and docetaxel as front-line chemotherapy in patients with carcinoma of an unknown primary site. Cancer 2004;100:1257-1261.
[21] Yonemori K, Ando M, Yunokawa M, et al. Irinotecan plus carboplatin for patients with carcinoma of unknown primary site. Br J Cancer 2009;100:50-55.

Continued on OCC-B 14 of 14

Note: All recommendations are category 2A unless otherwise indicated.

Version 2.2025, 09/11/2024 © 2024 National Comprehensive Cancer Network® (NCCN®), All rights reserved. NCCN Guidelines® and this illustration may not be reproduced in any form without the express written permission of NCCN.

Printed by Elizabeth Moore on 4/30/2025 10:21:39 AM. For personal use only. Not approved for distribution. Copyright © 2025 National Comprehensive Cancer Network, Inc., All Rights Reserved.

PRINCIPLES OF SYSTEMIC THERAPY

REFERENCES

[22] Salama AKS, Li S, Macrae ER, et al. Dabrafenib and trametinib in patients with tumors with BRAFV600E mutations: Results of the NCI-MATCH trial Subprotocol H. J Clin Oncol 2020;38:3895-3904.
[23] Berton D, Banerjee SN, Curigliano G, et al. Antitumor activity of dostarlimab in patients with mismatch repair-deficient/microsatellite instability–high tumors: A combined analysis of two cohorts in the GARNET study [Abstract]. J Clin Oncol 2021;39(Suppl):Abstract 2564.
[24] Eggermont AM, Blank CU, Mandala M, et al. Adjuvant pembrolizumab versus placebo in resected stage III melanoma. N Engl J Med 2018;378:1789-1801.
[25] Lala M, Li TR, De Alwis DP, et al. A six-weekly dosing schedule for pembrolizumab in patients with cancer based on evaluation using modelling and simulation. Eur J Cancer 2020;131:68-75.
[26] Marabelle A, Le DT, Ascierto P, et al. Efficacy of pembrolizumab in patients with noncolorectal high microsatellite instability/mismatch repair-deficient cancer: results from the phase 2 KEYNOTE-158 study. J Clin Oncol 2020;38:1-10.
[27] Doebele RC, Drilon A, Paz-Ares L, et al. Entrectinib in patients with advanced or metastatic NTRK fusion-positive solid tumours: integrated analysis of three phase 1-2 trials. Lancet Oncol 2020;21:271-282. Erratum in Lancet Oncol 2020;21:e70; Lancet Oncol 2020;21:e341; Lancet Oncol 2020;21:e372; and Lancet Oncol 2021;22:e428.
[28] Drilon A, Laetsch TW, Kummar S, et al. Efficacy of larotrectinib in TRK fusion-positive cancers in adults and children. N Engl J Med 2018;378:731-739.
[29] Solomon BJ, Drilon A, Lin JJ, et al. Repotrectinib in patients with NTRK fusion-positive advanced solid tumors, including non-small cell lung cancer: update from the phase 1/2 TRIDENT-1 trial [abstract]. Eur Soc Med Onc Congress 2023;34(Suppl 2):Abstract 1372P.
[30] Marabelle A, Fakih M, Lopez J, et al. Association of tumour mutational burden with outcomes in patients with advanced solid tumours treated with pembrolizumab: prospective biomarker analysis of the multicohort, open-label, phase 2 KEYNOTE-158 study. Lancet Oncol 2020;21:1353-1365.
[31] Meric-Bernstam F, Makker V, Oaknin A, et al. Efficacy and safety of trastuzumab deruxtecan in patients with HER2-expressing solid tumors: primary results from the DESTINY-PanTumor02 phase II trial. J Clin Oncol 2024;42:47-58.
[32] Subbiah V, Wolf J, Konda B, et al. Tumour-agnostic efficacy and safety of selpercatinib in patients with RET fusion-positive solid tumours other than lung or thyroid tumours (LIBRETTO-001): a phase 1/2, open-label, basket trial. Lancet Oncol 2022;23:1261-1273.
[33] Conroy T, Desseigne F, Ychou M, et al. FOLFIRINOX versus gemcitabine for metastatic pancreatic cancer. N Engl J Med 2011;364:1817-1825.
[34] Hainsworth JD, Spigel DR, Clark BL, et al. Paclitaxel/carboplatin/etoposide versus gemcitabine/irinotecan in the first-line treatment of patients with carcinoma of unknown primary site: a randomized, phase III Sarah Cannon Oncology Research Consortium Trial. Cancer J 2010;16:70-75.
[35] Conroy T, Hammel P, Hebbar M, et al. FOLFIRINOX or gemcitabine as adjuvant therapy for pancreatic cancer. N Engl J Med 2018;379:2395-2406.
[36] Lamarca A, Foster L, Valle JW, et al. FOLFIRINOX or FOLFOXIRI in locally advanced duodenal adenocarcinoma: are we missing out? [published correction appears in ESMO Open 2021;6:100138]. ESMO Open 2020;5:e000633.
[37] Greco FA, Burris HA III, Erland JB, et al. Carcinoma of unknown primary site. Cancer 2000;89:2655-2660.
[38] Kusaba H, Shibata Y, Arita S, et al. Infusional 5-fluorouracil and cisplatin as first-line chemotherapy in patients with carcinoma of unknown primary site. Med Oncol 2007;24:259-264.
[39] Tepper J, Krasna MJ, Niedzwiecki D, et al. Phase III trial of trimodality therapy with cisplatin, fluorouracil, radiotherapy, and surgery compared with surgery alone for esophageal cancer: CALGB 9781. J Clin Oncol 2008;26:1086-1092.
[40] Bedenne L, Michel P, Bouche O, et al. Chemoradiation followed by surgery compared with chemoradiation alone in squamous cancer of the esophagus: FFCD 9102. J Clin Oncol 2007;25:1160-1168.
[41] Pentheroudakis G, Briasoulis E, Kalofonos HP, et al. Docetaxel and carboplatin combination chemotherapy as outpatient palliative therapy in carcinoma of unknown primary: a multicentre Hellenic Cooperative Oncology Group phase II study. Acta Oncol 2008;47:1148-1155.
[42] Mukai H, Katsumata N, Ando M, Watanabe T. Safety and efficacy of a combination of docetaxel and cisplatin in patients with unknown primary cancer. Am J Clin Oncol 2010;33:32-35.
[43] Park YH, Ryoo BY, Choi SJ, et al. A phase II study of paclitaxel plus cisplatin chemotherapy in an unfavourable group of patients with cancer of unknown primary site. Jpn J Clin Oncol 2004;34:681-685.
[44] Pointreau Y, Garaud P, Chapet S, et al. Randomized trial of induction chemotherapy with cisplatin and 5-fluorouracil with or without docetaxel for larynx preservation. J Natl Cancer Inst 2009;101:498-506.

Note: All recommendations are category 2A unless otherwise indicated.

Version 2.2025, 09/11/2024 © 2024 National Comprehensive Cancer Network® (NCCN®), All rights reserved. NCCN Guidelines® and this illustration may not be reproduced in any form without the express written permission of NCCN.

Printed by Elizabeth Moore on 4/30/2025 10:21:39 AM. For personal use only. Not approved for distribution. Copyright © 2025 National Comprehensive Cancer Network, Inc., All Rights Reserved.

PRINCIPLES OF RADIATION THERAPY

General Principles

- **Consider definitive radiotherapy for patients with active disease.**
  - **Dosing regimen: Consider SBRT/SABR[1] for limited (1–3)[2] metastases and pulmonary metastases (48–60 Gy in 4–5 fractions).**

Adjuvant Therapy

- **Consider adjuvant RT after lymph node dissection if the disease is limited to a single nodal site with extranodal extension or inadequate nodal dissection with multiple positive nodes.**
  - **Dosing regimen: 45 Gy is recommended with or without boost of 5–9 Gy/1.8–2.0 Gy fraction to nodal basin for isolated supraclavicular, axillary, or inguinal nodal metastasis.**

Palliative Therapy

- **Consider palliative radiotherapy for symptomatic patients.**
  - **Hypofractionated RT can be used as palliative treatment for uncontrolled pain, impending pathologic fracture, or impending cord compression.**
  - **Dosing regimen: A number of hypofractionation regimens can be considered, but typically 8 Gy in 1 fraction, 20 Gy in 4–5 fractions, or 30 Gy in 10 fractions are most frequently used.**

[1] Palma DA, Olson R, Harrow S, et al. Stereotactic ablative radiotherapy versus standard of care palliative treatment in patients with oligometastatic cancers (SABR-COMET): a randomised, phase 2, open-label trial. Lancet 2019;393:2051-2058.
[2] Gomez DR, Blumenschein GR Jr, Lee JJ, et al. Local consolidative therapy versus maintenance therapy or observation for patients with oligometastatic non-small-cell lung cancer without progression after first-line systemic therapy: a multicentre, randomised, controlled, phase 2 study. Lancet Oncol 2016;17:1672-1682.

Note: All recommendations are category 2A unless otherwise indicated.

Version 2.2025, 09/11/2024 © 2024 National Comprehensive Cancer Network® (NCCN®), All rights reserved. NCCN Guidelines® and this illustration may not be reproduced in any form without the express written permission of NCCN.

Printed by Elizabeth Moore on 4/30/2025 10:21:39 AM. For personal use only. Not approved for distribution. Copyright © 2025 National Comprehensive Cancer Network, Inc., All Rights Reserved.

PRINCIPLES OF GENETIC/FAMILIAL CANCER RISK ASSESSMENT AND COUNSELING

See the NCCN Guidelines for Genetic/Familial High-Risk Assessment: Breast, Ovarian, and Pancreatic for the following:
- **Pre-test Counseling (EVAL-A 1 of 10)**
- **Principles of Cancer Risk Assessment and Counseling (EVAL-A)**
- **Pedigree: First-, Second-, and Third-Degree Relatives of Proband (EVAL-B)**
- **General Testing Criteria (CRIT-1)**
- **Cancer Risk Management Based on Genetic Test Results (GENE-A)**
- **Autosomal Recessive Risk in Cancer Genes – Multi-Gene Panel Testing (GENE-B)**
- ***BRCA* Pathogenic/Likely Pathogenic Variant-Positive Management (BRCA-A)**
- **Pancreatic Cancer Screening (PANC-A)**
- **Li-Fraumeni Syndrome Management in Adults (LIFR-A)**
- **Cowden Syndrome/PHTS Management (COWD-A)**
- **Summary of Genes and/or Syndromes Included/Mentioned in Other NCCN Guidelines (SUMM-1)**

See the NCCN Guidelines for Genetic/Familial High-Risk Assessment: Colorectal, Endometrial and Gastric for the following:
- **Principles of Cancer Risk Assessment and Counseling (EVAL-A)**
- **Multigene Testing (GENE-1)**
- **Lynch Syndrome (Hereditary Nonpolyposis Colorectal Cancer) (LS-1)**
- **Principles of dMMR Testing for Lynch Syndrome (LS-A)**
- **Gene-Specific Lynch Syndrome Cancer Risks and Surveillance/Prevention Strategies (LS-B through LS-E)**
- **Adenomatous Polyposis Testing Criteria (POLYP-1)**

Note: All recommendations are category 2A unless otherwise indicated.

Version 2.2025, 09/11/2024 © 2024 National Comprehensive Cancer Network® (NCCN®), All rights reserved. NCCN Guidelines® and this illustration may not be reproduced in any form without the express written permission of NCCN.

Printed by Elizabeth Moore on 4/30/2025 10:21:39 AM. For personal use only. Not approved for distribution. Copyright © 2025 National Comprehensive Cancer Network, Inc., All Rights Reserved.

ABBREVIATIONS

AUC	area under the curve
CA-15-3	cancer antigen 15-3
CA-19-9	cancer antigen 19-9
CA-125	cancer antigen 125
CBC	complete blood count
CEA	carcinoembryonic antigen
CK	cytokeratin
CNS	central nervous system
CUP	cancer of unknown primary
dMMR	mismatch repair deficient
EBV	Epstein-Barr virus
ECOG	Eastern Cooperative Oncology Group
FDG	fluorodeoxyglucose
FNA	fine-needle aspiration
GI	gastrointestinal
H&P	history and physical
hCG	human chorionic gonadotropin
HepPar-1	hepatocyte paraffin 1
HPV	human papillomavirus
IHC	immunohistochemistry
ISH	in situ hybridization
LCA	leukocyte common antigen, CD45, PTPRC
LDH	lactate dehydrogenase
LFT	liver function test
MMR	mismatch repair
MSI	microsatellite instability
MSI-H	microsatellite instability-high
NGS	next-generation sequencing
PAP	prostatic acid phosphatase
PCR	polymerase chain reaction
PD-L1	programmed death ligand 1
PLAP	placental alkaline phosphatase
PS	performance status
PSA	prostate-specific antigen
PSAP	prostate specific acid phosphatase
RCC	renal cell carcinoma
ROSE	rapid on-site evaluation
SABR	stereotactic ablative radiotherapy
SBRT	stereotactic body radiation therapy
TMB	tumor mutational burden
TMB-H	tumor mutational burden-high
TTF-1	thyroid transcription factor-1
WT1	Wilms tumor 1

Version 2.2025, 09/11/2024 © 2024 National Comprehensive Cancer Network® (NCCN®), All rights reserved. NCCN Guidelines® and this illustration may not be reproduced in any form without the express written permission of NCCN.

Printed by Elizabeth Moore on 4/30/2025 10:21:39 AM. For personal use only. Not approved for distribution. Copyright © 2025 National Comprehensive Cancer Network, Inc., All Rights Reserved.

NCCN Categories of Evidence and Consensus	
Category 1	Based upon high-level evidence (≥1 randomized phase 3 trials or high-quality, robust meta-analyses), there is uniform NCCN consensus (≥85% support of the Panel) that the intervention is appropriate.
Category 2A	Based upon lower-level evidence, there is uniform NCCN consensus (≥85% support of the Panel) that the intervention is appropriate.
Category 2B	Based upon lower-level evidence, there is NCCN consensus (≥50%, but <85% support of the Panel) that the intervention is appropriate.
Category 3	Based upon any level of evidence, there is major NCCN disagreement that the intervention is appropriate.

All recommendations are category 2A unless otherwise indicated.

NCCN Categories of Preference	
Preferred intervention	Interventions that are based on superior efficacy, safety, and evidence; and, when appropriate, affordability.
Other recommended intervention	Other interventions that may be somewhat less efficacious, more toxic, or based on less mature data; or significantly less affordable for similar outcomes.
Useful in certain circumstances	Other interventions that may be used for selected patient populations (defined with recommendation).

All recommendations are considered appropriate.

Note: All recommendations are category 2A unless otherwise indicated.

Version 2.2025, 09/11/2024 © 2024 National Comprehensive Cancer Network® (NCCN®), All rights reserved. NCCN Guidelines® and this illustration may not be reproduced in any form without the express written permission of NCCN.

Printed by Elizabeth Moore on 4/30/2025 10:21:39 AM. For personal use only. Not approved for distribution. Copyright © 2025 National Comprehensive Cancer Network, Inc., All Rights Reserved.

Discussion

This discussion corresponds to the NCCN Guidelines for Occult Primary. Last updated on September 11, 2024

Table of Contents

Overview MS-2
Literature Search Criteria and Guidelines Update Methodology MS-2
Sensitive/Inclusive Language Usage MS-3
Epidemiology MS-3
Presentation and Prognosis MS-4
Pathology MS-4
- Immunohistochemistry MS-5
- In Situ Hybridization MS-5
- Molecular Profiling MS-6
  - GEP and Molecular Cancer Classifier Assays for Tissue of Origin MS-6
  - Mutational Testing with Next-Generation Sequencing MS-7

Initial Evaluation MS-8
- Diagnostic Imaging MS-8

Workup MS-9
- Workup for Possible Breast Primary MS-10
- Workup for Possible Testicular Germ Cell Primary MS-10
- Workup for Possible Ovarian Primary MS-11
- Workup for Possible Prostate Primary MS-11
- Additional Workup for Localized Adenocarcinoma or Carcinoma Not Otherwise Specified MS-11
- Workup for Squamous Cell Carcinoma MS-11
- Workup for Neuroendocrine Tumors MS-12

Management MS-12
- Psychosocial Distress MS-12
- Supportive Care MS-12
- Treatment Based on Workup Findings MS-12
  - Adenocarcinoma MS-12
  - Squamous Cell Carcinoma MS-13
  - Neuroendocrine Tumors MS-14
- Systemic Therapy MS-14
  - Adenocarcinoma MS-14
  - Squamous Cell Carcinoma MS-20
  - Neuroendocrine Tumors MS-21
  - Leucovorin Shortage MS-22
- Radiation Therapy MS-22
- Locoregional Therapeutic Options MS-23
- Specialized Approaches MS-23

Follow-up MS-23
References MS-24

Version 2.2025 © 2024 National Comprehensive Cancer Network© (NCCN©), All rights reserved. NCCN Guidelines® and this illustration may not be reproduced in any form without the express written permission of NCCN.

Printed by Elizabeth Moore on 4/30/2025 10:21:39 AM. For personal use only. Not approved for distribution. Copyright © 2025 National Comprehensive Cancer Network, Inc., All Rights Reserved.

Overview

Occult primary tumors, or cancers of unknown primary (CUPs), are histologically confirmed metastatic tumors whose primary site cannot be identified during standard pretreatment evaluation.[1,2] These heterogeneous tumors have a wide variety of clinical presentations and a poor prognosis in most patients. Early dissemination, aggressiveness, and unpredictability of metastatic pattern are characteristic of these tumors.[3] Median survival is 8 to 12 months and depends on several prognostic factors that are discussed below.[2] Select patients with favorable subsets of CUP have median overall survival (OS) in the range of 12 to 36 months.[4,5]

These guidelines provide recommendations for evaluation, workup, management, and follow-up of two pathologic diagnoses in patients with epithelial occult primary cancer:

- Adenocarcinoma, or carcinoma not otherwise specified
- Squamous cell carcinoma (SCC)

Recommendations for neuroendocrine tumors or head and neck tumors of unknown primary origin can be found in the NCCN Guidelines for Neuroendocrine and Adrenal Tumors and the NCCN Guidelines for Head and Neck Cancers, respectively.

The NCCN Clinical Practice Guidelines in Oncology (NCCN Guidelines®) for Occult Primary suggest diagnostic tests based on the location of disease and histology. For SCC, the guidelines focus on the most common sites of clinical presentation, namely the head and neck nodes, supraclavicular nodes, axillary nodes, inguinal nodes, and bone. For adenocarcinoma, 12 different clinical presentations are addressed, with suggested diagnostic tests for each location. For each of the pathologic diagnoses, if a primary tumor is subsequently found, treatment should be based on recommendations in the NCCN Clinical Practice Guidelines for the cancer site corresponding to the primary tumor (see the list of NCCN Guidelines for Treatment by Cancer Type).

The management portion of the algorithm focuses on treatment of disseminated or localized disease for adenocarcinoma and site-specific SCC. The Panel endorses enrollment of patients in appropriate clinical trials when possible. In most patients with CUP, systemic therapy is palliative and does not significantly improve long-term survival. In patients with disseminated disease in particular, the treatment goals are directed toward symptom control and providing the best quality of life possible. However, certain clinical presentations of these tumors are associated with a better prognosis.[6] Special pathologic studies can identify subsets of patients with tumor types that are more responsive to systemic therapy. Treatment options should be individualized for this selected group of patients to achieve optimal response and survival rates.

Literature Search Criteria and Guidelines Update Methodology

Prior to the update of this version of the NCCN Guidelines® for Occult Primary (Cancer of Unknown Primary [CUP]), an electronic search of the PubMed database was performed to obtain key literature using the following search terms: occult primary cancer; cancer of unknown primary; carcinoma of unknown primary; and cancer of unknown origin. The PubMed database was chosen as it remains the most widely used resource for medical literature and indexes peer-reviewed biomedical literature.[7]

The search results were narrowed by selecting studies in humans published in English. Results were confined to the following article types: Clinical Trial, Phase II; Clinical Trial, Phase III; Clinical Trial, Phase IV; Guideline; Practice Guideline; Randomized Controlled Trial; Meta-Analysis; Systematic Reviews; and Validation Studies.

Version 2.2025 © 2024 National Comprehensive Cancer Network© (NCCN©), All rights reserved. NCCN Guidelines® and this illustration may not be reproduced in any form without the express written permission of NCCN.

Printed by Elizabeth Moore on 4/30/2025 10:21:39 AM. For personal use only. Not approved for distribution. Copyright © 2025 National Comprehensive Cancer Network, Inc., All Rights Reserved.

The data from key PubMed articles as well as articles from additional sources deemed as relevant to these guidelines and discussed by the Panel have been included in this version of the Discussion section (eg, e-publications ahead of print, meeting abstracts). Recommendations for which high-level evidence is lacking are based on the Panel's review of lower-level evidence and expert opinion.

NCCN recommendations have been developed to be inclusive of individuals of all sexual and gender identities to the greatest extent possible. When citing published studies and recommendations from other organizations, the terms used (eg, *male*, *female*) reflect the cited sources.

The complete details of the development and update of the NCCN Guidelines are available at www.NCCN.org.

Sensitive/Inclusive Language Usage

NCCN Guidelines strive to use language that advances the goals of equity, inclusion, and representation. NCCN Guidelines endeavor to use language that is person-first; not stigmatizing; anti-racist, anti-classist, anti-misogynist, anti-ageist, anti-ableist, and anti-weight-biased; and inclusive of individuals of all sexual orientations and gender identities. NCCN Guidelines incorporate non-gendered language, instead focusing on organ-specific recommendations. This language is both more accurate and more inclusive and can help fully address the needs of individuals of all sexual orientations and gender identities. NCCN Guidelines will continue to use the terms *men*, *women*, *female*, and *male* when citing statistics, recommendations, or data from organizations or sources that do not use inclusive terms. Most studies do not report how sex and gender data are collected and use these terms interchangeably or inconsistently. If sources do not differentiate gender from sex assigned at birth or organs present, the information is presumed to predominantly represent cisgender individuals. NCCN encourages researchers to collect more specific data in future studies and organizations to use more inclusive and accurate language in their future analyses.

Epidemiology

CUP has an average age at diagnosis of 60 to 75 years and accounts for 2% to 9% of all tumors.[2,8] CUP is among the 10 most frequently diagnosed tumors in developed countries.[2,9] An estimated 34,950 cases of CUP are expected to be diagnosed in the United States in 2024, accounting for approximately 2% of all U.S. cancers.[10] However, deaths from CUP are estimated to reach 49,240 in 2024. This discrepancy is believed to reflect a lack of specificity in recording the underlying cause of death on death certificates and/or an undercount in the case estimate. Recently, the incidence of CUP diagnoses has been decreasing, which is likely attributed to improved diagnostics and detection of primary tumors.[11] Unfortunately, no improvement in median survival was seen over this time period.

A study based on an analysis of the Swedish Family-Cancer Database revealed that CUP may have a genetic basis.[12] The analysis showed that 2.8% of occult primary cases were familial (ie, a parent and offspring were both diagnosed with occult primary cancer). In addition, CUP was associated with the occurrence of lung, kidney, and colorectal cancers in families, suggesting that these tumor types are often the primary sites of the disease.[12] A latent primary cancer may emerge during the natural course of the disease, although it is uncommon. In 20% to 50% of patients, the primary tumor is not identified even after postmortem examination.[8,13,14] Some data also suggest an epidemiologic correlation between smoking and risk of developing CUP.[15] A literature review found strong associations between CUP risk and smoking frequency (>20 cigarettes per day) as compared to individuals who never smoked. Individuals who smoked ≥40 years also had an increased likelihood of developing CUP (multivariable adjusted hazard ratio [HR], 1.45; 95%

Version 2.2025 © 2024 National Comprehensive Cancer Network© (NCCN©), All rights reserved. NCCN Guidelines® and this illustration may not be reproduced in any form without the express written permission of NCCN.

Printed by Elizabeth Moore on 4/30/2025 10:21:39 AM. For personal use only. Not approved for distribution. Copyright © 2025 National Comprehensive Cancer Network, Inc., All Rights Reserved.

confidence interval [CI], 1.09–1.94; *P*trend = .02) when compared to those who never smoked.

Presentation and Prognosis

Multiple sites of involvement are observed in >50% of patients with CUP.[16] Common sites of involvement are the liver, lungs, bones, and lymph nodes.[16,17] Although certain patterns of metastases suggest possible primary sites, CUP can metastasize to any site. Therefore, physicians should not rely on patterns of known metastases to determine the primary site in patients with CUP.

About 80% of patients with CUP have a poor prognosis and median OS of 3 to 10 months.[2,18] In general, adenocarcinomas and undifferentiated tumors have a worse prognosis than SCC (3.5% vs. 41.6% 3-year survival).[2] Other unfavorable prognostic features include male gender assigned at birth; older age (≥65 years); poor performance status (PS); multiple comorbidities; metastases involving multiple organs (eg, liver, lung, bone); nonpapillary malignant ascites (adenocarcinoma); peritoneal metastases; multiple cerebral metastases; and adenocarcinoma with multiple lung/pleural or bone lesions.[2,19-21] For these patients, an empiric approach to therapy is recommended, although the likelihood of survival benefit is questionable.

The 20% of patients with CUP with a more favorable prognosis include those with a single, small, and potentially resectable tumor; poorly differentiated carcinoma with midline nodal distribution; SCC involving cervical lymph nodes (constituting 2%–5% of all cases of occult primary cancers[22]); isolated inguinal adenopathy (SCC); poorly differentiated neuroendocrine (PDNE) carcinomas; women with papillary adenocarcinoma of the peritoneal cavity; women with adenocarcinoma involving only axillary lymph nodes; and men with blastic bone metastases and elevated prostate-specific antigen (PSA; adenocarcinoma).[2,19,23,24] For patients with favorable prognostic features, tailored approaches to treatment, such as locoregional treatments or specific systemic therapy regimens (eg, fluorouracil-based therapy for suspected colon primary or cisplatin-based therapy for possible germ cell tumor), are likely to provide clinical benefit and may prolong survival.

A robust prognostic model and nomogram to predict OS in patients with CUP was recently developed and externally validated using a large multicenter cohort of 926 patients.[5] Five independent prognostic factors were identified: gender assigned at birth, Eastern Cooperative Oncology Group (ECOG) PS, histology, number of metastatic sites, and neutrophil-lymphocyte ratio. Male gender assigned at birth, poor ECOG PS, adenocarcinoma histology, high number of metastatic sites, and high neutrophil-lymphocyte ratio were associated with worse survival in the Cox regression model. ECOG PS and neutrophil-lymphocyte ratio were the strongest predictors of OS ($P < .001$). The resulting model predicted OS with superior performance (concordance probability estimate [CPE] of 0.69 and concordance index of 0.71) compared with traditional prognostic classifiers. This model uses universally available baseline factors to ensure feasibility of use in diverse settings and can potentially aid in clinical decision-making as well as clinical trial selection and stratification.

Pathology

CUP can be classified into five major subtypes after routine evaluation with light microscopy. The most frequently occurring subtype is well- or moderately differentiated adenocarcinoma (60%), followed by poorly differentiated adenocarcinoma (25%), SCC (5%), undifferentiated carcinoma (5%), and neuroendocrine tumors (5%).[1,2] CUP often has multiple chromosomal abnormalities and overexpression of several genes, including *EGFR*, *MET, JAK3, BRAF, PIK3CA, c-kit/PDGFR (PDGFRα or PDGFRβ)*, *RAS*, *BCL2*, *HER2*, and *TP53*.[9,25-27] The *BRD4-NUT* oncogene, resulting from the chromosomal translocation t(15;19), has been identified in children and young adults with carcinoma of midline structures and

Version 2.2025 © 2024 National Comprehensive Cancer Network© (NCCN©), All rights reserved. NCCN Guidelines® and this illustration may not be reproduced in any form without the express written permission of NCCN.

Printed by Elizabeth Moore on 4/30/2025 10:21:39 AM. For personal use only. Not approved for distribution. Copyright © 2025 National Comprehensive Cancer Network, Inc., All Rights Reserved.

unclear primary sites.[1,29,30] Other chromosomal abnormalities frequently observed in CUP are activation of angiogenesis genes (50%–89% of CUP tumors), oncogene overexpression (10%–30%), epithelial-to-mesenchymal transition marker elevation (16%), and activation of hypoxia-related proteins (25%) and intracellular signaling molecules (20%–35%).[2] A study that performed targeted gene panel sequencing in a series of 252 patients with CUP found that the most common genetic alterations were deletions in the tumor suppressor genes *p53* (49.6%), *CDKN2A* (19.0%), and *NOTCH1* (14.1%) as well as activation of the oncogenes *KRAS* (23.4%), *FGFR4* (14.9%), and *PIK3CA* (10.7%).[31] Both *KRAS* activation and *CDKN2A* deletion were associated with poor prognosis. Additionally, chromosomal instability has been suggested as a possible cause or prognostic factor for more aggressive presentations of CUP.[2,32]

In an attempt to identify the tissue of origin, biopsy specimens are often analyzed by immunohistochemistry (IHC).[33-36] Gene expression profiling (GEP) assays have also been developed to attempt to identify the tissue of origin in patients with occult primary cancers.[37-39] Both methodologies offer a similar range of accuracy in tumor classification (approximately 75%).[40] While there may be a diagnostic benefit to GEP, a clinical benefit has not been demonstrated. Consequently, the Panel does not currently recommend use of gene sequencing to predict tissue of origin. Until more robust outcomes and comparative effectiveness data are available, pathologists and oncologists must collaborate on the judicious use of IHC and GEP on a case-by-case basis, with the best possible individualized patient outcome in mind.[41]

Immunohistochemistry

IHC studies are useful for the characterization of CUP tumors by providing information about tumor lineage, cell type, and pathologic diagnosis.[33-36,42] The use of IHC in CUP is based on the premise that concordance exists in the expression profiles of primary and metastatic cancers.[37,39] The predictive value of IHC panels improves with the recognition of patterns that are strongly indicative of specific tumors. However, limitations of IHC testing include factors affecting tissue antigenicity, interobserver and intraobserver variability in interpretation, tissue heterogeneity, and inadequate biopsy samples. Nevertheless, with well-performed and interpreted IHC panels, pathologists can identify the putative site of origin of CUP in about 75% of samples (however, validation to determine accuracy is a challenge given the unknown primary cancer designation).[40] Exhaustive IHC studies (in excess of 10–12 stains) have not been shown to increase the diagnostic accuracy in identifying the putative primary sites.[43] Therefore, testing a large series of IHC markers in individual patients should be avoided.

To determine tissue of origin using IHC, a tiered approach is recommended to conserve the diagnostic material. A first tier of IHC assays can be used to help determine tissue lineage using lineage-restricted markers (eg, carcinoma, sarcoma, lymphoma, melanoma). A second tier of IHC, using organ-specific markers, can be used to help suggest the putative primary site.[40] In select patients, it may be helpful to use a third tier of testing for tumor biomarkers that might inform treatment decisions, such as *RAS*, HER2, or *ALK* rearrangements. Per physician discretion, TRK protein testing can be considered as part of broad IHC testing (a positive test should be confirmed with next-generation sequencing [NGS]).[44,45] IHC studies should be used in conjunction with imaging studies to select the best possible treatment options for patients with CUP.

In Situ Hybridization

The use of in situ hybridization (ISH) studies in CUP tumors is critical for evaluating chromosomal aberrations including translocations, insertions or inversions, deletions, and amplifications.[46]The utility of ISH in CUP is multifaceted and can provide information that may aid in the identification of the primary tumor or in guiding treatment. Detected genetic changes

Version 2.2025 © 2024 National Comprehensive Cancer Network© (NCCN©), All rights reserved. NCCN Guidelines® and this illustration may not be reproduced in any form without the express written permission of NCCN.

Printed by Elizabeth Moore on 4/30/2025 10:21:39 AM. For personal use only. Not approved for distribution. Copyright © 2025 National Comprehensive Cancer Network, Inc., All Rights Reserved.

(ie, HER2 positivity) can help predict sensitivity to certain targeted agents.[47] Select chromosomal errors may help delineate solid tumors, potentially leading to identification of the primary site. In a study of 85 patients with metastatic head and neck SCC, human papillomavirus (HPV) (p16) analysis via ISH was conducted as part of the clinical workup.[48] Of the 60 p16-positive samples, 98% correlated with the presence of HPV via ISH. In cancers of the head and neck, p16 positivity is prognostic of oropharyngeal origin ($P < .001$). Limitations to ISH include factors relating to the complexity of ISH testing, that of which is more cumbersome than IHC testing.[49] Historically, ISH also has decreased sensitivity to low-expression genes or short transcripts. The emergence of new and informative IHC markers, and recent advances in testing methodologies and test sensitivity in ISH, will likely continue to aid in the diagnosis of CUP.[49,50] See *Immunohistochemistry/In Situ Hybridization Markers for Unknown Primary Cancers* in the algorithm for suggested IHC markers.

Molecular Profiling

Recent advances in molecular profiling techniques can potentially offer new therapy options to patients with CUP; however, the clinical benefit of using molecular profiling to guide treatment decisions in CUP remains to be determined. There are two main applications for molecular profiling in the management of CUP. The first application utilizes GEP and molecular cancer classifier assays to determine the tissue of origin to guide site-specific therapy. The second application utilizes NGS to identify genomic aberrations that can be targeted therapeutically.

GEP and Molecular Cancer Classifier Assays for Tissue of Origin

Over the past decade, several studies have examined various molecular assays designed to identify the tissue of origin in CUP.[39,51] These assays are designed based on the assumption that metastatic tumors will have a similar molecular profile to that of the primary tumor. Assays used in GEP utilize messenger RNA (mRNA)-, DNA-, or microRNA (miRNA)-based platforms, which analyze anywhere between 10 and 2000 genes simultaneously and can distinguish between 6 and 50 different cancer types.[52-61] When compared to samples from known tumor types, these assays have generally demonstrated an accuracy rate of 83% to 94% in determining the tissue of origin.[62] However, because it is difficult to confirm the site of origin in most cases of CUP, the accuracy of GEP assays in occult primary tumor samples is challenging to determine. Surrogate measures used to determine accuracy include correlation with IHC findings, clinical presentation/response to therapy, as well as the appearance of latent disease at the primary tumor site.[39,51] Several studies suggest that the accuracy of GEP profiling is comparable or superior to the accuracy of IHC for poorly differentiated/undifferentiated carcinomas.[43,62,63]

Several commercially available GEP tests have been evaluated in prospective clinical studies in an attempt to determine if the information they provide regarding tissue of origin translates into clinically meaningful benefits for patients.[64] Comparisons between commercially available GEP tests have also been published.[39,41,51] Currently, there is no evidence of improved outcomes with the use of site-specific therapy guided by molecular testing results in patients with CUP. Results from a prospective phase II study of 194 patients with CUP in which treatments were based on the identification of primary sites by a 92-gene assay showed that clinical features and response to treatment were generally consistent with assay results.[64] However, while the median survival time of 12.5 months in the subset of patients who received GEP-directed treatment was better than the predefined historical cohort, the difference was small and similar results could be expected from empiric use of these regimens in a good PS group of patients with CUP predominantly below the diaphragm. In a randomized phase II trial conducted in Japan, GEP-based site-specific

Version 2.2025 © 2024 National Comprehensive Cancer Network© (NCCN©), All rights reserved. NCCN Guidelines® and this illustration may not be reproduced in any form without the express written permission of NCCN.

Printed by Elizabeth Moore on 4/30/2025 10:21:39 AM. For personal use only. Not approved for distribution. Copyright © 2025 National Comprehensive Cancer Network, Inc., All Rights Reserved.

treatment did not significantly improve 1-year survival rates compared with empirical carboplatin plus paclitaxel in patients with CUP.[65] The randomized phase III GEFCAPI04 trial directly compared the clinical effectiveness of systemic treatment based on GEP results to empiric chemotherapy with cisplatin and gemcitabine in 243 European patients with CUP.[66] Median progression-free survival (PFS) and OS were similar between the two groups. Although GEP-based site-specific treatment did not improve outcomes, it is important to note that many patients in this trial had cancers that are difficult to treat and for which no targeted therapies are available (ie, pancreatico-biliary cancer). Molecular testing in a small number of patients with suspected primary cancers unlikely to respond to empiric chemotherapy allowed the use of a targeted agent or better tailored therapy. However, there were not enough of these patients to impact the overall trial results. Thus, the clinical benefit that might be derived from the use of GEP assays, if any, remains to be determined.

Mutational Testing with Next-Generation Sequencing

Since the identification of clinically relevant genomic alterations has the potential to influence therapy options, use of standardized comprehensive NGS assays may help identify novel treatment paradigms to address the limited treatment options and poor prognoses of patients with CUP.[67-70] The ability of NGS to identify potentially actionable mutations in patients with CUP varies widely in the literature. Depending on the study, mutations with potential therapeutic relevance have been identified in 30% to 85% of patients with CUP.[21,67,71-75] The wide reported variation in the detection of actionable mutations by NGS in patients with CUP may be attributed to the different NGS assays, gene panels, analysis tools, and definitions for what is considered an actionable mutation used across the different studies. In a study by Ross et al, use of a hybrid-capture–based NGS assay enabled the identification of at least one potentially actionable genomic alteration in 85% of the 200 CUP specimens analyzed.[67] However, only 13% of patients had alterations associated with U.S. Food and Drug Administration (FDA)-approved targeted therapies.[21] In an updated analysis by the same group, 32% of the 303 patients with CUP analyzed had actionable genomic alterations associated with FDA-approved targeted therapies, including alterations in programmed death ligand 1 (PD-L1) expression, microsatellite instability (MSI) status, and tumor mutational burden (TMB).[75] Similarly, a study by Varghese et al, which defined an actionable mutation as a specific molecular alteration that is linked to a drug response by an FDA approval or other high-level clinical evidence, found actionable genomic alterations in 30% of patients with CUP.[74] Another study analyzed the mutation and copy number profile of 1709 CUP samples in the GENIE cohort to identify potential targeted treatment options.[76] Fifty two significantly mutated genes were detected, in which 13 (25%) had approved (or undergoing clinical trials) targeted therapy options available. In a large study by Kato et al, comprehensive genomic profiling identified genomic alterations potentially targetable by FDA-approved agents in 63.8% of the 442 patients with CUP who were tested.[73] Using multi-platform profiling, including IHC, gene sequencing, and ISH, Gatalica et al identified actionable mutations in 96% of 1806 CUP cases.[72] However, most of these were identified using established IHC techniques. Importantly, 4 years after the publication of this study, the authors used a 592-gene panel to profile 389 CUP cases and found that only 28% were associated with therapeutically targetable mutations.[77]

To date, there is a lack of high-level evidence to suggest that use of targeted therapies based on NGS results improves outcomes in patients with CUP. The phase II, randomized, international CUPISCO trial assessed the clinical benefit of NGS-directed targeted therapy in 528 participants by directly comparing the efficacy of empiric platinum-based chemotherapy with molecularly targeted therapies relevant to the aberrations found by genomic profiling in patients with histologically confirmed CUP. The primary endpoint was PFS; secondary endpoints included OS, overall response rate (ORR), duration of response, and

Version 2.2025 © 2024 National Comprehensive Cancer Network© (NCCN©), All rights reserved. NCCN Guidelines® and this illustration may not be reproduced in any form without the express written permission of NCCN.

Printed by Elizabeth Moore on 4/30/2025 10:21:39 AM. For personal use only. Not approved for distribution. Copyright © 2025 National Comprehensive Cancer Network, Inc., All Rights Reserved.

percentage of patients with adverse events. This trial has recently closed and results are pending (Clinical Trial ID: NCT03498521).

Initial Evaluation

Patients with a suspected metastatic malignancy should undergo a complete history and physical examination (including breast, genitourinary, pelvic, rectal, skin, and/or oral cavity examinations as appropriate) with a detailed review of past biopsies or malignancies, removed lesions, spontaneously regressing lesions, and existing imaging studies. Routine laboratory tests (ie, complete blood count [CBC], electrolytes, liver function tests, creatinine, calcium) and contrast-enhanced chest/abdomen/pelvis CT scans with IV contrast are also recommended. Clinically directed endoscopy, urinalysis [UA], hemoccult test, and measurement of lactate dehydrogenase (LDH) can be included in the initial evaluation, if indicated.

Diagnostic Imaging

Imaging can play an integral role in the multidisciplinary diagnostic evaluation of patients with CUP.[78] CT is the most frequently used imaging modality in the management of occult primary cancers. PET scan has been shown to be useful for the diagnosis, staging, and restaging of many malignancies,[79,80] and might be warranted in some situations for CUP. PET scan has shown intermediate specificity and high sensitivity in a few small studies, but larger randomized studies are required to determine the clinical utility of PET in patients with CUP.[4,78,81] In a comprehensive review of 10 published studies, Seve et al concluded that PET is a valuable imaging modality for patients with CUP with a single site of metastasis if therapy with a curative intent is planned.[82] Cumulative data from a meta-analysis examining PET as a diagnostic tool in 246 patients with cervical nodal metastases of unknown primary tumors demonstrated a tumor detection rate of 44% and a sensitivity and specificity rate of 97% and 68%, respectively.[83]

One of the limitations of PET has been the limited accuracy of anatomic localization of functional abnormalities because of very little accumulation of 18F-fluorodeoxyglucose (FDG) tracer in some neoplastic tissues. In these cases, the combination of PET with either CT or MRI can provide more useful information.[84,85] Several studies have reported that the combination of PET/CT identified the primary site in 25% to 75% of patients with CUP.[86-94] A multicentric diagnostic accuracy test study assessed the role of FDG-PET/CT in the detection of primary tumors in 175 patients with CUP.[95] Lesions indicative of malignant primary tumors were detected in 60% of patients and pathologically proven in 57.1%. Results also showed a sensitivity of 100% and specificity of 93.3%. In a prospective study of 56 patients with CUP, the sensitivity and accuracy of PET/CT for the detection of primary tumors were significantly higher than the sensitivity and accuracy of CT/MRI (69% and 77% vs. 41% and 48%, respectively; $P < .04$).[96] PET/CT has also been shown to improve the accuracy of staging CUP by detecting more metastases than CT alone.[97] Although one study suggested that PET/CT detected more primary sites (24%–40%) than conventional CT (20%–27%),[98] the exact role of PET/CT remains undefined because of the lack of large prospective clinical trials comparing PET/CT with conventional imaging modalities. Therefore, the Panel recommends using FDG-PET/CT as an alternative to CT/MRI for the initial evaluation only in patients with a contraindication to contrast enhancement. However, FDG-PET/CT may be warranted in some other situations, especially when considering local or regional therapy.

Combined modality screening with PET/MRI has been evaluated in several studies for its diagnostic significance in CUP. In a preliminary comparison trial to evaluate the diagnostic potential of whole-body PET/MRI versus PET/CT, Ruhlmann et al found that both hybrid imaging techniques provide a comparable diagnostic ability for detection of the primary cancer site in patients with CUP.[99] Furthermore, due to the significantly lower dose of ionizing radiation (IR), PET/MRI may serve as

Version 2.2025 © 2024 National Comprehensive Cancer Network© (NCCN©), All rights reserved. NCCN Guidelines® and this illustration may not be reproduced in any form without the express written permission of NCCN.

Printed by Elizabeth Moore on 4/30/2025 10:21:39 AM. For personal use only. Not approved for distribution. Copyright © 2025 National Comprehensive Cancer Network, Inc., All Rights Reserved.

an alternative to PET/CT, particularly for therapy monitoring and long-term surveillance.[99] In a prospective study by Sekine et al, 43 patients with suspected CUP were assessed with PET/CT and PET/MRI for the presence of a primary tumor, lymph node metastases, and distant metastases.[100] PET/MRI was found to be superior to PET/CT for primary tumor detection (sensitivity/specificity, 85%/97% vs. 69%/73%; P = .02) and comparable to PET/CT for the detection of lymph node metastases (93%/100% vs. 93%/93%; P = .157) and distant metastases (100%/97% vs. 82%/100%; P = .564). PET/CT also tended to misclassify physiologic uptake of FDG as malignancy compared with PET/MRI.[100]

Advances in MRI technology have enabled the emergence of more sensitive and accurate techniques. Multiparametric MRI (MPMRI), which consists of three separate imaging parameters (T2-weighted imaging, diffusion-weighted imaging, and dynamic contrast-enhanced imaging), allows for detailed visualization of tissues as well as their chemical makeup, enabling experienced radiologists to better separate cancerous tissue from benign tissue. In a retrospective study of 38 patients with CUP and cervical lymph node metastases, the accuracy of PET/CT and MPMRI in locating the primary tumor in the neck region was identical, with MPMRI having the added advantage of sparing patients the exposure to IR.[101] T1-weighted high-resolution isotropic volume examination (THRIVE) is a 3D ultrafast spoiled gradient MRI sequence that provides more detailed anatomic information and improved spatial resolution with reduced artifacts when compared to traditional 2D spin-echo MRI. In a retrospective study of 73 patients with CUP and cervical lymph node metastases, 3D-THRIVE MRI enabled the identification of the primary tumor in 72.9% of patients compared to 49.2% and 36.4%, respectively, for spin-echo MRI and contrast-enhanced CT.[102] The diagnostic accuracy of 3D-THRIVE MRI (71.2%) was found to be higher than the accuracies of spin-echo MRI (53.4%) and CT (46.4%; P = .001). Therefore, because of their lower IR dose levels and either identical or improved efficacy and accuracy, PET/MRI, MPMRI, and 3D-THRIVE MRI may be favorable over PET/CT scans in the workup of suspected occult malignancies. However, more robust data from randomized prospective trials that include treatment outcome and patient survival data are required to support this assertion.

Workup

Patients with a suspected occult primary tumor should undergo an initial core needle biopsy (preferred) and/or fine-needle aspiration (FNA) with cell block of the most accessible site. Accurate pathologic assessment of the biopsied material is of utmost importance. Therefore, a pathologist must be consulted to determine the adequacy of the specimen and to perform additional studies including IHC stains or ISH testing. If available, the pathologist should provide rapid on-site evaluation (ROSE) and confirm adequate sampling of the lesion.[103,104] If additional biopsy material is necessary, a core needle, incisional, or excisional biopsy may be performed. Examination of the biopsy material by light microscopy is usually performed first. Other techniques include electron microscopy and flow cytometry. Although IHC stains can be informative (see *Immunohistochemistry* above), large panels of IHC markers should be avoided.

MSI/mismatch repair (MMR) testing is indicated for patients with CUP; however, it should be noted that the population of patients with MSI-high/MMR-deficient (MSI-H/dMMR) occult primary tumors is generally low. In a comprehensive analysis of 389 CUP tumors, only 1.8% of tumors were MSI-H.[77] Determination of TMB by a validated and/or FDA-approved assay is a category 2B recommendation.[105] Molecular profiling of tumor tissue using NGS or other technique to identify gene fusions can be considered after an initial determination of histology has been made. Tumor/somatic molecular profiling should be considered for patients who are candidates for anti-cancer therapy to identify uncommon mutations (ie, *RET* fusions). Testing on tumor tissue is preferred; however, cell-free

Version 2.2025 © 2024 National Comprehensive Cancer Network© (NCCN©), All rights reserved. NCCN Guidelines® and this illustration may not be reproduced in any form without the express written permission of NCCN.

Printed by Elizabeth Moore on 4/30/2025 10:21:39 AM. For personal use only. Not approved for distribution. Copyright © 2025 National Comprehensive Cancer Network, Inc., All Rights Reserved.

DNA testing can be considered if tumor tissue testing is not feasible. The Panel does not recommend tissue-of-origin studies.

At this point, a specific pathologic diagnosis may be made (ie, epithelial occult primary [not site-specific], lymphoma or other hematologic malignancy, thyroid carcinoma, melanoma, sarcoma, germ cell tumor). Other diagnostic studies should be based on clinical presentation and subsequent histopathologic findings. This initial evaluation will identify a primary site in approximately 30% of patients presenting with CUP. These patients should be treated according to the appropriate NCCN Guidelines for Treatment by Cancer Type (see list of NCCN Guidelines for Treatment by Cancer Type). For the remaining patients, a great deal of controversy exists regarding whether an exhaustive, time-consuming, and costly evaluation should be conducted to search for the primary tumor beyond these initial tests, as opposed to a more directed evaluation based on the complete history and physical examination, clinical presentation, histopathologic diagnosis, and metastatic sites of involvement. Suggested diagnostic tests for each pathologic subtype, location, and anatomic site (where applicable) are indicated in the algorithm and are discussed below. Additional studies can be important in determining whether the occult primary cancer is potentially curable, or in diagnosing a possibly treatable disease associated with long-term survival.

Workup for Possible Breast Primary

Adenocarcinoma with positive axillary and/or mediastinal nodes in individuals with intact breast tissue (including gynecomastia) is highly suggestive of a breast primary site. Adenocarcinoma in the supraclavicular nodes, chest, peritoneum, retroperitoneum, liver, bone, or brain could also indicate primary breast cancer. Therefore, mammogram is indicated for these patients. For patients with a non-diagnostic mammogram and histopathologic evidence of breast cancer, contrast-enhanced MRI and/or ultrasound of the breast should be considered. Contrast-enhanced breast MRI (if not contraindicated) should also be considered when mammography is not adequate to assess the extent of the disease, especially in individuals with dense breast tissue and/or positive axillary nodes, or to evaluate the chest wall.[106] Breast MRI has been shown to be useful in identifying the primary site in patients with occult primary breast cancer and may also facilitate breast conservation in select patients by allowing for lumpectomy instead of mastectomy.[107,108] In one report, MRI identified the breast as the primary site in approximately half of the patients presenting with axillary metastases, irrespective of breast density.[109]

For patients with involvement of the mediastinum whose workup does not indicate primary breast cancer, additional consultation with a pathologist to determine whether further analysis would help differentiate between breast and non-small cell lung cancer (or other putative primary sites) should be considered.

Workup for Possible Testicular Germ Cell Primary

Adenocarcinoma with positive mediastinal nodes in patients with testes who are <50 years suggests a possible primary testicular germ cell tumor, as does a retroperitoneal mass in such patients <65 years of age. Measurement of the serum tumor markers β-human chorionic gonadotropin (β-hCG) and α-fetoprotein (AFP) is recommended; testicular ultrasound is indicated for patients found to have elevated levels of serum β-hCG or AFP. For patients who have involvement of the mediastinum and whose workup does not indicate a primary germ cell tumor, additional consultation with a pathologist to determine whether further analysis would help differentiate between testicular and non-small cell lung cancer should be considered.

Version 2.2025 © 2024 National Comprehensive Cancer Network© (NCCN©), All rights reserved. NCCN Guidelines® and this illustration may not be reproduced in any form without the express written permission of NCCN.

Printed by Elizabeth Moore on 4/30/2025 10:21:39 AM. For personal use only. Not approved for distribution. Copyright © 2025 National Comprehensive Cancer Network, Inc., All Rights Reserved.

Workup for Possible Ovarian Primary

Adenocarcinoma with positive mediastinal nodes in patients with ovaries present who are <50 years is suggestive of an ovarian primary tumor. Adenocarcinoma in the inguinal nodes, chest (multiple nodules), or peritoneum (with or without ascites) also suggests possible primary ovarian cancer, as does the presence of pleural effusion or a retroperitoneal mass. Testing for the ovarian cancer marker CA-125 is recommended in these cases, as is consultation with a gynecologic oncologist. For patients who have involvement of the mediastinum but whose workup does not indicate a primary ovarian tumor, consider treating for germ cell tumors (including poor-risk germ cell tumors) or non-small cell lung cancer based on the age of the individual.

Workup for Possible Prostate Primary

All patients with a prostate (or post-prostatectomy) who are >40 years with an adenocarcinoma of unknown primary, except for those with metastases limited to the liver or brain, should undergo testing for PSA levels. In addition, patients presenting with bone metastases or multiple sites of involvement should have PSA levels assessed regardless of age.

Additional Workup for Localized Adenocarcinoma or Carcinoma Not Otherwise Specified

In patients with adenocarcinoma involving painful bone lesions, a contrast-enhanced chest/abdomen/pelvis CT with bone scan is indicated. For patients presenting with a retroperitoneal mass, peritoneal mass, or ascites, urine cytology is recommended followed by cystoscopy if findings are suspicious. In patients with inguinal lymph node involvement, the guidelines include proctoscopy, if clinically indicated, to assess for rectal or anal cancer.[110] Endoscopic evaluation is recommended for patients presenting with malignancy in the liver and is suggested for patients with positive supraclavicular nodes, if clinically indicated. However, endoscopy is not routinely recommended for patients presenting with malignant ascites (ie, peritoneal presentation). Since the differentiation between metastatic adenocarcinoma of the liver and primary hepatocellular carcinoma (HCC) is sometimes challenging, the use of AFP as a marker for HCC is recommended as part of the additional workup for CUP in the liver.[111] In the absence of a positive fecal occult blood test or other clinical factors suggesting a putative colon primary or concern for bowel involvement/obstruction from metastatic cancer or carcinomatosis, the diagnostic yield of colonoscopy is low and is therefore not recommended as standard practice in the workup process of CUP.[112]

Workup for Squamous Cell Carcinoma

SCC can be present in the lymph nodes of the head and neck region, as well as in the supraclavicular, axillary, and inguinal nodes. Contrast-enhanced CT scans of the abdomen and pelvis, careful perineal and lower extremity examination including reproductive organs and genitalia, gynecologic oncology consult, and anal endoscopy are recommended for patients with SCC involving inguinal lymph nodes. PET/CT can be considered as an alternative for patients with a contraindication to contrast enhancement. Cystoscopy can also be considered, if clinically indicated. Chest CT is recommended for patients with SCC involving the axillary nodes. The workup recommendations for Occult Primary in the NCCN Guidelines for Head and Neck Cancers should be followed for patients with unknown primary lesions in the head and neck region or supraclavicular nodes. Importantly, clinicians should check results of p16 IHC, HPV ISH, and Epstein-Barr virus (EBV) ISH since positive results may help localize the primary site.

A bone scan (if only chest/abdomen/pelvis CT scan was previously done) and diagnostic imaging studies are recommended for SCC involving painful bone lesions. Directives for diagnostic imaging in this context have

Version 2.2025 © 2024 National Comprehensive Cancer Network© (NCCN©), All rights reserved. NCCN Guidelines® and this illustration may not be reproduced in any form without the express written permission of NCCN.

Printed by Elizabeth Moore on 4/30/2025 10:21:39 AM. For personal use only. Not approved for distribution. Copyright © 2025 National Comprehensive Cancer Network, Inc., All Rights Reserved.

been previously described under *Additional Workup for Localized Adenocarcinoma or Carcinoma Not Otherwise Specified* above.

Workup for Neuroendocrine Tumors

Neuroendocrine tumors can metastasize to several sites, including the head and neck, supraclavicular lymph nodes, lung, inguinal lymph nodes, liver, bone, brain, and skin. The workup recommendations for *Neuroendocrine Tumors of Unknown Primary* in the NCCN Guidelines for Neuroendocrine and Adrenal Tumors should be followed for patients with suspected primary neuroendocrine tumors.

Management

Psychosocial Distress

For many patients, the apparent uncertainties surrounding the diagnosis of an unknown primary cancer may result in significant psychosocial distress and increased difficulty in accepting treatment options. A study by Hyphantis et al found that psychiatric manifestations, including anxiety and depression, were more common in patients with CUP than in those with known primary cancers.[113] Empathetic discussion about the natural history of these types of cancers, their prognoses, and the provision of support and counseling by both the primary oncology team and specialized services may help alleviate this distress. Please see the NCCN Guidelines for Distress Management for further information.

Supportive Care

In addition to psychosocial support, patients with active and incurable CUP often require symptom management and palliative care interventions. Given the natural history of this disease, end-of-life discussions should be initiated early in the clinical course. Hospice care should also be considered and utilized as appropriate. Please see the NCCN Guidelines for Palliative Care and the NCCN Guidelines for Survivorship for more information.

Treatment Based on Workup Findings

Adenocarcinoma

Localized adenocarcinoma or carcinoma not otherwise specified is treated according to the most likely primary site. Patients with localized adenocarcinoma or carcinoma not otherwise specified involving supraclavicular nodes or the head and neck regions should be treated according to the Occult Primary pathway described in the NCCN Guidelines for Head and Neck Cancers. Patients with localized adenocarcinoma involving axillary nodes as well as those who are breast-marker positive and have pleural effusion should be treated according to the NCCN Guidelines for Breast Cancer. Patients with localized adenocarcinoma with a peritoneal mass or ascites consistent with ovarian histology should be treated according to the NCCN Guidelines for Ovarian Cancer. Patients with a retroperitoneal mass consistent with germ cell histology should be treated according to the NCCN Guidelines for Testicular Cancer or NCCN Guidelines for Ovarian Cancer, respectively.

Localized adenocarcinoma occurring in the mediastinum most likely derives from either a germ cell tumor or a non-small cell lung tumor. Patients <40 years and those between 40 and 50 years should be treated for poor-risk germ cell tumors according to the NCCN Guidelines for Testicular Cancer or the NCCN Guidelines for Ovarian Cancer. Alternatively, patients aged 40 to 50 years could also be treated according to the NCCN Guidelines for Non-Small Cell Lung Cancer. Patients aged ≥50 years should be treated according to the NCCN Guidelines for Non-Small Cell Lung Cancer.

Other locations of adenocarcinomas of unknown primary are not associated with a common primary site. Treatment recommendations in

Version 2.2025 © 2024 National Comprehensive Cancer Network© (NCCN©), All rights reserved. NCCN Guidelines® and this illustration may not be reproduced in any form without the express written permission of NCCN.

Printed by Elizabeth Moore on 4/30/2025 10:21:39 AM. For personal use only. Not approved for distribution. Copyright © 2025 National Comprehensive Cancer Network, Inc., All Rights Reserved.

these cases are thus general and may involve local and/or systemic therapies. For example, axillary node dissection is recommended for patients with a prostate (or post-prostatectomy) with localized adenocarcinoma involving the axillary nodes. Additionally, radiation therapy (RT) or systemic therapy can also be considered if clinically indicated. Patients with completely resectable lung nodules should be considered for surgery. Systemic therapy, preferably as part of a clinical trial, or stereotactic body RT (SBRT) can be considered for oligometastatic lung nodules with or without resection. Lymph node dissection is recommended for inguinal nodal involvement; RT with or without systemic therapy can also be considered if clinically indicated. It should be noted that the use of RT alone in cases of bilateral inguinal node involvement is a category 2B recommendation.[114]

Surgical resection with or without systemic therapy is recommended for patients with localized adenocarcinoma in the liver. If surgery is medically contraindicated or declined by the patient, or if the tumor is unresectable, recommended systemic therapy and/or locoregional treatment options as described in the NCCN Guidelines for Hepatocellular Carcinoma should be followed.

For patients with good PS and bone lesions with potential for fracture in weight-bearing areas, surgery and RT are recommended. In the case of patients with poor PS, RT without surgery is recommended. Patients with brain metastases should be treated according to the recommendations for treating metastatic lesions in the NCCN Guidelines for Central Nervous System Cancers. Systemic therapy (preferably within a clinical trial) can be considered for patients presenting with breast marker-negative pleural effusion or ascites/peritoneal mass of non-ovarian origin. In the case of a retroperitoneal mass of non-germ cell histology, surgery and/or RT is recommended, with systemic therapy considered only for select patients.

Efforts should be made to control symptoms in patients with disseminated adenocarcinoma of unknown primary. The preferred treatment approach for these patients is enrollment in a clinical trial. Additional recommendations include consideration of systemic therapy on an individual basis and specialized approaches (see *Specialized Approaches* below).

SCC

In patients with site-specific SCC and localized axillary or inguinal lymph node involvement, lymph node dissection is recommended. RT with or without systemic therapy can be considered if clinically indicated (the use of RT alone in the case of bilateral inguinal node involvement is a category 2B recommendation).[114] Systemic therapy is not recommended if the tumor has a high likelihood of cutaneous origin.

Patients with involvement of SCC in the supraclavicular lymph nodes or in the head and neck regions should be treated according to the recommendations for occult primary tumors described in the NCCN Guidelines for Head and Neck Cancers. Patients with site-specific SCC in the mediastinum should be treated according to the NCCN Guidelines for Non-Small Cell Lung Cancer. Participation in a clinical trial is the preferred treatment option for patients with multiple lung nodules or pleural effusion. Systemic therapy can also be considered.

Surgery and RT are recommended for patients with good PS and bone lesions with potential for fracture in weight-bearing areas. For patients with poor PS, RT alone is recommended. Patients with brain metastases should be treated according to the recommendations for metastatic lesions in the NCCN Guidelines for Central Nervous System Cancers.

Efforts should be made to control symptoms in patients with disseminated SCC of unknown primary. Enrollment in a clinical trial is the preferred treatment option for these patients. Systemic therapy can be considered on an individual basis.

Version 2.2025 © 2024 National Comprehensive Cancer Network© (NCCN©), All rights reserved. NCCN Guidelines® and this illustration may not be reproduced in any form without the express written permission of NCCN.

Printed by Elizabeth Moore on 4/30/2025 10:21:39 AM. For personal use only. Not approved for distribution. Copyright © 2025 National Comprehensive Cancer Network, Inc., All Rights Reserved.

Neuroendocrine Tumors

Treatment of suspected neuroendocrine tumors should follow the Neuroendocrine Unknown Primary pathway of the NCCN Guidelines for Neuroendocrine and Adrenal Tumors.

Systemic Therapy

Many systemic therapy regimens have been evaluated in patients with CUP in an attempt to prolong survival and provide symptom relief. Various regimens have shown efficacy in the treatment of patients with CUP in phase II studies. However, a 2012 systematic review of chemotherapy trials in patients with CUP of unfavorable presentations concluded that no specific regimen can be recommended as standard of care.[115] Historically, response rates of around 20% and median OS of 6 months have been observed in patients with CUP treated with taxane- or platinum-based regimens.[116,117] A systematic review and meta-analysis published in 2013 largely reached the same conclusion, with taxanes showing a possible slight advantage over platinum-based regimens.[118] In general, systemic therapy shows limited efficacy and considerable toxicity in patients with CUP. Therefore, these guidelines recommend that systemic therapy for patients with disseminated disease be limited to patients who are symptomatic with a PS of 1–2 or to patients who are asymptomatic with aggressive cancer and a PS of 0. The choice of regimen should be based on the histologic type of cancer. Regimens in addition to those listed in the guidelines can be considered.

Adenocarcinoma

Poorly differentiated or undifferentiated occult primary tumors respond differently from well- to moderately differentiated occult primary tumors. Tumors in the former group seem to be highly responsive to cisplatin-based combination chemotherapy.[119,120] ORRs reported in two studies from the early 1990s were 53% (van der Gaast et al[120]) and 63% (Hainsworth et al[119]) with complete response rates of 12% and 26%, respectively, with cisplatin-based regimens. In one study, patients who had tumors with extragonadal germ cell features showed an especially high response rate.[119] In the other, patients with undifferentiated carcinomas had a better response rate than those with poorly differentiated carcinomas (79% vs. 35%; $P = .02$).[120] Taxane-based chemotherapy has also been associated with long-term survival in some patients with CUP, with 1-, 2-, 3-, and 4-year survival rates of 42%, 22%, 17%, and 17%, respectively, and a median survival of 10 months.[121]

The following regimens are included in the algorithm for treating adenocarcinoma of unknown primary based on the results of phase II and/or phase III studies, as described below. Regimens other than those listed can also be considered. It is important to note that leucovorin is indicated with certain fluorouracil-based regimens. However, depending on availability, these regimens may be used with or without leucovorin. For more information regarding the leucovorin shortage, see below.

Paclitaxel and Carboplatin with or without Etoposide

The combination of paclitaxel and carboplatin is commonly used to treat non-small cell lung and esophageal cancers.[122-128] The combination of paclitaxel and carboplatin (with or without etoposide) was found to be effective for the treatment of adenocarcinoma of unknown primary in several studies.[121,129-133] In the phase II Hellenic Cooperative Oncology Group study, the combination of paclitaxel and carboplatin was well tolerated and produced an ORR of 38.7%.[129] In a randomized prospective phase II study conducted by the German CUP Study Group, paclitaxel and carboplatin showed better clinical activity than gemcitabine and vinorelbine.[133] The median OS, 1-year survival rate, and response rate were 11.0 months, 38%, and 23.8%, respectively, for patients treated with paclitaxel and carboplatin, compared with 7.0 months, 29%, and 20%, respectively, for those treated with gemcitabine and vinorelbine. A phase

Version 2.2025 © 2024 National Comprehensive Cancer Network© (NCCN©), All rights reserved. NCCN Guidelines® and this illustration may not be reproduced in any form without the express written permission of NCCN.

Printed by Elizabeth Moore on 4/30/2025 10:21:39 AM. For personal use only. Not approved for distribution. Copyright © 2025 National Comprehensive Cancer Network, Inc., All Rights Reserved.

III randomized trial found paclitaxel, carboplatin, and etoposide to be an effective regimen in the first-line treatment of patients with CUP.[132] The ORR was 18% among 93 patients; median PFS and OS were 3.3 months and 7.4 months, respectively; and the 2-year survival rate was 15%. In a phase II trial with long-term follow-up, patients treated with paclitaxel, carboplatin, and etoposide had 2- and 3-year survival rates of 20% and 14%, respectively.[130] However, overall toxicity is higher with the addition of etoposide than that typically observed with paclitaxel and carboplatin. Therefore, paclitaxel and carboplatin is a preferred regimen for the treatment of occult primary adenocarcinoma while the combination of paclitaxel, carboplatin, and etoposide should be reserved for patients with a PS of 0 to 1 on the ECOG scale.

Gemcitabine and Cisplatin or Docetaxel

The combination of gemcitabine and cisplatin is commonly used to treat non-small cell lung cancer and bladder cancer.[124,125,134-137] The efficacy of combined gemcitabine and cisplatin for the treatment of CUP was evaluated in the randomized phase II GEFCAPI 01 study.[138] Well-differentiated adenocarcinoma was the most common histology, with one-fourth of patients having a single metastatic site. Objective responses were observed in 55% of patients (n = 21) receiving gemcitabine and cisplatin and the median survival was 8 months. The follow-up GEFCAPI 02 trial randomly assigned 52 patients 1:1 to receive gemcitabine and cisplatin or cisplatin alone.[139] Median OS and 1-year survival rates were 11 months and 46% for the gemcitabine and cisplatin arm compared to 8 months and 35% for cisplatin alone. Median PFS was 5 months in the gemcitabine and cisplatin arm and 3 months in the cisplatin arm; 1-year PFS rates were 29% and 15%, respectively.

Gemcitabine and docetaxel was also found to be active and well-tolerated as first-line therapy in patients with CUP.[140] Of 35 patients, 1 complete response and 13 partial responses were observed with an ORR of 40%. The median time to disease progression was 2 months and the median OS was 10 months. Based on these data, the Panel recommends gemcitabine and cisplatin (preferred) and gemcitabine and docetaxel as treatment options for patients with adenocarcinoma of unknown primary.

Capecitabine with Oxaliplatin (CapeOx) and Fluorouracil/Leucovorin with Oxaliplatin (mFOLFOX6)

The combination of capecitabine and oxaliplatin (CapeOx) has been evaluated in phase II studies for first-line[141] and second-line[142] treatment of patients with CUP. As an active and well-tolerated regimen, CapeOx is a preferred option in patients with presumed GI primary adenocarcinoma. A phase II trial involving 51 patients with adenocarcinoma of unknown primary, first-line treatment with CapeOx resulted in an ORR of 11.7%, median PFS of 2.5 months, OS of 7.5 months, and a favorable toxicity profile.[141] Second-line treatment with CapeOx resulted in an ORR of 19%, median PFS of 3.7 months, and OS of 9.7 months in a phase II trial of 48 patients with CUP, the majority of whom (65%) had adenocarcinoma of unknown primary.[142]

Although fluorouracil/leucovorin and oxaliplatin (FOLFOX) has not been prospectively evaluated in patients with CUP, FOLFOX has been shown to be equivalent to CapeOx in the treatment of colorectal cancer.[143-147] The Panel therefore recommends FOLFOX (mFOLFOX6 regimen[148]) as a preferred treatment option for patients with presumed GI primary adenocarcinoma.

Fluorouracil/Leucovorin and Irinotecan (FOLFIRI)

The combination of fluorouracil, leucovorin, and irinotecan (FOLFIRI) is commonly used in the first- and second-line treatment of gastrointestinal (GI) cancers.[149-154] The landmark phase III French Intergroup trial, which compared first-line treatment with FOLFIRI to epirubicin, cisplatin, and fluorouracil (ECF) in patients with advanced or metastatic gastric

Version 2.2025 © 2024 National Comprehensive Cancer Network© (NCCN©), All rights reserved. NCCN Guidelines® and this illustration may not be reproduced in any form without the express written permission of NCCN.

Printed by Elizabeth Moore on 4/30/2025 10:21:39 AM. For personal use only. Not approved for distribution. Copyright © 2025 National Comprehensive Cancer Network, Inc., All Rights Reserved.

adenocarcinoma, showed that the median time to treatment failure (TTF) was significantly longer with FOLFIRI than with ECF (5.1 vs. 4.2 months; $P = .008$).[150] While median PFS and OS were similar in the two groups, FOLFIRI was associated with a more favorable toxicity profile than ECF (overall rate of grade 3–4 toxicity, 69% vs. 84%; $P < .001$). Second-line therapy with FOLFIRI has also been shown to be active and well-tolerated in patients with metastatic gastric cancer, recurrent or advanced biliary tract cancer, and locally advanced or metastatic pancreatic cancer.[151,153]

Data for the efficacy of FOLFIRI in the treatment of patients with CUP are limited. A retrospective study identified 32 patients with CUP predicted to have a colorectal site of origin by molecular profiling who were treated with colorectal cancer regimens, including FOLFIRI.[155] Results showed significantly improved ORRs in patients treated with site-specific regimens such as FOLFIRI compared to empirical regimens used to treat CUP (50% vs. 17%; $P = .0257$). Since a colorectal primary site is among the most common primary sites in CUP,[156,157] the Panel recommends FOLFIRI as a preferred treatment option for first- or second-line therapy in patients with presumed GI CUP.

Docetaxel and Carboplatin or Cisplatin

Greco et al reported that docetaxel in combination with either cisplatin or carboplatin was active in patients with adenocarcinoma and poorly differentiated CUP.[158] Major response to therapy was observed in 26% of patients receiving docetaxel and cisplatin, with a median survival of 8 months and a 1-year survival rate of 42%. In patients receiving docetaxel and carboplatin, the corresponding response rate was 22%, with a median survival of 8 months and a 1-year survival rate of 29%. Docetaxel in combination with carboplatin was better tolerated than docetaxel with cisplatin in this study.[158]

In a phase II Hellenic Cooperative Oncology Group study, treatment with docetaxel and carboplatin every 3 weeks was found to be as safe and effective as palliative treatment for patients with adenocarcinoma or poorly differentiated CUP with a PS of 0 to 2.[159] Median time to progression was 5.5 months and OS was 16.2 months. Combination therapy with docetaxel and cisplatin was examined in a cohort of 29 patients with CUP.[160] Approximately half of these patients (51.7%) had well- to moderately differentiated adenocarcinoma; patients with undifferentiated carcinoma (27.6%) and SCC histologies (13.8%) were also included. The ORR was 37.9%, and median PFS and OS were 6 and 16 months, respectively. Therefore, docetaxel in combination with either cisplatin or carboplatin are recommended treatment options for patients with adenocarcinoma of unknown primary.

Irinotecan and Carboplatin or Gemcitabine

The combination of irinotecan and carboplatin was evaluated in a phase II study of 45 chemotherapy-naïve patients with CUP. The regimen was associated with an ORR of 41.9%; median PFS was 4.8 months and OS was 12.2 months. The 1- and 2-year survival rates were 44% and 27%, respectively. However, this regimen was also associated with significant toxicities, including grade 3 or higher leukopenia (21%), neutropenia (33%), anemia (25%), and thrombocytopenia (20%).[161] A phase III randomized trial found irinotecan and gemcitabine to be an effective regimen in the first-line treatment of patients with CUP, with a response rate and 2-year survival rate of 18% each. Median PFS and OS were 5.3 months and 8.5 months, respectively.[132] The Panel recommends irinotecan and carboplatin as a treatment option for occult primary adenocarcinoma; irinotecan and gemcitabine should be reserved for patients who are ineligible to receive platinum-based chemotherapy.

Version 2.2025 © 2024 National Comprehensive Cancer Network© (NCCN©), All rights reserved. NCCN Guidelines® and this illustration may not be reproduced in any form without the express written permission of NCCN.

Printed by Elizabeth Moore on 4/30/2025 10:21:39 AM. For personal use only. Not approved for distribution. Copyright © 2025 National Comprehensive Cancer Network, Inc., All Rights Reserved.

Capecitabine or Fluorouracil

Capecitabine and fluorouracil are commonly used as single agents in the treatment of GI cancers.[162-165] A trial conducted by the National Surgical Adjuvant Breast and Bowel Project reported that treatment with fluorouracil significantly improved disease-free survival (DFS) and OS in patients with stage II or III colon cancer.[164] In this trial, 1081 patients were randomized to receive fluorouracil or lomustine, vincristine, and fluorouracil (MOF). Three-year DFS was 73% in the fluorouracil group compared to 64% in patients receiving MOF ($P = .003$). Additionally, patients treated with fluorouracil had a 30% reduction in treatment failure and a 32% reduction in mortality risk compared to patients treated with MOF after 3 years of follow-up. In a phase III randomized trial involving 1987 patients with metastatic colon cancer, adjuvant treatment with single-agent capecitabine improved relapse-free survival (HR, 0.86; 95% CI, 0.74–0.99; $P = .04$) and was associated with significantly fewer adverse events than fluorouracil ($P < .001$).[162] Therefore, single-agent capecitabine and single-agent fluorouracil are recommended options for the treatment of occult primary adenocarcinoma. Single-agent capecitabine or fluorouracil can be given with concurrent RT, if clinically indicated.

Fluorouracil/Leucovorin, Irinotecan, and Oxaliplatin (FOLFIRINOX) and mFOLFIRINOX

The FOLFIRINOX regimen is commonly used in the treatment of pancreatic cancer.[166-170] The landmark phase III PRODIGE trial, which randomized 342 patients with metastatic pancreatic cancer and good PS to receive FOLFIRINOX or gemcitabine, found that treatment with FOLFIRINOX resulted in dramatic improvements in median OS (11.1 vs. 6.8 months; $P < .001$), median PFS (6.4 vs. 3.3 months; $P < .001$), and ORR (31.6% vs. 9.4%; $P < .001$) compared to treatment with gemcitabine.[166] In a systematic review and meta-analysis that included 315 patients with locally advanced pancreatic cancer across 11 studies, treatment with FOLFIRINOX showed a pooled median OS of 24.2 months, which is longer than that typically observed with gemcitabine (6–13 months).[169] However, FOLFIRINOX has been associated with significant toxicities, including grade 3–4 febrile neutropenia, thrombocytopenia, diarrhea, vomiting, fatigue, and sensory neuropathy.[166,169] Additionally, there is a lack of data regarding the efficacy of FOLFIRINOX in the treatment of CUP. Therefore, FOLFIRINOX should be reserved for patients with a PS of 0–1 and a presumed GI primary site.

The mFOLFIRINOX regimen has also shown efficacy in the treatment of pancreatic adenocarcinoma. In a multicenter phase III trial, 493 patients with resected pancreatic ductal adenocarcinoma were randomized to receive mFOLFIRINOX or gemcitabine.[171] At a median follow-up of 34 months, the median DFS was 22 months in the mFOLFIRINOX group and 13 months in the gemcitabine group ($P < .001$). The median OS was 54 months with mFOLFIRINOX compared to 35 months with gemcitabine ($P = .003$). The 3-year OS rate was 63% in the modified-FOLFIRINOX group and 49% in the gemcitabine group. Grade 3 or 4 adverse events occurred in 76% of patients receiving mFOLFIRINOX compared to 53% of those receiving gemcitabine. Due to significant toxicity and a lack of data regarding the efficacy of mFOLFIRINOX in the treatment of CUP, mFOLFIRINOX should be reserved for patients with a PS of 0–1 and a presumed GI primary site.

Pembrolizumab

Pembrolizumab, an anti-programmed cell death protein 1 (PD-1) antibody, was approved by the FDA in 2017 for the treatment of patients with unresectable or metastatic MSI-H/dMMR solid tumors that have progressed following prior treatment and who have no satisfactory alternative treatment options.[172] This first-ever tissue- and site-agnostic approval was based on data from 149 patients with MSI-H/dMMR cancers

Version 2.2025 © 2024 National Comprehensive Cancer Network© (NCCN©), All rights reserved. NCCN Guidelines® and this illustration may not be reproduced in any form without the express written permission of NCCN.

Printed by Elizabeth Moore on 4/30/2025 10:21:39 AM. For personal use only. Not approved for distribution. Copyright © 2025 National Comprehensive Cancer Network, Inc., All Rights Reserved.

(90 patients had colorectal cancer) enrolled across five multicenter single-arm clinical trials. One of the trials included in the FDA approval was KEYNOTE-016, a phase II trial that evaluated the activity of pembrolizumab in 41 patients with metastatic treatment-refractory dMMR colorectal cancer, MMR-proficient colorectal cancer, or dMMR non-colorectal cancer who had received at least two previous lines of therapy.[173,174] The immune-related ORR for patients with dMMR colorectal cancers was 40% with an immune-related PFS rate of 78%.[173] Responses of patients with dMMR noncolorectal cancers were similar. Importantly, the immune-related ORR and PFS rate were 0% and 11%, respectively, in patients with MMR-proficient colorectal cancer. In an expansion of this study, data from 86 patients with dMMR tumors representing 12 different cancer types achieved an ORR of 53% with 21% of patients achieving a complete response to pembrolizumab.[174] In the phase II KEYNOTE-158 trial, 233 patients with 27 different MSI-H/dMMR tumor types (endometrial, gastric, cholangiosarcoma, and pancreatic cancers being the most common) were treated with pembrolizumab following the failure of at least one previous line of therapy.[175] After a median follow-up of 13 months, the ORR was 34.3%. Median PFS was 4 months and median OS was 24 months. Treatment-related adverse events occurred in 64.8% of patients (14.6% were grade 3–5).

In 2020, the FDA approved pembrolizumab for the treatment of patients with metastatic TMB-high (TMB-H) [≥10 mutations/megabase (mut/Mb)] solid tumors, as determined by an FDA-approved test, that have progressed following prior treatment and who have no satisfactory alternative treatment options.[176] This approval was based on a retrospective analysis of 102 patients enrolled in the KEYNOTE-158 trial who had tumors identified as TMB-H.[177] The ORR for these patients was 29%, with a 4% complete response rate and 25% partial response rate. The median duration of response was not reached, with 50% of patients having response durations for ≥24 months. Based on these data, pembrolizumab may be used to treat patients with MSI-H/dMMR or TMB-H (≥10 mut/Mb) occult primary tumors.

Dostarlimab-gxly

Dostarlimab-gxly, an anti-PD-1 antibody, was approved by the FDA in 2021 for the treatment of patients with dMMR recurrent or advanced solid tumors that have progressed on or following prior treatment and who have no satisfactory alternative treatment options.[178] This approval was based on data from the nonrandomized phase 1 multi-cohort GARNET trial that evaluated the safety and antitumor activity of dostarlimab-gxly in 209 patients with dMMR solid tumors.[179,180] The majority of patients had endometrial or GI cancers. The ORR was 42%, with a 9% complete response rate and 33% partial response rate, and the median duration of response was 35 months. The most common treatment-related adverse events were fatigue, anemia, diarrhea, and nausea. Immune-mediated adverse events also occurred, including pneumonitis, colitis, hepatitis, endocrinopathies, nephritis, and dermatologic toxicities. Based on these data, dostarlimab-gxly may be used to treat patients with MSI-H/dMMR occult primary adenocarcinoma tumors.

Selpercatinib

Selpercatinib, a *RET* kinase inhibitor, was approved by the FDA in 2022 for the treatment of advanced or metastatic *RET* gene fusion-positive solid tumors that have progressed on or following prior systemic treatment or who have no satisfactory alternative treatment options.[181] This approval was based on data from the ongoing international phase I/II LIBRETTO-001 trial, which evaluated the dose escalation and dose expansion of selpercatinib in patients with *RET* gene fusion-positive tumors (other than non-small cell lung cancer and thyroid cancer).[182] The ORR was 44% in the 41 evaluable patients who received the recommended starting dose of 160 mg twice daily. Serious treatment-

Version 2.2025 © 2024 National Comprehensive Cancer Network© (NCCN©), All rights reserved. NCCN Guidelines® and this illustration may not be reproduced in any form without the express written permission of NCCN.

Printed by Elizabeth Moore on 4/30/2025 10:21:39 AM. For personal use only. Not approved for distribution. Copyright © 2025 National Comprehensive Cancer Network, Inc., All Rights Reserved.

related adverse events occurred in 40% of 45 patients. The most common grade 3 or higher treatment-related adverse events were hypertension (22%), increased alanine aminotransferase (16%), and increased aspartate aminotransferase (13%). Based on these data, selpercatinib may be used to treat patients with locally advanced or metastatic solid tumors that progressed on or following prior systemic treatment or who have no satisfactory alternative treatment options.

Dabrafenib and Trametinib

Dabrafenib, a *BRAF* V600E-directed tyrosine kinase inhibitor (TKI), used in combination with trametinib, a MEK inhibitor, was approved by the FDA in 2022 for the treatment of unresectable or metastatic *BRAF* V600E mutated solid tumors that have progressed following prior treatment and have no satisfactory alternative treatment options.[183] The open-label, single-arm EAY131-H study evaluated the efficacy of dabrafenib and trametinib in solid tumors with *BRAF* V600 mutations (excluding those with melanoma, thyroid or colorectal cancer, and non-small cell lung cancer).[184] Of the 29 patients included in the primary efficacy analysis, ORR was 38% (90% CI, 22.9%–54.9%) with $P < .0001$ against a null rate of 5%, and PFS was 11.4 months (90% CI, 8.4–16.3 months). Average OS was 28.6 months. Based on these data, the Panel recommends dabrafenib and trametinib as a treatment option for patients with *BRAF* V600E mutated solid tumors that have progressed following prior treatment and have no satisfactory treatment options.

Entrectinib, Larotrectinib, and Repotrectinib

Entrectinib and larotrectinib (*TRK*-directed TKIs), and repotrectinib (a next-generation *ROS1* and *TRK*-directed TKI), are used as single agents in patients with *NTRK* gene fusion-positive tumors without a known acquired resistance mutation, that are metastatic or where surgical resection is likely to result in severe morbidity, and that have no satisfactory alternative treatments or that have progressed following treatment. A pooled analysis of three clinical trials (two phase 1 trials [ALKA-372–001 and STARTRK-1] and one phase 2 trial [STARTRK-2]) evaluated the activity of entrectinib in 54 patients aged ≥18 years with *NTRK* gene fusion-positive solid tumors.[45] Thirty one participants (57%; 95% CI 43.2–70.8]) had an objective response, of which 4 (7%) and 27 (50%) had a complete response and partial response, respectively. The average duration of response was 10 months. To evaluate the efficacy of larotrectinib on *NTRK* gene fusion-positive solid tumors, 55 patients were enrolled in one of three protocols: a phase 1 study involving adults, a phase 1–2 study involving children, or a phase 2 study involving adolescents and adults.[44] ORR was 75% (95% CI, 61–85) at the primary data cutoff date. Seven (13%) patients had a complete response, 34 (62%) had a partial response, and 7 (13%) had stable disease. At 1 year, 71% of participants continued to have a response and 55% remained progression free. The ongoing phase I/II TRIDENT-1 trial evaluated the safety and efficacy of repotrectinib in TKI-naïve and TKI-pretreated *ROS1* and *NTRK* gene fusion-positive locally advanced or metastatic solid tumors.[185] Of the total participants in the study (TKI-naïve: n = 40; TKI-pretreated: n = 48), one (n =1) had CUP in the TKI-pretreated cohort. The primary endpoint of TRIDENT-1 was confirmed ORR and results showed an ORR of 50% (95% CI, 35-65) in the TKI-pretreated cohort (Clinical Trial ID: NCT03093116).

Fam-Trastuzumab Deruxtecan-nxki

Fam-trastuzumab deruxtecan-nxki (T-DXd), an antibody drug conjugate, was approved by the FDA in 2024 for patients with HER2-positive (IHC 3+) advanced or metastatic solid tumors that progressed on or following prior systemic treatment and who have no satisfactory alternative treatment options.[186] An open-label phase II study evaluated the efficacy of T-DXd in 267 patients (of which n = 5 had CUP) with HER2-expressing (IHC 3+/2+) locally advanced or metastatic solid tumors who had received ≥1 systemic treatment or without alternative treatment options.[187] Results

Version 2.2025 © 2024 National Comprehensive Cancer Network© (NCCN©), All rights reserved. NCCN Guidelines® and this illustration may not be reproduced in any form without the express written permission of NCCN.

Printed by Elizabeth Moore on 4/30/2025 10:21:39 AM. For personal use only. Not approved for distribution. Copyright © 2025 National Comprehensive Cancer Network, Inc., All Rights Reserved.

in those with central HER2 (IHC 3+) expressing solid tumors showed an ORR of 61.3% (95% CI, 49.4–72.4) and average OS of 21.1 months (95% CI, 15.3–29.6). Based on these data, the Panel recommends T-DXd as a useful in certain circumstances treatment option for patients with HER2-positive (IHC 3+) solid tumors who meet the criteria consistent with the FDA indication.

Squamous Cell Carcinoma

Platinum-based regimens have typically been used to treat disseminated SCC. Historically, the combination of cisplatin and fluorouracil has been the most frequently used regimen for patients with SCC of unknown primary.[188,189] Overall, only a few small studies have evaluated the efficacy of systemic therapy regimens in patients with SCC occult primary tumors. Therefore, the Panel lists possible regimens based on evidence from studies of patients with SCC of known primaries and small studies of patients with SCC of occult primaries. Regimens other than those listed can also be considered.

Paclitaxel and Carboplatin

In the Hellenic Cooperative Oncology Group phase II study of paclitaxel and carboplatin in patients with CUP (discussed above for adenocarcinoma), three patients had tumors of SCC histology.[129] These patients had a response rate of 30% and a median response duration of 3 months. The Panel recommends paclitaxel and carboplatin as a preferred treatment option for patients with occult primary SCC.

mFOLFOX6

FOLFOX is used to treat SCC of the esophagus and stomach.[190,191] The Panel lists mFOLFOX6 as a preferred treatment option for occult primary SCC based on the evidence discussed above for adenocarcinoma.[147,148]

Gemcitabine and Cisplatin

The GEFCAPI 02 trial compared cisplatin to cisplatin plus gemcitabine in 52 patients with CUP.[139] Although the trial was terminated early due to poor accrual, there was a trend towards better OS with the addition of gemcitabine (11 vs. 8 months, with overlapping CIs).

Capecitabine or Fluorouracil

As previously stated, capecitabine and fluorouracil are commonly used as single agents in the treatment of GI cancers.[162-165] The Panel lists single-agent capecitabine and single-agent fluorouracil as treatment options for occult primary SCC based on the evidence discussed above for adenocarcinoma. Single-agent capecitabine or fluorouracil can be given with concurrent RT, if clinically indicated.

Paclitaxel and Cisplatin

The combination of paclitaxel and cisplatin is commonly used to treat esophageal, head and neck, and non-small cell lung cancers.[125,192-195] This regimen has also been assessed in a phase II study of 37 patients with unfavorable presentations of CUP.[196] The ORR was 42% (95% CI, 23%–61%), median time to disease progression was 4 months (95% CI, 1.3–6.8), and the median OS was 11 months (95% CI, 8.3–13.5). Three of the 37 patients had SCC.

Docetaxel and Carboplatin or Cisplatin

The combination of docetaxel and carboplatin was assessed in a phase II trial of 47 patients with CUP.[159] Twenty-four patients had favorable risk disease (defined as predominantly nodal disease or non-mucinous peritoneal carcinomatosis) and 23 had unfavorable risk disease (visceral metastases). The average response rate was 32%, the median time to disease progression was 5.5 months, and the median OS was 16.2 months. It is important to note that these results were mainly driven by

Version 2.2025 © 2024 National Comprehensive Cancer Network© (NCCN©), All rights reserved. NCCN Guidelines® and this illustration may not be reproduced in any form without the express written permission of NCCN.

Printed by Elizabeth Moore on 4/30/2025 10:21:39 AM. For personal use only. Not approved for distribution. Copyright © 2025 National Comprehensive Cancer Network, Inc., All Rights Reserved.

the superior outcomes seen in patients with favorable risk disease. Patients with favorable risk disease had a response rate of 46% (compared to 17% in patients with unfavorable risk disease) and a median OS of 22.6 months (compared to only 5.3 months in patients with unfavorable risk disease).

The efficacy of docetaxel and cisplatin was assessed in a trial of 45 patients with CUP.[197] The ORR was 65.1%, the median time to progression was 5 months, and the median OS was 11.8 months. Two patients in this study had tumors of SCC histology and both had a partial response to the docetaxel/cisplatin regimen. Combination therapy with docetaxel and cisplatin was also examined in a cohort of 29 patients with CUP, four of whom had tumors of SCC histology.[160] The ORR was 37.9%, and median PFS and OS were 6 months and 16 months, respectively.

Cisplatin and Fluorouracil

This regimen has historically been used in the treatment of metastatic anal, head and neck, and esophageal SCC.[194,198-202] Cisplatin and fluorouracil has been retrospectively evaluated in patients with SCC of unknown primary.[188,189] Kusaba et al reported a response rate of 54.5%, median time to progression of 3 months, and a median OS of 10 months in a retrospective analysis of 11 patients with CUP who had received this regimen.[203] Combined cisplatin and fluorouracil can be given with concurrent RT, if clinically indicated.

Docetaxel, Cisplatin, and Fluorouracil (DCF)

The combination of docetaxel, cisplatin, and fluorouracil is commonly used to treat gastric, esophageal, and head and neck cancers.[204-207] In a randomized trial of 213 patients with advanced SCC of the head and neck, patients received cisplatin and fluorouracil (with or without docetaxel) followed by RT.[204] The ORRs were 80% and 59.2% in the 3-drug and 2-drug arms, respectively (P = .002). A similar trial involving 501 patients with advanced head and neck SCC reported ORRs of 72% and 64%, respectively, for patients treated with DCF or cisplatin and fluorouracil alone.[205] However, DCF has been associated with significant toxicities, including grade 4 febrile neutropenia, and should therefore be reserved for patients with a PS of 0 to 1.

Pembrolizumab

The Panel recommends pembrolizumab for dMMR/MSI-H or TMB-H (≥10 mut/Mb) occult primary SCC tumors based on the evidence discussed above for adenocarcinoma.[175,177]

Selpercatinib

The Panel recommends selpercatinib for patients with locally advanced or metastatic solid SCC occult primary tumors that progressed on or following prior systemic treatment or who have no satisfactory alternative treatment options based on the evidence discussed above for adenocarcinoma.[182]

Neuroendocrine Tumors

Neuroendocrine CUPs are uncommon, constituting approximately 12% to 22% of all diagnosed neuroendocrine tumors, and their clinical behavior is dependent on the tumor grade and level of differentiation.[208,209] Neuroendocrine tumors, regardless of grade, represent a favorable prognostic subset of CUPs that are responsive to combination chemotherapy, making long-term survival a possibility in some patients.[208]

Hainsworth et al evaluated the efficacy of paclitaxel, carboplatin, and etoposide in patients with metastatic PDNE carcinomas who had received no prior treatment.[210] Of these patients, 62% had PDNE of unknown primary. Major responses were observed in 53% of patients,

Version 2.2025 © 2024 National Comprehensive Cancer Network© (NCCN©), All rights reserved. NCCN Guidelines® and this illustration may not be reproduced in any form without the express written permission of NCCN.

Printed by Elizabeth Moore on 4/30/2025 10:21:39 AM. For personal use only. Not approved for distribution. Copyright © 2025 National Comprehensive Cancer Network, Inc., All Rights Reserved.

with a median survival of 14.5 months and 2- and 3-year survival rates of 33% and 24%, respectively. The results of this trial showed that PDNE carcinomas are chemosensitive, with a high ORR to combination chemotherapy.

In another study, the combination of cisplatin and etoposide produced significant responses in patients with poorly differentiated, rapidly progressing neuroendocrine tumors (carcinoids and pancreatic neuroendocrine tumors of known primaries) when used as a second- or third-line treatment.[211] In two small series of patients, temozolomide, as a single agent or in combination with thalidomide, was also found to be effective in the treatment of advanced or metastatic neuroendocrine tumors.[212,213]

PDNE tumors can also be treated with small cell lung cancer regimens. In a randomized phase III trial (JCOG 9702), the combination of carboplatin plus etoposide was equally as effective as cisplatin plus etoposide in older patients with small cell lung cancer or those with poor-risk disease who were not previously treated.[214] No significant differences were seen in response rate (73% for both regimens) and median OS (10.6 months for carboplatin and etoposide vs. 9.9 months for cisplatin and etoposide).

The Panel recommends that poorly differentiated (high-grade or anaplastic) or small cell subtype (other than lung) neuroendocrine tumors be treated following the NCCN Guidelines for Small Cell Lung Cancer. Well-differentiated neuroendocrine tumors should be treated as carcinoid tumors in the NCCN Guidelines for Neuroendocrine and Adrenal Tumors.

Leucovorin Shortage

Leucovorin is indicated with certain fluorouracil-based regimens. However, there is currently a shortage of leucovorin in the United States.[172] There are no specific data to guide management under these circumstances, and all proposed strategies are empiric. One is the use of levoleucovorin, which is commonly used in Europe. A levoleucovorin dose of 200 mg/m^2 is equivalent to 400 mg/m^2 of standard leucovorin. Another option is to use lower doses of leucovorin in all patients, since lower doses are likely to be as efficacious as higher doses based on several studies in patients with colorectal cancer.[215-217] However, there are insufficient high-quality data to support either approach. Therefore, the Panel recommends use of these regimens without leucovorin in situations where leucovorin is not available.

Radiation Therapy

RT is a treatment option for a variety of localized tumors, particularly as follow-up treatment after lymph node dissection. Adjuvant RT may be appropriate if the disease is limited to a single nodal site with extranodal extension, or in the case of inadequate nodal dissection with multiple positive nodes. Definitive RT can be considered for patients with localized disease. RT alone may also be considered for bone lesions, a retroperitoneal mass with non-germ cell histology, or supraclavicular nodal involvement in site-specific SCC. Stereotactic ablative radiotherapy (SABR) may be used for limited (1–3) metastases or pulmonary metastases.[218,219] In the palliative setting, hypofractionated RT can be considered for symptomatic patients with uncontrolled pain, impending pathologic fracture, or impending spinal cord compression.

A study by Janssen et al examined individualized intensity-modulated RT (IMRT) with risk-adapted planning treatment volumes in 28 patients with CUP and cervical nodal metastases.[220] The majority of patients (71%) received concomitant systemic therapy. In this cohort, 3-year OS, mucosal control, neck control, and distant metastasis-free survival rates were 76%, 100%, 93%, and 88%, respectively. No patient experienced a locoregional recurrence and no grade 2 or higher adverse events were reported. Another retrospective study evaluated the utility of IMRT in 260 patients with CUP metastatic to the neck. The 5-year OS, regional

Version 2.2025 © 2024 National Comprehensive Cancer Network© (NCCN©), All rights reserved. NCCN Guidelines® and this illustration may not be reproduced in any form without the express written permission of NCCN.

Printed by Elizabeth Moore on 4/30/2025 10:21:39 AM. For personal use only. Not approved for distribution. Copyright © 2025 National Comprehensive Cancer Network, Inc., All Rights Reserved.

control, and distant metastases-free survival rates were 84%, 91%, and 94%, respectively.[221] However, 7% of patients were diagnosed with chronic radiation-associated dysphagia. A third retrospective study assessed RT in 68 patients with metastatic head and neck SCC of unknown primary.[222] These patients underwent oropharynx-targeted RT to spare the mucosal surfaces of the nasopharynx, hypopharynx, and larynx; 40% of patients received IMRT and 56% of patients received concurrent chemoradiation, resulting in an actuarial locoregional control rate of 95.5% and a median time to locoregional recurrence of 18 months. RT-associated toxicities included grade 1 xerostomia, dysphagia, neck stiffness, and trismus. The results of these studies are promising; however, large randomized prospective trials are needed to further assess the efficacy and safety of IMRT-based treatment approaches for CUP.

Locoregional Therapeutic Options

In patients with unresectable localized liver lesions, locoregional therapeutic options may be considered when clinically indicated based on tumor size, pathology, and clinical presentation. Recommendations for locoregional treatment options are described in the NCCN Guidelines for Hepatocellular Carcinoma.

Specialized Approaches

Specialized approaches are suggested for all patients with disseminated metastases. The term emphasizes the importance of individualized treatment plans. Specialized approaches may include palliative care options (such as thoracentesis and paracentesis), targeted therapies, and/or novel approaches to RT. The importance of distress management is also discussed in the algorithm and included as a specialized approach. For many patients the apparent uncertainties surrounding the diagnosis of an unknown primary cancer may result in significant psychosocial distress and increased difficulty in accepting treatment options. Empathetic discussion about the natural history of these types of cancer and their prognosis, and the provision of support and counseling both by the primary oncology team and specialized services may help to alleviate this distress. For additional information on addressing psychosocial distress, see the NCCN Guidelines for Distress Management.

Follow-up

Follow-up frequency should be determined by clinical need in patients with active disease or localized disease in remission. Follow-up consists of a history and physical examination, with diagnostic tests for patients who are symptomatic.

For patients with active and incurable disease, psychosocial support, symptom management, end-of-life discussions, palliative care interventions, and hospice care should all be considered and used as appropriate (see *Psychosocial Distress* and *Supportive Care* above). Please see the NCCN Guidelines for Distress Management, the NCCN Guidelines for Palliative Care, and the NCCN Guidelines for Survivorship for more information.

Version 2.2025 © 2024 National Comprehensive Cancer Network© (NCCN©), All rights reserved. NCCN Guidelines® and this illustration may not be reproduced in any form without the express written permission of NCCN.

Printed by Elizabeth Moore on 4/30/2025 10:21:39 AM. For personal use only. Not approved for distribution. Copyright © 2025 National Comprehensive Cancer Network, Inc., All Rights Reserved.

References

1. Greco FA, Hainsworth JD. Cancer of Unknown Primary Site. In: DeVita VT, Lawrence TS, Rosenburg SA, eds. DeVita, Hellman, and Rosenberg's Cancer: Principles & Practice of Oncology (ed 10th). Philadelphia: Lippincott Williams & Wilkins; 2014:1720-1737.
2. Losa F, Iglesias L, Pane M, et al. 2018 consensus statement by the Spanish Society of Pathology and the Spanish Society of Medical Oncology on the diagnosis and treatment of cancer of unknown primary. Clin Transl Oncol 2018;20:1361-1372. Available at: https://www.ncbi.nlm.nih.gov/pubmed/29808414.
3. Pavlidis N. Cancer of unknown primary: biological and clinical characteristics. Ann Oncol 2003;14 Suppl 3:iii11-18. Available at: http://www.ncbi.nlm.nih.gov/pubmed/12821533.
4. Pavlidis N, Pentheroudakis G. Cancer of unknown primary site. Lancet 2012;379:1428-1435. Available at: http://www.ncbi.nlm.nih.gov/pubmed/22414598.
5. Raghav K, Hwang H, Jacome AA, et al. Development and validation of a novel nomogram for individualized prediction of survival in cancer of unknown primary. Clin Cancer Res 2021;27:3414-3421. Available at: https://www.ncbi.nlm.nih.gov/pubmed/33858857.
6. Kang S, Jeong JH, Yoon S, et al. Real-world data analysis of patients with cancer of unknown primary. Sci Rep 2021;11:23074. Available at: https://www.ncbi.nlm.nih.gov/pubmed/34845302.
7. PubMed Overview. National Institutes of Health; Available at: https://pubmed.ncbi.nlm.nih.gov/about/. Accessed July 20, 2023.
8. Bugat R, Bataillard A, Lesimple T, et al. Summary of the standards, options and recommendations for the management of patients with carcinoma of unknown primary site (2002). Br J Cancer 2003;89 Suppl 1:S59-66. Available at: http://www.ncbi.nlm.nih.gov/pubmed/12915904.
9. Pavlidis N, Fizazi K. Cancer of unknown primary (CUP). Crit Rev Oncol Hematol 2005;54:243-250. Available at: http://www.ncbi.nlm.nih.gov/pubmed/15890271.
10. Siegel RL, Giaquinto AN, Jemal A. Cancer statistics, 2024. CA Cancer J Clin 2024;74:12-49. Available at: https://www.ncbi.nlm.nih.gov/pubmed/38230766.
11. Qaseem A, Usman N, Jayaraj JS, et al. Cancer of unknown primary: A review on clinical guidelines in the development and targeted management of patients with the unknown primary site. Cureus 2019;11:e5552. Available at: https://www.ncbi.nlm.nih.gov/pubmed/31695975.
12. Hemminki K, Ji J, Sundquist J, Shu X. Familial risks in cancer of unknown primary: tracking the primary sites. J Clin Oncol 2011;29:435-440. Available at: http://www.ncbi.nlm.nih.gov/pubmed/21189391.
13. Blaszyk H, Hartmann A, Bjornsson J. Cancer of unknown primary: clinicopathologic correlations. APMIS 2003;111:1089-1094. Available at: http://www.ncbi.nlm.nih.gov/pubmed/14678017.
14. Hillen HF. Unknown primary tumours. Postgrad Med J 2000;76:690-693. Available at: http://www.ncbi.nlm.nih.gov/pubmed/11060142.
15. Hermans K, Kazemzadeh F, Loef C, et al. Risk factors for cancer of unknown primary: a literature review. BMC Cancer 2023;23:314. Available at: https://www.ncbi.nlm.nih.gov/pubmed/37020279.
16. Buttar A, Lambert L, Liebmann J, Pieters R. Cancers of Unknown Primary. In: Pieters R, Liebmann J, eds. Cancer Concepts: A Guidebook for the Non-Oncologist. Worcester, MA: University of Massachusetts Medical School; 2015.
17. Chorost MI, Lee MC, Yeoh CB, et al. Unknown primary. J Surg Oncol 2004;87:191-203. Available at: http://www.ncbi.nlm.nih.gov/pubmed/15334635.
18. Ostojewska J, Wieczorek I, Pachcinski O, et al. Detecting undetectable - epidemiology, etiology, and diagnosis of carcinoma of unknown primary - systematic review. Folia Med Cracov 2023;63:19-37. Available at: https://www.ncbi.nlm.nih.gov/pubmed/37406274.
19. Culine S. Prognostic factors in unknown primary cancer. Semin Oncol 2009;36:60-64. Available at: http://www.ncbi.nlm.nih.gov/pubmed/19179189.
20. Thomassen I, Verhoeven RH, van Gestel YR, et al. Population-based incidence, treatment and survival of patients with peritoneal metastases of unknown origin. Eur J Cancer 2014;50:50-56. Available at: http://www.ncbi.nlm.nih.gov/pubmed/24011935.

Version 2.2025 © 2024 National Comprehensive Cancer Network© (NCCN©), All rights reserved. NCCN Guidelines® and this illustration may not be reproduced in any form without the express written permission of NCCN.

Printed by Elizabeth Moore on 4/30/2025 10:21:39 AM. For personal use only. Not approved for distribution. Copyright © 2025 National Comprehensive Cancer Network, Inc., All Rights Reserved.

21. Binder C, Matthes KL, Korol D, et al. Cancer of unknown primary-epidemiological trends and relevance of comprehensive genomic profiling. Cancer Med 2018;7:4814-4824. Available at: https://www.ncbi.nlm.nih.gov/pubmed/30019510.
22. Jereczek-Fossa BA, Jassem J, Orecchia R. Cervical lymph node metastases of squamous cell carcinoma from an unknown primary. Cancer Treat Rev 2004;30:153-164. Available at: http://www.ncbi.nlm.nih.gov/pubmed/15023433.
23. Hainsworth JD, Fizazi K. Treatment for patients with unknown primary cancer and favorable prognostic factors. Semin Oncol 2009;36:44-51. Available at: http://www.ncbi.nlm.nih.gov/pubmed/19179187.
24. Beauchamp K, Moran B, O'Brien T, et al. Carcinoma of unknown primary (CUP): an update for histopathologists. Cancer Metastasis Rev 2023;42:1189-1200. Available at: https://www.ncbi.nlm.nih.gov/pubmed/37394540.
25. van de Wouw AJ, Jansen RLH, Speel EJM, Hillen HFP. The unknown biology of the unknown primary tumour: a literature review. Ann Oncol 2003;14:191-196. Available at: http://www.ncbi.nlm.nih.gov/pubmed/12562643.
26. Kamposioras K, Pentheroudakis G, Pavlidis N. Exploring the biology of cancer of unknown primary: breakthroughs and drawbacks. Eur J Clin Invest 2013;43:491-500. Available at: http://www.ncbi.nlm.nih.gov/pubmed/23480555.
27. Rassy E, Assi T, Pavlidis N. Exploring the biological hallmarks of cancer of unknown primary: where do we stand today? Br J Cancer 2020;122:1124-1132. Available at: https://www.ncbi.nlm.nih.gov/pubmed/32042068.
28. Varadhachary GR. Carcinoma of unknown primary origin. Gastrointest Cancer Res 2007;1:229-235. Available at: https://www.ncbi.nlm.nih.gov/pubmed/19262901.
29. Stelow EB, French CA. Carcinomas of the upper aerodigestive tract with rearrangement of the nuclear protein of the testis (NUT) gene (NUT midline carcinomas). Adv Anat Pathol 2009;16:92-96. Available at: http://www.ncbi.nlm.nih.gov/pubmed/19550370.
30. French CA, Kutok JL, Faquin WC, et al. Midline carcinoma of children and young adults with NUT rearrangement. J Clin Oncol 2004;22:4135-4139. Available at: http://www.ncbi.nlm.nih.gov/pubmed/15483023.
31. Bochtler T, Reiling A, Endris V, et al. RAS activation and CDKN2A deletion to predict prognosis in cancer of unknown primary. J Clin Oncol 2019;37:(suppl; abstr e13026). Available at: http://abstracts.asco.org/239/AbstView_239_262817.html.
32. Vikesa J, Moller AK, Kaczkowski B, et al. Cancers of unknown primary origin (CUP) are characterized by chromosomal instability (CIN) compared to metastasis of know origin. BMC Cancer 2015;15:151. Available at: https://www.ncbi.nlm.nih.gov/pubmed/25885340.
33. Dabbs DJ. Diagnostic Immunohistochemistry (ed 3). Philadelphia: Saunders Elsevier; 2010.
34. Oien KA. Pathologic evaluation of unknown primary cancer. Semin Oncol 2009;36:8-37. Available at: http://www.ncbi.nlm.nih.gov/pubmed/19179185.
35. Varadhachary GR, Greco FA. Overview of patient management and future directions in unknown primary carcinoma. Semin Oncol 2009;36:75-80. Available at: http://www.ncbi.nlm.nih.gov/pubmed/19179191.
36. Wick MR. Immunohistochemical approaches to the diagnosis of undifferentiated malignant tumors. Ann Diagn Pathol 2008;12:72-84. Available at: http://www.ncbi.nlm.nih.gov/pubmed/18164421.
37. Bender RA, Erlander MG. Molecular classification of unknown primary cancer. Semin Oncol 2009;36:38-43. Available at: http://www.ncbi.nlm.nih.gov/pubmed/19179186.
38. Monzon FA, Koen TJ. Diagnosis of metastatic neoplasms: molecular approaches for identification of tissue of origin. Arch Pathol Lab Med 2010;134:216-224. Available at: http://www.ncbi.nlm.nih.gov/pubmed/20121609.
39. Varadhachary GR, Raber MN. Cancer of unknown primary site. N Engl J Med 2014;371:757-765. Available at: http://www.ncbi.nlm.nih.gov/pubmed/25140961.
40. Kandalaft PL, Gown AM. Practical applications in immunohistochemistry: carcinomas of unknown primary site. Arch Pathol Lab Med 2016;140:508-523. Available at: https://www.ncbi.nlm.nih.gov/pubmed/26457625.
41. Handorf CR. Gene expression analysis and immunohistochemistry in evaluation of cancer of unknown primary: time for a patient-centered

Version 2.2025 © 2024 National Comprehensive Cancer Network© (NCCN©), All rights reserved. NCCN Guidelines® and this illustration may not be reproduced in any form without the express written permission of NCCN.

Printed by Elizabeth Moore on 4/30/2025 10:21:39 AM. For personal use only. Not approved for distribution. Copyright © 2025 National Comprehensive Cancer Network, Inc., All Rights Reserved.

approach. J Natl Compr Canc Netw 2011;9:1415-1420. Available at: http://www.ncbi.nlm.nih.gov/pubmed/22157559.
42. Selves J, Long-Mira E, Mathieu MC, et al. Immunohistochemistry for Diagnosis of Metastatic Carcinomas of Unknown Primary Site. Cancers (Basel) 2018;10. Available at: https://www.ncbi.nlm.nih.gov/pubmed/29621151.
43. Handorf CR, Kulkarni A, Grenert JP, et al. A multicenter study directly comparing the diagnostic accuracy of gene expression profiling and immunohistochemistry for primary site identification in metastatic tumors. Am J Surg Pathol 2013;37:1067-1075. Available at: http://www.ncbi.nlm.nih.gov/pubmed/23648464.
44. Drilon A, Laetsch TW, Kummar S, et al. Efficacy of larotrectinib in TRK fusion-positive cancers in adults and children. N Engl J Med 2018;378:731-739. Available at: https://www.ncbi.nlm.nih.gov/pubmed/29466156.
45. Doebele RC, Drilon A, Paz-Ares L, et al. Entrectinib in patients with advanced or metastatic NTRK fusion-positive solid tumours: integrated analysis of three phase 1-2 trials. Lancet Oncol 2020;21:271-282. Available at: https://www.ncbi.nlm.nih.gov/pubmed/31838007.
46. Chrzanowska NM, Kowalewski J, Lewandowska MA. Use of fluorescence in situ hybridization (FISH) in diagnosis and tailored therapies in solid tumors. Molecules 2020;25. Available at: https://www.ncbi.nlm.nih.gov/pubmed/32316657.
47. Carter D. How fluorescence in situ hybridization (FISH) fits into cancer care. Cancerwise 2021. Available at: https://www.mdanderson.org/cancerwise/how-fluorescence-in-situ-hybridization--fish--fits-into-cancer-care.h00-159463212.html.
48. Holmes BJ, Maleki Z, Westra WH. The fidelity of p16 staining as a surrogate marker of human papillomavirus status in fine-needle aspirates and core biopsies of neck node metastases: implications for HPV testing protocols. Acta Cytol 2015;59:97-103. Available at: https://www.ncbi.nlm.nih.gov/pubmed/25765380.
49. Higo S, Ishii H, Ozawa H. Recent advances in high-sensitivity in situ hybridization and costs and benefits to consider when employing these methods. Acta Histochem Cytochem 2023;56:49-54. Available at: https://www.ncbi.nlm.nih.gov/pubmed/37425096.
50. Conner JR, Hornick JL. Metastatic carcinoma of unknown primary: diagnostic approach using immunohistochemistry. Adv Anat Pathol 2015;22:149-167. Available at: http://www.ncbi.nlm.nih.gov/pubmed/25844674.
51. Hainsworth JD, Greco FA. Gene expression profiling in patients with carcinoma of unknown primary site: from translational research to standard of care. Virchows Arch 2014;464:393-402. Available at: http://www.ncbi.nlm.nih.gov/pubmed/24487792.
52. Monzon FA, Dumur CI. Diagnosis of uncertain primary tumors with the Pathwork tissue-of-origin test. Expert Rev Mol Diagn 2010;10:17-25. Available at: http://www.ncbi.nlm.nih.gov/pubmed/20014919.
53. Monzon FA, Lyons-Weiler M, Buturovic LJ, et al. Multicenter validation of a 1,550-gene expression profile for identification of tumor tissue of origin. J Clin Oncol 2009;27:2503-2508. Available at: http://www.ncbi.nlm.nih.gov/pubmed/19332734.
54. Pillai R, Deeter R, Rigl CT, et al. Validation and reproducibility of a microarray-based gene expression test for tumor identification in formalin-fixed, paraffin-embedded specimens. J Mol Diagn 2011;13:48-56. Available at: http://www.ncbi.nlm.nih.gov/pubmed/21227394.
55. Tothill RW, Shi F, Paiman L, et al. Development and validation of a gene expression tumour classifier for cancer of unknown primary. Pathology 2015;47:7-12. Available at: http://www.ncbi.nlm.nih.gov/pubmed/25485653.
56. Meiri E, Mueller WC, Rosenwald S, et al. A second-generation microRNA-based assay for diagnosing tumor tissue origin. Oncologist 2012;17:801-812. Available at: http://www.ncbi.nlm.nih.gov/pubmed/22618571.
57. Talantov D, Baden J, Jatkoe T, et al. A quantitative reverse transcriptase-polymerase chain reaction assay to identify metastatic carcinoma tissue of origin. J Mol Diagn 2006;8:320-329. Available at: http://www.ncbi.nlm.nih.gov/pubmed/16825504.
58. Ma X-J, Patel R, Wang X, et al. Molecular classification of human cancers using a 92-gene real-time quantitative polymerase chain reaction assay. Arch Pathol Lab Med 2006;130:465-473. Available at: http://www.ncbi.nlm.nih.gov/pubmed/16594740.
59. Rosenfeld N, Aharonov R, Meiri E, et al. MicroRNAs accurately identify cancer tissue origin. Nat Biotechnol 2008;26:462-469. Available at: http://www.ncbi.nlm.nih.gov/pubmed/18362881.
60. Rosenwald S, Gilad S, Benjamin S, et al. Validation of a microRNA-based qRT-PCR test for accurate identification of tumor tissue origin.

Version 2.2025 © 2024 National Comprehensive Cancer Network© (NCCN©), All rights reserved. NCCN Guidelines® and this illustration may not be reproduced in any form without the express written permission of NCCN.

Printed by Elizabeth Moore on 4/30/2025 10:21:39 AM. For personal use only. Not approved for distribution. Copyright © 2025 National Comprehensive Cancer Network, Inc., All Rights Reserved.

Mod Pathol 2010;23:814-823. Available at: http://www.ncbi.nlm.nih.gov/pubmed/20348879.
61. Varadhachary GR, Spector Y, Abbruzzese JL, et al. Prospective gene signature study using microRNA to identify the tissue of origin in patients with carcinoma of unknown primary (CUP). Clin Cancer Res 2011;17:4063-4070. Available at: http://www.ncbi.nlm.nih.gov/pubmed/21531815.
62. Posner A, Prall OW, Sivakumaran T, et al. A comparison of DNA sequencing and gene expression profiling to assist tissue of origin diagnosis in cancer of unknown primary. J Pathol 2023;259:81-92. Available at: https://www.ncbi.nlm.nih.gov/pubmed/36287571.
63. Weiss LM, Chu P, Schroeder BE, et al. Blinded comparator study of immunohistochemical analysis versus a 92-gene cancer classifier in the diagnosis of the primary site in metastatic tumors. J Mol Diagn 2013;15:263-269. Available at: http://www.ncbi.nlm.nih.gov/pubmed/23287002.
64. Hainsworth JD, Rubin MS, Spigel DR, et al. Molecular gene expression profiling to predict the tissue of origin and direct site-specific therapy in patients with carcinoma of unknown primary site: a prospective trial of the Sarah Cannon research institute. J Clin Oncol 2013;31:217-223. Available at: http://www.ncbi.nlm.nih.gov/pubmed/23032625.
65. Hayashi H, Kurata T, Takiguchi Y, et al. Randomized phase II trial comparing site-specific treatment based on gene expression profiling with carboplatin and paclitaxel for patients with cancer of unknown primary site. J Clin Oncol 2019;37:570-579. Available at: https://www.ncbi.nlm.nih.gov/pubmed/30653423.
66. Fizazi K, Maillard A, Penel N, et al. A phase III trial of empiric chemotherapy with cisplatin and gemcitabine or systemic treatment tailored by molecular gene expression analysis in patients with carcinomas of an unknown primary (CUP) site (GEFCAPI 04). Ann Oncol 2019;30:v851. Available at: https://doi.org/10.1093/annonc/mdz394.
67. Ross JS, Wang K, Gay L, et al. Comprehensive genomic profiling of carcinoma of unknown primary site: new routes to targeted therapies. JAMA Oncol 2015;1:40-49. Available at: http://www.ncbi.nlm.nih.gov/pubmed/26182302.
68. Ma W, Wu H, Chen Y, et al. New techniques to identify the tissue of origin for cancer of unknown primary in the era of precision medicine: progress and challenges. Brief Bioinform 2024;25. Available at: https://www.ncbi.nlm.nih.gov/pubmed/38343328.
69. Huey RW, Shah AT, Reddi HV, et al. Feasibility and value of genomic profiling in cancer of unknown primary: real-world evidence from prospective profiling study. J Natl Cancer Inst 2023;115:994-997. Available at: https://www.ncbi.nlm.nih.gov/pubmed/37202363.
70. Mosele MF, Westphalen CB, Stenzinger A, et al. Recommendations for the use of next-generation sequencing (NGS) for patients with advanced cancer in 2024: a report from the ESMO Precision Medicine Working Group. Ann Oncol 2024;35:588-606. Available at: https://www.ncbi.nlm.nih.gov/pubmed/38834388.
71. Tothill RW, Li J, Mileshkin L, et al. Massively-parallel sequencing assists the diagnosis and guided treatment of cancers of unknown primary. J Pathol 2013;231:413-423. Available at: http://www.ncbi.nlm.nih.gov/pubmed/24037760.
72. Gatalica Z, Millis SZ, Vranic S, et al. Comprehensive tumor profiling identifies numerous biomarkers of drug response in cancers of unknown primary site: analysis of 1806 cases. Oncotarget 2014;5:12440-12447. Available at: http://www.ncbi.nlm.nih.gov/pubmed/25415047.
73. Kato S, Krishnamurthy N, Banks KC, et al. Utility of genomic analysis in circulating tumor DNA from patients with carcinoma of unknown primary. Cancer Res 2017;77:4238-4246. Available at: https://www.ncbi.nlm.nih.gov/pubmed/28642281.
74. Varghese AM, Arora A, Capanu M, et al. Clinical and molecular characterization of patients with cancer of unknown primary in the modern era. Ann Oncol 2017;28:3015-3021. Available at: https://www.ncbi.nlm.nih.gov/pubmed/29045506.
75. Ross JS, Sokol ES, Moch H, et al. Comprehensive genomic profiling (CGP) of carcinoma of unknown primary origin (CUP): Retrospective molecular classification of potentially eligible patients (pts) for targeted or immunotherapy treatment (tx) using the prospective CUPISCO trial's criteria. Ann Oncol 2019;30:v851. Available at: https://oncologypro.esmo.org/meeting-resources/esmo-2019-congress/Comprehensive-genomic-profiling-CGP-of-carcinoma-of-unknown-primary-origin-CUP-Retrospective-molecular-classification-of-potentially-eligible-patients-pts-for-targeted-or-immunotherapy-treatment-tx-using-the-prospective-CUPISCO-trial-s-criteria#page.

Version 2.2025 © 2024 National Comprehensive Cancer Network© (NCCN©), All rights reserved. NCCN Guidelines® and this illustration may not be reproduced in any form without the express written permission of NCCN.

Printed by Elizabeth Moore on 4/30/2025 10:21:39 AM. For personal use only. Not approved for distribution. Copyright © 2025 National Comprehensive Cancer Network, Inc., All Rights Reserved.

76. Es HA, Mahdizadeh H, Asl AAH, Totonchi M. Genomic alterations and possible druggable mutations in carcinoma of unknown primary (CUP). Sci Rep 2021;11:15112. Available at: https://www.ncbi.nlm.nih.gov/pubmed/34302033.
77. Gatalica Z, Xiu J, Swensen J, Vranic S. Comprehensive analysis of cancers of unknown primary for the biomarkers of response to immune checkpoint blockade therapy. Eur J Cancer 2018;94:179-186. Available at: https://www.ncbi.nlm.nih.gov/pubmed/29571084.
78. Kim KW, Krajewski KM, Jagannathan JP, et al. Cancer of unknown primary sites: what radiologists need to know and what oncologists want to know. AJR Am J Roentgenol 2013;200:484-492. Available at: http://www.ncbi.nlm.nih.gov/pubmed/23436835.
79. Chen K, Chen X. Positron emission tomography imaging of cancer biology: current status and future prospects. Semin Oncol 2011;38:70-86. Available at: http://www.ncbi.nlm.nih.gov/pubmed/21362517.
80. Demir H, Berk F, Raderer M, et al. The role of nuclear medicine in the diagnosis of cancer of unknown origin. Q J Nucl Med Mol Imaging 2004;48:164-173. Available at: http://www.ncbi.nlm.nih.gov/pubmed/15243411.
81. Delgado-Bolton RC, Fernandez-Perez C, Gonzalez-Mate A, Carreras JL. Meta-analysis of the performance of 18F-FDG PET in primary tumor detection in unknown primary tumors. J Nucl Med 2003;44:1301-1314. Available at: http://www.ncbi.nlm.nih.gov/pubmed/12902422.
82. Seve P, Billotey C, Broussolle C, et al. The role of 2-deoxy-2-[F-18]fluoro-D-glucose positron emission tomography in disseminated carcinoma of unknown primary site. Cancer 2007;109:292-299. Available at: http://www.ncbi.nlm.nih.gov/pubmed/17167760.
83. Zhu L, Wang N. 18F-fluorodeoxyglucose positron emission tomography-computed tomography as a diagnostic tool in patients with cervical nodal metastases of unknown primary site: a meta-analysis. Surg Oncol 2013;22:190-194. Available at: http://www.ncbi.nlm.nih.gov/pubmed/23849685.
84. Podoloff DA, Ball DW, Ben-Josef E, et al. NCCN task force: clinical utility of PET in a variety of tumor types. J Natl Compr Canc Netw 2009;7 Suppl 2:1-26. Available at: http://www.ncbi.nlm.nih.gov/pubmed/19555588.
85. Townsend DW, Carney JPJ, Yap JT, Hall NC. PET/CT today and tomorrow. J Nucl Med 2004;45 Suppl 1:14. Available at: http://www.ncbi.nlm.nih.gov/pubmed/14736831.
86. Breuer N, Behrendt FF, Heinzel A, et al. Prognostic relevance of 18F-FDG PET/CT in carcinoma of unknown primary. Clin Nucl Med 2013;39:131-135. Available at: http://www.ncbi.nlm.nih.gov/pubmed/24368527.
87. Gutzeit A, Antoch G, Kuhl H, et al. Unknown primary tumors: detection with dual-modality PET/CT--initial experience. Radiology 2005;234:227-234. Available at: http://www.ncbi.nlm.nih.gov/pubmed/15564390.
88. Hu M, Zhao W, Zhang PL, et al. Clinical applications of 18F-fluorodeoxyglucose positron emission tomography/computed tomography in carcinoma of unknown primary. Chin Med J (Engl) 2011;124:1010-1014. Available at: http://www.ncbi.nlm.nih.gov/pubmed/21542959.
89. Imperiale A, Rust E, Gabriel S, et al. 18F-Fluorodihydroxyphenylalanine PET/CT in patients with neuroendocrine tumors of unknown origin: relation to tumor origin and differentiation. J Nucl Med 2013;55:367-372. Available at: http://www.ncbi.nlm.nih.gov/pubmed/24343986.
90. Nanni C, Rubello D, Castellucci P, et al. Role of 18F-FDG PET-CT imaging for the detection of an unknown primary tumour: preliminary results in 21 patients. Eur J Nucl Med Mol Imaging 2005;32:589-592. Available at: http://www.ncbi.nlm.nih.gov/pubmed/15726356.
91. Pelosi E, Pennone M, Deandreis D, et al. Role of whole body positron emission tomography/computed tomography scan with 18F-fluorodeoxyglucose in patients with biopsy proven tumor metastases from unknown primary site. Q J Nucl Med Mol Imaging 2006;50:15-22. Available at: http://www.ncbi.nlm.nih.gov/pubmed/16557200.
92. Prowse SJ, Shaw R, Ganeshan D, et al. The added value of 18F-fluorodeoxyglucose positron emission tomography computed tomography in patients with neck lymph node metastases from an unknown primary malignancy. J Laryngol Otol 2013;127:780-787. Available at: http://www.ncbi.nlm.nih.gov/pubmed/23919968.
93. Tamam MO, Mulazimoglu M, Guveli TK, et al. Prediction of survival and evaluation of diagnostic accuracy whole body 18F-fluoro-2-deoxyglucose positron emission tomography/computed tomography in

Version 2.2025 © 2024 National Comprehensive Cancer Network© (NCCN©), All rights reserved. NCCN Guidelines® and this illustration may not be reproduced in any form without the express written permission of NCCN.

Printed by Elizabeth Moore on 4/30/2025 10:21:39 AM. For personal use only. Not approved for distribution. Copyright © 2025 National Comprehensive Cancer Network, Inc., All Rights Reserved.

the detection carcinoma of unknown primary origin. Eur Rev Med Pharmacol Sci 2012;16:2120-2130. Available at: http://www.ncbi.nlm.nih.gov/pubmed/23280029.
94. Wang G, Wu Y, Zhang W, et al. Clinical value of whole-body F-18 fluorodeoxyglucose positron emission tomography/computed tomography in patients with carcinoma of unknown primary. J Med Imaging Radiat Oncol 2013;57:65-71. Available at: http://www.ncbi.nlm.nih.gov/pubmed/23374557.
95. Zytoon AA, Elsayed EE, Nassar AI, Murakami K. Pivotal role of PET/CT in characterization of occult metastasis with undetermined origin. Egyptian Journal of Radiology and Nuclear Medicine 2020;51:240. Available at: https://doi.org/10.1186/s43055-020-00357-1.
96. Lee JR, Kim JS, Roh JL, et al. Detection of occult primary tumors in patients with cervical metastases of unknown primary tumors: comparison of (18)F FDG PET/CT with contrast-enhanced CT or CT/MR imaging-prospective study. Radiology 2015;274:764-771. Available at: https://www.ncbi.nlm.nih.gov/pubmed/25405771.
97. Wolpert F, Weller M, Berghoff AS, et al. Diagnostic value of (18)F-fluordesoxyglucose positron emission tomography for patients with brain metastasis from unknown primary site. Eur J Cancer 2018;96:64-72. Available at: https://www.ncbi.nlm.nih.gov/pubmed/29677642.
98. Ambrosini V, Nanni C, Rubello D, et al. 18F-FDG PET/CT in the assessment of carcinoma of unknown primary origin. Radiol Med 2006;111:1146-1155. Available at: http://www.ncbi.nlm.nih.gov/pubmed/17171520.
99. Ruhlmann V, Ruhlmann M, Bellendorf A, et al. Hybrid imaging for detection of carcinoma of unknown primary: a preliminary comparison trial of whole-body PET/MRI versus PET/CT. Eur J Radiol 2016;85:1941-1947. Available at: https://www.ncbi.nlm.nih.gov/pubmed/27776644.
100. Sekine T, Barbosa FG, Sah BR, et al. PET/MR outperforms PET/CT in suspected occult tumors. Clin Nucl Med 2017;42:88-95. Available at: https://www.ncbi.nlm.nih.gov/pubmed/27922861.
101. Godeny M, Lengyel Z, Polony G, et al. Impact of 3T multiparametric MRI and FDG-PET-CT in the evaluation of occult primary cancer with cervical node metastasis. Cancer Imaging 2016;16:38. Available at: https://www.ncbi.nlm.nih.gov/pubmed/27814768.
102. Yoo MG, Kim J, Bae S, et al. Detection of clinically occult primary tumours in patients with cervical metastases of unknown primary tumours: comparison of three-dimensional THRIVE MRI, two-dimensional spin-echo MRI, and contrast-enhanced CT. Clin Radiol 2018;73:410 Available at: https://www.ncbi.nlm.nih.gov/pubmed/29195660.
103. Sauter JL, Chen Y, Alex D, et al. Results from the 2019 American Society of Cytopathology survey on rapid onsite evaluation (ROSE)-part 2: subjective views among the cytopathology community. J Am Soc Cytopathol 2020;9:570-578. Available at: https://www.ncbi.nlm.nih.gov/pubmed/32861593.
104. VanderLaan PA, Chen Y, Alex D, et al. Results from the 2019 American Society of Cytopathology survey on rapid on-site evaluation-Part 1: objective practice patterns. J Am Soc Cytopathol 2019;8:333-341. Available at: https://www.ncbi.nlm.nih.gov/pubmed/31495750.
105. Merino DM, McShane LM, Fabrizio D, et al. Establishing guidelines to harmonize tumor mutational burden (TMB): in silico assessment of variation in TMB quantification across diagnostic platforms: phase I of the Friends of Cancer Research TMB Harmonization Project. J Immunother Cancer 2020;8. Available at: https://www.ncbi.nlm.nih.gov/pubmed/32217756.
106. Bleicher RJ, Morrow M. MRI and breast cancer: role in detection, diagnosis, and staging. Oncology (Williston Park) 2007;21:1521-1528. Available at: http://www.ncbi.nlm.nih.gov/pubmed/18077995.
107. McMahon K, Medoro L, Kennedy D. Breast magnetic resonance imaging: an essential role in malignant axillary lymphadenopathy of unknown origin. Australas Radiol 2005;49:382-389. Available at: http://www.ncbi.nlm.nih.gov/pubmed/16174176.
108. Olson JA, Morris EA, Van Zee KJ, et al. Magnetic resonance imaging facilitates breast conservation for occult breast cancer. Ann Surg Oncol 2000;7:411-415. Available at: http://www.ncbi.nlm.nih.gov/pubmed/10894136.
109. Buchanan CL, Morris EA, Dorn PL, et al. Utility of breast magnetic resonance imaging in patients with occult primary breast cancer. Ann Surg Oncol 2005;12:1045-1053. Available at: http://www.ncbi.nlm.nih.gov/pubmed/16244803.
110. Varadhachary GR, Abbruzzese JL, Lenzi R. Diagnostic strategies for unknown primary cancer. Cancer 2004;100:1776-1785. Available at: http://www.ncbi.nlm.nih.gov/pubmed/15112256.

Version 2.2025 © 2024 National Comprehensive Cancer Network© (NCCN©), All rights reserved. NCCN Guidelines® and this illustration may not be reproduced in any form without the express written permission of NCCN.

Printed by Elizabeth Moore on 4/30/2025 10:21:39 AM. For personal use only. Not approved for distribution. Copyright © 2025 National Comprehensive Cancer Network, Inc., All Rights Reserved.

111. Swaid F, Downs D, Rosemurgy AS. A practical approach to liver metastasis from unknown primary cancer: what surgeons need to know. Cancer Genet 2016;209:559-566. Available at: https://www.ncbi.nlm.nih.gov/pubmed/27601260.
112. Saliminejad M, Bemanian S, Ho A, et al. The yield and cost of colonoscopy in patients with metastatic cancer of unknown primary. Aliment Pharmacol Ther 2013;38:628-633. Available at: http://www.ncbi.nlm.nih.gov/pubmed/23869398.
113. Hyphantis T, Papadimitriou I, Petrakis D, et al. Psychiatric manifestations, personality traits and health-related quality of life in cancer of unknown primary site. Psychooncology 2013;22:2009-2015. Available at: http://www.ncbi.nlm.nih.gov/pubmed/23359412.
114. Guarischi A, Keane TJ, Elhakim T. Metastatic inguinal nodes from an unknown primary neoplasm. A review of 56 cases. Cancer 1987;59:572-577. Available at: http://www.ncbi.nlm.nih.gov/pubmed/3791166.
115. Amela EY, Lauridant-Philippin G, Cousin S, et al. Management of "unfavourable" carcinoma of unknown primary site: synthesis of recent literature. Crit Rev Oncol Hematol 2012;84:213-223. Available at: http://www.ncbi.nlm.nih.gov/pubmed/22503530.
116. Losa F, Soler G, Casado A, et al. SEOM clinical guideline on unknown primary cancer (2017). Clin Transl Oncol 2018;20:89-96. Available at: https://www.ncbi.nlm.nih.gov/pubmed/29230692.
117. Pentheroudakis G, Stoyianni A, Pavlidis N. Cancer of unknown primary patients with midline nodal distribution: midway between poor and favourable prognosis? Cancer Treat Rev 2011;37:120-126. Available at: https://www.ncbi.nlm.nih.gov/pubmed/20673701.
118. Lee J, Hahn S, Kim DW, et al. Evaluation of survival benefits by platinums and taxanes for an unfavourable subset of carcinoma of unknown primary: a systematic review and meta-analysis. Br J Cancer 2013;108:39-48. Available at: http://www.ncbi.nlm.nih.gov/pubmed/23175147.
119. Hainsworth JD, Johnson DH, Greco FA. Cisplatin-based combination chemotherapy in the treatment of poorly differentiated carcinoma and poorly differentiated adenocarcinoma of unknown primary site: results of a 12-year experience. J Clin Oncol 1992;10:912-922. Available at: http://www.ncbi.nlm.nih.gov/pubmed/1375284.
120. van der Gaast A, Verweij J, Henzen-Logmans SC, et al. Carcinoma of unknown primary: identification of a treatable subset? Ann Oncol 1990;1:119-122. Available at: http://www.ncbi.nlm.nih.gov/pubmed/1706613.
121. Greco FA, Gray J, Burris HA, et al. Taxane-based chemotherapy for patients with carcinoma of unknown primary site. Cancer J 2001;7:203-212. Available at: http://www.ncbi.nlm.nih.gov/pubmed/11419028.
122. Belani CP, Choy H, Bonomi P, et al. Combined chemoradiotherapy regimens of paclitaxel and carboplatin for locally advanced non-small-cell lung cancer: a randomized phase II locally advanced multi-modality protocol. J Clin Oncol 2005;23:5883-5891. Available at: http://www.ncbi.nlm.nih.gov/pubmed/16087941.
123. Gadgeel SM, Shields AF, Heilbrun LK, et al. Phase II study of paclitaxel and carboplatin in patients with advanced gastric cancer. Am J Clin Oncol 2003;26:37-41. Available at: http://www.ncbi.nlm.nih.gov/pubmed/12576922.
124. Ohe Y, Ohashi Y, Kubota K, et al. Randomized phase III study of cisplatin plus irinotecan versus carboplatin plus paclitaxel, cisplatin plus gemcitabine, and cisplatin plus vinorelbine for advanced non-small-cell lung cancer: Four-Arm Cooperative Study in Japan. Ann Oncol 2007;18:317-323. Available at: http://www.ncbi.nlm.nih.gov/pubmed/17079694.
125. Schiller JH, Harrington D, Belani CP, et al. Comparison of four chemotherapy regimens for advanced non-small-cell lung cancer. N Engl J Med 2002;346:92-98. Available at: http://www.ncbi.nlm.nih.gov/pubmed/11784875.
126. van Hagen P, Hulshof MC, van Lanschot JJ, et al. Preoperative chemoradiotherapy for esophageal or junctional cancer. N Engl J Med 2012;366:2074-2084. Available at: https://www.ncbi.nlm.nih.gov/pubmed/22646630.
127. van Meerten E, Muller K, Tilanus HW, et al. Neoadjuvant concurrent chemoradiation with weekly paclitaxel and carboplatin for patients with oesophageal cancer: a phase II study. Br J Cancer 2006;94:1389-1394. Available at: http://www.ncbi.nlm.nih.gov/pubmed/16670722.
128. Rassy E, Parent P, Lefort F, et al. New rising entities in cancer of unknown primary: Is there a real therapeutic benefit? Crit Rev Oncol Hematol 2020;147:102882. Available at: https://www.ncbi.nlm.nih.gov/pubmed/32106012.

Version 2.2025 © 2024 National Comprehensive Cancer Network© (NCCN©), All rights reserved. NCCN Guidelines® and this illustration may not be reproduced in any form without the express written permission of NCCN.

Printed by Elizabeth Moore on 4/30/2025 10:21:39 AM. For personal use only. Not approved for distribution. Copyright © 2025 National Comprehensive Cancer Network, Inc., All Rights Reserved.

129. Briasoulis E, Kalofonos H, Bafaloukos D, et al. Carboplatin plus paclitaxel in unknown primary carcinoma: a phase II Hellenic Cooperative Oncology Group Study. J Clin Oncol 2000;18:3101-3107. Available at: http://www.ncbi.nlm.nih.gov/pubmed/10963638.
130. Greco FA, Burris HA, Erland JB, et al. Carcinoma of unknown primary site. Cancer 2000;89:2655-2660. Available at: http://www.ncbi.nlm.nih.gov/pubmed/11135228.
131. Greco FA, Rodriguez GI, Shaffer DW, et al. Carcinoma of unknown primary site: sequential treatment with paclitaxel/carboplatin/etoposide and gemcitabine/irinotecan: a Minnie Pearl Cancer Research Network phase II trial. Oncologist 2004;9:644-652. Available at: http://www.ncbi.nlm.nih.gov/pubmed/15561808.
132. Hainsworth JD, Spigel DR, Clark BL, et al. Paclitaxel/carboplatin/etoposide versus gemcitabine/irinotecan in the first-line treatment of patients with carcinoma of unknown primary site: a randomized, phase III Sarah Cannon Oncology Research Consortium Trial. Cancer J 2010;16:70-75. Available at: http://www.ncbi.nlm.nih.gov/pubmed/20164695.
133. Huebner G, Link H, Kohne CH, et al. Paclitaxel and carboplatin vs gemcitabine and vinorelbine in patients with adeno- or undifferentiated carcinoma of unknown primary: a randomised prospective phase II trial. Br J Cancer 2009;100:44-49. Available at: http://www.ncbi.nlm.nih.gov/pubmed/19066607.
134. Sandler AB, Nemunaitis J, Denham C, et al. Phase III trial of gemcitabine plus cisplatin versus cisplatin alone in patients with locally advanced or metastatic non-small-cell lung cancer. J Clin Oncol 2000;18:122-130. Available at: http://www.ncbi.nlm.nih.gov/pubmed/10623702.
135. Dash A, Pettus JAt, Herr HW, et al. A role for neoadjuvant gemcitabine plus cisplatin in muscle-invasive urothelial carcinoma of the bladder: a retrospective experience. Cancer 2008;113:2471-2477. Available at: https://www.ncbi.nlm.nih.gov/pubmed/18823036.
136. von der Maase H, Hansen SW, Roberts JT, et al. Gemcitabine and cisplatin versus methotrexate, vinblastine, doxorubicin, and cisplatin in advanced or metastatic bladder cancer: results of a large, randomized, multinational, multicenter, phase III study. J Clin Oncol 2000;18:3068-3077. Available at: https://www.ncbi.nlm.nih.gov/pubmed/11001674.
137. Scagliotti GV, Parikh P, von Pawel J, et al. Phase III study comparing cisplatin plus gemcitabine with cisplatin plus pemetrexed in chemotherapy-naive patients with advanced-stage non-small-cell lung cancer. J Clin Oncol 2023;41:2458-2466. Available at: https://www.ncbi.nlm.nih.gov/pubmed/37146426.
138. Culine S, Lortholary A, Voigt J-J, et al. Cisplatin in combination with either gemcitabine or irinotecan in carcinomas of unknown primary site: results of a randomized phase II study--trial for the French Study Group on Carcinomas of Unknown Primary (GEFCAPI 01). J Clin Oncol 2003;21:3479-3482. Available at: http://www.ncbi.nlm.nih.gov/pubmed/12972523.
139. Gross-Goupil M, Fourcade A, Blot E, et al. Cisplatin alone or combined with gemcitabine in carcinomas of unknown primary: results of the randomised GEFCAPI 02 trial. Eur J Cancer 2012;48:721-727. Available at: http://www.ncbi.nlm.nih.gov/pubmed/22317952.
140. Pouessel D, Culine S, Becht C, et al. Gemcitabine and docetaxel as front-line chemotherapy in patients with carcinoma of an unknown primary site. Cancer 2004;100:1257-1261. Available at: http://www.ncbi.nlm.nih.gov/pubmed/15022294.
141. Schuette K, Folprecht G, Kretzschmar A, et al. Phase II trial of capecitabine and oxaliplatin in patients with adeno- and undifferentiated carcinoma of unknown primary. Onkologie 2009;32:162-166. Available at: http://www.ncbi.nlm.nih.gov/pubmed/19372710.
142. Hainsworth JD, Spigel DR, Burris HA, 3rd, et al. Oxaliplatin and capecitabine in the treatment of patients with recurrent or refractory carcinoma of unknown primary site: a phase 2 trial of the Sarah Cannon Oncology Research Consortium. Cancer 2010;116:2448-2454. Available at: http://www.ncbi.nlm.nih.gov/pubmed/20209610.
143. Cassidy J, Clarke S, Diaz-Rubio E, et al. XELOX vs FOLFOX-4 as first-line therapy for metastatic colorectal cancer: NO16966 updated results. Br J Cancer 2011;105:58-64. Available at: http://www.ncbi.nlm.nih.gov/pubmed/21673685.
144. de Gramont A, Van Cutsem E, Schmoll HJ, et al. Bevacizumab plus oxaliplatin-based chemotherapy as adjuvant treatment for colon cancer (AVANT): a phase 3 randomised controlled trial. Lancet Oncol 2012;13:1225-1233. Available at: https://www.ncbi.nlm.nih.gov/pubmed/23168362.

Version 2.2025 © 2024 National Comprehensive Cancer Network© (NCCN©), All rights reserved. NCCN Guidelines® and this illustration may not be reproduced in any form without the express written permission of NCCN.

Printed by Elizabeth Moore on 4/30/2025 10:21:39 AM. For personal use only. Not approved for distribution. Copyright © 2025 National Comprehensive Cancer Network, Inc., All Rights Reserved.

145. Ducreux M, Bennouna J, Hebbar M, et al. Capecitabine plus oxaliplatin (XELOX) versus 5-fluorouracil/leucovorin plus oxaliplatin (FOLFOX-6) as first-line treatment for metastatic colorectal cancer. Int J Cancer 2011;128:682-690. Available at: http://www.ncbi.nlm.nih.gov/pubmed/20473862.
146. Rothenberg ML, Cox JV, Butts C, et al. Capecitabine plus oxaliplatin (XELOX) versus 5-fluorouracil/folinic acid plus oxaliplatin (FOLFOX-4) as second-line therapy in metastatic colorectal cancer: a randomized phase III noninferiority study. Ann Oncol 2008;19:1720-1726. Available at: http://www.ncbi.nlm.nih.gov/pubmed/18550577.
147. Cassidy J, Clarke S, Diaz-Rubio E, et al. Randomized phase III study of capecitabine plus oxaliplatin compared with fluorouracil/folinic acid plus oxaliplatin as first-line therapy for metastatic colorectal cancer. J Clin Oncol 2008;26:2006-2012. Available at: http://www.ncbi.nlm.nih.gov/pubmed/18421053.
148. Cheeseman SL, Joel SP, Chester JD, et al. A 'modified de Gramont' regimen of fluorouracil, alone and with oxaliplatin, for advanced colorectal cancer. Br J Cancer 2002;87:393-399. Available at: http://www.ncbi.nlm.nih.gov/pubmed/12177775.
149. Fuchs CS, Marshall J, Mitchell E, et al. Randomized, controlled trial of irinotecan plus infusional, bolus, or oral fluoropyrimidines in first-line treatment of metastatic colorectal cancer: results from the BICC-C Study. J Clin Oncol 2007;25:4779-4786. Available at: https://www.ncbi.nlm.nih.gov/pubmed/17947725.
150. Guimbaud R, Louvet C, Ries P, et al. Prospective, randomized, multicenter, phase III study of fluorouracil, leucovorin, and irinotecan versus epirubicin, cisplatin, and capecitabine in advanced gastric adenocarcinoma: a French intergroup (Federation Francophone de Cancerologie Digestive, Federation Nationale des Centres de Lutte Contre le Cancer, and Groupe Cooperateur Multidisciplinaire en Oncologie) study. J Clin Oncol 2014;32:3520-3526. Available at: https://www.ncbi.nlm.nih.gov/pubmed/25287828.
151. Sebbagh S, Roux J, Dreyer C, et al. Efficacy of a sequential treatment strategy with GEMOX-based followed by FOLFIRI-based chemotherapy in advanced biliary tract cancers. Acta Oncol 2016;55:1168-1174. Available at: https://www.ncbi.nlm.nih.gov/pubmed/27333436.
152. Zaniboni A, Aitini E, Barni S, et al. FOLFIRI as second-line chemotherapy for advanced pancreatic cancer: a GISCAD multicenter phase II study. Cancer Chemother Pharmacol 2012;69:1641-1645. Available at: https://www.ncbi.nlm.nih.gov/pubmed/22576338.
153. Maugeri-Sacca M, Pizzuti L, Sergi D, et al. FOLFIRI as a second-line therapy in patients with docetaxel-pretreated gastric cancer: a historical cohort. J Exp Clin Cancer Res 2013;32:67. Available at: https://www.ncbi.nlm.nih.gov/pubmed/24330513.
154. Fawaz A, Tilley D, Karachiwala H. Real-world outcomes of patients with advanced gastric cancer treated with FOLFIRI. Journal of Clinical Oncology 2023;41:307-307. Available at: https://ascopubs.org/doi/abs/10.1200/JCO.2023.41.4_suppl.307.
155. Hainsworth JD, Schnabel CA, Erlander MG, et al. A retrospective study of treatment outcomes in patients with carcinoma of unknown primary site and a colorectal cancer molecular profile. Clin Colorectal Cancer 2012;11:112-118. Available at: https://www.ncbi.nlm.nih.gov/pubmed/22000811.
156. Varadhachary GR, Raber MN, Matamoros A, Abbruzzese JL. Carcinoma of unknown primary with a colon-cancer profile-changing paradigm and emerging definitions. Lancet Oncol 2008;9:596-599. Available at: http://www.ncbi.nlm.nih.gov/pubmed/18510991.
157. Varadhachary GR, Talantov D, Raber MN, et al. Molecular profiling of carcinoma of unknown primary and correlation with clinical evaluation. J Clin Oncol 2008;26:4442-4448. Available at: http://www.ncbi.nlm.nih.gov/pubmed/18802157.
158. Greco FA, Erland JB, Morrissey LH, et al. Carcinoma of unknown primary site: phase II trials with docetaxel plus cisplatin or carboplatin. Ann Oncol 2000;11:211-215. Available at: http://www.ncbi.nlm.nih.gov/pubmed/10761758.
159. Pentheroudakis G, Briasoulis E, Kalofonos HP, et al. Docetaxel and carboplatin combination chemotherapy as outpatient palliative therapy in carcinoma of unknown primary: a multicentre Hellenic Cooperative Oncology Group phase II study. Acta Oncol 2008;47:1148-1155. Available at: http://www.ncbi.nlm.nih.gov/pubmed/18607872.
160. Demirci U, Coskun U, Karaca H, et al. Docetaxel and cisplatin in first line treatment of patients with unknown primary cancer: a multicenter study of the Anatolian Society of Medical Oncology. Asian Pac J Cancer

Version 2.2025 © 2024 National Comprehensive Cancer Network© (NCCN©), All rights reserved. NCCN Guidelines® and this illustration may not be reproduced in any form without the express written permission of NCCN.

Printed by Elizabeth Moore on 4/30/2025 10:21:39 AM. For personal use only. Not approved for distribution. Copyright © 2025 National Comprehensive Cancer Network, Inc., All Rights Reserved.

Prev 2014;15:1581-1584. Available at: http://www.ncbi.nlm.nih.gov/pubmed/24641371.
161. Yonemori K, Ando M, Yunokawa M, et al. Irinotecan plus carboplatin for patients with carcinoma of unknown primary site. Br J Cancer 2009;100:50-55. Available at: http://www.ncbi.nlm.nih.gov/pubmed/19088717.
162. Twelves C, Wong A, Nowacki MP, et al. Capecitabine as adjuvant treatment for stage III colon cancer. N Engl J Med 2005;352:2696-2704. Available at: https://www.ncbi.nlm.nih.gov/pubmed/15987918.
163. Lee HS, Choi Y, Hur WJ, et al. Pilot study of postoperative adjuvant chemoradiation for advanced gastric cancer: adjuvant 5-FU/cisplatin and chemoradiation with capecitabine. World J Gastroenterol 2006;12:603-607. Available at: https://www.ncbi.nlm.nih.gov/pubmed/16489675.
164. Wolmark N, Rockette H, Fisher B, et al. The benefit of leucovorin-modulated fluorouracil as postoperative adjuvant therapy for primary colon cancer: results from National Surgical Adjuvant Breast and Bowel Project protocol C-03. J Clin Oncol 1993;11:1879-1887. Available at: https://www.ncbi.nlm.nih.gov/pubmed/8410113.
165. Jager E, Heike M, Bernhard H, et al. Weekly high-dose leucovorin versus low-dose leucovorin combined with fluorouracil in advanced colorectal cancer: results of a randomized multicenter trial. Study Group for Palliative Treatment of Metastatic Colorectal Cancer Study Protocol 1. J Clin Oncol 1996;14:2274-2279. Available at: http://www.ncbi.nlm.nih.gov/pubmed/8708717.
166. Conroy T, Desseigne F, Ychou M, et al. FOLFIRINOX versus gemcitabine for metastatic pancreatic cancer. N Engl J Med 2011;364:1817-1825. Available at: https://www.ncbi.nlm.nih.gov/pubmed/21561347.
167. Sadot E, Doussot A, O'Reilly EM, et al. FOLFIRINOX induction therapy for stage 3 pancreatic adenocarcinoma. Ann Surg Oncol 2015;22:3512-3521. Available at: https://www.ncbi.nlm.nih.gov/pubmed/26065868.
168. Faris JE, Blaszkowsky LS, McDermott S, et al. FOLFIRINOX in locally advanced pancreatic cancer: the Massachusetts General Hospital Cancer Center experience. Oncologist 2013;18:543-548. Available at: https://www.ncbi.nlm.nih.gov/pubmed/23657686.
169. Suker M, Beumer BR, Sadot E, et al. FOLFIRINOX for locally advanced pancreatic cancer: a systematic review and patient-level meta-analysis. Lancet Oncol 2016;17:801-810. Available at: https://www.ncbi.nlm.nih.gov/pubmed/27160474.
170. Inoue N, Matsumoto G, Sumitomo S, et al. Cancer of unknown primary with presumptive pancreatic cancer treated with FOLFIRINOX. J Med Cases 2021;12:442-445. Available at: https://www.ncbi.nlm.nih.gov/pubmed/34804303.
171. Conroy T, Hammel P, Hebbar M, et al. FOLFIRINOX or gemcitabine as adjuvant therapy for pancreatic cancer. N Engl J Med 2018;379:2395-2406. Available at: https://www.ncbi.nlm.nih.gov/pubmed/30575490.
172. Drugs@FDA: FDA-Approved Drugs. U.S. Food & Drug Administration; Available at: https://www.accessdata.fda.gov/scripts/cder/daf/index.cfm. Accessed August 1, 2023.
173. Le DT, Uram JN, Wang H, et al. PD-1 Blockade in Tumors with Mismatch-Repair Deficiency. New England Journal of Medicine 2015;372:2509-2520. Available at: https://pubmed.ncbi.nlm.nih.gov/26028255/.
174. Le DT, Durham JN, Smith KN, et al. Mismatch repair deficiency predicts response of solid tumors to PD-1 blockade. Science 2017;357:409-413. Available at: https://pubmed.ncbi.nlm.nih.gov/28596308/.
175. Marabelle A, Le DT, Ascierto PA, et al. Efficacy of pembrolizumab in patients with noncolorectal high microsatellite instability/mismatch repair-deficient cancer: results from the phase II KEYNOTE-158 study. J Clin Oncol 2020;38:1-10. Available at: https://www.ncbi.nlm.nih.gov/pubmed/31682550.
176. U.S. Food and Drug Administration. FDA approves pembrolizumab for adults and children with TMB-H solid tumors. 2020. Available at: https://www.fda.gov/drugs/drug-approvals-and-databases/fda-approves-pembrolizumab-adults-and-children-tmb-h-solid-tumors. Accessed January 19, 2021.
177. Marabelle A, Fakih M, Lopez J, et al. Association of tumour mutational burden with outcomes in patients with advanced solid tumours treated with pembrolizumab: prospective biomarker analysis of the multicohort, open-label, phase 2 KEYNOTE-158 study. Lancet Oncol 2020;21:1353-1365. Available at: https://www.ncbi.nlm.nih.gov/pubmed/32919526.

Version 2.2025 © 2024 National Comprehensive Cancer Network© (NCCN©), All rights reserved. NCCN Guidelines® and this illustration may not be reproduced in any form without the express written permission of NCCN.

Printed by Elizabeth Moore on 4/30/2025 10:21:39 AM. For personal use only. Not approved for distribution. Copyright © 2025 National Comprehensive Cancer Network, Inc., All Rights Reserved.

178. U.S. Food and Drug Administration. FDA grants accelerated approval to dostarlimab-gxly for dMMR advanced solid tumors. 2021. Available at: https://www.fda.gov/drugs/resources-information-approved-drugs/fda-grants-accelerated-approval-dostarlimab-gxly-dmmr-advanced-solid-tumors. Accessed August 30, 2021.
179. Oaknin A, Tinker AV, Gilbert L, et al. Clinical activity and safety of the anti–programmed death 1 monoclonal antibody dostarlimab for patients with recurrent or advanced mismatch repair–deficient endometrial cancer: a nonrandomized phase 1 clinical trial. JAMA Oncology 2020;6:1766-1772. Available at: https://doi.org/10.1001/jamaoncol.2020.4515.
180. Berton D, Banerjee SN, Curigliano G, et al. Antitumor activity of dostarlimab in patients with mismatch repair-deficient/microsatellite instability–high tumors: A combined analysis of two cohorts in the GARNET study. J Clin Oncol 2021;39:2564-2564. Available at: https://ascopubs.org/doi/abs/10.1200/JCO.2021.39.15_suppl.2564.
181. U.S. Food and Drug Administration. FDA approves selpercatinib for locally advanced or metastatic RET fusion-positive solid tumors. 2022. Available at: https://www.fda.gov/drugs/resources-information-approved-drugs/fda-approves-selpercatinib-locally-advanced-or-metastatic-ret-fusion-positive-solid-tumors. Accessed November 28, 2022.
182. Subbiah V, Wolf J, Konda B, et al. Tumour-agnostic efficacy and safety of selpercatinib in patients with RET fusion-positive solid tumours other than lung or thyroid tumours (LIBRETTO-001): a phase 1/2, open-label, basket trial. Lancet Oncol 2022;23:1261-1273. Available at: https://www.ncbi.nlm.nih.gov/pubmed/36108661.
183. Administration USFD. FDA grants accelerated approval to dabrafenib in combination with trametinib for unresectable or metastatic solid tumors with BRAF V600E mutation. 2022. Available at: https://www.fda.gov/drugs/resources-information-approved-drugs/fda-grants-accelerated-approval-dabrafenib-combination-trametinib-unresectable-or-metastatic-solid.
184. Salama AKS, Li S, Macrae ER, et al. Dabrafenib and trametinib in patients with tumors with BRAF(V600E) mutations: Results of the NCI-MATCH trial subprotocol H. J Clin Oncol 2020;38:3895-3904. Available at: https://www.ncbi.nlm.nih.gov/pubmed/32758030.
185. Solomon BJ, Drilon A, Lin JJ, et al. 1372P Repotrectinib in patients (pts) with NTRK fusion-positive (NTRK+) advanced solid tumors, including NSCLC: Update from the phase I/II TRIDENT-1 trial [abstract]. Annals of Oncology 2023;34:Abstract S787-S788. Available at: https://doi.org/10.1016/j.annonc.2023.09.2405.
186. Administration FD. DA grants accelerated approval to fam-trastuzumab deruxtecan-nxki for unresectable or metastatic HER2-positive solid tumors. 2024. Available at: https://www.fda.gov/drugs/resources-information-approved-drugs/fda-grants-accelerated-approval-fam-trastuzumab-deruxtecan-nxki-unresectable-or-metastatic-her2.
187. Meric-Bernstam F, Makker V, Oaknin A, et al. Efficacy and safety of trastuzumab deruxtecan in patients with HER2-expressing solid tumors: Primary results from the DESTINY-PanTumor02 phase II trial. J Clin Oncol 2024;42:47-58. Available at: https://www.ncbi.nlm.nih.gov/pubmed/37870536.
188. Jeremic B, Zivic DJ, Matovic M, Marinkovic J. Cisplatin and 5-fluorouracil as induction chemotherapy followed by radiation therapy in metastatic squamous cell carcinoma of an unknown primary tumor localized to the neck. A phase II study. J Chemother 1993;5:262-265. Available at: http://www.ncbi.nlm.nih.gov/pubmed/8229155.
189. Khansur T, Allred C, Little D, Anand V. Cisplatin and 5-fluorouracil for metastatic squamous cell carcinoma from unknown primary. Cancer Invest 1995;13:263-266. Available at: http://www.ncbi.nlm.nih.gov/pubmed/7743377.
190. Al-Batran SE, Hartmann JT, Probst S, et al. Phase III trial in metastatic gastroesophageal adenocarcinoma with fluorouracil, leucovorin plus either oxaliplatin or cisplatin: a study of the Arbeitsgemeinschaft Internistische Onkologie. J Clin Oncol 2008;26:1435-1442. Available at: http://www.ncbi.nlm.nih.gov/pubmed/18349393.
191. Conroy T, Yataghene Y, Etienne PL, et al. Phase II randomised trial of chemoradiotherapy with FOLFOX4 or cisplatin plus fluorouracil in oesophageal cancer. Br J Cancer 2010;103:1349-1355. Available at: http://www.ncbi.nlm.nih.gov/pubmed/20940718.
192. Bonomi P, Kim K, Fairclough D, et al. Comparison of survival and quality of life in advanced non-small-cell lung cancer patients treated with two dose levels of paclitaxel combined with cisplatin versus etoposide with cisplatin: results of an Eastern Cooperative Oncology

Version 2.2025 © 2024 National Comprehensive Cancer Network© (NCCN©), All rights reserved. NCCN Guidelines® and this illustration may not be reproduced in any form without the express written permission of NCCN.

Printed by Elizabeth Moore on 4/30/2025 10:21:39 AM. For personal use only. Not approved for distribution. Copyright © 2025 National Comprehensive Cancer Network, Inc., All Rights Reserved.

Group trial. J Clin Oncol 2000;18:623-631. Available at: http://www.ncbi.nlm.nih.gov/pubmed/10653877.
193. Garden AS, Harris J, Vokes EE, et al. Preliminary results of Radiation Therapy Oncology Group 97-03: a randomized phase II trial of concurrent radiation and chemotherapy for advanced squamous cell carcinomas of the head and neck. J Clin Oncol 2004;22:2856-2864. Available at: http://www.ncbi.nlm.nih.gov/pubmed/15254053.
194. Gibson MK, Li Y, Murphy B, et al. Randomized phase III evaluation of cisplatin plus fluorouracil versus cisplatin plus paclitaxel in advanced head and neck cancer (E1395): an Intergroup trial of the Eastern Cooperative Oncology Group. J Clin Oncol 2005;23:3562-3567. Available at: http://www.ncbi.nlm.nih.gov/pubmed/15908667.
195. Ilson DH, Forastiere A, Arquette M, et al. A phase II trial of paclitaxel and cisplatin in patients with advanced carcinoma of the esophagus. Cancer J 2000;6:316-323. Available at: http://www.ncbi.nlm.nih.gov/pubmed/11079171.
196. Park YH, Ryoo BY, Choi SJ, et al. A phase II study of paclitaxel plus cisplatin chemotherapy in an unfavourable group of patients with cancer of unknown primary site. Jpn J Clin Oncol 2004;34:681-685. Available at: http://www.ncbi.nlm.nih.gov/pubmed/15613558.
197. Mukai H, Katsumata N, Ando M, Watanabe T. Safety and efficacy of a combination of docetaxel and cisplatin in patients with unknown primary cancer. Am J Clin Oncol 2010;33:32-35. Available at: http://www.ncbi.nlm.nih.gov/pubmed/19786850.
198. Faivre C, Rougier P, Ducreux M, et al. 5-fluorouracile and cisplatinum combination chemotherapy for metastatic squamous-cell anal cancer. Bull Cancer 1999;86:861-865. Available at: http://www.ncbi.nlm.nih.gov/pubmed/10572237.
199. Lorenzen S, Schuster T, Porschen R, et al. Cetuximab plus cisplatin-5-fluorouracil versus cisplatin-5-fluorouracil alone in first-line metastatic squamous cell carcinoma of the esophagus: a randomized phase II study of the Arbeitsgemeinschaft Internistische Onkologie. Ann Oncol 2009;20:1667-1673. Available at: http://www.ncbi.nlm.nih.gov/pubmed/19549707.
200. Vermorken JB, Mesia R, Rivera F, et al. Platinum-based chemotherapy plus cetuximab in head and neck cancer. N Engl J Med 2008;359:1116-1127. Available at: http://www.ncbi.nlm.nih.gov/pubmed/18784101.
201. Bedenne L, Michel P, Bouche O, et al. Chemoradiation followed by surgery compared with chemoradiation alone in squamous cancer of the esophagus: FFCD 9102. J Clin Oncol 2007;25:1160-1168. Available at: http://www.ncbi.nlm.nih.gov/pubmed/17401004.
202. Tepper J, Krasna MJ, Niedzwiecki D, et al. Phase III trial of trimodality therapy with cisplatin, fluorouracil, radiotherapy, and surgery compared with surgery alone for esophageal cancer: CALGB 9781. J Clin Oncol 2008;26:1086-1092. Available at: https://www.ncbi.nlm.nih.gov/pubmed/18309943.
203. Kusaba H, Shibata Y, Arita S, et al. Infusional 5-fluorouracil and cisplatin as first-line chemotherapy in patients with carcinoma of unknown primary site. Med Oncol 2007;24:259-264. Available at: http://www.ncbi.nlm.nih.gov/pubmed/17848753.
204. Pointreau Y, Garaud P, Chapet S, et al. Randomized trial of induction chemotherapy with cisplatin and 5-fluorouracil with or without docetaxel for larynx preservation. J Natl Cancer Inst 2009;101:498-506. Available at: http://www.ncbi.nlm.nih.gov/pubmed/19318632.
205. Posner MR, Hershock DM, Blajman CR, et al. Cisplatin and fluorouracil alone or with docetaxel in head and neck cancer. N Engl J Med 2007;357:1705-1715. Available at: http://www.ncbi.nlm.nih.gov/pubmed/17960013.
206. Van Cutsem E, Moiseyenko VM, Tjulandin S, et al. Phase III study of docetaxel and cisplatin plus fluorouracil compared with cisplatin and fluorouracil as first-line therapy for advanced gastric cancer: a report of the V325 Study Group. J Clin Oncol 2006;24:4991-4997. Available at: http://www.ncbi.nlm.nih.gov/pubmed/17075117.
207. Vermorken JB, Remenar E, van Herpen C, et al. Cisplatin, fluorouracil, and docetaxel in unresectable head and neck cancer. N Engl J Med 2007;357:1695-1704. Available at: http://www.ncbi.nlm.nih.gov/pubmed/17960012.
208. Spigel DR, Hainsworth JD, Greco FA. Neuroendocrine carcinoma of unknown primary site. Semin Oncol 2009;36:52-59. Available at: http://www.ncbi.nlm.nih.gov/pubmed/19179188.
209. Juhlin CC, Zedenius J, Hoog A. Metastatic neuroendocrine neoplasms of unknown primary: Clues from pathology workup. Cancers (Basel) 2022;14. Available at: https://www.ncbi.nlm.nih.gov/pubmed/35565339.

Version 2.2025 © 2024 National Comprehensive Cancer Network© (NCCN©), All rights reserved. NCCN Guidelines® and this illustration may not be reproduced in any form without the express written permission of NCCN.

Printed by Elizabeth Moore on 4/30/2025 10:21:39 AM. For personal use only. Not approved for distribution. Copyright © 2025 National Comprehensive Cancer Network, Inc., All Rights Reserved.

210. Hainsworth JD, Spigel DR, Litchy S, Greco FA. Phase II trial of paclitaxel, carboplatin, and etoposide in advanced poorly differentiated neuroendocrine carcinoma: a Minnie Pearl Cancer Research Network Study. J Clin Oncol 2006;24:3548-3554. Available at: http://www.ncbi.nlm.nih.gov/pubmed/16877720.
211. Fjällskog M-LH, Granberg DPK, Welin SLV, et al. Treatment with cisplatin and etoposide in patients with neuroendocrine tumors. Cancer 2001;92:1101-1107. Available at: http://www.ncbi.nlm.nih.gov/pubmed/11571721.
212. Ekeblad S, Sundin A, Janson ET, et al. Temozolomide as monotherapy is effective in treatment of advanced malignant neuroendocrine tumors. Clin Cancer Res 2007;13:2986-2991. Available at: http://www.ncbi.nlm.nih.gov/pubmed/17505000.
213. Kulke MH, Stuart K, Enzinger PC, et al. Phase II study of temozolomide and thalidomide in patients with metastatic neuroendocrine tumors. J Clin Oncol 2006;24:401-406. Available at: http://www.ncbi.nlm.nih.gov/pubmed/16421420.
214. Okamoto H, Watanabe K, Kunikane H, et al. Randomised phase III trial of carboplatin plus etoposide vs split doses of cisplatin plus etoposide in elderly or poor-risk patients with extensive disease small-cell lung cancer: JCOG 9702. Br J Cancer 2007;97:162-169. Available at: http://www.ncbi.nlm.nih.gov/pubmed/17579629.
215. Reynolds J, Chamberland-Tremblay A, Herrington JD, et al. High-versus low-dose leucovorin in the modified FOLFOX6 regimen for first-line treatment of metastatic colorectal cancer. J Oncol Pharm Pract 2017;23:173-178. Available at: https://www.ncbi.nlm.nih.gov/pubmed/26786027.
216. Clarke S, Goldstein D, Mitchell P, et al. Modification of leucovorin dose within a simplified FOLFOX regimen improves tolerability without compromising efficacy. Clin Colorectal Cancer 2007;6:578-582. Available at: https://www.ncbi.nlm.nih.gov/pubmed/17681104.
217. Comparison of flourouracil with additional levamisole, higher-dose folinic acid, or both, as adjuvant chemotherapy for colorectal cancer: a randomised trial. QUASAR Collaborative Group. Lancet 2000;355:1588-1596. Available at: http://www.ncbi.nlm.nih.gov/pubmed/10821362.
218. Gomez DR, Blumenschein GR, Jr., Lee JJ, et al. Local consolidative therapy versus maintenance therapy or observation for patients with oligometastatic non-small-cell lung cancer without progression after first-line systemic therapy: a multicentre, randomised, controlled, phase 2 study. Lancet Oncol 2016;17:1672-1682. Available at: https://www.ncbi.nlm.nih.gov/pubmed/27789196.
219. Palma DA, Olson R, Harrow S, et al. Stereotactic ablative radiotherapy versus standard of care palliative treatment in patients with oligometastatic cancers (SABR-COMET): a randomised, phase 2, open-label trial. Lancet 2019;393:2051-2058. Available at: https://www.ncbi.nlm.nih.gov/pubmed/30982687.
220. Janssen S, Glanzmann C, Huber G, Studer G. Individualized IMRT treatment approach for cervical lymph node metastases of unknown primary. Strahlenther Onkol 2014;190:386-393. Available at: http://www.ncbi.nlm.nih.gov/pubmed/24638240.
221. Kamal M, Mohamed ASR, Fuller CD, et al. Outcomes of patients diagnosed with carcinoma metastatic to the neck from an unknown primary source and treated with intensity-modulated radiation therapy. Cancer 2018;124:1415-1427. Available at: https://www.ncbi.nlm.nih.gov/pubmed/29338089.
222. Mourad WF, Hu KS, Shasha D, et al. Initial experience with oropharynx-targeted radiation therapy for metastatic squamous cell carcinoma of unknown primary of the head and neck. Anticancer Res 2014;34:243-248. Available at: http://www.ncbi.nlm.nih.gov/pubmed/24403470.

Version 2.2025 © 2024 National Comprehensive Cancer Network© (NCCN©), All rights reserved. NCCN Guidelines® and this illustration may not be reproduced in any form without the express written permission of NCCN.