Cryodestruction of Vidian Nerve Branches

M. M. L. ARORA, F. A. KHAN, Y. N. MEHRA

Cryodestruction of the nasal branches of the Vidian nerve in the region of the sphenopalatine foramen has been done in cases of vasomotor rhinitis. The technique is described. The results show 87.1% of the patients have been completely relieved of their symptoms during a follow up period of 2 to 6 months. This simple office procedure is without any complication and is recommended as the treatment of choice in vasomotor rhinitis.

The incidence of vasomotor rhinitis is directly proportional to the tensions, conflicts, frustrations and anxieties of modern day life. Golding Wood (1973) postulates that the hypothalmus responds to a variety of stimuli including the emotional, endocrinal and reflex. The stimulation results in parasympathetic discharge via the superior salivary nucleus, nervus intermedius, greater superficial petrosal nerve, vidian nerve, sphenopalatine ganglion and then to the nasal mucosa. The parasympathetic response is isolated and discrete and is practically confined to the nose (Fig. 1).

Various modalities of treatment for vasomotor rhinitis have been tried. These have been oral decongestants, cautery of the turbinates with silver nitrate or phenol, submucosal electro-cautery, submucosal repository steroids and surgical resections. None of these are based on any scientific principle. The relief obtained in most of the cases is at the most temporary, and a multitude of iatrogenic atrophic rhinitis cases have appeared as a result of such treatment.

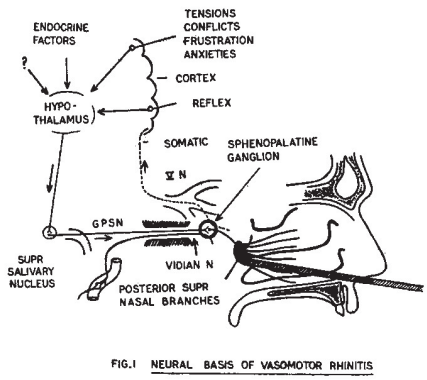

Fig. 1. Neural basis of Vasomotor Rhinitis

Golding Wood (1961, 1962, 1970, 1973) was the pioneer in treating this condition on a scientific basis. He interrupted the effector pathways by sectioning the petrosal nerve in the first seven cases and the vidian nerve via the transantral route in a few hundred patients. He has followed up his cases for 5-15 years and 94% of the pure vasomotor rhinitis cases (Cholinergic cases) obtained complete relief. Following Golding-Wood's technique various other approaches to the vidian nerve have been described. While reviewing these approaches, especially the trans-septal by Minnis and Morrison (1971), transantral subperiosteal by Nomura (1974) and transnasal by Patel and Gaikwad (1975), one wondered whether these blind approaches actually reached the vidian canal or one is only lifting up the vidian nasal branches leading to their destruction. Malcolmson (1957) obtained some success in few cases of chronic vasomotor rhinitis by lifting up the nasal mucosa over the upper part of the *medial pterygoid plate.* The vidian branches in the region of the sphenopalatine foramen were avulsed with the elevation. He, however, did not report his results and the above information is quoted by Golding-Wood (1961) in a personal communication to him.

Ozenberger (1973) obtained symptomatic relief to the nasal obstruction lasting for three to four years, by the application of a straight cryoprobe to the turbinates. He also reported the application of a hooked probe to the sphenopalatine area in a few cases for the complaints of sneezing and rhinorrhoea. He postulated that the autonomic nerve supply to the secreting tissue can be destroyed at least temporarily by this procedure. The relief of symptoms, especially sneezing, was almost immediate and he cautioned his patients that the simple procedure may have to be repeated at intervals of several months.

Since this report of Ozenberger (1973) there has been no report in the literature on the followup of these patients either by him or by any other worker. The presumption of Ozenberger that the autonomic nerves regenerate fast is not borne out by the long term follow-up by Golding-Wood (1973) in which the patients have been symptom free for upto 15 years.

We planned to destroy the vidian nasal branches with the application of a hooked cryoprobe to the sphenopalatine area, however, keeping in view Malcolmson's (1957) observation and our assumption that in blind approaches to the vidian canal one is only lifting up and destroying the vidian nasal branches, we limited the

M.M.L. Arora., Associate Professor of E.N.T.
Farooq. A. Khan., Resident, E.N.T.
Y. N. Mehra., Professor & Head, Department of Otolaryngology, Postgraduate Institute of Medical Education and Research, Chandigarh.

NEURENT 1054

cryodestruction to the sphenopalatine area and did not include the turbinate in the mass destruction as practised by Ozenberger (1973).

Material and Methods

Fortyeight patients of vasomotor rhinitis in the age groups between 18 and 55 years of both sexes (males 28 and females 20) were

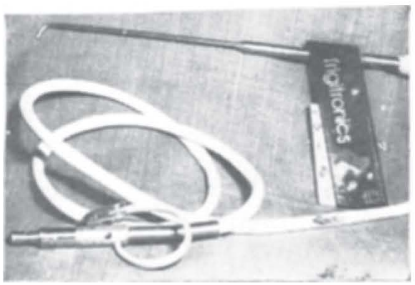

Fig. 2. Showing the Cryosurgical Unlt

selected solely on the basis of a meticulously taken history. The skin testing for allergens was not done and so there is a possibility that some of our cases are of a mixed variety i.e. cholinergic and atopic. A complete otolaryngological examination including an X-ray of the paranasal sinuses was done to rule out sinus infection. Local surface anaesthesia was given by anaesthetising the sphenopalatine and anterior ethmoidal areas with 4% xylocaine with 1 : 25000 dilution adrenaline solution. The hooked nasal probe (Fig. 2) of the cryosurgical unit (Frigitronic CT-73) was passed along the floor of the nasal cavity like a eustachian catheter. The posterior end of the nasal septum was felt by rotating the probe medially and then at that level it is rotated by 180 degrees. By this manoeuvre the hook of the probe comes to hug the posterior end of the middle turbinate and the marker on the probe is near the nasal columella (Fig. 3). The probe is cooled rapidly by turning the Nitrous oxide gas on. The probe temperature drops to—80 degree centigrade. It is maintained for two minutes and then gradually withdrawn. The procedure is repeated on the opposite side. Gross deviation of the nasal septum sometimes interferes with the bilateral application of the probe in the precise area. When the probe is in the area of sphenopalatine foramen and the machine is turned on, the patient experiences a referred pain in the area supplied by the second division of the trigeminal nerve.

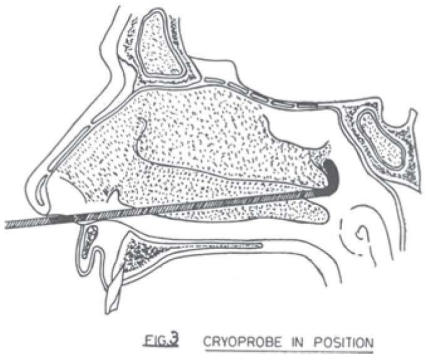

Fig. 3. Cryoprobe in position

The area destroyed by the hooked probe is crescent shaped and measures about 6 mm X 15 mm. The rest of the nasal cavity is not affected because the probe is insulated. The patient is given a course of antibiotics for five days as a prophylactic measure. The patients have been followed up for 2 to 6 months so far. Out of 48 cases, eleven have been lost to follow up and Table No. I & II show the results of the remaining 37 cases.

Results

There is immediate relief in sneezing and rhinorrhoea following the treatment. There is separation of slough on the 4th to 5th day and the nasal airway starts to improve. The relief in nasal obstruction takes about three weeks to reach the optimum. Objective examination of the nasal cavity at this stage shows that the airway is definitely increased especially in the olfactory cleft area. Instead of the normal 1 mm it is about 2-3 mm in size. In unilateral application there was no appreciable difference in the sensory innervation of the nose and the lacrimation between the treated and the untreated sides. There has been no complication in any of our patients.

Discussion

The longest follow up of our cases is 6 months. However, this period is too short to comment whether our results are going to be permanent or whether there is going to be regeneration of the automomic nerve fibres. Since the sensory innervation of the nose is not appreciably affected, we postulate that the smaller size non-myelinated postganglionic autonomic fibres are destroyed whereas the larger somatic fibres are not affected by the temperature reached with the nitrous oxide probe.The des-

TABLE I

Shows the incidence of dominant symptoms and cryoapplication.

	Dominant symptom		Cryoapplication	
	Sneezing &	Obstruction	Bilateral	Unilateral
Cases 37	25	12	31	6

TABLE II

Shows the results with 2-4 months follow up.

Cases	Cryoapplication	Completely relieved	Partially relieved	Unaffected
31	Bilateral	27(87.1%)	4(12.9%)	—
6	Unilateral	—	4	2

truction of autonomic fibres whether by diathermic coagulation or cryodestruction should make no difference in their power of regeneration. Golding-Wood (1973) in his vidian neurectomy series has achieved 94 percent success rate with a follow up of 5-15 years, thus indicating that the destruction is permanent and there is no regeneration if the nerve is coagulated for a few mm in the vidian canal. With the hooked probe there is destruction of at least 6 mm of the length of the posterior superior nasal branches and we hope there will be no regeneration.

Assuming that there will be regeneration and return of the symptoms we would still prefer this simple office modality with no complications, rather than the vidian neurectomy in which occasional complications like ophthalmoplegias are worse than the original disease. Moreover, the treatment can be repeated any number of times whereas the the vidian neurectomy is a one time procedure and cannot be repeated because of scar tissue formation and loss of all land marks. Another point in favour of this procedure is that it is a simple office treatment whereas the vidian neurectomy is a highly technical procedure and requires impeccable technique as emphasized by Golding-Wood (1973). Lastly, the preservation of normal lacrimal secretion is an advantage.

References :

1. Golding-Wood P. H. (1961), Observations on Petrosal And Vidian Neurectomy in Chronic Vasomotor Rhinitis. *Journal of Larynogology & Otology*. **75** : 232-247
2. Golding-Wood, P. H. (1962), Pathology and Surgery of Chronic Vasomotor Rhinitis. *Journal of Laryngology & Otology*. **76** : 969-977.
3. Golding-Wood, P. H. (1970), Vidian Neurectomy and other Transantral Surgery. *The Laryngoscope*, **80** : 1179-89.
4. Golding-Wood P. H. (1973), Vidian Neurectomy, Its Results And Complications. *The Laryngoscope*. **83** : 1173-1183.
5. Malcolmson (1957) Quoted by Golding Wood 1961.
6. Minnis, N. L. and Morrison, A. W. (1971), Transeptal approach for. Vidian Neurectomy. *Journal of Laryngology & Otology*. **85** : 255-260.
7. Nomura, Y. (1974) Vidian Neurectomy, Some Technical Remarks. *The Laryngoscope*, **84** : 578-585.
8. Ozenberger, J. M. (1973), Cryosurgery for the Treatment of Chronic Rhinitis. *The Laryngoscope*. **83** : 508-516.
9. Patel, K. H. andGaikwad G. A.(1975) Bilateral Transnasal Cauterization of Vidian Nerve in Vasomotor Rhinitis. *Journal of Laryngology. & Otology* **89** : 1291-96.