Sinusitis

From Microbiology to Management

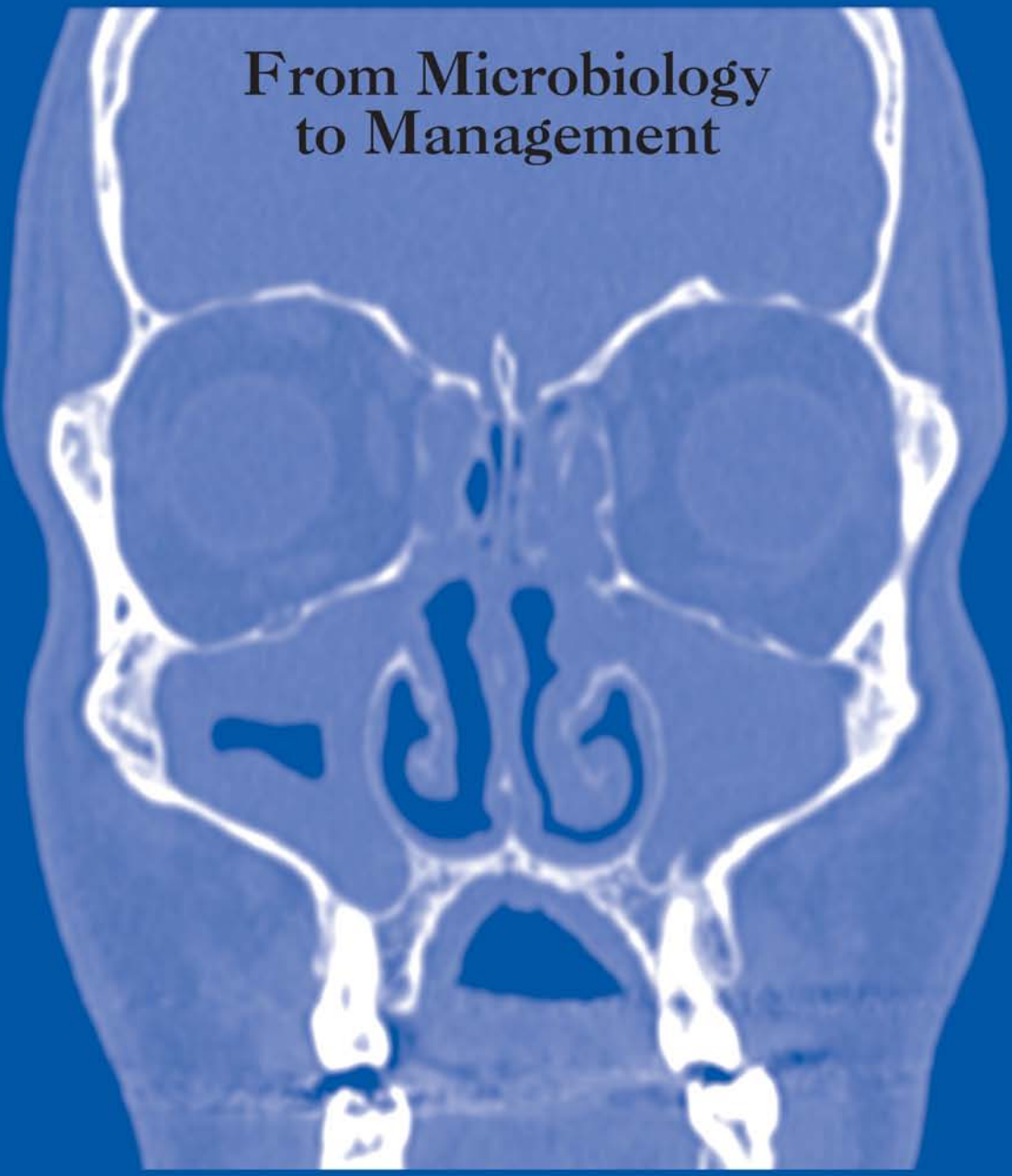

edited by

Itzhak Brook

The Foundry, LLC Exhibit 2001, Page 1 of 58
Neurent Medical Inc. & Neurent Medical Ltd. v. The Foundry, LLC
IPR2024-00669

Sinusitis

From Microbiology to Management

The Foundry, LLC Exhibit 2001, Page 2 of 58
Neurent Medical Inc. & Neurent Medical Ltd. v. The Foundry, LLC
IPR2024-00669

INFECTIOUS DISEASE AND THERAPY

Series Editor

Burke A. Cunha

Winthrop-University Hospital
Mineola, and
State University of New York School of Medicine
Stony Brook, New York

1. Parasitic Infections in the Compromised Host, *edited by Peter D. Walzer and Robert M. Genta*
2. Nucleic Acid and Monoclonal Antibody Probes: Applications in Diagnostic Methodology, *edited by Bala Swaminathan and Gyan Prakash*
3. Opportunistic Infections in Patients with the Acquired Immunodeficiency Syndrome, *edited by Gifford Leoung and John Mills*
4. Acyclovir Therapy for Herpesvirus Infections, *edited by David A. Baker*
5. The New Generation of Quinolones, *edited by Clifford Siporin, Carl L. Heifetz, and John M. Domagala*
6. Methicillin-Resistant *Staphylococcus aureus*: Clinical Management and Laboratory Aspects, *edited by Mary T. Cafferkey*
7. Hepatitis B Vaccines in Clinical Practice, *edited by Ronald W. Ellis*
8. The New Macrolides, Azalides, and Streptogramins: Pharmacology and Clinical Applications, *edited by Harold C. Neu, Lowell S. Young, and Stephen H. Zinner*
9. Antimicrobial Therapy in the Elderly Patient, *edited by Thomas T. Yoshikawa and Dean C. Norman*
10. Viral Infections of the Gastrointestinal Tract: Second Edition, Revised and Expanded, *edited by Albert Z. Kapikian*
11. Development and Clinical Uses of *Haemophilus b* Conjugate Vaccines, *edited by Ronald W. Ellis and Dan M. Granoff*
12. *Pseudomonas aeruginosa* Infections and Treatment, *edited by Aldona L. Baltch and Raymond P. Smith*

13. Herpesvirus Infections, *edited by Ronald Glaser and James F. Jones*
14. Chronic Fatigue Syndrome, *edited by Stephen E. Straus*
15. Immunotherapy of Infections, *edited by K. Noel Masihi*
16. Diagnosis and Management of Bone Infections, *edited by Luis E. Jauregui*
17. Drug Transport in Antimicrobial and Anticancer Chemotherapy, *edited by Nafsika H. Georgopapadakou*
18. New Macrolides, Azalides, and Streptogramins in Clinical Practice, *edited by Harold C. Neu, Lowell S. Young, Stephen H. Zinner, and Jacques F. Acar*
19. Novel Therapeutic Strategies in the Treatment of Sepsis, *edited by David C. Morrison and John L. Ryan*
20. Catheter-Related Infections, *edited by Harald Seifert, Bernd Jansen, and Barry M. Farr*
21. Expanding Indications for the New Macrolides, Azalides, and Streptogramins, *edited by Stephen H. Zinner, Lowell S. Young, Jacques F. Acar, and Harold C. Neu*
22. Infectious Diseases in Critical Care Medicine, *edited by Burke A. Cunha*
23. New Considerations for Macrolides, Azalides, Streptogramins, and Ketolides, *edited by Stephen H. Zinner, Lowell S. Young, Jacques F. Acar, and Carmen Ortiz-Neu*
24. Tickborne Infectious Diseases: Diagnosis and Management, *edited by Burke A. Cunha*
25. Protease Inhibitors in AIDS Therapy, *edited by Richard C. Ogden and Charles W. Flexner*
26. Laboratory Diagnosis of Bacterial Infections, *edited by Nevio Cimolai*
27. Chemokine Receptors and AIDS, *edited by Thomas R. O'Brien*
28. Antimicrobial Pharmacodynamics in Theory and Clinical Practice, *edited by Charles H. Nightingale, Takeo Murakawa, and Paul G. Ambrose*
29. Pediatric Anaerobic Infections: Diagnosis and Management, Third Edition, Revised and Expanded, *Itzhak Brook*

30. Viral Infections and Treatment, *edited by Helga Ruebsamen-Waigmann, Karl Deres, Guy Hewlett, and Reinhold Welker*
31. Community-Aquired Respiratory Infections, *edited by Charles H. Nightingale, Paul G. Ambrose, and Thomas M. File*
32. Catheter-Related Infections: Second Edition, *Harald Seifert, Bernd Jansen and Barry Farr*
33. Antibiotic Optimization: Concepts and Strategies in Clinical Practice (PBK), *edited by Robert C. Owens, Jr., Charles H. Nightingale and Paul G. Ambrose*
34. Fungal Infections in the Immunocompromised Patient, *edited by John R. Wingard and Elias J. Anaissie*
35. Sinusitis: From Microbiology to Management, *edited by Itzhak Brook*
36. Herpes Simplex Viruses, *edited by Marie Studahl, Paola Cinque and Tomas Bergström*
37. Antiviral Agents, Vaccines, and Immunotherapies, *Stephen K. Tyring*

Sinusitis

From Microbiology to Management

edited by

Itzhak Brook

Georgetown University School of Medicine
Washington, D.C., U.S.A.

Taylor & Francis
Taylor & Francis Group
New York London

The Foundry, LLC Exhibit 2001, Page 6 of 58
Neurent Medical Inc. & Neurent Medical Ltd. v. The Foundry, LLC
IPR2024-00669

Published in 2006 by
Taylor & Francis Group
270 Madison Avenue
New York, NY 10016

© 2006 by Taylor & Francis Group, LLC

No claim to original U.S. Government works
Printed in the United States of America on acid-free paper
10 9 8 7 6 5 4 3 2 1

International Standard Book Number-10: 0-8247-2948-X (Hardcover)
International Standard Book Number-13: 978-0-8247-2948-6 (Hardcover)

This book contains information obtained from authentic and highly regarded sources. Reprinted material is quoted with permission, and sources are indicated. A wide variety of references are listed. Reasonable efforts have been made to publish reliable data and information, but the author and the publisher cannot assume responsibility for the validity of all materials or for the consequences of their use.

No part of this book may be reprinted, reproduced, transmitted, or utilized in any form by any electronic, mechanical, or other means, now known or hereafter invented, including photocopying, microfilming, and recording, or in any information storage or retrieval system, without written permission from the publishers.

For permission to photocopy or use material electronically from this work, please access www.copyright.com (http://www.copyright.com/) or contact the Copyright Clearance Center, Inc. (CCC) 222 Rosewood Drive, Danvers, MA 01923, 978-750-8400. CCC is a not-for-profit organization that provides licenses and registration for a variety of users. For organizations that have been granted a photocopy license by the CCC, a separate system of payment has been arranged.

Trademark Notice: Product or corporate names may be trademarks or registered trademarks, and are used only for identification and explanation without intent to infringe.

Library of Congress Cataloging-in-Publication Data

Catalog record is available from the Library of Congress

T&F informa

Taylor & Francis Group
is the Academic Division of T&F Informa plc.

Visit the Taylor & Francis Web site at
http://www.taylorandfrancis.com

This book is dedicated to my wife, Joyce, and my children,
Dafna, Tamar, Yoni, and Sara

Preface

Upper respiratory tract infections and, especially, sinusitis are frequently encountered in the day-to-day practice of infectious disease specialists, allergists, pediatricians, otolaryngologists, internists, and family practitioners. The range of causative agents and available therapies and the constantly changing spectrum of antibiotic resistance can make it difficult to select the most appropriate course of treatment. Given the increasing global concerns regarding the scale of worldwide bacterial resistance, which is largely because of the misuse and overuse of antibiotics, information that can enable physicians to optimize management of infections such as sinusitis will be of great value.

This book provides state-of-the-art information on management of sinusitis tailored to the clinicians and health care providers of varied specialties. It contains a liberal number of figures and tables that clarify the underlying concepts and illustrate specific details. The authors selected to contribute to the book are the world experts and leaders in the topic(s) they address.

The book opens with a comprehensive overview of the epidemiology, clinical presentation, and diagnostic techniques of sinusitis. It then delves into the pathophysiology and the microbiology underlying the condition. The next section of the book addresses the medical management of acute and chronic sinusitis as well as the comorbid medical symptoms. We then conclude with the surgical management of these conditions and their complications. It is our hope that this book will be a useful tool and an important resource for clinicians in the management of sinusitis.

Itzhak Brook, M.D., M.Sc.

The Foundry, LLC Exhibit 2001, Page 10 of 58
Neurent Medical Inc. & Neurent Medical Ltd. v. The Foundry, LLC
IPR2024-00669

Contents

Preface . . . . *v*
Contributors . . . . *xv*

SECTION I. EPIDEMIOLOGY, PRESENTATION AND DIAGNOSIS

1. Sinusitis: Epidemiology *1*
Thomas M. File Jr.
Introduction 1
Prevalence and Burden of Disease 2
Epidemiology and Risk Factors 5
Pathogens of Bacterial Sinusitis 10
Sinusitis and HIV 11
Nosocomial Sinusitis 12
References 13

2. Classification of Rhinosinusitis *15*
Peter A. R. Clement
Introduction 15
Classifications of Sinusitis 17
The Classification of Fungal Sinusitis 28
The Classification of Pediatric Rhinosinusitis 32
References 34

The Foundry, LLC Exhibit 2001, Page 12 of 58
Neurent Medical Inc. & Neurent Medical Ltd. v. The Foundry, LLC
IPR2024-00669

3. Rhinosinusitis: Clinical Presentation and Diagnosis *39*
Michael S. Benninger and Joshua Gottschall
Introduction 39
Definitions 40
Pathophysiology 41
Rhinosinusitis or Upper Respiratory Tract Infection? 42
Diagnosis of Rhinosinusitis 43
Conclusion 52
References 52

4. Imaging Sinusitis *55*
Nafi Aygun, Ovsev Uzunes, and S. James Zinreich
Introduction 55
Available Imaging Modalities 55
Anatomy 60
Imaging Rhinosinusitis 71
Presurgical Imaging Evaluation 84
Postsurgical Imaging Evaluation 87
Surgical Complications 87
Computer-Aided Surgery 89
References 89

SECTION II. ANATOMY AND PATHOPHYSIOLOGY

5. Anatomy and Physiology of the Paranasal Sinuses *95*
John H. Krouse and Robert J. Stachler
Introduction 95
Embryology of the Nose and Paranasal Sinuses 96
Anatomy of the Nose and Paranasal Sinuses 100
Physiology of the Nose and Paranasal Sinuses 106
Conclusion 108
References 108

6. Pathophysiology of Sinusitis *109*
Alexis H. Jackman and David W. Kennedy
Introduction 109
Definitions of Rhinosinusitis 113
Acute Rhinosinusitis 113
Chronic Rhinosinusitis 116
Etiologies of Chronic Rhinosinusitis 117

The Foundry, LLC Exhibit 2001, Page 13 of 58
Neurent Medical Inc. & Neurent Medical Ltd. v. The Foundry, LLC
IPR2024-00669

Summary 128
References 129

SECTION III. MICROBIOLOGY

7. Infective Basis of Acute and Recurrent Acute Sinusitis . . . ***135***
Ellen R. Wald
Introduction 135
Obtaining Specimens 135
Microbiology of Acute Sinusitis in Children 137
Microbiology of Acute Community-Acquired Sinusitis in Adults 138
Conclusion 141
References 142

8. Infectious Causes of Sinusitis ***145***
Itzhak Brook
Introduction 145
The Oral Cavity Normal Flora 145
Interfering Flora 151
Nasal Flora 152
Normal Sinus Flora 153
Microbiology of Sinusitis 154
The Role of Fungi in Sinusitis 167
Conclusion 169
References 169

SECTION IV. THERAPEUTIC OPTIONS

9. Antimicrobial Management of Sinusitis ***179***
Itzhak Brook
Introduction 179
Antimicrobial Resistance 179
Beta-Lactamase Production 180
Antimicrobial Agents 186
Principles of Therapy 193
Conclusions 198
References 198

The Foundry, LLC Exhibit 2001, Page 14 of 58
Neurent Medical Inc. & Neurent Medical Ltd. v. The Foundry, LLC
IPR2024-00669

10. Medical Management of Acute Sinusitis 203
Dennis A. Conrad
Introduction 203
Rationale for the Recommended Management of Acute Bacterial Sinusitis 204
Current Recommendations for the Management of Acute Bacterial Sinusitis 211
References 216

11. Medical Management of Chronic Rhinosinusitis 219
Alexander G. Chiu and Daniel G. Becker
Definition of CRS 220
Inciting Factors in Sinusitis 220
Antimicrobial Therapy 220
Antimicrobial Agents 221
Anti-inflammatory Agents 222
Adjunctive Therapy 223
Maximal Medical Therapy for CRS 224
Infections Following Functional Endoscopic Sinus Surgery 225
Nebulized Medications 226
Topical Antibiotic Irrigations 227
Intravenous Antibiotics 227
Aspirin Desensitization 229
Conclusion 229
References 229

12. Surgical Management 233
David Lewis and Nicolas Y. Busaba
Introduction 233
Diagnostic Work-Up 234
Indications for Paranasal Sinus Surgery 236
Contraindications for Paranasal Sinus Surgery 238
Endoscopic (Endonasal) Sinus Surgery 238
Complications of Endoscopic Sinus Surgery 245
Image Guidance Systems 247
Microdebriders and Sinus Surgery 248
Types of Paranasal Sinus Surgery 249
Antibiotic Coverage in Paranasal Sinus Surgery: Prophylactic and Post Surgery 264

The Foundry, LLC Exhibit 2001, Page 15 of 58
Neurent Medical Inc. & Neurent Medical Ltd. v. The Foundry, LLC
IPR2024-00669

Lasers and Sinus Surgery 265
Conclusion 265
References 266

13. Complications of Acute and Chronic Sinusitis and Their Management *269*
Gary Schwartz and Steve White
Introduction 269
Pathophysiology 270
Local Complications 270
Orbital Infections 272
Intracranial Complications of Sinusitis 278
References 288

SECTION V. SINUSITIS AND SPECIFIC DISEASES

14. Sinusitis and Asthma *291*
Frank S. Virant
Introduction 291
Historical Association of Sinusitis and Asthma 291
Chemical, Cytokine, and Cellular Mediators of Airway Disease 292
Impact of Medical Sinus Therapy on Asthma 294
Impact of Surgical Sinus Therapy on Asthma 294
Sinusitis as a Trigger for Asthma—Mechanisms 295
Clinical Implications 297
Conclusions 300
References 300

15. Rhinosinusitis and Allergy *305*
Desiderio Passàli, Valerio Damiani, Giulio Cesare Passàli, Francesco Maria Passàli, and Luisa Bellussi
Epidemiology 305
Pathophysiology 306
Diagnosis 308
Treatment 310
Prevention 313
References 314

The Foundry, LLC Exhibit 2001, Page 16 of 58
Neurent Medical Inc. & Neurent Medical Ltd. v. The Foundry, LLC
IPR2024-00669

16. Nosocomial Sinusitis 319
Viveka Westergren and Urban Forsum
Introduction 319
Etiology and Pathogenesis 320
Epidemiology 328
Diagnosis of an Infectious Sinusitis in the ICU 339
Microbiology and Choice of Antimicrobials 342
Treatment 345
Complications 346
Prevention 347
References 348

17. Cystic Fibrosis and Sinusitis 357
Noreen Roth Henig
Introduction 357
Pathophysiology of CF 357
Pathophysiology of CF-Related Sinusitis 358
Microbiology 359
Clinical Overview of CF Sinusitis 361
Diagnosis of Cystic Fibrosis 363
Treatment of CF-Related Sinusitis 363
Experimental Therapies 366
Special Considerations 367
Conclusion 367
References 368

18. Chronic Rhinosinusitis With and Without Nasal Polyposis 371
Joel M. Bernstein
Introduction 371
Potential Etiologies for the Early Stages of CRS 373
Microbiology 374
Epidemiology of CRS with Massive Nasal Polyposis 375
The Clinical Diagnosis of Nasal Polyposis 377
Medical and Surgical Therapy of Nasal Polyposis 380
Pathogenesis of CRS 381
Conclusions 397
References 398

The Foundry, LLC Exhibit 2001, Page 17 of 58
Neurent Medical Inc. & Neurent Medical Ltd. v. The Foundry, LLC
IPR2024-00669

19. Sinusitis of Odontogenic Origin *403*
Itzhak Brook and John Mumford
Introduction 403
Pathophysiology 403
Microbiology 407
Symptoms 411
Diagnosis 412
Management 412
Summary 415
References 416

20. Fungal Sinusitis *419*
Carol A. Kauffman
Introduction 419
Epidemiology 420
Pathogenesis 422
Diagnosis 424
Treatment 428
Conclusions 432
References 433

21. Sinusitis in Immunocompromised, Diabetic, and Human Immunodeficiency Virus–Infected Patients *437*
Todd D. Gleeson and Catherine F. Decker
Introduction 437
Sinusitis in Neutropenic Patients 438
Sinusitis in Diabetic Patients 444
Sinusitis in HIV-Infected Patients 446
Conclusion 449
References 450

Index 455

The Foundry, LLC Exhibit 2001, Page 18 of 58
Neurent Medical Inc. & Neurent Medical Ltd. v. The Foundry, LLC
IPR2024-00669

Contributors

Nafi Aygun The Russell H. Morgan Department of Radiology and Radiological Sciences, The Johns Hopkins Medical Institution, Baltimore, Maryland, U.S.A.

Daniel G. Becker Department of Otorhinolaryngology—Head and Neck Surgery, University of Pennsylvania, Philadelphia, Pennsylvania, U.S.A.

Luisa Bellussi Ear, Nose, and Throat Department—University of Siena Medical School, Viale Bracci, Siena, Italy

Michael S. Benninger Department of Otolaryngology–Head and Neck Surgery, Henry Ford Hospital, Detroit, Michigan, U.S.A.

Joel M. Bernstein Departments of Otolaryngology and Pediatrics, School of Medicine and Biomedical Sciences, Department of Communicative Disorders and Sciences, State University of New York at Buffalo, Buffalo, New York, U.S.A.

Itzhak Brook Departments of Pediatrics and Medicine, Georgetown University School of Medicine, Washington, D.C., U.S.A.

Nicolas Y. Busaba Department of Otolaryngology, Harvard Medical School, VA Boston Healthcare System, Massachusetts Eye and Ear Infirmary, Boston, Massachusetts, U.S.A.

Alexander G. Chiu Division of Rhinology, Department of Otorhinolaryngology—Head and Neck Surgery, University of Pennsylvania, Philadelphia, Pennsylvania, U.S.A.

The Foundry, LLC Exhibit 2001, Page 20 of 58
Neurent Medical Inc. & Neurent Medical Ltd. v. The Foundry, LLC
IPR2024-00669

Peter A. R. Clement Department of Otorhinolaryngology and ENT Department, University Hospital, Free University Brussels (VUB), Brussels, Belgium

Dennis A. Conrad Division of Infectious Diseases, Department of Pediatrics, University of Texas Health Science Center at San Antonio, San Antonio, Texas, U.S.A.

Valerio Damiani Ear, Nose, and Throat Department—University of Siena Medical School, Viale Bracci, Siena, Italy

Catherine F. Decker Division of Infectious Diseases, Department of Internal Medicine, National Naval Medical Center, Bethesda, Maryland, U.S.A.

Thomas M. File, Jr. Northeastern Ohio Universities College of Medicine, Rootstown, and Infectious Disease Service, Summa Health Service, Akron, Ohio, U.S.A.

Urban Forsum Division of Clinical Microbiology, Department of Molecular and Clinical Medicine, Faculty of Health Sciences, Linköping University, Linköping, Sweden

Todd D. Gleeson Division of Infectious Diseases, Department of Internal Medicine, National Naval Medical Center, Bethesda, Maryland, U.S.A.

Joshua Gottschall Department of Otolaryngology–Head and Neck Surgery, Henry Ford Hospital, Detroit, Michigan, U.S.A.

Noreen Roth Henig Adult Cystic Fibrosis Center, Advanced Lung Disease Center, California Pacific Medical Center, San Francisco, California, U.S.A.

Alexis H. Jackman Department of Otorhinolaryngology Head and Neck Surgery, University of Pennsylvania, Philadelphia, Pennsylvania, U.S.A.

Carol A. Kauffman Division of Infectious Diseases, University of Michigan Medical School, Veterans Affairs Ann Arbor Healthcare System, Ann Arbor, Michigan, U.S.A.

David W. Kennedy Department of Otorhinolaryngology Head and Neck Surgery, University of Pennsylvania, Philadelphia, Pennsylvania, U.S.A.

The Foundry, LLC Exhibit 2001, Page 21 of 58
Neurent Medical Inc. & Neurent Medical Ltd. v. The Foundry, LLC
IPR2024-00669

John H. Krouse Department of Otolaryngology Head and Neck Surgery, Wayne State University, Detroit, Michigan, U.S.A.

David Lewis Department of Otolaryngology, Harvard Medical School, Massachusetts Eye and Ear Infirmary, Boston, Massachusetts, U.S.A.

John Mumford Department of Periodontics, Naval Postgraduate Dental School, Bethesda, Maryland, U.S.A.

Desiderio Passàli Ear, Nose, and Throat Department—University of Siena Medical School, Viale Bracci, Siena, Italy

Francesco Maria Passàli Ear, Nose, and Throat Department—University of Siena Medical School, Viale Bracci, Siena, Italy

Giulio Cesare Passàli Ear, Nose, and Throat Department—University of Siena Medical School, Viale Bracci, Siena, Italy

Gary Schwartz Vanderbilt University Medical Center, Nashville, Tennessee, U.S.A.

Robert J. Stachler Department of Otolaryngology Head and Neck Surgery, Wayne State University, Detroit, Michigan, U.S.A.

Ovsev Uzunes The Russell H. Morgan Department of Radiology and Radiological Sciences, The Johns Hopkins Medical Institution, Baltimore, Maryland, U.S.A.

Frank S. Virant University of Washington, Seattle, Washington, U.S.A.

Ellen R. Wald Department of Pediatrics and Otolaryngology, University of Pittsburgh School of Medicine, Allergy, Immunology, and Infectious Diseases, Pittsburgh, Pennsylvania, U.S.A.

Viveka Westergren Division of Clinical Microbiology, Department of Molecular and Clinical Medicine, Faculty of Health Sciences, Linköping University, Linköping, Sweden

Steve White Vanderbilt University Medical Center, Nashville, Tennessee, U.S.A.

S. James Zinreich The Russell H. Morgan Department of Radiology and Radiological Sciences, The Johns Hopkins Medical Institution, Baltimore, Maryland, U.S.A.

The Foundry, LLC Exhibit 2001, Page 22 of 58
Neurent Medical Inc. & Neurent Medical Ltd. v. The Foundry, LLC
IPR2024-00669

12

Surgical Management

David Lewis

Department of Otolaryngology, Harvard Medical School, Massachusetts Eye and Ear Infirmary, Boston, Massachusetts, U.S.A.

Nicolas Y. Busaba

Department of Otolaryngology, Harvard Medical School, VA Boston Healthcare System, Massachusetts Eye and Ear Infirmary, Boston, Massachusetts, U.S.A.

INTRODUCTION

The surgical treatment of sinus disease has changed dramatically over the past 20 years in the United States and nearly 30 years in Europe. In the past, otolaryngologists relied on using the nasal speculum and a headlight to diagnose and treat diseases of the nasal cavity and paranasal sinuses. Such an examination only allowed for viewing of the anterior components of the nose, and the observer was unable to adequately view the paranasal sinuses or their ostia. For improved visualization and more thorough treatment, open approaches were the only option. There has also been a conceptual shift away from attempting to surgically exenterate the disease within the paranasal sinuses to simply opening specific areas in order to improve sinus function and allow better aeration and drainage. The amount of tissue removed during sinus surgery is minimized now, and the surgeon relies on opening key functional areas to restore the normal physiology within the paranasal sinuses, which thereby helps to reverse the disease.

Since the introduction of nasal endoscopes, the diagnosis and the treatment of sinus disease have changed remarkably. One now has the ability to view the anatomy of the nasal cavity, and at times, the paranasal

The Foundry, LLC Exhibit 2001, Page 23 of 58
Neurent Medical Inc. & Neurent Medical Ltd. v. The Foundry, LLC
IPR2024-00669

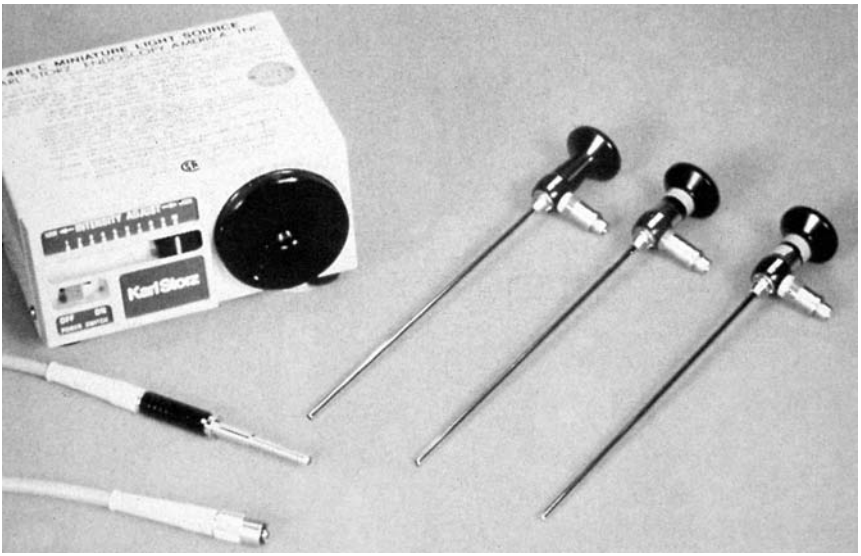

Figure 1 Light source and three 4-mm diameter rigid endoscopes. The endoscopes have a zero, 30-degree, and 70-degree viewing angles.

sinuses themselves, up close and with remarkable detail (Fig. 1). Nasal endoscopes use fiberoptic light cables to transmit light into the nose. Special optical lenses are used for improved viewing. There are both flexible and rigid endoscopes; the latter are available in many different angled optics systems. These scopes allow for excellent visualization of the entire nasal cavity, both in the office and in the operating room, and all of the key paranasal sinus ostia that are involved in sinus disease. The cameras attach to the eyepiece of the endoscope, allow for easy viewing on a television monitor, and also offer the added advantage of using endoscopes for video recording to demonstrate anatomy and pathology to patients in the office, and for teaching purposes.

DIAGNOSTIC WORK-UP

Medical History

When a patient with sinus complaints is referred to the otolaryngologist, the evaluation always begins with a thorough history followed by a careful examination of the nose. (Please refer to the chapter on Clinical Presentation and Diagnosis for a more detailed review on the evaluation of a patient with sinus disease). The patient should be asked about symptoms of facial pain or pressure over individual sinuses, headache, nasal blockage, rhinorrhea, postnasal drip, and hyposmia (Table 1). It is very important to ask

The Foundry, LLC Exhibit 2001, Page 24 of 58
Neurent Medical Inc. & Neurent Medical Ltd. v. The Foundry, LLC
IPR2024-00669

Table 1 Medical History

Symptoms
Facial pain or pressure
Headache
Nasal blockage
Rhinorrhea
Post-nasal drip
Hyposmia and/or hypogeusia
Previous treatment attempts
Antibiotics
Steroids
Antihistamines
Allergen avoidance
Previous sinus surgery
Past medical and surgical history
Other medications
Drug allergies
Environmental allergies
Social history including tobacco smoke exposure
Family history
Review of systems

about previous attempts at medical management. What antibiotics have been used to treat the symptoms and for how long were they used? Did they improve the symptoms? Is the patient a smoker or exposed to passive smoke or other irritants? Does the patient have an allergic component to the disease process? If so, have these issues been maximally treated medically with antihistamines, nasal steroids, or other medications? Is the patient a candidate for immunotherapy? Is allergen avoidance a realistic possibility for the patient? What other comorbidities does the patient have? These questions are important to ensure that all patients have been given the most optimal attempt at medical management prior to making any decisions about surgery.

Physical Examination

As part of the head and neck evaluation, a thorough nasal examination should be completed in the office. Anterior rhinoscopy using a headlight or mirror and a nasal speculum should be performed prior to any attempts at nasal decongestion. Any evidence of mucopurulent discharge, nasal polyps, enlarged turbinates, nasal septal deviation, or diseased mucosa should be noted. Using either a rigid or flexible endoscope, one can almost always view the middle meatus and the sphenoethmoid recess. Decongestion and anesthesia with a sprayed mixture of 4% lidocaine with phenylephrine

The Foundry, LLC Exhibit 2001, Page 25 of 58
Neurent Medical Inc. & Neurent Medical Ltd. v. The Foundry, LLC
IPR2024-00669

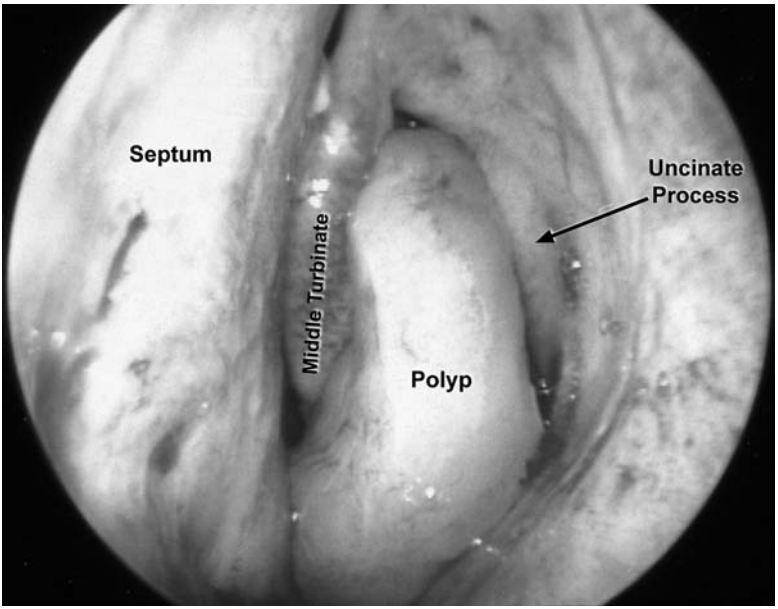

Figure 2 Endoscopic view of an inflammatory polyp in the left middle meatus.

facilitates this part of the examination. The findings noted on anterior rhinoscopy can be confirmed. Additionally, one might see limited areas of inflammation, mucopurulent discharge, and/or polypoid changes that could not be seen during the initial rhinoscopic examination (1) (Fig. 2).

Imaging

Based on the history and examination findings, a decision is made whether or not to obtain a computed tomography (CT) scan. Noncontrast CT scans, particularly in the coronal plane, can be very helpful both for diagnosis and pre-operative planning if surgery is indicated. CT scans can confirm sinusitis, and they can offer the surgeon valuable information about the patient's anatomy that can be used to help avoid complications during surgery. Occasionally, a CT scan can also be useful in ruling out sinus disease in a patient with convincing sinus complaints but no evidence of disease on exam. Additionally, the CT scan has become a valuable tool in image-guided sinus surgery (see following sections).

INDICATIONS FOR PARANASAL SINUS SURGERY

There is currently a wide range of indications for paranasal sinus surgery (Table 2). The most common indication is for chronic rhinosinusitis (CRS).

The Foundry, LLC Exhibit 2001, Page 26 of 58
Neurent Medical Inc. & Neurent Medical Ltd. v. The Foundry, LLC
IPR2024-00669

Table 2 Indications for Paranasal Sinus Surgery

1. Inflammatory or infectious rhinosinusitis
Chronic rhinosinusitis that failed medical therapy
Recurrent rhinosinusitis
Symptomatic nasal polyposis
Acute or chronic rhinosinusitis with periorbital or intracranial complications
Invasive fungal sinusitis
Fungus ball-mycetoma
2. Sinonasal neoplasm (benign and malignant)
3. Repair of skull base defects
CSF rhinorrhea
Menigoceles or meningoencephaloceles
4. Approach for excision of intracranial pathology
Pituitary tumors
Petrous apex cholesterol granuloma
5. Control of epistaxis
6. Orbital decompression for Graves' ophthalmopathy
7. Removal of sinus foreign bodies
8. Management of nasolacrimal duct obstruction

Patients who continue to have signs and symptoms of rhinosinusitis despite maximal medical therapy are often candidates for sinus surgery. Maximum medical therapy has not been standardized, but typically involves four to six weeks of broad-spectrum oral antibiotics used in conjunction with decongestants and mucolytic agents. Patients with allergies are often also given antihistamines and intranasal steroid sprays. Surgery may also be considered in patients who have repeated episodes of acute rhinosinusitis that clears with antibiotics. Although there is no agreed treatment algorithm for patients with recurrent rhinosinusitis, many rhinologists feel that if the frequency and severity of the patient's symptoms are sufficient to interfere significantly with school or work, then surgery is a reasonable option (2). Prior to surgery, it is important to rule out non-sinus causes of a patient's symptoms, i.e., atypical migraines or other neurologic causes including neuralgia.

Another indication for sinus surgery is to treat patients with symptomatic nasal polyposis. The pathophysiology of polyp formation is poorly understood. However, polyps are commonly associated with asthma and environmental allergies. On the other hand, it is not unusual to diagnose polyps in a patient without atopy or asthma. An antral-choanal polyp is such an example. Unfortunately, medical therapy is rarely sufficient to control nasal polyposis and surgery is often indicated. Patients should be counseled about the high recurrence following surgery. Special attention must be given to those patients with asthma, particularly those with aspirin-sensitivity (Samter's triad). These patients often require preoperative corticosteroids and maximal bronchodilator therapy to optimize their

The Foundry, LLC Exhibit 2001, Page 27 of 58
Neurent Medical Inc. & Neurent Medical Ltd. v. The Foundry, LLC
IPR2024-00669

pulmonary status. The corticosteroids may also serve to shrink the polyps and possibly decrease their risk of recurrence. Aspirin-desensitization may also be beneficial in these patients. It is important to note that the differential diagnosis of nasal polyps includes some benign and malignant tumors. Hence, at the time of surgery, tissue specimens should be sent for permanent pathology in all cases. Unilateral disease, a rubbery or fleshy, highly vascular, or ulcerative appearance, or CT evidence of bone destruction should alert one to the possibility of a neoplasm.

In addition to the more common above-mentioned indications, sinus surgery can be performed to treat allergic fungal sinusitis and periorbital and intracranial complications of sinusitis; marsupialize muco(pyo)celes; control epistaxis; remove maxillary sinus foreign bodies; repair anterior skull base cerebrospinal fluid (CSF) leaks or meningo(encephalo)celes; decompress the orbit in patients with Graves' ophthalmopathy; dacrocystorhinostomy; approach and remove pituitary tumors, petrous apex cholesterol granulomas or other skull base lesions; resect benign neoplasms (osteomas, inverting papillomas, or fibrous dysplasia); and decompress the optic nerve (2).

CONTRAINDICATIONS FOR PARANASAL SINUS SURGERY

The only true contraindication to paranasal sinus surgery is the absence of sinus disease. Patients with migraine headaches or other neurological causes of facial pain should not be operated on. Additionally, surgery is not a substitute for medical management; patients with CRS, as mentioned above, should be given maximum medical therapy prior to being offered surgery. A bleeding disorder can place a patient at an increased risk for postoperative hemorrhage, but does not in itself represent a contraindication to surgery.

ENDOSCOPIC (ENDONASAL) SINUS SURGERY

The techniques for performing endoscopic sinus surgery were first described by Messerklinger during the 1970s. These techniques were later introduced into the United States during the mid-1980s by Kennedy, who coined the term "Functional Endoscopic Sinus Surgery" (FESS) to describe a minimally invasive approach to improve drainage of the paranasal sinuses for the treatment of CRS (3–6). Endoscopic endonasal surgery (EES) or endoscopic sinus surgery (ESS) are other terms commonly used to describe the same operation and can be used interchangeably.

FESS involves opening up narrow areas within the nose and paranasal sinuses that are responsible for the pathological changes seen in CRS. Messerklinger studied patterns of mucociliary clearance and noted that in narrow areas of mucosal contact, mucociliary clearance was disrupted (6,7). When this occurs, the mucus becomes either stagnant or recirculated

The Foundry, LLC Exhibit 2001, Page 28 of 58
Neurent Medical Inc. & Neurent Medical Ltd. v. The Foundry, LLC
IPR2024-00669

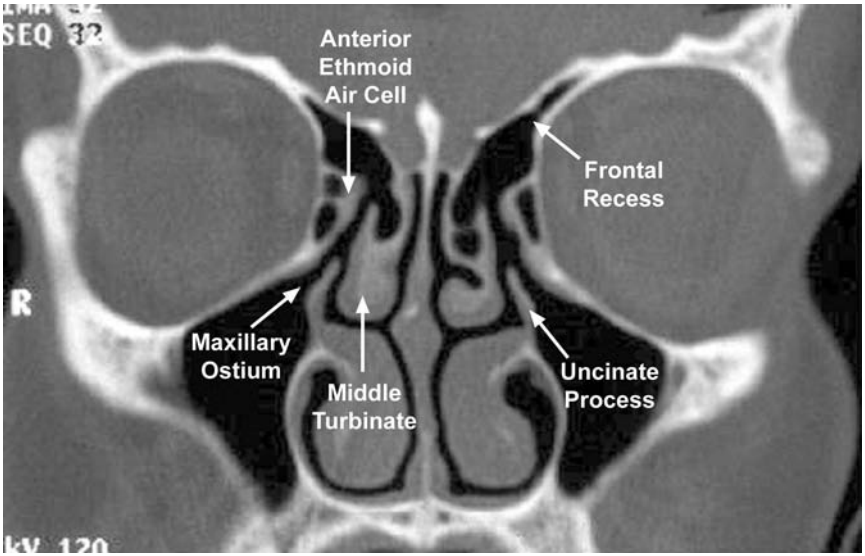

Figure 3 CT image (coronal projection) through the ostiomeatal unit (OMU).

within the affected sinus rather than freely draining into the nasal cavity and nasopharynx. Stagnant or recirculated mucus predisposes the patient to infection, which leads to inflammation that further impedes mucociliary clearance, resulting in increased infection followed by more inflammation, and then a vicious cycle ensues.

The two primary areas of narrowing that can impair mucociliary clearance and lead to problems with CRS are the ethmoidal infundibulum and the frontal recess. These two anatomical points of narrowing are both located in the anterior ethmoid area within the middle meatus. Many rhinologists use the term osteomeatal complex (OMC) or osteomeatal unit (OMU) to describe this functional area where narrowing can occur (Fig. 3). The ethmoidal infundibulum is a three-dimensional space that is a convergence point for mucus flowing from the anterior ethmoid air cells, the maxillary sinus, and the frontal sinus (8). Similarly, the frontal recess is a narrow area in which mucus from the frontal sinus must pass prior to reaching the ethmoidal infundibulum (1,6–8). This area can be further narrowed by projections from the most anterior of the ethmoid air cells, the agger nasi cells (Fig. 4). FESS aims at opening up these two key areas of narrowing to allow adequate drainage of the frontal, anterior ethmoid, and maxillary sinuses. When widespread disease affects all paranasal sinuses, ESS can be tailored to treat all the involved areas.

There are two primary goals of FESS. The first is to open up the narrow areas described above. The second is to perform the surgery in as

The Foundry, LLC Exhibit 2001, Page 29 of 58
Neurent Medical Inc. & Neurent Medical Ltd. v. The Foundry, LLC
IPR2024-00669

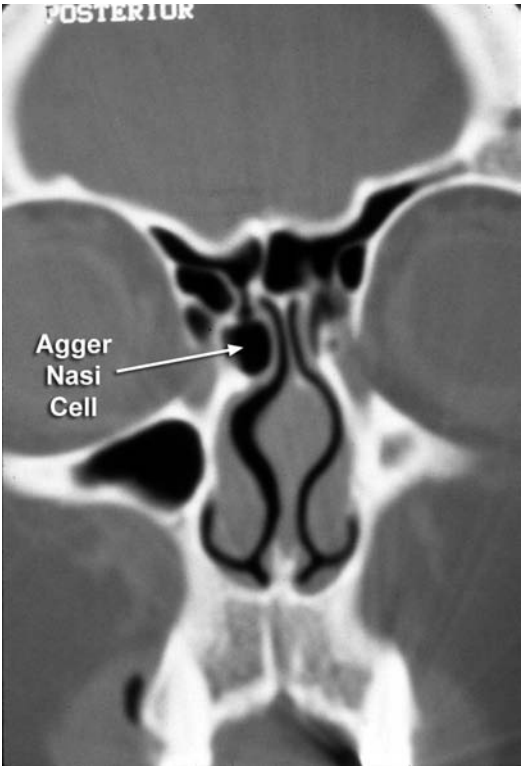

Figure 4 CT image (coronal projection) showing a right agger nasi cell.

atraumatic a manner as possible (1,6–8). Accordingly, sinus surgeons must remove the anatomical areas of obstruction without disturbing the surrounding healthy mucosa. In order to open a narrowed ostiomeatal complex, a thin piece of bone called the uncinate process is carefully removed in its entirety. Additionally, an ethmoid air cell called the ethmoid bulla is typically removed to allow better drainage (Fig. 3). Any further removal of tissue is dependent on the extent of disease. Some believe that an uncinectomy with an ethmoid bullectomy is all that is necessary during FESS and coined the term minimally invasive sinus technique (MIST) (9). The majority of rhinologists recommend a more complete ethmoidectomy in addition to widening of the maxillary ostium and opening of the frontal recess cells. All agree, however, that any diseased mucosa that is not a direct component of the osteomeatal complex should not be removed or manipulated because this surrounding area of disease will eventually revert to normal once there is a wide open area for drainage and aeration (8). In other words, one does not need to strip away all of the diseased mucosa because paranasal sinus

The Foundry, LLC Exhibit 2001, Page 30 of 58
Neurent Medical Inc. & Neurent Medical Ltd. v. The Foundry, LLC
IPR2024-00669

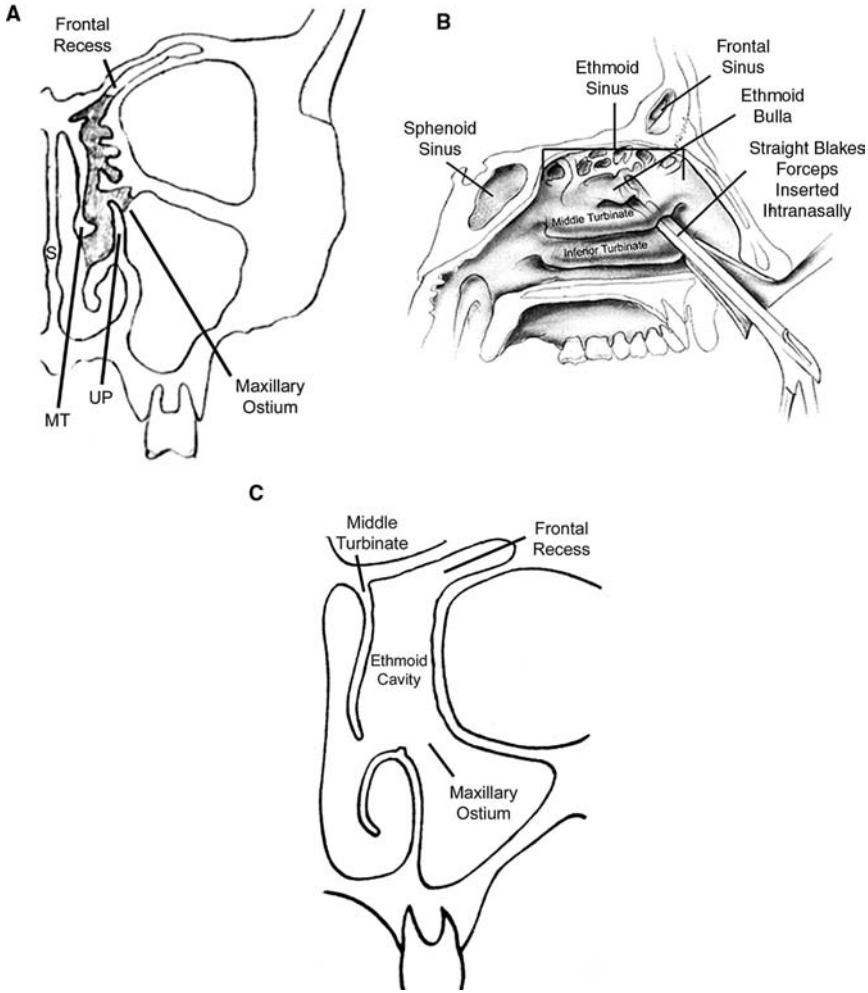

Figure 5 Schematic representation of endoscopic sinus surgery. (**A**) Coronal projection through the OMU. The shaded area represents the ethmoid sinus. (**B**) Schematic drawing of the procedure. (**C**) Ethmoid sinus cavity at the end of surgery with patent maxillary antrostomy and frontal recess. Note that the uncinate process has been removed. *Abbreviations*: UP, uncinate process; MT, middle turbinate; S, septum.

mucosal pathology can be reversed by improving the ventilation and drainage of the involved sinus (Fig. 5).

By minimizing mucosal disruption, one can minimize postoperative scarring. This is very important because some areas of scar tissue formation can be devoid of the respiratory epithelium required for mucociliary clearance. If there are large areas of scar, then mucus will stagnate. Additionally, mucosal

The Foundry, LLC Exhibit 2001, Page 31 of 58
Neurent Medical Inc. & Neurent Medical Ltd. v. The Foundry, LLC
IPR2024-00669

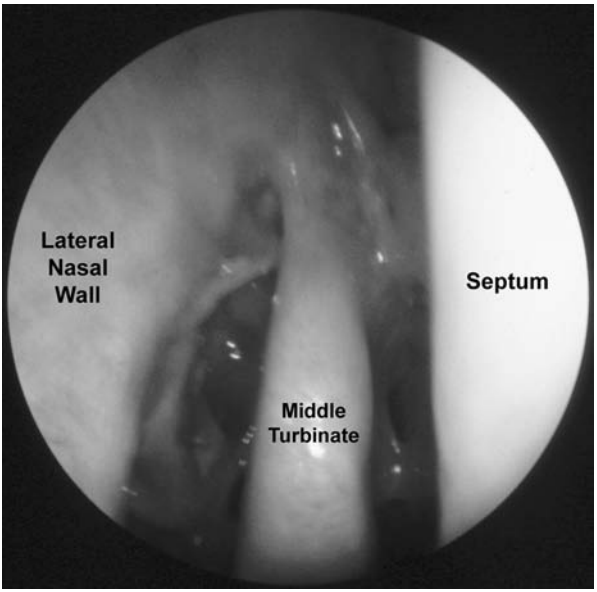

Figure 6 Adhesions in a right ethmoid cavity in a patient with previous endoscopic ethmoidectomy.

disruption with scarring often results in fibrous adhesions that can re-obstruct the drainage of mucus resulting in recurrence of sinus disease (Fig. 6). In these instances, a revision surgery may be required.

The role of several anatomical findings that are noted on CT or nasal endoscopy in the pathophysiology of rhinosinusitis is controversial (10). These include Haller cells, agger nasi cells, concha bullosa, and paradoxical middle turbinate. A Haller cell is an ethmoidal cell that is located along the floor of the orbit and can narrow the maxillary outflow tract (Fig. 7). An agger nasi cell is the anterior-most cell of the ethmoid sinus and may represent pneumatization of the lacrimal bone. Agger nasi cells can narrow the frontal recess (Fig. 4). A concha bullosa is a pneumatized middle turbinate. When large, it can conceivably narrow the OMU (Fig. 8). A paradoxical middle turbinate is convex along its lateral wall instead of the medial wall (Fig. 9). Similar to a concha bullosa, a paradoxical middle turbinate can narrow the OMU. All of the above-mentioned anatomical findings are very prevalent and may be better labeled as anatomical variants, not anomalies. Surgery is not indicated to treat them in the absence of clinical rhinosinusitis. On the other hand, these anatomical findings need to be addressed during ESS that is indicated to treat CRS.

The concept of OMU is valid when the pathophysiology of the CRS is believed to be infectious. More recent theories about the pathogenesis of

The Foundry, LLC Exhibit 2001, Page 32 of 58
Neurent Medical Inc. & Neurent Medical Ltd. v. The Foundry, LLC
IPR2024-00669

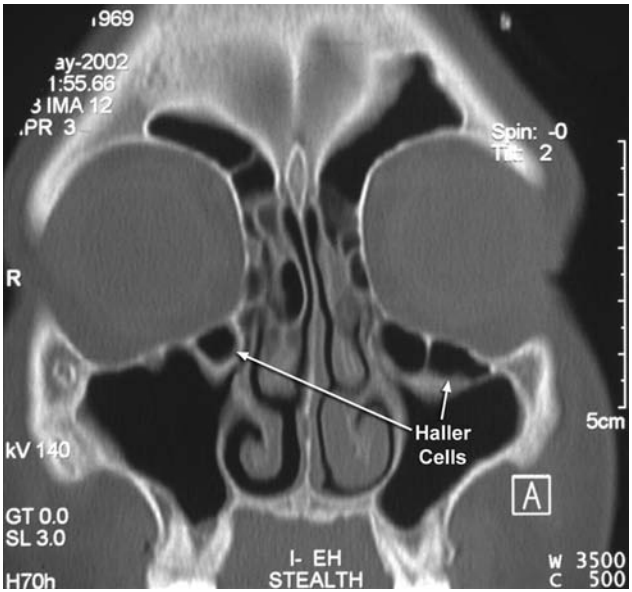

Figure 7 Bilateral Haller cells that narrowed the maxillary outflow tract as seen on a CT scan (coronal projection).

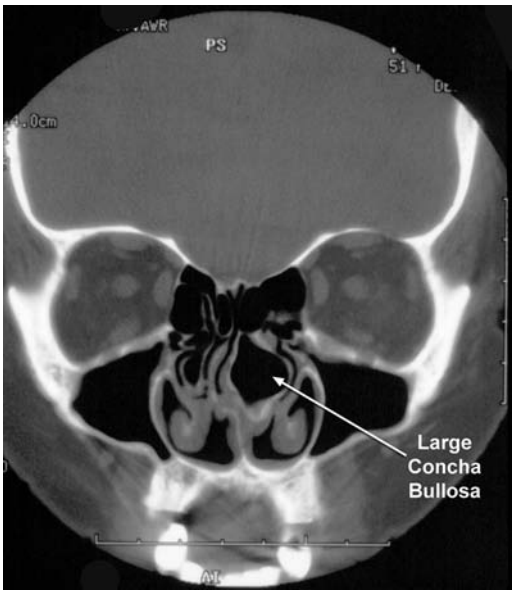

Figure 8 Large left concha bullosa. A smaller concha bullosa can be seen on the right side. (CT scan; coronal projection).

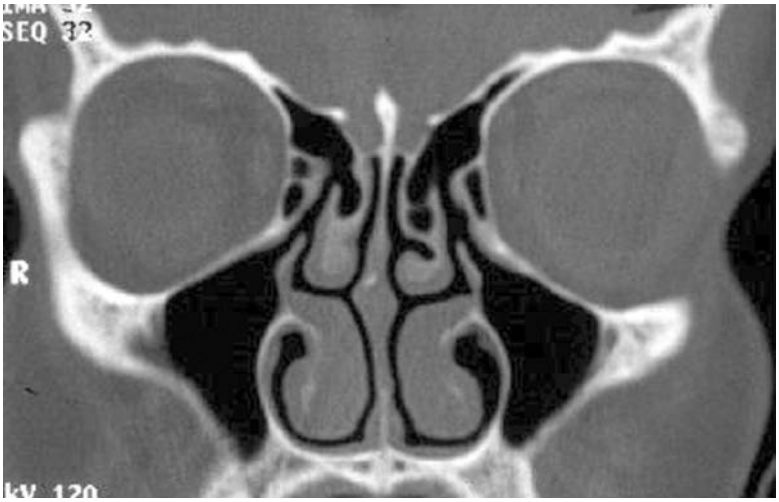

Figure 9 Paradoxical left middle turbinate. Note that the middle turbinate is convex on the lateral surface.

rhinosinusitis stress the role of inflammation as the primary event, i.e., rhinosinusitis is primarily an inflammatory and not an infectious disease. The inflammation is believed to be predominantly caused by the inflammatory mediators that are released by eosinophils, usually in response to the presence of fungi or other superantigens in the nose or sinus mucus (eosinophilic CRS) (11,12). In such a case, the role of ESS is to reduce the offending antigen load by allowing repeated cleaning of inspissated mucus from the sinus cavities in the office by opening their ostia, which in turn can reduce the inflammation. Therefore, ESS in this clinical scenario has a complementary function, and is not a substitute to medical therapy.

The patients who undergo ESS typically are given perioperative antibiotics. Coverage is aimed at preventing acute infection by normal flora that has pathogenic potential, such as *Staphylococcus aureus*, *Streptococcus pneumoniae*, *Haemophilus influenzae*, or alpha streptococci. A common choice for an antibiotic would be a first-generation cephalosporin, such as cephalexin. Other choices include clindamycin or azithromycin, the former of which covers anaerobes as well. It should be noted that although there are data to support the use of perioperative antibiotics for other types of surgery, there is no proven benefit to the use of postoperative prophylactic antibiotics after ESS (13,14).

When inflammatory rhinosinusits is complicated by chronic infection, at least 2 weeks of culture driven antibiotics may be used perioperatively in order to decrease intraoperative bleeding.

The Foundry, LLC Exhibit 2001, Page 34 of 58
Neurent Medical Inc. & Neurent Medical Ltd. v. The Foundry, LLC
IPR2024-00669

The majority of ESSs can be done on an outpatient basis. The surgery typically takes between 45 minutes and two hours to perform, depending on the extent of surgery. Although this rarely is a painful surgery, patients are sent home with a prescription for analgesics, which at times contain a narcotic. However, many patients only require regular acetaminophen for analgesia. Like in any other surgery, patients are instructed that they must avoid aspirin and nonsteroidal anti-inflammatory medications for two weeks prior to and at least one week after surgery. Patients can often return to work after a couple of days; however, they are advised to avoid physical exertion for one to two weeks. Additionally, they are instructed to avoid hot liquids and spicy foods to prevent intranasal vasodilation that might result in epistaxis.

Postoperative care is of utmost importance. In order to prevent recurrence of the disease secondary to scarring, patients must return for intranasal debridements on a routine basis for up to six weeks after surgery. If intranasal packing was placed for hemostasis, it can be removed on the first postoperative day. Any material that may have been used to stent open the middle meatus is typically removed at the first or second office visit. If adhesions are found between the middle turbinate and lateral nasal wall or restenosis is noted of the maxillary antrostomy or frontal recess at any point during routine follow up, this can often be successfully treated under local anesthesia in the office. Additionally, irrigation is a very effective method that patients can use at home to remove crusts and clots. Many surgeons have their patients started on saline irrigations immediately after surgery and continue irrigating until the healing process is complete. Using a combination of nasal irrigation and in-office debridements, one can often prevent complications that might otherwise have resulted in recurrence of disease and the need for revision surgery (8,15).

COMPLICATIONS OF ENDOSCOPIC SINUS SURGERY

When sinus surgery is performed by experienced surgeons who have a detailed knowledge of sinus anatomy, complications are extremely rare. However, complications can and do occasionally occur, even with the most seasoned of surgeons (Table 3). A small amount of bleeding is expected postoperatively. Nasal packing, and, at times, hemostasis in the operating room can control major bleeding. Postoperative infection is uncommon. When an infection does occur, office debridement and an oral antibiotic which is determined by culture of the sinus cavity are usually sufficient treatment. As mentioned above, scarring with adhesions and restenosis of ostia can occur. If the office-based treatments fail, then these patients may require a revision surgery.

The paranasal sinuses are surrounded by a number of important structures, which can be potentially injured during sinus surgery. Injury to the anterior skull base can result in a CSF leak. If this is identified during

The Foundry, LLC Exhibit 2001, Page 35 of 58
Neurent Medical Inc. & Neurent Medical Ltd. v. The Foundry, LLC
IPR2024-00669

Table 3 Complications

Bleeding
Infection
Adhesions
Restenosis
CSF leak
Periorbital hematoma
Subcutaneous emphysema
Diplopia
Blindness
Epiphora

surgery, then it can be repaired at the time of the incident. If a CSF leak is noted postoperatively, then the patient is placed on bed rest with the head elevated, either with or without placement of a lumbar drain depending on the severity of the leak. These leaks may close spontaneously. Those that do not close can be repaired via either an endoscopic or an open approach, the latter being performed by a neurosurgeon (8,16). Injury to the medial wall of the orbit can result in a retro-orbital hematoma, diplopia, subcutaneous orbital emphysema, or blindness. If the lamina papyracea and periorbita are entered, then blood can accumulate in the orbit. Usually this only results in periorbital ecchymosis; however, patients must be closely monitored for signs of increased intraocular pressure. An ophthalmologist should be consulted immediately because an elevated intraocular pressure for a prolonged interval causes ischemia to the optic nerve, which can result in blindness. Direct injury to the optic nerve along the superior-lateral wall of the sphenoid sinus or posterior aspect of the lamina papyracea (in the region of annulus of Zinn) can similarly cause blindness. The presence of an Onodi cell (a posterior ethmoid air cell that is lateral and at times posterior to the sphenoid sinus) is associated with an increased incidence of optic nerve injury since the nerve may be dehiscent and pass through the cell. Such an anatomic variant can be detected on a preoperative CT (Fig. 10). Blindness can also rarely result from the dissection of local anesthetic containing decongestants (epinephrine) towards the orbital apex, which can cause spasm of the central retinal artery. Diplopia can occur if inadvertent entry into the orbit results in injury to the medial rectus muscle or violation of the periorbita that results in extensive herniation of intraorbital fat. Subcutaneous orbital emphysema occurs if there is injury to the lamina papyracea and the patient inadvertently performs a Valsalva maneuver during vomiting, sneezing, or nose blowing, which usually resolves spontaneously.

Damage to the nasolacrimal duct may occur following sinus surgery, resulting in epiphora and possibly dacrocystitis. The nasolacrimal duct runs

The Foundry, LLC Exhibit 2001, Page 36 of 58
Neurent Medical Inc. & Neurent Medical Ltd. v. The Foundry, LLC
IPR2024-00669

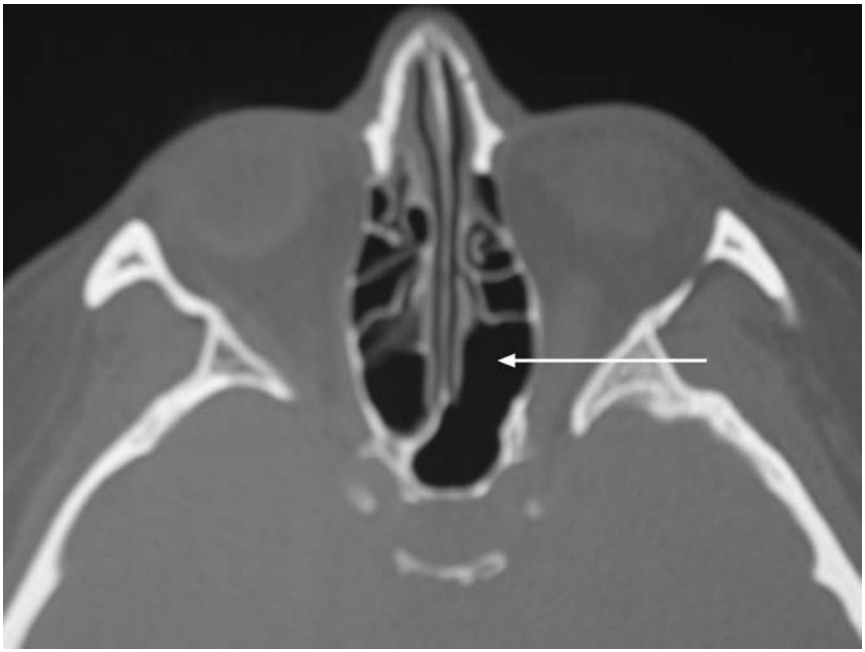

Figure 10 CT (axial projection) showing a left Onodi cell (a posterior ethmoid cell that extends lateral and at times posterior to the sphenoid sinus).

anterior to the anteromedial wall of the maxillary sinus. Hence, an aggressive anterior maxillary antrostomy can accidentally damage this duct as it travels to the inferior meatus (8,16).

Fortunately, these complications are very uncommon. However, patients must be aware of and understand the implications of each of these complications prior to consenting to any form of sinus surgery.

IMAGE GUIDANCE SYSTEMS

The advent of image-guided sinus surgery has had a dramatic impact on ESS. Although it is not a substitute for experience and anatomical knowledge, image-guided surgery has allowed rhinologists to perform challenging and complicated endoscopic procedures with increased confidence and precision. Image guidance systems consist of a computer workstation that displays three-dimensional images of the patient's paranasal sinuses using information obtained from preoperative CT scans. Either an infrared or an electromagnetic signal is used to track the position of a probe or surgical instrument relative to the patient's head (17). Hence, a surgeon can place the tip of an instrument on, for example, the middle turbinate, and see a

The Foundry, LLC Exhibit 2001, Page 37 of 58
Neurent Medical Inc. & Neurent Medical Ltd. v. The Foundry, LLC
IPR2024-00669

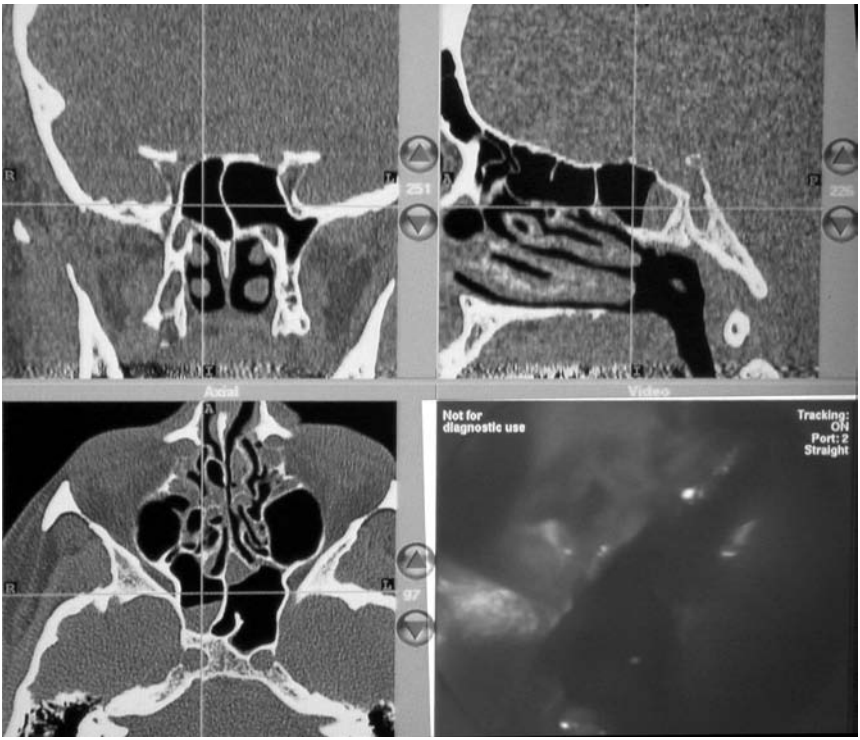

Figure 11 Image guidance system. Right upper, left upper, and left lower images are sagittal, coronal, and axial projections of CT scan with the cross-hairs indicating the position of the probe during surgery. The probe is inside the right sphenoid sinus. The right lower image shows a simultaneous endoscopic view into the sphenoid sinus.

real-time representation of the probe in coronal, axial, and sagittal planes. This can be done to within 2 mm of accuracy (18–20). They can, therefore, be used to confirm certain anatomical locations that are of interest to the surgeon, for example, the lamina papyracea, the skull base, the frontal recess, the sphenoid sinus, or any other area accessible by the probe (Fig. 11). This is particularly helpful in revision cases where the normal anatomical landmarks are obscured. The major limitations to widespread use of this technology are the increased cost and operative time that it requires (18).

MICRODEBRIDERS AND SINUS SURGERY

Mechanical debriders are becoming more and more popular in the field of ESS. These powered instruments precisely shave tissue using an oscillating burr connected to a suction machine (Fig. 12). When used correctly, these mechanical microdebriders can minimize trauma to the tissues and help to



Figure 12 A picture of a microdebrider (Diego Microdebrider; Xomed, USA). The insert is a magnified view of the tip of the microdebrider showing its serrated edges ("aggressive cutter"), which has a 4 mm diameter tip.

preserve normal tissue. In contrast, the use of traditional endoscopic instruments can occasionally tear or strip away healthy mucosa leaving exposed bone, which results in increased crusting and risk of scarring (21,22). The microdebrider can remove diseased tissue quickly and efficiently, which is particularly helpful in cases of nasal polyposis when there can be profuse intraoperative bleeding. The main disadvantages to this technology are the cost, the slightly increased set-up time required, and the repeated clogging of the instrument by the resected tissue. Additionally, aggressive use of a microdebrider through an iatrogenic or disease-related dehiscence of the lamina papyracea or fovea ethmoidalis (roof of the ethmoid sinus) can lead to injury of intraorbital or intracranial structures, respectively.

TYPES OF PARANASAL SINUS SURGERY

The type of surgery performed on a patient depends on the extent and nature of the disease. Now that ESS has become the standard of care for the surgical management of uncomplicated CRS, open approaches to the sinuses are utilized far less often than in the past. Nonetheless, many open procedures are still indicated in select cases. Additionally, there are instances when only a single paranasal sinus needs to be surgically addressed. This section describes the various surgical approaches specific to each individual paranasal sinus.

Maxillary Sinus Surgery

Antral Puncture and Lavage

This procedure takes approximately 10 minutes and can be performed under local anesthesia via two approaches: the canine fossa or the inferior meatus. In the first approach, a small stab incision is made in the upper gingivobuccal sulcus and the anterior bony wall of the maxillary sinus is then entered. In

The Foundry, LLC Exhibit 2001, Page 39 of 58
Neurent Medical Inc. & Neurent Medical Ltd. v. The Foundry, LLC
IPR2024-00669

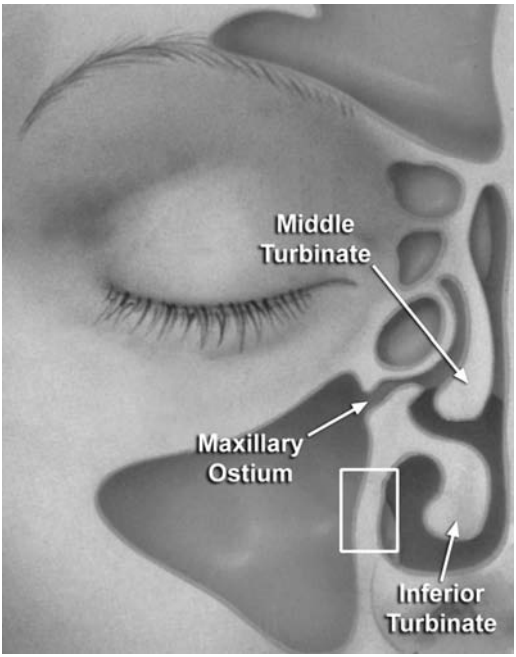

Figure 13 Schematic representation of the right maxillary sinus. The white rectangle represents the area in the inferior meatus where antral puncture or inferior nasoantral window is performed.

the latter approach, the thin bone of the medial maxillary wall is punctured in the inferior meatus (Fig. 13). Either approach can be performed under local anesthesia. The maxillary sinus cavity may then be aspirated and the contents sent for microbiology. The cavity can also be irrigated (lavage) with saline or antibiotic-containing solution. This procedure is indicated for symptomatic relief of acute maxillary sinusitis or for obtaining a culture to guide in the choice of an antimicrobial, usually in the ICU setting or with immunocompromised patients. The main disadvantages are the discomfort and the risk of bleeding.

Inferior Nasoantral Window

The technique is similar to antral puncture through the inferior meatus (Fig. 13). However, in this instance, a wider opening is created in the medial wall of the maxillary sinus to allow for permanent drainage and aeration. The procedure can be performed under local or general anesthesia. This procedure can be particularly helpful in patients with congenital or acquired ciliary dyskinesia since it provides for gravitational drainage of the maxillary sinus secretions. However, there is a high incidence of stenosis or

The Foundry, LLC Exhibit 2001, Page 40 of 58
Neurent Medical Inc. & Neurent Medical Ltd. v. The Foundry, LLC
IPR2024-00669

complete closure of the window. In addition, maxillary sinus disease may persist despite a patent inferior nasoantral window since the mucociliary clearance drives the mucus towards the natural ostium and that may still be obstructed.

Endoscopic Middle Meatal Antrostomy

As mentioned earlier in this chapter, ESS has become the mainstay of surgical treatment of both chronic and recurrent maxillary rhinosinusitis. In order to gain endoscopic access to the maxillary sinus, one must surgically remove the uncinate process in order to open up the ethmoidal infundibulum. Once this is done, the natural maxillary sinus ostium can typically be seen. This can be enlarged if necessary through the posterior fontanelle (Fig. 14). Obstructive anatomic abnormalities, such as Haller cells, can also be addressed. This is usually sufficient to treat the maxillary disease without the need for stripping the maxillary sinus mucosa. Establishing adequate aeration and drainage of the maxillary sinus by opening its natural ostium can reverse the disease in the sinus mucosa. This technique is also utilized to remove mycotic "fungus balls" or symptomatic mucus retention cysts, marsupialize muco(pyo)celes of the maxillary sinus, and excise antrochoanal polyps (23,24) (Fig. 15). In the latter cases, a 30-degree or a 70-degree rigid endoscope is used to view the entirety of the maxillary sinus cavity to ensure complete excision, which reduces recurrence. The main advantages in using an endoscopic approach is that it avoids the need for an incision, it is relatively quick, and often can be performed on an outpatient basis. The primary disadvantage is the risk of being unable to fully remove disease in the most lateral recesses of the sinus or along its floor. This is particularly relevant during excision antrochoanal polyp or maxillary sinus retention cyst where recurrences following endoscopic approach can be up to 50% (24). For this reason, many surgeons will often consent select patients for a Caldwell-Luc procedure (see following section) in case an endoscopic approach does not provide adequate exposure to sufficiently treat the disease. Clinical failures of middle meatal antrostomy can be attributed to ciliary dyskinesia or to its occlusion by scar tissue. Optimal postoperative care with office endoscopic debridement in the immediate postoperative period can prevent adhesions in the middle meatus and hence occlusion of the antrostomy.

Caldwell-Luc Procedure

The Caldwell-Luc procedure has been used for over a hundred years to gain access to the maxillary sinus. The Caldwell-Luc procedure involves opening up the anterior wall of the maxillary sinus through the upper gingivobuccal sulcus. A flap of gingiva and periosteum is used to obtain access to the sinus. Unlike the endoscopic approach, the maxillary sinus mucosa is typically stripped and removed during a Caldwell-Luc operation. The procedure

The Foundry, LLC Exhibit 2001, Page 41 of 58
Neurent Medical Inc. & Neurent Medical Ltd. v. The Foundry, LLC
IPR2024-00669

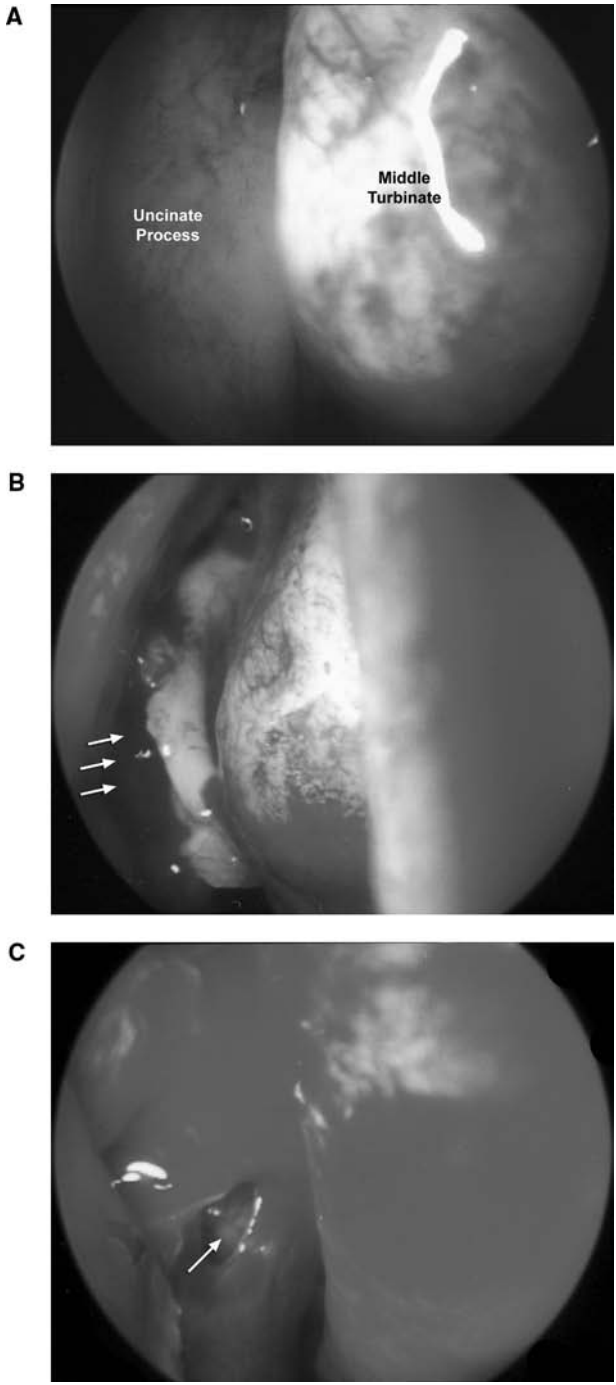

Figure 14 (*Caption on facing page*)

The Foundry, LLC Exhibit 2001, Page 42 of 58
Neurent Medical Inc. & Neurent Medical Ltd. v. The Foundry, LLC
IPR2024-00669

Figure 15 Left antrochoanal polyp. (CT image; coronal projection).

takes approximately one hour. Postoperatively, the patient may or may not have packing in the sinus depending on the amount of bleeding during the case. Some surgeons will apply ice to the upper lip or a pressure dressing to minimize postoperative swelling. Prophylactic antibiotics targeted at normal oral flora are often given perioperatively for five to seven days. Complications are relatively uncommon and include facial swelling, bleeding, and infection. Transient, or rarely permanent, anesthesia of the upper lip and teeth due to a stretch-on or a transection of the infraorbital nerve can occur. This typically subsides within weeks to months in the earlier case but is permanent in the latter (25). An oroantral fistula can develop from nonhealing of the gingivobuccal sulcus incision.

Current indications for the Caldwell-Luc procedure include the removal of mycotic "fungus balls," symptomatic multiseptate mucoceles of the maxillary sinus, antrochoanal polyps that cannot be removed in their

Figure 14 (*Facing page*) Endoscopic intraoperative views during right middle meatal antrostomy. (A) View of the middle meatus showing the uncinate process. (B) An incision (*arrows*) is made at the attachment of the uncinate process. (C) The maxillary ostium (*arrow*) is visualized following the uncinectomy.

The Foundry, LLC Exhibit 2001, Page 43 of 58
Neurent Medical Inc. & Neurent Medical Ltd. v. The Foundry, LLC
IPR2024-00669

Table 4 Indications for Caldwell-Luc

Removal of mycotic "fungus balls"
Symptomatic multiseptate mucoceles of the maxillary sinus
Antrochoanal polyps
Biopsy and/or removal of neoplasms or other masses
Exposure to the pterygopalatine fossa (particularly for epistaxis control)
Oroantral fistula repair

entirety via ESS, and neoplasms (Table 4). Additionally, this procedure provides excellent exposure to the pterygopalatine fossa and can be used for closure of oroantral fistula and the biopsy of lesions within the maxillary sinus that are suspicious for malignancy (26). A relative contraindication to the procedure involves those pediatric patients with deciduous teeth because entry into the sinus by this approach may damage the permanent dentition. The advantage of this procedure is the increased exposure and access to the maxillary sinus. The disadvantages are the potential risks listed above that are associated with the procedure and the need for an external incision, which increases postoperative pain. In addition, maxillary sinus mucoceles can form several years following the procedure due to entrapment of the sinus mucosa (27).

Ethmoid Sinus Surgery

Endoscopic Endonasal Ethmoidectomy

As previously mentioned, FESS involves opening the anterior ethmoid air cells in order to improve aeration and drainage with the paranasal sinuses (ostiomeatal unit). Depending on the extent of the disease, the amount of surgery can range from opening up a single ethmoid air cell to opening every cell. The least extensive surgery involves opening the ethmoid bulla and removal of the uncinate process. Agger nasi cells, when present, are removed in patients with frontal sinusitis. Penetrating the basal lamella (insertion of the middle turbinate along the lateral nasal wall) is needed to gain access to the posterior ethmoid cells to treat disease in that area. Healthy mucosa in uninvolved ethmoid cells is preserved. Similarly, the middle turbinate is commonly preserved (Fig. 5). At times, a partial anterior–inferior middle turbinectomy is performed to reduce middle meatal adhesions and facilitate viewing of the middle meatal antrostomy in the office.

Indications for endoscopic ethmoidectomy have been already mentioned earlier in this chapter. The advantages are that there is no incision required and the patients recover quickly with minimal postoperative pain. The potential complications of the procedure were detailed earlier in the chapter. In addition, ethmoid mucoceles can form several years following

The Foundry, LLC Exhibit 2001, Page 44 of 58
Neurent Medical Inc. & Neurent Medical Ltd. v. The Foundry, LLC
IPR2024-00669

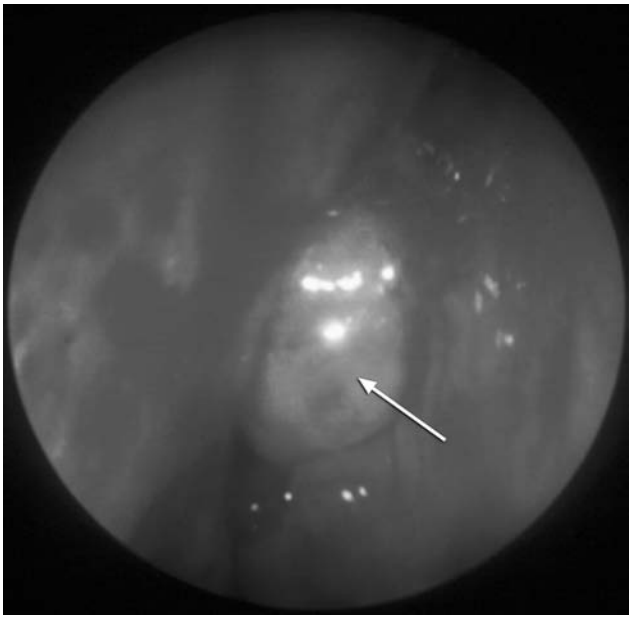

Figure 16 Endoscopic view of an ethmoid mucocele (*arrow*) in a patient with previous endoscopic ethmoidectomy.

the surgery, secondary to entrapment of sinus mucosa (Figs. 16 and 17) (28). Avoiding trauma to healthy mucosa and repeated postoperative cleaning and debridement of the ethmoid cavity can reduce the incidence of mucoceles.

External Ethmoidectomy

An external ethmoidectomy requires that a skin incision be made in order to enter the ethmoid and therefore results in an often barely perceptible scar on the lateral aspect of the nasal dorsum. This procedure takes one to two hours. As with other sinus surgeries, prophylactic perioperative antibiotics are often given. Patients are instructed to place ice over the wound for 24 hours postoperatively and sutures are removed on postoperative day 5. Intranasal postoperative care is similar to the endoscopic procedures, as are the potential complications of the procedure. Additional possible complications include medial canthal scarring and injury to the trochlea or enopthalmos if too much bone is removed (27). The main advantage of this procedure is that it provides excellent visualization and exposure of the medial orbit, ethmoid sinuses, and anterior skull base. Additionally, when the procedure is performed to treat acute ethmoiditis with periorbital abscess, a drain that can be used for irrigation of the ethmoid cavity can be placed. The main disadvantage is that it

The Foundry, LLC Exhibit 2001, Page 45 of 58
Neurent Medical Inc. & Neurent Medical Ltd. v. The Foundry, LLC
IPR2024-00669

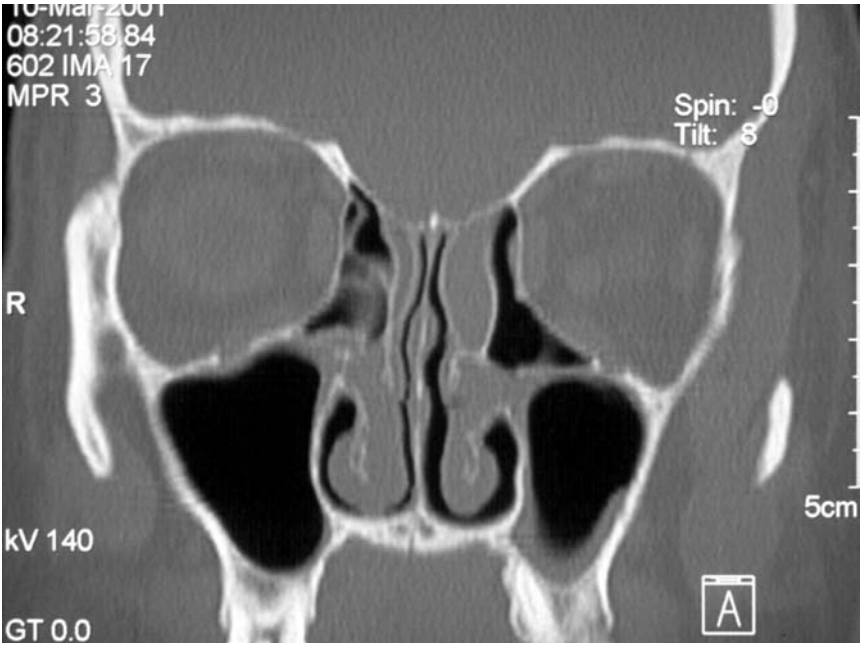

Figure 17 CT image (coronal projection) showing a left posterior ethmoid mucocele that formed five years following an endoscopic ethmoidectomy.

requires an incision, that can result in a cosmetic deformity. Additionally, the incision carries the risk of a sinocutaneous fistula.

External ethmoidectomy continues to have a role in otolaryngology. Although it no longer is used for the treatment of CRS, it is currently indicated for the treatment of acute ethmoiditis complicated by a periorbital or orbital abscess. This approach is also used for the following: for open dacrocystorhinostomy, for complete excision of ethmoid mucocele's with frontal or orbital extension, for orbital decompression or exanteration, for repair of CSF leak or anterior skull base meningo(encephalo)celes, and additionally, as an adjunctive procedure to assist with craniofacial resections and medial maxillectomies (27). Although there are no absolute contraindications to this procedure, one might argue that it is not an acceptable first-line surgical therapy for CRS given the widely available and less morbid endoscopic approaches.

Sphenoid Sinus Surgery

Endoscopic Endonasal Sphenoidotomy

Like the maxillary and ethmoid sinuses, the sphenoid sinus can be similarly opened via an endoscopic approach. The sphenoid sinus can be opened up in conjunction with an endoscopic ethmoidectomy in cases with pansinusitis.

The Foundry, LLC Exhibit 2001, Page 46 of 58
Neurent Medical Inc. & Neurent Medical Ltd. v. The Foundry, LLC
IPR2024-00669

Figure 18 Endoscopic view of a right sphenoidotomy.

On the other hand, isolated sphenoid sinus disease can be successfully treated by an endoscopic sphenoidotomy without the need for an ethmoidectomy (29). In such a case, the sphenoid ostium is accessed between the nasal septum medially, the roof of the posterior choana inferiorly, and the middle and superior turbinates laterally. The sphenoid ostium is above the level of the sinus floor and, therefore, the sphenoidotomy is enlarged in an inferior and medial direction. The posterior septum (vomer bone) and the intersinus septum may be drilled for improved drainage and access, if necessary. As is the case with sinus surgery in general, nondiseased mucosa is preserved (Fig. 18).

Indications for sphenoidotomy include sphenoid sinusitis with or without polyposis, especially in patients with symptoms of retro-orbital headaches or pressure, the removal of or marsupialization of mucoceles or mucopyeloceles, the removal of mycotic "fungus balls," or to assist neurosurgeons in their approach to removing pituitary lesions or other skull base lesions (Fig. 19). The management of these patients is the same as for other endoscopic surgeries; however, it should be noted that the internal carotid artery and the optic nerve run along the lateral and superior

The Foundry, LLC Exhibit 2001, Page 47 of 58
Neurent Medical Inc. & Neurent Medical Ltd. v. The Foundry, LLC
IPR2024-00669

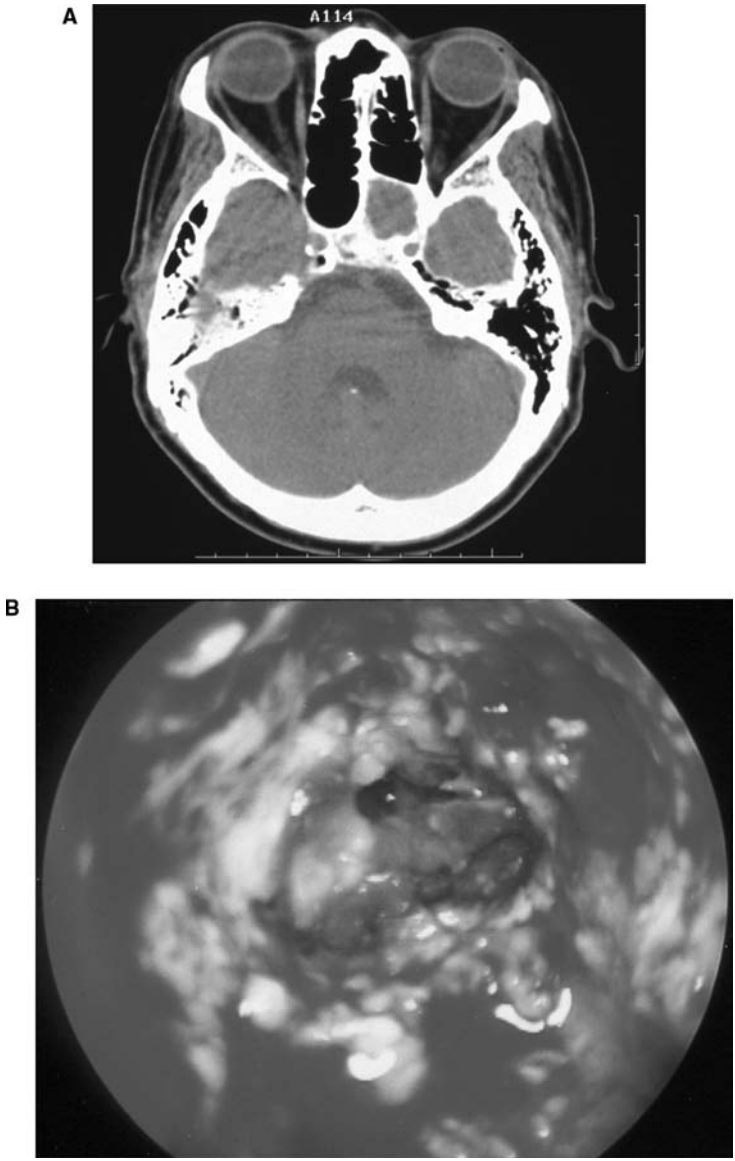

Figure 19 A patient who presented with occipital and vertex headache and was later diagnosed with chronic invasive fungal sinusitis based on the clinical presentation and histopathology. (A) CT scan (axial projection) showing a completely opacified left sphenoid sinus. (B) Intraoperative endoscopic view of the sinus cavity following sphenoidotomy. The sphenoid sinus was filled with fungal debris and hyphae.

The Foundry, LLC Exhibit 2001, Page 48 of 58
Neurent Medical Inc. & Neurent Medical Ltd. v. The Foundry, LLC
IPR2024-00669

walls of the sphenoid sinus, and either can be dehiscent. Hence, surgeons must look carefully for any bony dehiscences on CT scan and be extra cautious when working in this area. Complications of the procedure include bleeding, stenosis/closure of the sphenoidotomy, and injury to the vital structures that are in close proximity to the sinus.

External Spenoethmoidectomy

The majority of sphenoid sinus lesions can be addressed via an endoscopic approach; however, in select cases, an external sphenoethmoidectomy can be used to approach this sinus. This involves performing an external ethmoidectomy and then opening the anterior wall of the sphenoid to gain access to the sinus. This opening is then connected to the natural ostium. A middle turbinectomy is also performed for improved access. The main indication for this approach is for access to skull base tumors or repair of large defects in the skull base. Similar to an external ethmoidectomy, the main advantage of an external sphenoidotomy is that it can provide increased exposure, working room, and if necessary, can be used in conjunction with a microscope for improved visualization. The disadvantage is that it requires an external incision with its potential complications (see external ethmoidectomy).

Frontal Sinus Surgery

Trephination

Frontal sinus trephination involves making an opening in the inferior wall of the frontal sinus through an incision along the inferior aspect of the medial eyebrow. The inferior wall of the frontal sinus is devoid of bone marrow, which averts the risk of developing osteomyelitis in the setting of frontal sinusitis. The sinus cavity is then irrigated with saline or antibiotic-containing solution. The entire procedure takes less than 30 minutes. A drain may be placed for continued irrigation of the sinus. This procedure is indicated in cases of complicated acute frontal sinusitis. Additionally, it can be used in conjunction with endoscopic approaches to the frontal sinus in chronic frontal sinusitis or frontal sinus mucoceles, when the trephination is used to positively identify the frontal duct and pass a catheter through it into the nasal passage to stent it and prevent its stenosis. The main advantage to this approach is that it provides fast and easy access to the frontal sinus. It also affords the surgeon an opportunity to place a drain in the sinus for irrigation. Its main disadvantages are its associated scarring, risk of sinocutaneous fistula formation, and risk of trochlea injury that can cause diplopia.

Lynch Procedure (External Frontoethmoidectomy)

This procedure is performed via an external ethmoidectomy approach. The floor of the frontal sinus is entered. The opening is then widened to include

The Foundry, LLC Exhibit 2001, Page 49 of 58
Neurent Medical Inc. & Neurent Medical Ltd. v. The Foundry, LLC
IPR2024-00669

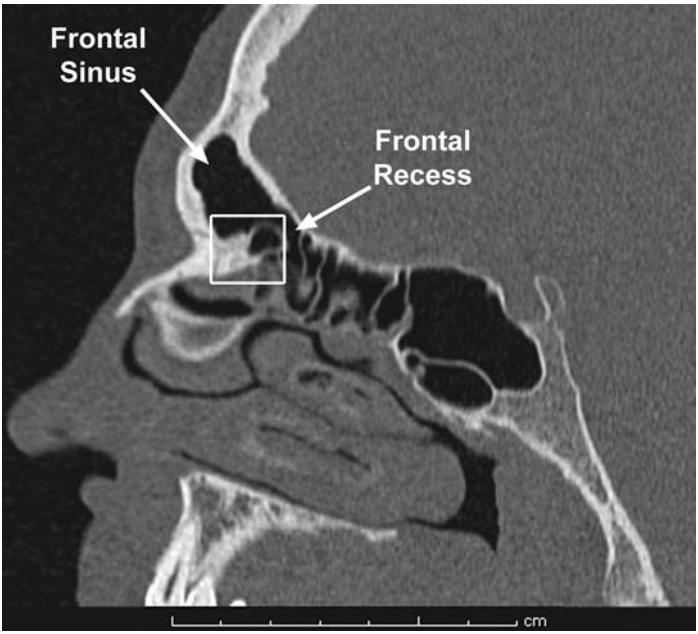

Figure 20 CT image (sagittal projection) through the frontal recess. The "white square" indicates the area that is opened during a Lynch procedure and endoscopic approaches to the frontal sinus.

the frontal duct, which is in turn enlarged to establish what is considered an adequate communication with the anterior ethmoid sinus (Fig. 20). The surgery takes one to two hours to perform and aims at achieving permanent drainage and aeration of the frontal sinus. Accordingly, it is indicated to treat symptomatic frontal sinusitis and frontal sinus muco(pyo)celes. The procedure is currently very rarely performed due to a high failure rate. The frontoethmoid opening occludes in up to 50% of cases, leading to recurrent disease and formation of frontal sinus mucoceles (30). In addition, the surgery entails an external incision with the associated cosmetic issues.

Lothrop Procedure

The Lothrop procedure was originally described as an open approach to treat chronic frontal rhinosinusitis. In this procedure, a common frontal sinus cavity and recess is created by means of removing the bone that divides the left and right sinuses as well as the floor of the frontal sinus. In addition, a portion of the superior nasal septum is resected. The surgery takes one to two hours to perform. Indications for the Lothrop procedure include the treatment of patients with recurrence of frontal sinusitis despite surgery and to remove frontoethmoid mucoceles, osteomas, or inverting papillomas.

The Foundry, LLC Exhibit 2001, Page 50 of 58
Neurent Medical Inc. & Neurent Medical Ltd. v. The Foundry, LLC
IPR2024-00669

This procedure fell out of favor because of a high incidence of restenosis with recurrence of frontal sinus disease.

Endoscopic Frontal Sinusotomy

An endoscopic anterior ethmoidectomy is first performed. The frontal recess air cells of the anterior ethmoid are opened to expose the frontal duct (Fig. 21). This area is anterior to the anterior ethmoid artery as it crosses along the roof of the ethmoid sinus and just posterior to the anterior attachment of the middle turbinate. Openings into supra-orbital ethmoid air cells can at times be confused with the frontal duct, which has a more medial and anterior location. When present, agger nasi cells are opened to widen the frontal recess (Fig. 4). What is to be done once the frontal duct is identified is controversial. Some warn against instrumentation of the duct itself since this can lead to its stenosis. For these surgeons, opening the frontal recess air cells and treating the anterior ethmoid sinus disease is adequate. On the other hand, others recommend widening the duct by either removing part of its inflamed mucosa or by drilling the bony walls anteriorly and along the floor of the frontal sinus with a long handle drill (Fig. 20).

Figure 21 Endoscopic view of the frontal duct and into the frontal sinus following endoscopic frontal sinusotomy.

The Foundry, LLC Exhibit 2001, Page 51 of 58
Neurent Medical Inc. & Neurent Medical Ltd. v. The Foundry, LLC
IPR2024-00669

In recalcitrant cases of frontal sinusitis or those with fibro-osseous stenosis of the frontal duct/recess, the floor of the frontal sinus is drilled in addition to the upper nasal septum, which may then be extended to the floor of the contralateral frontal sinus (modified Lothrop procedure) (31,32). The newly created opening is at times maintained by placing a stent for four to 12 months following the surgery (33). These cases can usually be performed in about two hours. Perioperative antibiotics are typically used, and postoperative care is similar to that of other endoscopic procedures. Indications for endoscopic frontal sinus surgery include the treatment of patients with chronic frontal sinusitis; to remove frontoethmoid mucoceles, osteomas, or inverting papillomas; or to treat recurrent disease as a salvage procedure for osteoplastic flap operation failures (see following sections) (Fig. 22) (32–36).

Most surgeons advocate performing endoscopic frontal sinus procedures with the aid of computer guidance systems (31,34,37). Even so, it should be noted that these procedures involve working extremely close to the anterior cranial fossa, medial orbit, and lacrimal sac; hence, only very experienced surgeons should perform this surgery in order to prevent complications. When they do occur, the complications are typically the same as

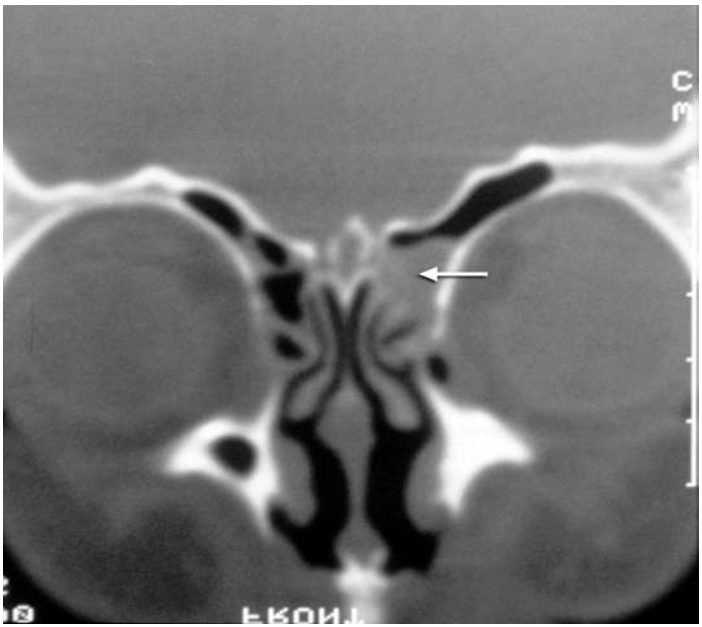

Figure 22 CT image (coronal projection) showing soft tissue opacity in the left frontal recess. This patient suffered from recurrent left frontal sinusitis and was successfully treated by an endoscopic frontal sinusotomy.

The Foundry, LLC Exhibit 2001, Page 52 of 58
Neurent Medical Inc. & Neurent Medical Ltd. v. The Foundry, LLC
IPR2024-00669

those with other endoscopic approaches. Additionally, there appears to be a high incidence of recurrent frontal sinus disease due to restenosis of the frontal recess (31,32,34–37).

Like the other endoscopic approaches, the advantages are that there is no incision required and patients recover quickly with minimal postoperative pain. The main disadvantage of the endoscopic approach is that there appears to be a higher recurrence rate with these procedures when compared to the osteoplastic frontal sinus obliteration (see following sections). The area that is opened via the endoscopic approaches, including drilling of the floor of the frontal sinus, is similar to the one opened by a Lynch or Lothrop procedure (Fig. 20). Hence, there is no reason to expect a higher success rate with the endoscopic approaches compared to the external ones. The success of the endoscopic approach should not be judged until adequate long-term follow-up is conducted, since frontal sinus mucoceles can form more than 10 years following the surgery.

Osteoplastic Frontal Sinus Obliteration

The osteoplastic frontal sinus obliteration procedure is an effective means to eradicate disease in patients who have recurrent or chronic frontal sinusitis despite attempts at improving drainage via the endoscopic route. The procedure takes about two hours. Additional indications are frontal sinus mucoceles, repair of CSF leaks originating from the posterior wall of the frontal sinus, repair of certain frontal sinus fractures, and repair of frontal sinocutaneous fistula (30,38). Its main rationale is the high failure rate of procedures that aim at opening the frontal recess/duct, hence leading to persistent symptoms and, at times, the formation of mucoceles. Therefore, the frontal sinus is obliterated to circumvent the consequences of an occluded frontal recess.

This procedure involves making a skin incision in either the scalp, the mid-forehead, or the eyebrow. The scalp incision that is made above the hairline (bicoronal incision) requires longer operative time and increases intraoperative blood loss but offers superior cosmetics. The supraciliary incision (above the eyebrow) offers more direct access to the frontal sinus and hence reduces operative time and blood loss. However, it is associated with higher incidence of scalp hypesthesia and sometimes long term pain due to transaction of the supratrochlear and supraorbital nerves. The mid-forehead incision offers a compromise. This is made along a skin crease in the forehead and, therefore, has acceptable cosmetics. It also affords direct access to the anterior wall of the sinus with a short operative time and minimal blood loss (38). The bone of the anterior wall of the frontal sinus is then carefully raised in order to open up the sinus. The mucosa of the sinus is completely removed. A large frontal sinus with extensive lateral recesses poses a challenge at removing the entire sinus mucosa. The opening of the frontal duct is then occluded with fascia or other material, such as

The Foundry, LLC Exhibit 2001, Page 53 of 58
Neurent Medical Inc. & Neurent Medical Ltd. v. The Foundry, LLC
IPR2024-00669

bone wax. Fat is harvested from the abdomen and used to obliterate the sinus cavity. The anterior bony wall is then reflected into position. Drains are placed under both the scalp and the abdomen incisions for a few days after the surgery. For this reason, patients typically stay in the hospital as inpatients until the drains come out. Perioperative antibiotics are given and there is no intranasal postoperative care. Sutures are removed within one week.

The main advantage to this procedure is that it has a low failure rate (30,38). The disadvantages are that this procedure involves a large incision and is associated with increased length of hospital stay. Permanent frontal scalp hypesthesia may develop, especially following a supraciliary incision since it may transect the supraorbital and supratrochlear nerves. Additional complications include headache, abdominal or scalp wound seroma, hematoma or abscess, headache, dural laceration, and recurrence of disease (33,37). Despite these potential complications, this is a safe and very effective procedure, when done by an experienced surgeon. However, this procedure is not indicated for patients with uncomplicated frontal sinus disease who are undergoing surgery for the first time. These patients are better served by endoscopic procedures.

ANTIBIOTIC COVERAGE IN PARANASAL SINUS SURGERY: PROPHYLACTIC AND POST SURGERY

The role of prophylactic antibiotic coverage in paranasal sinus surgery is controversial (13,14). In addition, there is a lack of consensus regarding antibiotic choice and the duration of such therapy.

It is common practice, however, to put patients on antibiotic coverage following sinus surgery for a duration ranging from 48 hours to two weeks. We recommend a 10- to 14-day course. The choice of the antibiotic is dictated by the surgical approach, nature of the disease process, likely bacteria based on published medical literature, and, when available, preoperative or intraoperative bacteriology culture results.

The chosen antibiotic should have adequate coverage against skin flora such as *Streptococcus* spp. and *S. aureus* and the likely pathogenic bacteria in the involved sinus(es) for surgery via an external approach that require a skin incision. Antibiotic coverage for anaerobic bacteria present in the oral flora is needed for transoral approaches such as Caldwell-Luc procedure. In addition, an antibiotic with demonstrated activity against nasal flora, *S. aureus*, and likely paranasal sinus pathogens is selected for endonasal approaches, both conventional and endoscopic procedures.

The antibiotic of choice should preferably have an easy administration schedule (QD or BID dosing), be well-tolerated, and be available in intravenous as well as equivalent oral formulations. Ability to cross the blood–brain barrier is essential during surgery in patients with periorbital or

The Foundry, LLC Exhibit 2001, Page 54 of 58
Neurent Medical Inc. & Neurent Medical Ltd. v. The Foundry, LLC
IPR2024-00669

intracranial complications from sinusitis or iatrogenic CSF rhinorrhea (violation of the base of the skull).

LASERS AND SINUS SURGERY

Presently, lasers have a limited role in sinus surgery. Over the years, various investigators have attempted to use lasers to aid in the eradication of sinus disease. For the most part, these attempts have been somewhat successful; however, the use of lasers is expensive and can be time-consuming. Therefore, the use of lasers has not gained widespread acceptance.

The CO_2 laser has not been found successful in the treatment of sinus disease. It has a wavelength that gets absorbed by water, and its thermal energy is concentrated with very little spread to the surrounding soft tissues. The principle difficulties in applying the CO_2 laser to sinus disease treatment is that it requires a relatively dry field for hemostasis, it results in significant smoke accumulation, and most importantly, its mid-infrared light cannot travel through a fiberoptic cable. Thus, tissues must be visualized directly in order to be treated with the CO_2 laser (39).

In contrast, the Nd:YAG, KTP/532, Argon, and Ho:YAG lasers can be carried through fiberoptic cables. Fiberoptic threads can be passed into instruments, that are designed for intranasal use. Hence, the instruments that transmit the laser energy can be handled manually and placed directly onto tissues with ease and precision. Each of these has advantages and disadvantages related to depth of penetration, scatter of thermal energy, and their ability to coagulate small blood vessels. These lasers have been used to treat inferior turbinate hypertrophy with moderate success (39). They can also be used to remove nasal lesions, such as nasal papillomata, pyogenic granuloma, and other small superficial lesions (40).

A common application of laser technique is the treatment of hereditary hemorrhagic telangiectasias. This is an autosomal-dominant disease characterized by telangiectatic lesions primarily in mucosalized areas, such as the nose, mouth, and gastrointestinal tract. These patients often suffer from severe bouts of epistaxis throughout their lives. The Nd:YAG and KTP/532 lasers have each been used successfully to ablate these lesions (39–43). Patients often require retreatment, however, every four to six months. Ho:YAG laser with its capability to vaporize bone has been used in intranasal endoscopic dacryocystorhinostomy. It did not gain widespread popularity since it does not offer any significant advantage over using cold instruments to justify the added cost and operative time.

CONCLUSION

Paranasal sinus surgery has several indications; the most common is CRS that failed medical therapy. The approach and extent of surgery is dictated

The Foundry, LLC Exhibit 2001, Page 55 of 58
Neurent Medical Inc. & Neurent Medical Ltd. v. The Foundry, LLC
IPR2024-00669

by the nature of the disease and the involved sinuses. Endoscopic approaches that are made possible with the technological advances in fiberoptics have gained widespread use. They offer a minimally invasive technique that has a low morbidity and high success rate for treating inflammatory paranasal sinus pathology. The surgery is not risk free, however. Image guidance systems can make the surgery safer. Surgery is often an adjunct to medical therapy. A better understanding of the pathogenesis of rhinosinusitis allows for better delineation of the role of medical therapy and surgery.

REFERENCES

1. Kennedy DW, Zinreich SJ, Rosenbaum AE, Johns ME. Functional endoscopic sinus surgery. Theory and diagnostic evaluation. Arch Otolaryngol 1985; 111:576–582.
2. Rice DH. Indications for endoscopic sinus surgery. Ear Nose Throat J 1994; 73:461–464, 466.
3. Messerklinger W. Background and evolution of endoscopic sinus surgery. Ear Nose Throat J 1994; 73:449–450.
4. Stammberger H. The evolution of functional endoscopic sinus surgery. Ear Nose Throat J 1994; 73:451, 454–455.
5. Vining EM, Kennedy DW. The transmigration of endoscopic sinus surgery from Europe to the United States. Ear Nose Throat J 1994; 73:456–458, 460.
6. Kennedy DW. Functional endoscopic sinus surgery. Technique. Arch Otolaryngol 1985; 111:643–649.
7. Messerklinger W. On the drainage of the normal frontal sinus of man. Acta Otolaryngol 1967; 63:176–181.
8. Stammberger H, Hasler G. Functional Endoscopic Sinus Surgery: The Messerklinger Technique. St Louis, MO: Mosby, 1991.
9. Catalano PJ. Minimally invasive sinus technique: what is it? Should we consider it? Curr Opin Otolaryngol Head Neck Surg 2004; 12:34–37.
10. Kieff DA, Busaba NY. Non-dental related isolated chronic maxillary sinus opacification does not correlate with ipsilateral intranasal structural abnormalities. Ann Otol Rhinol Laryngol 2004; 113:474–476.
11. Taylor MJ, Ponikau JU, Sherris DA, Kern EB, Gaffey TA, Kephart G, Kita H. Detection of fungal organisms in eosinophilic mucin using a fluorescein-labeled chitin-specific binding protein. Otolaryngol Head Neck Surg 2002; 127: 377–383.
12. Ferguson BJ. Categorization of eosinophilic chronic rhinosinusitis. Curr Opin Otolaryngol Head Neck Surg 2004; 12:237–242.
13. Annys E, Jorissen M. Short term effects of antibiotics (Zinnat) after endoscopic sinus surgery. Acta Otorhinolaryngol Belg 2000; 54(1):23–28.
14. Hasselgren PO, Ivarsson L, Risberg B, Seeman T. Effects of prophylactic antibiotics in vascular surgery. A prospective, randomized, double-blind study. Ann Surg 1984 Jul; 200(1):86–92.
15. Gross CW, Gross WE. Post-operative care for functional endoscopic sinus surgery. Ear Nose Throat J 1994; 73:476–479.

16. Stankiewicz JA. Complications of endoscopic sinus surgery. Otolaryngol Clin North Am 1989; 22:749–758.
17. Parikh SR, Fried MP. Navigational systems for sinus surgery: new developments. J Otolaryngol 2002; 31(suppl 1):S24—S27.
18. Metson R. Image-guided sinus surgery: lessons learned from the first 1000 cases. Otolaryngol Head Neck Surg 2003; 128:8–13.
19. Metson R, Gliklich RE, Cosenza M. A comparison of image guidance systems for sinus surgery. Laryngoscope 1998; 108(8 Pt 1):1164–1170.
20. Fried MP, Kleefield J, Gopal H, Reardon E, Ho BT, Kuhn FA. Image-guided endoscopic surgery: results of accuracy and performance in a multicenter clinical study using an electromagnetic tracking system. Laryngoscope 1997; 107:594–601.
21. Selivanova O, Kuehnemund M, Mann WJ, Amedee RG. Comparison of conventional instruments and mechanical debriders for surgery of patients with chronic sinusitis. Am J Rhinol 2003; 17:197–202.
22. Bernstein JM, Lebowitz RA, Jacobs JB. Initial report on postoperative healing after endoscopic sinus surgery with the microdebrider. Otolaryngol Head Neck Surg 1998; 118:800–803.
23. Busaba NY, Salman SD. Maxillary sinus mucoceles: clinical presentation and long-term results of endoscopic surgical treatment. Laryngoscope 1999; 109:1446–1449.
24. Busaba NY, Kieff DA. Endoscopic sinus surgery for inflammatory maxillary sinus pathology. Larynogoscope 2002; 112:1378–1383.
25. Goodman WS. The Caldwell-Luc procedure. Otolaryngol Clin North Am 1976; 9:187–195.
26. Schaefer SD, Gustafson RO, Bansberg SF. Sinus surgery. In: Bailey BJ, Calhoun KH, eds. Head and Neck Surgery—Otolaryngology. 3rd ed. Philadelphia, PA: Lippincott Williams and Wilkins, 2001:359–370.
27. Weber R, Keerl R, Draf W. Endonasal endoscopic surgery of maxillary sinus mucoceles after Caldwell-Luc operation. Laryngorhinootologie 2000; 79: 532–535.
28. Busaba NY, Salman SD. Ethmoid mucocele as a late complication of endoscopic ethmoidectomy. Otolaryngol Head Neck Surg 2003; 128:517–522.
29. Kieff DA, Busaba NY. Treatment of isolated sphenoid sinus inflammatory disease by endoscopic sphenoidotomy without ethmoidectomy. Laryngoscope 2002; 112:2186–2188.
30. Hardy JM, Montgomery WW. Osteoplastic frontal sinusotomy: an analysis of 250 operations. Ann Otol Rhinol Laryngol 1976; 85(4 Pt 1):523–532.
31. Wormald PJ, Ananda A, Nair S. Modified endoscopic Lothrop as a salvage for the failed osteoplastic flap with obliteration. Laryngoscope 2003; 113: 1988–1992.
32. Stankiewicz JA, Wachter B. The endoscopic modified Lothrop procedure for salvage of chronic frontal sinusitis after osteoplastic flap failure. Otolaryngol Head Neck Surg 2003; 129:678–683.
33. Neal DG. External ethmoidectomy. Otolaryngol Clin North Am 1985; 18:55–60.
34. Kountakis SE, Gross CW. Long-term results of the Lothrop operation. Curr Opin Otolaryngol Head Neck Surg 2003; 11:37–40.

The Foundry, LLC Exhibit 2001, Page 57 of 58
Neurent Medical Inc. & Neurent Medical Ltd. v. The Foundry, LLC
IPR2024-00669

35. Gross CW, Harrison SE. The modified Lothrop procedure: indications, results, and complications. Otolaryngol Clin North Am 2001; 34:133–137.
36. Casiano RR, Livingston JA. Endoscopic Lothrop procedure: the University of Miami experience. Am J Rhinol 1998; 12:335–339.
37. Samaha M, Cosenza MJ, Metson R. Endoscopic frontal sinus drillout in 100 patients. Arch Otolaryngol Head Neck Surg 2003; 129:854–858.
38. Montgomery WW. State-of-the-art for osteoplastic frontal sinus operation. Otolaryngol Clin North Am 2001; 34:167–177.
39. Rathfoot CJ, Duncavage J, Shapshay SM. Laser use in the paranasal sinuses. Otolaryngol Clin North Am 1996; 29:943–948.
40. Shah RK, Dhingra JK, Shapshay SM. Hereditary hemorrhagic telangiectasia: a review of 76 cases. Laryngoscope 2002; 112:767–773.
41. Parkin JL, Dixon JA. Laser photocoagulation in hereditary hemorrhagic telangiectasia. Otolaryngol Head Neck Surg 1981; 89:204–208.
42. Levine HL. Lasers in endonasal surgery. Otolaryngol Clin North Am 1997; 30:451–455.
43. Levine HL. Endoscopy and the KTP/532 laser for nasal sinus disease. Ann Otol Rhinol Laryngol 1989; 98(1 Pt 1):46–51.