STEDMAN'S MEDICAL DICTIONARY

28th Edition

Cala Health Ex. 1013
Cala v. EMKinetics
USP 10,786,669

ILLUSTRATED IN COLOR



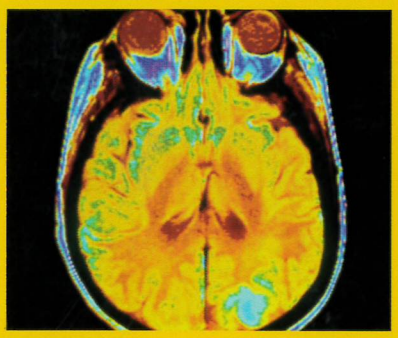

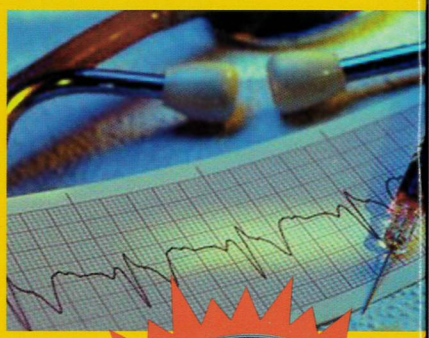



Bonus CD-ROM Inside

(see back cover for details)

SEP 26 2011

STEDMAN'S Medical Dictionary

28th Edition

Illustrated in Color

Registrau

KNOBBE, MARTENS, OLSON & BEAR, LLP
2040 MAIN ST.
14TH FLOOR
IRVINE, CA 92614

STEDMAN'S Medical Dictionary

28th Edition

Illustrated in Color

SEP 26 2011

Registration

KNOBBE, MARTENS, OLSON & BEAR, LLP
2040 MAIN ST.
14TH FLOOR
IRVINE, CA 92614

Publisher: Julie K. Stegman
Senior Product Manager: Eric Branger
Associate Managing Editor: Tiffany Piper
Marketing Manager: Yvonne Palmer
New Terms Editor: Thomas W. Filardo, MD
Etymology Editor: John H. Dirckx, MD
Chief Copyeditor: Raymond Lukens
Copyeditors: Ellen Atwood, Vincent Ercolano, Ellen Erkess, Linda Searing
Pronunciations Editor: William R. Hensyl
On-Line Editors: Barbara L. Ferretti, Kathryn J. Cadle, Lisa Fahnestock
Proofreaders: Richard Diamanti, Raymond Lukens, Kristi Lukens, Jeff Prucher, Linda C. Robbian
Database Programmers: Dave Marcus, Lexi-Comp Inc., Hudson, OH
Art Director: Jennifer Clements
Illustrations: Neil O. Hardy
Additional artwork by: Mary Anna Barratt Dimes, Kathryn Born, Rob Duckwall, Timothy Hengst, Mikki Senkarik, Michael Schenk, Larry Ward
Graphic Artist: Susan Caldwell
Typographic Design: Parkton Art Studio, Inc.

Copyright © 2006
Lippincott Williams & Wilkins
A Wolters Kluwer Health Company
351 West Camden Street
Baltimore, Maryland 21201-2436 USA
www.stedmans.com
stedmans@lww.com

Copyright © by William Wood and Company: 1911, 1st ed.; 1912, 2nd ed.; 1914, 34 ed.; 1916, 4th ed.; 1918, 5th ed.; 1920, 6th ed.; 1922, 7th ed.; 1924, 8th ed.; 1926, 9th ed.; 1928, 10th ed.; 1930, 11th ed.

Copyright © by Williams & Wilkins: 1933, 12th ed; 1935, 13th ed.; 1939, 14th ed.; 1942, 15th ed.; 1946, 16th ed.; 1949, 17th ed.; 1953, 18th ed.; 1957, 19th ed.; 1961, 20th ed.; 1966, 21st ed.; 1972, 22nd ed.; 1976, 23rd ed.; 1982, 24th ed.; 1990, 25th ed.; 1995, 26th ed.

Copyright © by Lippincott Williams & Wilkins: 2000, 27th ed.

All rights reserved. This book and software are protected by copyright. No part of this book or software may be reproduced in any form or by any means, including photocopying, or utilized by any information storage and retrieval system without written permission from the copyright owner.

Stedman's, STEDMAN'S is a registered trademark of Lippincott Williams & Wilkins.

The publisher is not responsible (as a matter of product liability, negligence or otherwise) for any injury resulting from any material contained herein. This publication contains information relating to general principles of medical care which should not be construed as specific instructions for individual patients. Manufacturers' product information and package inserts should be reviewed for current information, including contraindications, dosages and precautions.

Database design by Lexi-Comp Inc. Hudson, OH
Printed in the United States of America by Quebecor World

Library of Congress Cataloging-in-Publication Data
Stedman, Thomas Lathrop, 1853-1938.
Stedman's medical dictionary. —28th ed.
p. ; cm.
Includes bibliographical references and index.
ISBN 0-7817-3390-1 (alk. paper)
1. Medicine--Dictionaries. I. Title. II. Title: Medical dictionary.
[DNLM: 1. Medicine--Dictionary--English. W 13 S812m 2006]
R121.S8 2006
610'.3--dc22

2005021544

05 06 07 08 09
1 2 3 4 5

SEE ALSO antinion. SYN intercilium. [L. *glabellus,* hairless, smooth, dim. of *glaber*]

gla·bel·lad (glă-bel′ad). Toward the glabella.

gla·brous, gla·brate (glā′brŭs, glā′brāt). Smooth or hairless; denoting areas of the body where hair does not normally grow, i.e., palms or soles. [L. *glaber,* smooth]

glad·i·ate (glad′ē-āt). SYN xiphoid. [L. *gladius,* a sword]

gla·di·o·lus (glă-dī′ō-lŭs, glad′ē-ō′lŭs). *Although the correct pronunciation is* gladi′olus, *the word is often pronounced* gladio′lus *in the U.S.* SYN *body* of sternum. [L. dim. of *gladius,* a sword]

GLAND

gland (gland) [TA]. An organized aggregation of cells functioning as a secretory or excretory organ. See this page. SYN glandula (1) [TA]. [L. *glans,* acorn]

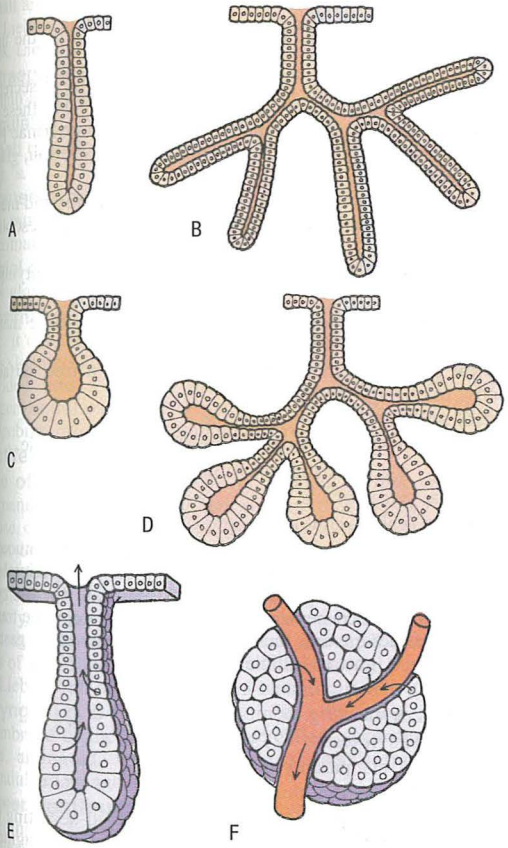

Types of **glands:** (A) tubular, (B) compound tubular, (C) acinous, (D) compound acinous, (E) exocrine, (F) endocrine

accessory g., a small mass of glandular structure, detached from but lying near another and larger g., to which it is similar in structure and probably in function.

accessory lacrimal g.'s [TA], small, compound, branched, tubular g.'s located sometimes in the middle part of the lid (Wolfring g.'s, 1872, or Ciaccio g.'s, 1874) or along the superior and inferior fornices of the conjunctival sac (Krause g.'s, 1854). These accessory g.'s are ectopic portions of the lacrimal g. tissue; all produce the same kind of tears, secreting onto the conjunctival surface. Henle and Baumgarten "glands" are in fact not g.'s at all, but mere epithelial invaginations. SYN glandulae lacrimales accessoriae [TA].

accessory parathyroid g. [TA], an additional (or detached portion of a) parathyroid g., resulting in at least five but usually many more glandular units. SYN glandula parathyroidea accessoria [TA].

accessory parotid g. [TA], an occasional islet of parotid tissue separate from the mass of the g., lying anteriorly just above the commencement of the parotid duct. SYN glandula parotidea accessoria [TA], admaxillary g., glandula parotis accessoria, socia parotidis.

accessory suprarenal g.'s [TA], isolated, often minute, masses of suprarenal tissue sometimes found near the main g.'s or in the broad ligament or the epididymis. SYN glandulae suprarenales accessoriae [TA].

accessory thyroid g. [TA], an isolated mass, or one of several such masses, of thyroid tissue, sometimes present in the side of the neck, or ranging in position from just superior to the hyoid bone (suprahyoid accessory thyroid g.) to the arch of the aorta inferiorly. SYN glandula thyroidea accessoria [TA], accessory thyroid, prehyoid g., suprahyoid g., thyroidea accessoria, thyroidea ima, Wölfler g.

acid g., one of the gastric g.'s that secretes the hydrochloric acid of the gastric juice. SYN oxyntic g.

acinotubular g., SYN tubuloacinar g.

acinous g., a g. in which the secretory unit(s) has a grapelike shape and a very small lumen; e.g., the exocrine part of the pancreas.

admaxillary g., SYN accessory parotid g.

adrenal g., SYN suprarenal g.

aggregate g.'s, SYN aggregated lymphoid *nodules* of the small intestine, under *nodule.*

agminate g.'s, agminated g.'s, SYN aggregated lymphoid *nodules* of the small intestine, under *nodule.*

Albarran g.'s (ahl′bah-rahn), minute submucosal g.'s or branching tubules in the subcervical region of the prostate g., emptying for the most part into the posterior portion of the urethra. SYN Albarran y Dominguez tubules.

albuminous g., a g. that secretes a watery fluid.

alveolar g., a g. in which the secretory unit(s) has a saclike form and an obvious lumen; e.g., the active mammary gland.

anal g., **(1)** one of a number of large sudoriferous g.'s in the mucous membrane of the anus; **(2)** an incorrect synonym for anal sac. **(3)** paired g.'s located at approximately the 4- and 8-o'clock positions when animal's anus is viewed from behind, present in dogs and cats. These small round saccular glands are located in the subcutis and produce an odoriferous oily discharge that likely serves to mark territory. They are connected to the terminal anus by a narrow bore tube; may become infected, impacted, abscessed, or neoplastic. Problems are more common in obese, constipated, or inactive animals.

anterior lingual g., a small mixed g. deeply placed near the apex of the tongue on each side of the frenulum. SYN apical g., Bauhin g., Blandin g., glandula lingualis anterior, Nuhn g.

apical g., SYN anterior lingual g.

apocrine g., a g. with a secretory product that includes an apical portion of the secretory cell (e.g., secretion of lipid droplets in lactation).

apocrine sweat g.'s, sudoriferous g.'s that develop in association with hair follicles and undergo enlargement and secretory development at puberty; they secrete a viscous, odorless sweat that supports bacteria growth leading to production of an acrid odor; secretion is by a merocrine, not apocrine, mechanism. SYN axillary sweat g.'s.

areolar g.'s [TA], a number of larger sebaceous g.'s forming small rounded projections (i.e., areolar tubercles) from the surface of the areola of the breast; they enlarge during pregnancy and during lactation secrete a substance presumed to provide resistance to chapping. SYN glandulae areolares [TA], Montgomery follicles, Montgomery g.'s.

arteriococcygeal g., SYN coccygeal *body.*

arytenoid g.'s, mucosal g.'s in the region of the arytenoid cartilages of the larynx. SEE laryngeal g.'s. SYN glandula arytenoidea.

cally follows a caudally directed course during development (e.g., testis) to descend or to follow the normal course.

mal·di·ges·tion (mal′dī-jes′chŭn). Imperfect digestion.

Mal·do·na·do-San Jo·se stain (mahl-dō-nah′dō san hō-zā′). See under stain.

male (māl). **1.** In zoology, denoting the sex to which those belong that produce sperms; a person of that sex. **2.** SYN masculine. [L. *masculus,* fr. *mas,* male]

genetic human m., (**1**) an individual with a karyotype containing a Y chromosome; (**2**) an individual whose cell nuclei do not contain Barr sex chromatin bodies, which are normally present in females. Patients with ambiguous sexual development and those with Turner syndrome are classed as genetic m.'s or genetic females according to the absence or presence of Barr bodies even though their sex chromosome complement may suggest otherwise.

XX m., a clear male phenotype in the presence of a 46,XX karyotype; presumably the vital parts of the Y chromosome are located elsewhere in the genome as a result of translocation at least in some affected persons.

XXY m., SEE Klinefelter *syndrome.*

XYY m., SEE XYY *syndrome.*

Mal·e·cot (mal-ĕ-kō′), Achille-Etienne, 19th-century French surgeon. SEE Malecot *catheter.*

ma·le·ic ac·id (mă-lē′ik as′id). Butenedioic acid; used for preparing maleate salts. SYN toxilic acid.

mal·e·mis·sion (mal-′ē-mish′ŭn). Failure to eject semen from the penis at orgasm. [mal- + L. *e-mitto,* pp. *missus,* to send out]

mal·e·rup·tion (mal′ē-rŭp′shŭn). Faulty eruption of teeth.

mal·e·yl·ac·e·to·ac·e·tate (mal′ē-il-as′ē-tō-as′ĕ-tāt). An intermediate in L-phenylalanine and L-tyrosine catabolism; accumulates in certain inherited disorders of tyrosine metabolism.

m. *cis-trans*-isomerase, an enzyme that catalyzes the reversible conversion of m. to 4-fumarylacetoacetate; an enzyme that participates in L-tyrosine catabolism; a deficiency of this enzyme is associated with tyrosinemia type IB.

mal·for·ma·tion (mal′fōr-mā′shŭn). Failure of proper or normal development; more specifically, a primary structural defect that results from a localized error of morphogenesis; e.g., cleft lip. Most m.'s are considered to be a defect of a morphogenetic or developmental field that responds as a coordinated unit to embryonic interaction. Cf. deformation.

Arnold-Chiari m. (ar′nŏld kē-ah′rē) [MIM*207950], malformed posterior fossa structures associated with caudad traction and displacement of the rhombencephalon as caused by tethering of the spinal cord; may be accompanied in some cases by spina bifida and associated anomalies such as meningomyelocele; usually multifactorial in inheritance. SYN Arnold-Chiari deformity, Arnold-Chiari syndrome, cerebellomedullary malformation syndrome.

arteriovenous m.'s (AVM), (**1**) vessels through which blood is shunted from arterioles to venules without passing through the capillaries. The term "arteriovenous anastomosis" is widely used, but not preferred, because the connection is between arterioles and venules rather than arteries and veins. (**2**) any improper or abnormal development related to arteries or veins. SYN arteriolovenular anastomoses [TA].

cystic adenomatoid m., a rare developmental lung-bud abnormality that results in stillbirth, acute progressive respiratory disease of newborns, or protracted childhood pneumonias; combines features of a hamartoma, dysplastic growth, and tumorous growth. Three types have been described, based chiefly on cyst diameters: Type I: up to 10 cm; Type II: less than 1.2 cm; and Type III: less than 0.5 cm.

dancer's foot m., SYN ballerina-foot *pattern.*

ductal plate m., M. consisting of congenital hepatic fibrosis with probable autosomal recessive inheritance. SEE ALSO dysencephalia splanchnocystica.

mermaid m., SYN sirenomelia.

Michel m. (mē-shel′), hypoplasia of the petrous pyramid and aplasia of the inner ear.

venous m., (rarely used). SYN venous *angioma.*

mal·func·tion (mal-fŭnk′shŭn). Disordered, inadequate, or abnormal function.

Mal·gai·gne (mahl-gān′), Joseph F., French surgeon, 1806–1865. SEE Malgaigne *amputation;* Malgaigne *fossa;* M. *hernia;* Malgaigne *luxation;* Malgaigne *triangle.*

Mal·her·be (mahl-ārb′ĕ), Albert, 1845–1915. SEE Malherbe calcifying *epithelioma.*

mal·ic ac·id (mal′ik as′id). Hydroxysuccinic acid; found in apples and various other tart fruits; an intermediate in the tricarboxylic acid cycle, and the glyoxylate cycle, and in the malate-aspartate shuttle system. SYN monohydroxysuccinic acid.

mal·ic ac·id de·hy·dro·gen·ase (mal′ik as′id dē′hī-drō′jen-ās). SYN *malate* dehydrogenase.

mal·ic de·hy·dro·gen·ase (mal′ik dē′hī-drō′jen-ās). SYN *malate* dehydrogenase.

ma·lig·nan·cy (mă-lig′nant-sē). The property or condition of being malignant.

ma·lig·nant (mă-lig′nănt). **1.** Resistant to treatment; occurring in severe form, and frequently fatal; tending to become worse and leading to an ingravescent course. **2.** In reference to a neoplasm, having the property of locally invasive and destructive growth and metastasis. [L. *maligno,* pres. p. *-ans* (*ant-*), to do anything maliciously]

ma·lin·ger (mă-ling′gĕr). To engage in malingering.

ma·lin·ger·er (mă-ling′gĕr-ĕr). One who engages in malingering.

ma·lin·ger·ing (mă-ling′gĕr-ing). Feigning illness or disability to escape work, excite sympathy, or gain compensation. [Fr. *malingre,* poor, weakly]

mal·in·ter·dig·i·ta·tion (mal′in-tĕr-dij′i-tā′shŭn). Faulty intercuspation of teeth.

Mall (mahl), Franklin Paine, U.S. anatomist and embryologist, 1862–1917. SEE M. *formula, ridges,* under *ridge;* periportal *space* of M.

mal·le·a·ble (mal′ē-ă-bŭl). Capable of being shaped by being beaten or subjected to pressure; a property of certain metals such as gold and silver. [L. *malleus,* a hammer]

mal·le·brin (mal′e-brin).

mal·le·o·in·cu·dal (mal′ē-ō-ing′kū-dăl). Relating to the malleus and the incus in the tympanum.

mal·le·o·lar (mă-lē′ō-lăr). Relating to one or both malleoli.

mal·le·o·lus, pl. **mal·le·o·li** (ma-lē′ō-lŭs, -lī) [TA]. *Avoid the mispronunciation* malleo′lus. A rounded bony prominence such as those on either side of the ankle joint. [L. dim. of *malleus,* hammer]

external m., SYN lateral m.

inner m., SYN medial m.

internal m., SYN medial m.

lateral m. [TA], the process at the lateral side of the lower end of the fibula, forming the projection of the lateral part of the ankle; the lateral malleolus extends farther inferiorly than the medial m. SYN m. lateralis [TA], external m., extramalleolus, outer m.

m. lateralis [TA], SYN lateral m.

medial m. [TA], the process at the medial side of the lower end of the tibia, forming the projection of the medial side of the ankle; the medial m. lies superior to the level of the lateral m. SYN m. medialis [TA], inner m., internal m.

m. medialis [TA], SYN medial m.

outer m., SYN lateral m.

mal·le·ot·o·my (mal′ē-ot′ŏ-mē). Division of the malleus. [malleus + G. *tomē,* incision]

mal·le·us, gen. and pl. **mal·lei** (mal′ē-ŭs, mal′ē-ī) [TA]. The largest of the three auditory ossicles, resembling a club rather than a hammer; it is regarded as having a head, below which is the

the acuity of distant vision; the letters vary in size in such a way that each one subtends a visual angle of 5′ at a particular distance.

tetan-. SEE tetano-.

te·tan·ic (te-tan′ik). *Avoid the mispronunciation* tet′anic. Relating to or marked by a sustained muscular contraction, as in tetanus. [G. *tetanikos*]

te·tan·i·form (te-tan′i-fōrm). SYN tetanoid (1).

tet·a·nig·e·nous (tet′ă-nij′ĕ-nŭs). Causing tetanus or tetaniform spasms. [tetanus + G. *-gen,* producing]

tet·a·nism (tet′ă-nizm). SYN neonatal *tetany.*

tet·a·ni·za·tion (tet′ă-ni-zā′shŭn). **1.** The act of tetanizing the muscles. **2.** A condition of tetaniform spasm.

tet·a·nize (tet′ă-nīz). To stimulate a muscle by a rapid series of stimuli so that the individual muscular responses (contractions) are fused into a sustained contraction; to cause tetanus (q.v. [2]) in a muscle.

tetano-, tetan-. Combining forms denoting tetanus, tetany. [G. *tetanos,* convulsive tension]

tet·a·noid (tet′ă-noyd). **1.** Resembling or of the nature of tetanus. SYN tetaniform. **2.** Resembling tetany. [tetano- + G. *eidos,* resemblance]

tet·a·nol·y·sin (tet′ă-nol′i-sin). A hemolytic principle, elaborated by *Clostridium tetani,* which seems to have no role in the etiology of tetanus.

tet·a·nom·e·ter (tet′ă-nom′ĕ-tĕr). An instrument for measuring the force of tonic muscular spasms. [tetano- + G. *metron,* measure]

tet·a·no·mo·tor (tet′ă-nō-mō′tŏr). An instrument by means of which tonic spasms are produced by the mechanical irritation of a hammer striking the motor nerve of the muscle affected. [tetano- + L. *motor,* a mover]

tet·a·no·spas·min (tet′ă-nō-spaz′min). The neurotoxin of *Clostridium tetani,* which causes the characteristic signs and symptoms of tetanus; chief action is on the anterior horn cells, and the spasms seem to be due to action at inhibitory synapses.

tet·a·no·toxin (tet′ă-nō-tok′sin). SYN tetanus *toxin.* [tetano- + G. *toxikon,* poison]

tet·a·nus (tet′ă-nŭs). *Avoid the misspelling/mispronunciation* tetnus. *Do not confuse this word with* tetany. **1.** A disease marked by painful tonic muscular contractions, caused by the neurotropic toxin (tetanospasmin) of *Clostridium tetani* acting on the central nervous system. Cf. lockjaw, trismus. **2.** A sustained muscular contraction caused by a series of nerve stimuli repeated so rapidly that individual muscular responses are fused, producing a sustained tetanic contraction. SEE emprosthotonos, opisthotonos. See page C9. [L. fr. G. *tetanos,* convulsive tension]

acoustic t., experimental t. induced by a faradic current, the speed of which is estimated by the pitch of the vibrations.

cephalic t., a type of local tetanus that follows wounds to the face and head; after a brief incubation (1–2 days) the facial and ocular muscles become paretic yet undergo repeated tetanic spasms. The throat and tongue muscles may also be affected. SYN cerebral t.

cerebral t., SYN cephalic t.

complete t., t. in which stimuli to a particular muscle are repeated so rapidly that decrease of tension between stimuli cannot be detected.

drug t., tonic spasms caused by strychnine or other tetanic agent. SYN toxic t.

generalized t., the most common type of t., often with trismus as its initial manifestation; the muscles of the head, neck, trunk, and limbs become persistently contracted, and then painful paroxysmal tonic contractions (tetanic seizures) are superimposed; the high mortality rate (50%) is due to asphyxia or cardiac failure.

incomplete t., t. (2) in which each stimulus causes a contraction to be initiated when the muscle has only partly relaxed from the previous contraction.

local t., the most benign type of t.; the muscles in close proximity to an infected wound develop persistent involuntary contractions, often with transient, intense superimposed spasms triggered by various stimuli. The more distal upper extremity muscles are most often affected; gradual but complete recovery is typical.

neonatal t., SYN t. neonatorum.

t. neonatorum, t. occurring in newborn infants, usually due to infection of umbilical area with *Clostridium tetani,* often a result of ritualistic practices; has high fatality rate (about 60%). SYN neonatal t.

postpartum t., SYN puerperal t.

puerperal t., t. occurring during the puerperium from infection of the obstetric wound. SYN postpartum t., uterine t.

Ritter opening t. (rit′ĕr), the tetanic contraction that occasionally occurs when a strong current, passing through a long stretch of nerve, is suddenly interrupted.

toxic t., SYN drug t.

traumatic t., t. after infection of a wound.

uterine t., SYN puerperal t.

tet·a·ny (tet′ă-nē). *Do not confuse this word with* tetanus. A clinical neurologic syndrome characterized by muscle twitches, cramps, and carpopedal spasm, and when severe, laryngospasm and seizures; these findings reflect irritability of the central and peripheral nervous systems, usually resulting from low serum levels of ionized calcium or, less commonly, magnesium. Causes include hyperventilation, hypoparathyroidism, rickets, and uremia. [G. *tetanos,* tetanus]

t. of alkalosis, t. due to a loss of acid from the body or an increase in alkali, resulting in a reduction of ionized calcium in plasma and body fluids, e.g., hyperventilation t. (loss of CO_2), gastric t. (loss of HCl by vomiting), or injection or ingestion of excessive amounts of sodium bicarbonate.

gastric t., t. associated with a gastric disorder, especially with loss of HCl by vomiting.

grass t., SYN grass *staggers.*

hyperventilation t., t. caused by forced overbreathing, due to a reduction in CO_2 in the blood.

hypoparathyroid t., SYN parathyroid t.

infantile t., t. of infants occurring usually in association with rickets, due to dietary deficiency of vitamin D.

manifest t., t. from any cause in which neuromuscular hyperexcitability is clearly evident, as opposed to latent t. SYN symptomatic t.

neonatal t., hypocalcemic t. occurring in neonates or young infants, due to transient functional hypoparathyroidism in consumption of cow's milk (high phosphorus content). SYN myotonia neonatorum, tetanism.

parathyroid t., t. due to lack of parathyroid function, spontaneous or following excision of the parathyroid glands. SYN hypoparathyroid t., parathyroprival t.

parathyroprival t., SYN parathyroid t.

phosphate t., t. due to the ingestion of an excess of alkaline phosphates (Na_2HPO_4 or K_2HPO_4); most commonly produced experimentally in animals by the injection of alkaline phosphate, which reduces the ionized calcium of the blood.

postoperative t., parathyroid t. caused by injury to or excision of the parathyroids during procedures in the neck.

symptomatic t., SYN manifest t.

tetra-. Four. [G. *tetra-,* four]

tet·ra·a·me·li·a (tet′ră-ă-mē′lē-ă). Absence of upper and lower limbs. [tetra- + G. *a-* priv. + *melos,* limb]

tet·ra·ba·sic (tet′ră-bā′sik). Denoting an acid having four acid groups and thereby being able to neutralize 4 Eq of base.

tet·ra·bor·ic ac·id (tet′ră-bōr′ik as′id). Perboric or pyroboric acid. SYN pyroboric acid.

tet·ra·bra·chi·us (tet′ră-brā′kē-ŭs). A person with four upper limbs. [tetra- + G. *brachiōn,* arm]

tet·ra·bro·mo·phe·nol·phthal·ein so·di·um (tet′ră-brō′mō-fē′nol-thal′ēn sō′dē-ŭm). The sodium salt of a brominated dye; it was used early in the development of cholecystography.