ADVANCED LAPAROSCOPY

Edited by **Ali Shamsa**

ENDYMED EXHIBIT 1023 - 1/12
EndyMed v Serendia
IPR2024-00842

Advanced Laparoscopy
http://dx.doi.org/10.5772/1545
Edited by Ali Shamsa

Contributors

Maria Aponte-Rueda, Ramón Saade-Cárdenas, Salvador Navarrete-Aulestia, Mohamed Amin El Gohary, Rajendra Nerli, Mallikarjun Reddy, Murigendra Hiremath, Ngozi Nwokoma, Ricardo Robles, Miguel F. Herrera, Hugo Sánchez, Seong Kuk Yoon, Junji Ueda, Hitoshi Ichimiya, Masao Tanaka, Masao Endo, Miwako Nakano, Toshihiko Watanabe, Michinobu Ohno, Fumiko Yoshida, Etsuji Ukiyama, Tulun Ozturk, Ali Shamsa, Stjepan Visnjic, Ahmed Khairi, Paul Sugarbaker, Terence Chua, David Lawson Morris, Tristan Yan, dan arbell, Armon Yaron

© The Editor(s) and the Author(s) 2011
The moral rights of the and the author(s) have been asserted.
All rights to the book as a whole are reserved by INTECH. The book as a whole (compilation) cannot be reproduced, distributed or used for commercial or non-commercial purposes without INTECH's written permission.
Enquiries concerning the use of the book should be directed to INTECH rights and permissions department (permissions@intechopen.com).
Violations are liable to prosecution under the governing Copyright Law.

Individual chapters of this publication are distributed under the terms of the Creative Commons Attribution 3.0 Unported License which permits commercial use, distribution and reproduction of the individual chapters, provided the original author(s) and source publication are appropriately acknowledged. If so indicated, certain images may not be included under the Creative Commons license. In such cases users will need to obtain permission from the license holder to reproduce the material. More details and guidelines concerning content reuse and adaptation can be foundat http://www.intechopen.com/copyright-policy.html.

Notice

Statements and opinions expressed in the chapters are these of the individual contributors and not necessarily those of the editors or publisher. No responsibility is accepted for the accuracy of information contained in the published chapters. The publisher assumes no responsibility for any damage or injury to persons or property arising out of the use of any materials, instructions, methods or ideas contained in the book.

First published in Croatia, 2011 by INTECH d.o.o.
eBook (PDF) Published by IN TECH d.o.o.
Place and year of publication of eBook (PDF): Rijeka, 2019.
IntechOpen is the global imprint of IN TECH d.o.o.
Printed in Croatia

Legal deposit, Croatia: National and University Library in Zagreb

Additional hard and PDF copies can be obtained from orders@intechopen.com

Advanced Laparoscopy
Edited by Ali Shamsa
p. cm.
ISBN 978-953-307-674-4
eBook (PDF) ISBN 978-953-51-6510-1

This material may be protected by Copyright law (Title 17 U.S. Code)

10

Radiofrequency Ablation of Renal Cell Carcinoma: A Systematic Review

Seong Kuk Yoon
Dong-A University College of Medicine
Republic of Korea

1. Introduction

The widespread use of abdominal cross-sectional imaging such as computed tomography (CT) and magnetic resonance imaging (MRI) has resulted in a significant rise in the frequency of incidentally detected renal masses (Mouraviev et al., 2006). Most tumors are small and localized renal tumors have been shown to be of a very early clinical stage. It is estimated that in 2009, 57,760 new cases of kidney caner will be diagnosed and 12,980 patients will die of the disease in the United States (American Cancer Society, 2009). Nephron-sparing surgery such as partial nephrectomy remains the gold standard in patients with small renal cell carcinomas (RCCs), with oncologic outcomes similar to the use of a radical nephrectomy (Bandi et al., 2008). However, both open and laparoscopic partial nephrectomy are associated with a significant complication rate and laparoscopic partial nephrectomy is also associated with a significant learning curve, increased warm ischemia time, and a higher morbidity rate as compared with open partial nephrectomy (Gill et al., 2003). Many cases with incidentally detected small renal tumors are found in elderly patients with significant comorbidities, and these patients may not be good surgical candidates. Therefore, several investigators have utilized a variety of energy-based tissue-ablative technologies such as radiofrequency (RF) ablation, cryoablation, high-intensity focused ultrasound, microwave thermotherapy, and interstitial photon irradiation as alternative treatment options of small renal masses (McAchran et al., 2005). Among these minimally invasive ablative techniques, RF ablation and cryoablation are the most commonly utilized methods and have been extensively studied. For short-term results, cryoablation (4.6% tumor-persistent disease and complication rate of 10.6%) is considered better than RF ablation (7.9% and 13.9%, respectively) (Weld & Landman, 2005). However, there are no prospective comparative studies to suggest that cryoablation is more effective than RF ablation for the treatment of small RCCs. RF ablation has several advantages with a superior relationship between the RF-probe diameter and the volume of ablated tissue (Mahnken et al., 2005). RF ablation also provides many potential benefits, including a low complication rate, reduced morbidity, shorter hospital stay, absence of an ischemic period, possible conscious sedation, less expensive than surgery, and the ability to avoid the higher risk of surgical resection in elderly patients (Lotan & Cadeddu, 2005; Mouraviev et al., 2006; Park et al., 2007). Furthermore, RF ablation may minimize destruction of normal renal tissue and thus minimizes removal of functional nephrons (Mylona et al., 2009). For the intermediate term, the oncologic outcomes of RF ablation appear comparable to that of

partial nephrectomy for small, early stage RCCs (Stern et al., 2007). However, long-term data is still lacking.

2. Mechanism

High-frequency, alternating electric current produced by the RF generator is delivered to target tissues through an electrode. RF current returns to the generator via grounding pads and thereby completes the electrical circuit. Deposition of RF energy results in molecular friction and heat production, leading to membrane disruption, protein denaturation, vascular thrombosis, and ultimately, coagulation necrosis. Thermal damage is dependent on both the tissue temperature achieved and the duration of heating. Heating tissue to 50°C to 55°C for 4 to 6 minutes produces irreversible cell injury. At temperatures between 60°C and 100°C, near-immediate coagulation necrosis is induced. At 110°C, tissue vaporizes and carbonizes (McAchran et al., 2005; Zagoria, 2004a).

3. Patient selection: Indications and contraindications

Indications for RF ablation include significant comorbidities making the patient a high surgical risk, pre-existing renal insufficiency, advanced age, life expectancy of more than 1 year but less than 10 years, a solitary kidney, patients who refuse surgery, or multifocal RCC, such as in patients with von Hippel-Lindau disease or familial RCC (Gervais et al., 2005b; McAchran et al., 2005). The only absolute contraindications include irreversible coagulopathy or acute and severe medical instability, such as sepsis (Zagoria, 2004a).

4. Techniques

4.1 Equipment: RF systems and electrodes

RF generators are either temperature-based or impedance-based systems. A temperature-based system (RITA Medical Systems, Mountain View, CA, USA) monitors tissue temperature by the use of thermocouples at the needle tips and determines completion of treatment when the tissue adjacent to the probe has reached a target temperature for a predetermined duration of time. Impedance-based systems (Radionics, Burlington, MA, USA; RadioTherapeutics, Sunnyvale, CA, USA; CelonPOWER System, Teltow, Germany) measure the impedance of the surrounding tissue of the electrode and RF energy is delivered until the impedance exceeds a critical level (Anderson et al., 2005; Desai & Gill, 2002). To the best of our knowledge, there are no comparative clinical studies showing a clear advantage for the use of each system. All of these generators modulate the amount of electrical current delivered to the electrode. If too much RF energy is provided too quickly, charring occurs immediately surrounding the electrode. This charring highly increases the resistance of the tissue and does not allow delivery of the electric current into the tissue. Thus, ablated zones are decreased in size and results are less reproducible (Anderson et al., 2005). There is a variety of electrodes: single versus multiple tined probes versus cluster, and wet versus dry versus cooled-tip probes. However, there are no randomized comparative clinical studies for the electrode types.

4.2 Guidance and approaches

RF ablation is performed under ultrasound (US), CT, or MR guidance for exact targeting of the electrode within renal tumors. Most investigators prefer CT guidance that allows

accurate placement of the electrode. Although US provides widespread availability, real-time imaging, absence of ionizing radiation, low cost capabilities, and portability, US has some limitations for guiding electrodes. (Fig. 1, US-guided radiofrequency ablation.) In some cases, it is difficult to visualize lesions due to a lack of innate tissue conspicuity or overlying bony structures or gas-containing bowel structures. During US-guided RF ablation, a tumor surrounding the electrode becomes centrifugally hyperechogenic secondary to microbubble formation in the ablated tissue. Thus, it may be difficult to appreciate the difference between tumor tissue and normal tissue. Such acoustic changes may increase the difficulty to reposition the probe for further treatment. For renal RF ablation, CT has some advantages, including superior anatomic delineation, easy visualization of small tumors, absence of obscuring artifacts after ablation, and intravenous contrast enhancement to determine the adequacy of ablation (Zagoria, 2004a). (Fig. 2, CT-guided radiofrequency ablation.)

RF ablation can be performed via open, laparoscopic, or percutaneous approach. Open RF ablation is rarely used in clinical practice. Laparoscopic RF ablation performed under general anesthesia is typically used for anterior and medial tumors or for tumors in close proximity to the ureter, renal hilum, or adjacent organs. Percutaneous RF ablation can be performed under conscious sedation or general anesthesia (Anderson, 2005; Carraway et al.,

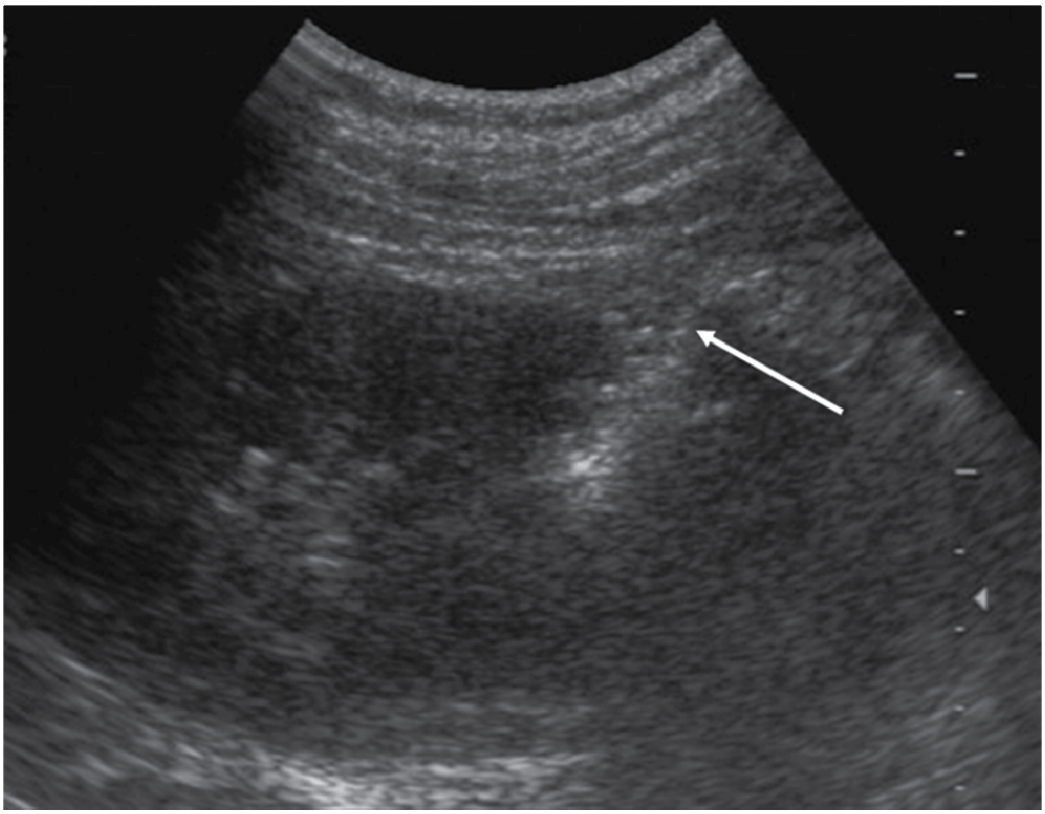

Fig. 1. US-guided radiofrequency. US image shows a echogenic electrode within the tumor (arrow).

Fig. 2. CT-guided radiofrequency ablation. Unenhanced CT scan shows a targeted electrode within the tumor (arrow).

2009). Meta-analysis has shown that a percutaneous RF ablation procedure is safer and as equally effective as compared with an open or laparoscopic approach, although more than one treatment session may be needed to treat renal tumors completely (Hui et al., 2008).

4.3 Pre-RF ablation biopsy

There is no consensus on the value of performing a percutaneous biopsy prior to ablation of renal tumors. A pre-ablation biopsy is not required for treatment and a biopsy should be performed at the preference of the surgeon (Anderson et al., 2005). However, a biopsy is recommended if it is expected that the biopsy results will have an impact on patient treatment and follow-up imaging planning (Zagoria, 2004a).

ENDYMED EXHIBIT 1023 - 6/12

4.4 Imaging follow-up

Immediate follow-up imaging on postoperative day one or two is generally unnecessary and can cause misinterpretation, as the presence of periablation enhancement suggestive of reactive hyperemia may mimic the presence of a residual viable tumor on contrast-enhanced imaging (Carraway et al., 2009). Follow-up CT examinations are performed at 1 month, 3 and 6 months, and then every 6 months thereafter in our institution. However, the timing of follow-up imaging studies varies among institutions and the optimal interval time remains to be determined (Gervais et al., 2005a).

4.5 Outcomes

4.5.1 Therapeutic efficacy

Treatment success for RF ablation is assessed by postprocedural imaging, and is typically assessed by CT imaging or MR imaging at least 1 month after treatment. Imaging immediately after the procedure can be difficult to interpret because periablation inflammation may mimic the appearance of a residual viable tumor (Hines-Peralta & Goldberg, 2004). A definition of complete coagulation necrosis and thus a completely ablated tumor after RF ablation is the absence of enhancement on CT or MR images. Enhancement (> 10 HU or > 15% with CT and MR imaging, respectively) of any portion of the tumor is considered a residual viable tumor. Recurrence is defined as new enhancement that develops after CT or MR images have been interpreted to show complete necrosis (Gervais et al., 2005b; Zagoria, 2004a). Effectiveness is defined by the proportion of tumors without residual enhancement after one treatment session (i.e., primary effectiveness) or after repeated treatments (i.e., secondary effectiveness) (Hui et al., 2008). In our series, 17 RCCs in 16 patients were subjected to RF ablation treatment. The mean tumor size was 2.2 cm (range, 1.6-5.0 cm) and all tumors were in an exophytic location. The mean follow-up period was 23.8 months (range, 17-33 months). During the radiological follow-up period, 13 tumors of 12 patients were successfully treated in one ablation session and 4 tumors of 4

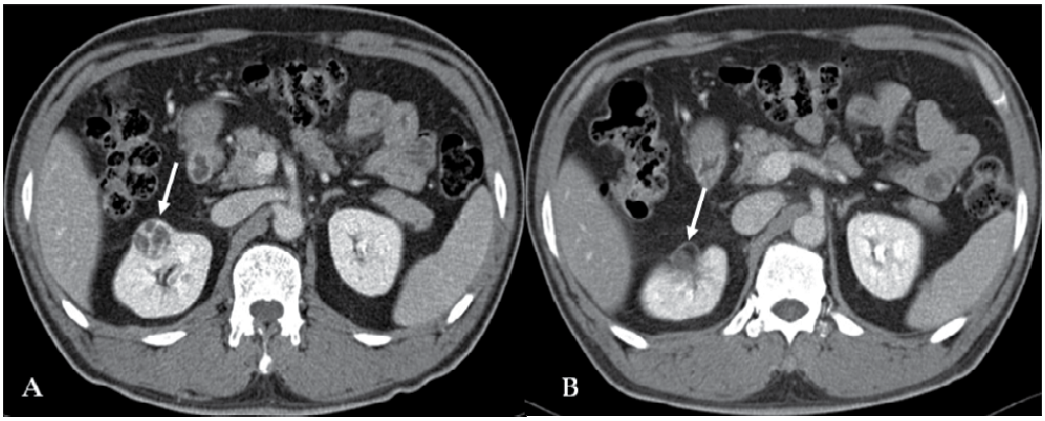

Fig. 3. Radiofrequency ablation of renal cell carcinoma. A. Contrast-enhanced CT scan shows low attenuated, exophytic tumor (arrow) with multiple, irregularly enhancing septa in the right kidney. B. Two-year follow-up contrast-enhanced CT scan after radiofrequency ablation treatment shows no intratumoral enhancement with decreased tumor size and peritumoral halo (arrow), suggesting complete ablation and no recurrence.

patients required more than one session on the basis on follow-up CT. (Fig. 3, Radiofrequency ablation of renal cell carcinoma.) One tumor required 3 sessions based on areas of persistent enhancement within the tumor. In addition, 7 tumors of 7 patients required electrode repositions, as the tumor size was too large. Technical success and technical effectiveness were achieved in all cases (100%). Local recurrence was not detected in any of the cases. On follow-up CT, all tumors showed a variable degree of size reduction (mean diameter, 0.6 cm; range, 0.2-1.7 cm) in comparison with pretreatment CT. No metastases developed in the patients during the follow-up period.

Successful rates for complete RF ablation of small renal tumors have ranged from 82% to 100% in recent series. Gervais *et al.* demonstrated that in 85 patients (100 renal tumors) who underwent percutaneous RF ablation, small (≤ 3 cm) peripheral tumors were completely ablated with 100% success; however, larger tumors (3-5 cm and > 5 cm) were ablated with 92% and 25% success rates, respectively (Gervais et al., 2005b). Zagoria *et al.* showed data on 125 RCCs in 104 patients who underwent percutaneous RF ablation. The tumor size ranged from 0.6 cm to 8.8 cm (mean size, 2.7 cm). Of 125 renal tumors, 116 (93%) tumors were completely ablated with a mean follow-up interval of 13.8 months (Zagoria et al., 2007). McDougal *et al.* presented outcomes of 16 patients with biopsy proven RCCs with greater than 4-year follow-up. These investigators showed successful outcomes in exophytic masses smaller than 5 cm. Twelve (92.3%) of the 13 tumors treated had no evidence of disease (McDougal et al., 2005). Levinson *et al.* reported data with the longest follow-up to date (61.6 months). A total of 31 patients received 34 RF ablation treatments. Tumor sizes ranged from 1.0 cm to 4.0 cm (median size, 2.0 cm). The overall recurrence-free survival rate was 90.3%. There was a 100% metastasis-free rate and disease specific survival rate in the cohort of patients. The overall patient survival was 71.0% (Levinson et al., 2008).

4.5.2 Complications

Complications are classified as major or minor based on the classification of the Society of Interventional Radiology with major complications requiring treatment or hospitalization and minor complications needing only conservative monitoring (Gervais et al., 2005a). In general, the overall complication rates of RF ablation have been reported from 2.8% to 17.6% with the majority of complications being minor complications (Carraway et al., 2009). The most common complication is hemorrhage (Gervais et al., 2005b). (Fig. 4, Perinephric hematoma.)

Major complications include superficial liver laceration, significant blood loss, congestive heart failure, conversion to open surgery, hemorrhage leading to nephrectomy, pulmonary embolism, myocardial infarction, pancreatic injury requiring surgery, ureteropelvic junction obstruction, ureteropelvic junction injury requiring nephrectomy, urine leakage, pneumonia, pelvic vein thrombosis, hematuria with significant blood clots and urinary obstruction, persistent muscle weakness, ureteric thermal injury requiring stent insertion, persistent urinoma, proximal ureteral stricture, cutaneous–urinary fistula, colon–nephric fistula, colon injury, and needle tract seeding. Minor complications include perirenal hematoma, transient hematuria, wound infection, postoperative ileus, hydronephrosis, wound separation, probe site pain or paresthesia, infection, an increased serum creatinine level, and transient neuropathy (Hui et al., 2008).

ENDYMED EXHIBIT 1023 - 8/12

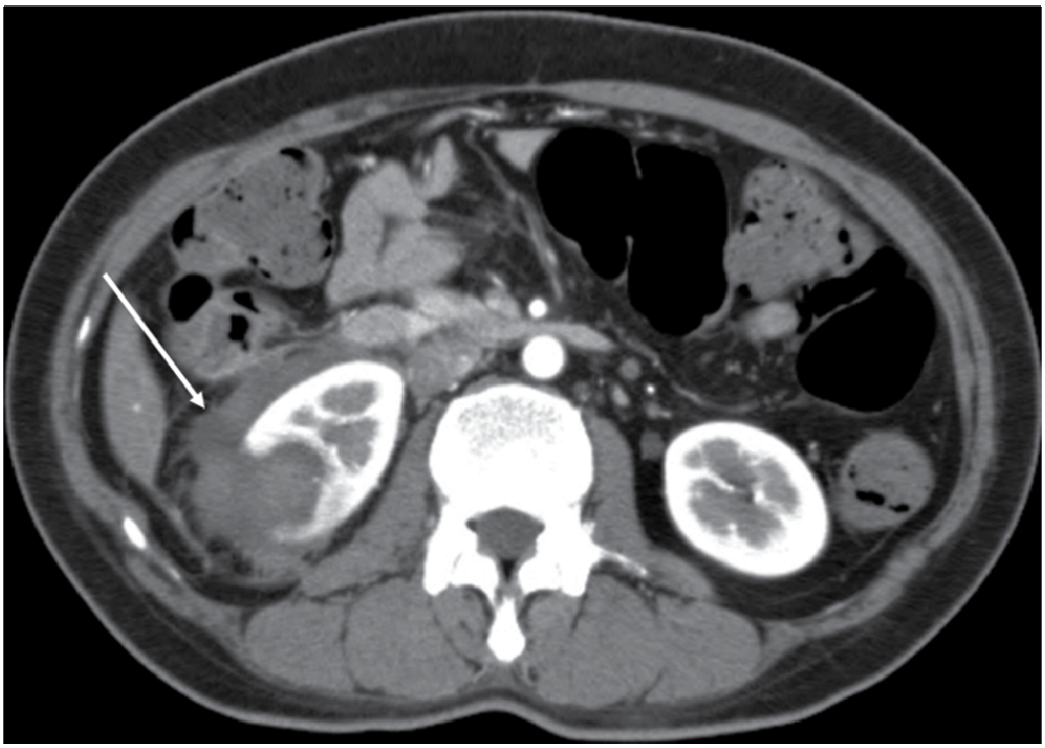

Fig. 4. Perinephric hematoma. Contrast-enhanced CT scan shows hematoma (arrow) in the right perinephric space after radiofrequency ablation treatment.

5. Factors influencing successful ablation

Tumor size and location are the two most important factors that determine whether RCCs can be treated successfully. Zagoria *et al*. found that the major determinant of successful RF ablation was tumor size. There was no correlation between the success of ablation and tumor location, histology, and the presence of renal disease (Zagoria et al., 2004b). A recent series showed that RF ablation could be reliably performed to treat RCCs smaller than 3.7 cm (Zagoria et al., 2007). However, upper size limits for consideration of renal tumors for RF ablation have not been determined. Various investigators have set this limit from 2.5 cm to 4.0 cm. (Gervais et al., 2005b). Despite advances in electrode design, successful ablation of tumors greater than 4 cm in diameter has been challenging. However, larger tumors require multiple overlapping ablations (Park et al., 2008). The location of the tumor can also influence the success of RF ablation. Even large exophytic tumors are usually treated successfully. However, central tumor ablation fails more frequently because of a heat sink effect where regional vascular flow reduces the extent of the thermally induced coagulation (Yoon et al., 2009). Gervais *et al.* found that both a small size and noncentral location are independent significant predictors of complete necrosis after a single ablation session, based on the use of multivariate analysis (Gervais et al., 2005b). The gauge and configuration of the electrode tip, intensity and length of the current, duration of energy applied, and certain characteristics of the tissue that is being ablated determine the extent of tissue ablation. Optimization of these factors is mandatory for success of RF ablation (McAchran et al., 2005).

6. Perspective

Many clinical and experimental studies have reported promising short and intermediate-term outcomes with RF ablation for the treatment of small renal tumors. However, multi-institutional, high volume, long-term follow-up data on cancer-specific survival are not as yet available and such data are required before RF ablation can be considered as a standard of management. A further prospective or a randomized trial comparing RF ablation with nephron-sparing surgery such as a partial nephrectomy is needed. Optimal techniques to perform RF ablation for renal tumors are still evolving. We are awaiting further studies on factors that influence successful ablation. Additionally, future trials should also use standard terminology. Further studies for RF ablation will likely aim to alleviate existing shortcomings by the improvement of imaging and guidance, by increasing the size of the ablation zone, and by improving performance for problematic cases.

7. Conclusion

Although nephron-sparing surgery such as laparoscopic partial nephrectomy must remain standard therapy for patients with small, localized RCCs, RF ablation for the treatment of RCC is a very promising technique that should be considered as a treatment option for patients with small renal tumors who are not good surgical candidates. For indications, RF ablation can be applied successfully for the treatment of refractory hematuria resulting from RCC, for local recurrence of RCC, and for isolated metastases from RCC (Zagoria, 2004a). RF ablation is increasingly performed and the use of RF ablation has become widespread due to comparable encouraging short and intermediate-term outcomes and a relatively low incidence of major complications. However, critical use of this procedure is emphasized until more long-term follow-up results are available. Although a number of controversies currently remain, we believe that image-guided RF ablation is a safe and effective treatment option with a very low complication rate for small exophytic renal tumors in selected patients.

8. References

American Cancer Society. (2009) Cancer Facts and Figures 2009. Available from: < www.cancer.org/downloads/STT/ 500809web.pdf>

Anderson J, Matsumoto E, & Cadeddu J. (2005) Renal radiofrequency ablation: technique and results. *Urol. Oncol.*, Vol.23, No.5, pp. 355-360

Bandi G, Hedican S, & Nakada S. (2008) Current practice patterns in the use of ablation technology for the management of small renal masses at academic centers in the United States. *Urology,* Vol. 71, No.1, pp. 113-117

Carraway W, Raman J, & Cadeddu J. (2009) Current status of renal radiofrequency ablation. *Curr. Opin. Urol.*, Vol.19, No2, pp. 143-147

Desai M, & Gill I. (2002) Current status of cryoablation and radiofrequency ablation in the management of renal tumors. *Curr. Opin, Urol.*, Vol.12, pp. 387-393

Gervais D, Arellano R, McGovern F, McDougal W, & Mueller P. (2005) Radiofrequency ablation of renal cell carcinoma: part 2, lessons learned with ablation of 100 tumors. *Am. J. Roentgenol.*, Vol.185, No.1, pp. 72-80

ENDYMED EXHIBIT 1023 - 10/12

Gervais D, McGovern F, Arellano R, McDougal W, & Mueller P. (2005) Radiofrequency ablation of renal cell carcinoma: part 1, indications, results, and role in patient management over a 6-year period and ablation of 100 tumors. *Am. J. Roentgenol.,* Vol.185, No.1, pp. 64-71

Gill I, Matin S, Desai M, Kaouk J, Steinberg A, Mascha E, Thornton J, Sherief M, Strzempkowski B, & Novick A. (2003) Comparative analysis of laparoscopic versus open partial nephrectomy for renal tumors in 200 patients. *J. Urol.,* Vol.170, pp. 64-68

Hines-Peralta A, & Goldberg S. (2004) Review of radiofrequency ablation for renal cell carcinoma. *Clin. Cancer Res.,* Vol.15, No.10, pp. 6328s-6334s

Hui G, Tuncali K, Tatli S, Morrison P, & Silverman S. (2008) Comparison of percutaneous and surgical approaches to renal tumor ablation: metaanalysis of effectiveness and complication rates. *J. Vasc. Interv. Radiol.,* Vol.19, No.9, pp. 1311-1320

Levinson A, Su L, Agarwal D, Agarwal D, Sroka M, Jarrett T, Kavoussi L, & Solomon S. (2008) Long-term oncological and overall outcomes of percutaneous radio frequency ablation in high risk surgical patients with a solitary small renal mass. *J. Urol.,* Vol.180, No.2, pp. 499-504

Lotan Y, & Cadeddu J. (2005) A cost comparison of nephron-sparing surgical techniques for renal tumour. *BJU Int.,* Vol.95, pp. 1039-1042

Mahnken A, Rohde D, Brkovic D, Günther R, & Tacke J. (2005) Percutaneous radiofrequency ablation of renal cell carcinoma: preliminary results. *Acta Radiol.,* Vol.46, No.2, pp. 208-214

McAchran S, Lesani O, & Resnick M. (2005) Radiofrequency ablation of renal tumors: past, present, and future. *Urology,* Vol.66, No.5A, pp. 15-22

McDougal W, Gervais D, McGovern F, & Mueller P. (2005) Long-term followup of patients with renal cell carcinoma treated with radio frequency ablation with curative intent. *J. Urol.,* Vol.74, No.1, pp. 61-63

Mouraviev V, Joniau S, Van Poppel H, & Polascik T. (2006) Current status of minimally invasive ablative techniques in the treatment of small renal tumours. *Eur. Urol.,* Vol.51, No.2, pp. 328-336

Mylona S, Kokkinaki A, Pomoni M, Galani P, Ntai S, & Thanos L. (2009) Percutaneous radiofrequency ablation of renal cell carcinomas in patients with solitary kidney: 6 years experience. *Eur. J. Radiol.,* Vol.69, No.2, pp. 351-356

Park S, Cadeddu J, & Shingleton W. (2007) Oncologic outcomes for ablative therapy of kidney cancer. *Curr. Urol. Rep.,* Vol.8, No.1, pp. 31-37

Park S, Yoon S, Cho J, Oh J, Nam K, Kwon H, Kim S, Kang M, Choi S, & Sung G. (2008) Radiofrequency ablation treatment for renal cell carcinoma: early clinical experience. *Korean J. Radiol.,* Vol.9, No.4, pp. 340-347

Stern J, Svatek R, Park S, Hermann M, Lotan Y, Sagalowsky A, & Cadeddu J. (2007) Intermediate comparison of partial nephrectomy and radiofrequency ablation for clinical T1a renal tumours. *BJU Int.,* Vol.100, No.2, pp. 287-290

Weld K, & Landman J. (2005) Comparison of cryoablation, radiofrequency ablation and high-intensity focused ultrasound for treating small renal tumours. *BJU Int.,* Vol.96, pp. 1224-1229

Yoon S, Choi J, Cho J, Oh J, Nam K, Jung S, Kwon H, Kim D, & Rha S. (2009) Radiofrequency ablation of renal VX2 tumors with and without renal artery occlusion in a rabbit

model: feasibility, therapeutic efficacy, and safety. *Cardiovasc. Intervent. Radiol.,* Vol.32, pp. 1241-1246

Zagoria R. (2004) Imaging-guided radiofrequency ablation of renal masses. *RadioGraphics,* Vol.24(Suppl. 1), pp. S59-S71

Zagoria R, Hawkins A, Clark P, Hall M, Matiaga B, Dyer R, & Chen M. (2004) Percutaneous CT-guided radiofrequency ablation of renal neoplasms: factors influencing success. *Am. J. Roentgenol.,* Vol.183, pp. 201-207

Zagoria R, Traver M, Werle D, Perini M, Hayasaka S, & Clark P. (2007) Oncologic efficacy of CT-guided percutaneous radiofrequency ablation of renal cell carcinomas. *Am. J. Roentgenol.,* Vol.189, No.2, pp. 429-436

ENDYMED EXHIBIT 1023 - 12/12