Budesonide for the Treatment of Obstructive Eosinophilic Jejunitis

Orales Budesonid zur Behandlung der obstruktiven eosinophilen Jejunitis

Authors C. Elsing[1], J. Placke[2], W. Gross-Weege[1]

Affiliations
[1] Departments of Gastroenterology and Surgery, St. Elisabeth-Krankenhaus Dorsten, Germany
[2] Institute of Pathology and Cytology, Dinslaken, Germany

Schlüsselwörter
- eosinophile Enteritis
- Therapie
- verzögert freigesetztes Budesonid

Key words
- eosinophilic enteritis
- treatment
- delayed release budesonide

Zusammenfassung

Die eosinophile Gastroenteritis ist eine seltene Erkrankung des Gastrointestinaltraktes mit unbekannter Ursache und einer eosinophilen Infiltration der Darmwand. Das klinische Bild richtet sich nach den betroffenen Wandschichten. Wir beschreiben einen männlichen Patienten mit eosinophiler Infiltration der Muscularis propria mit konsekutiver Obstruktion. Die Diagnose konnte nach chirurgischer Resektion gestellt werden. Ein Rückfall wurde kurzzeitig mit intravenösen Steroiden und im Verlauf mit oralem Budesonid für drei Monate behandelt. Die Behandlung war effektiv und zeigte keine Nebenwirkungen.

Abstract

Eosinophilic gastroenteritis is a rare gastrointestinal (GI) disorder of undetermined origin, characterized by infiltration of eosinophils in the GI tract. Different layers of the bowel wall can be involved and the clinical outlook depends on the area affected. Our subject is a male patient in whom the disease involves the muscular layer causing obstructive jejunitis. The diagnosis was made after surgical resection. A relapse was subsequently treated with short-term intravenous steroids followed by oral budesonide for three months. Treatment was effective with no apparent side effects.

Introduction

Eosinophilic jejunitis is a rare disorder characterised by eosinophilic infiltration of different layers of the bowel wall [1]. Like Crohn's disease it can involve any area of the gastrointestinal tract. A definitive diagnosis must fulfil the following criteria: a) GI symptoms are present, b) eosinophilic infiltration of one or more areas of the GI tract, c) eosinophilic involvement of multiple organs of the GI tract is not present and d) parasitic infection is absent. Peripheral blood eosinophilia and food intolerance or allergy are not necessary for a correct diagnosis. The clinical features are intermittent but may be long-standing, sometimes possibly for more than 30 years. Clinical symptoms include abdominal pain, nausea, vomiting, diarrhoea, weight loss and intestinal obstruction with an acute abdomen. Establishing the diagnosis is important as therapy with systemic steroids is effective and patients with bowel obstruction respond dramatically.
Budesonide is a new form of steroid therapy and is productive in different forms of inflammatory bowel diseases [2]. To the present day no patient with obstructive eosinophilic jejunitis and treatment with budesonide has been recorded. In the following we describe a patient with several episodes of intestinal obstruction due to eosinophilic infiltration and successful treatment with oral budesonide.

Case Report

The 64-year-old male patient was admitted to our hospital in September 2005 with signs of intestinal obstruction. He complained about abdominal pain and had been vomiting with increasing frequency for the last three days. No history of food allergy or other allergies were reported. On physical examination the abdomen was distended and slightly painful. Laboratory counts showed normal values for the red and white blood cells, no signs of eosinophilia, the ESR was 4 mm/h, CRP was 0.17 mg/dL and all other values for liver, kidney and pancreas functions were normal. In an abdominal ultrasound scan a 10-cm swollen small bowel segment with signs of obstruction was

reveiced 15.7.2006
accepted 3.9.2006

Bibliography
DOI 10.1055/s-2006-927138
Z Gastroenterol 2007; 45: 187 – 189 © Karl Demeter Verlag im Georg Thieme Verlag KG Stuttgart · New York ·
ISSN 0044-2771

Correspondence
Christoph Elsing, MD
Department of Gastroenterology, St. Elisabeth-Hospital
Pf.-W.-Schmitz-Straße 1
46282 Dorsten
Germany
Tel.: ++49/2 36/2 29 27 44
Fax: ++49/2 36/29 21 70 44
c.elsing@krankenhaus-dorsten.de

Dr. Falk Pharma Ex. 1013
IPR Petition - USP 8,771,729

Fig. 1 Abdominal CT scan revealed a segment of bowel wall thickening (8 mm) in the left upper abdomen (arrow).

Fig. 2 Intraoperative appearance of the small bowel with segmental enlargement prior to resection.

identified, there were no signs of ascites. This was confirmed by a CT scan (**Fig. 1**). An upper endoscopy revealed slight inflammation of the gastric mucosa and antral flat erosions. The duodenum appeared normal. Histology showed slight inflammation and an antibody test against H. pylori was positive. The patient received i.v. fluids, proton pump inhibitors and antibiotics. During the day the obstructive symptoms with pain and vomiting increased, the stool movement ceased and we decided for an explorative laparotomy. During the operation an inflamed 30-cm jejunum segment was resected (**Fig. 2**). Histologically, the resected segment showed eosinophilic infiltration predominantly in the area of the submucosa and muscularis propria (**Fig. 3, 4**). Thus we diagnosed segmental eosinophilic obstructive jejunitis. Stool specimens for parasites and ova were negative. The postoperative course was uneventful and the patient was discharged 7 days after the operation. Six months later the patient complained again of abdominal cramps, pain, diarrhoea and vomiting. Differential white blood counts did not show eosinophilia, CRP was slightly elevated (2.18 mg/dL), all other values were normal. On abdominal ultrasound scan, enlarged small bowel segments were seen in the left upper abdomen. The patient received i.v. steroids (60 mg) for three days and was then put on oral budesonide (3 × 3 mg) (Budenofalk®) for three months. Medication was gradually reduced. Symptoms disappeared under this therapy completely and no side effects occurred. The patient is presently free of any symptoms.

Discussion

Eosinophilic enteritis is a rare condition and its aetiology remains unknown, as in our patient. Based on its clinical manifestation and bowel peripheral tissue involvement three types have been identified: mucosal, muscle layer and serosal layer disease can be distinguished [3]. In our patient a predominant eosinophilic infiltration was found in the muscle layer. These patients typically present with an intestinal localised obstruction [4, 5]. Food intolerance or allergy is uncommon in this type of variant. Mucosal layer disease typically presents itself

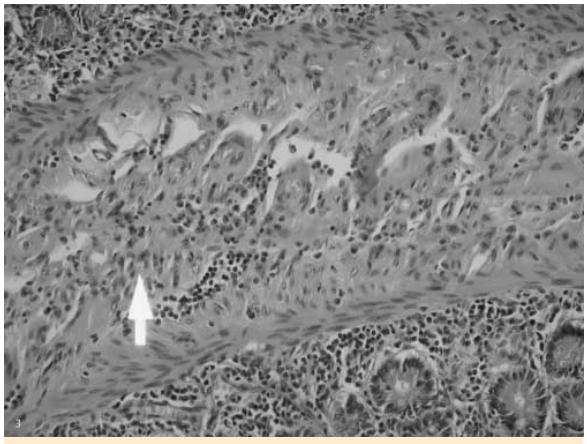

Fig. 3 Photomicrograph of the resected small bowel segment showing a slight eosinophilic infiltration of the submucosa (arrow) (H&E, orig mag × 200).

Fig. 4 Photomicrograph of the resected small bowel segment showing marked eosinophilic infiltration of the muscularis propria (arrow) (H&E, orig mag × 100).

Dr. Falk Pharma Ex. 1013
IPR Petition - USP 8,771,729

as a colicky abdominal pain, nausea, vomiting, diarrhoea and weight loss.

Patients with serosal disease typically present with eosinophilic ascites and acute or subacute small bowel obstruction with all layers of the bowel wall involved. The diagnosis of eosinophilic gastroenteritis is often retrospective and histopathological. For the diagnosis four criteria have to be fulfilled. Evidence of GI symptoms, eosinophilic infiltration of the GI tract, absence of eosinophilic penetration in other organs and absence of parasitic infections. Radiographic changes are variable and usually non-specific. In the case of involvement of the small bowel, a biopsy usually is not possible due to the inaccessibility of the small intestine [6]. Therefore this disease may be dealt with surgically. However, with the introduction of double balloon enteroscopy, it is now possible to reach the involved segments of the small bowel and to obtain biopsies [7]. In our case with predominant muscle layer involvement this approach could have failed, since biopsies usually do not reach deeper layers of the intestinal wall. Thus laparoscopy with a full-depth biopsy is necessary to confirm the diagnosis. A definitive diagnosis is desirable as treatment is available. Patients with obstructive symptoms respond rapidly to steroids. It is recommended to taper off the initial dose of 40 mg prednisone slowly over several weeks. Occasionally, low-dose maintenance prednisone is necessary to keep symptoms under acceptable control. If high-dose steroids are required to maintain remission the addition of azathioprin is recommended [1].

In our patient repetitive disease activity occurred and maintenance therapy had to be instituted. We started with parenteral steroids because of obstructive symptoms and changed rapidly to oral treatment with budesonide. Therapy could cessed after three months. Maintenance therapy has not yet been started. When symptoms appear again budesonide therapy will bridge until azathioprin is effective. Budesonide is used for several inflammatory bowel diseases including Crohn's disease and microscopic colitis [2]. The main advantage of budesonide is its high first pass metabolism with little risk of adrenal suppression and attenuation of systemic side effects.

In previous publications three patients with different forms of eosinophilic gastroenteritis and treatment with budesonide are recorded. These patients differ from ours due to the affected area (colonic, terminal ileum [8, 9], stomach [10]) and clinical presentation (protein losing enteropathy [8, 9], abdominal pain, ascites [10]) and the use of plain budesonide [10] instead of a delayed-release form.

In our case, we describe a patient with repetitive obstructive eosinophilic jejunitis due to infiltration of the muscle layer which was treated surgically during the first episode and during the relapse with short-term intravenous steroids and subsequently with oral budesonide. The treatment was effective and side effects were absent.

References

1 *Taley NJ.* Eosinophilic gastroenteritis. In: Feldman M, Sleisenger MH, Scharschmidt BF (Hrsg). Sleisengers und Fortran's gastrointestinal and liver disease. Philadelphia: W. B. Saunders, 1998; 6th edn: 1679–1688

2 *Spencer CM, McTavish D.* Budesonide. A review of its pharmacological properties and therapeutic efficacy in inflammatory bowel disease. Drugs 1995; 50: 854–872

3 *Talley NT, Shorter RG, Phillips SF et al.* Eosinophilic gastroenteritis: a clinicopathological study of patients with disease of the musosa, muscle layer, and subserosal tissue. Gut 1990; 31: 54–58

4 *Karande T, Oak SN, Trivedi A et al.* Proximal jejunal obstruction due to eosinophilic gastroenteritis. JPGM 1996; 42: 121–123

5 *Alamo Martinez JM, Ibanez Delagado F, Galindo A et al.* Intestinal obstruction by eosinophilic jejunitis. Rev Esp Enferm Dig 2004; 96: 279–283

6 *Edelman DS.* Eosinophilic enteritis. A case for diagnostic laparoscopy. Surg Endosc 1998; 12: 987–989

7 *Chen YY, Su WW, Soon MS et al.* Eosinophilic jejunitis presenting with acute abdomen: the usefulness of double-balloon enteroscopy. Gastroentestinal Endoscopy 2006; 63: 532–534

8 *Siewert E, Lammert F, Koppitz P et al.* Eosinophilic gastroenteritis with severe protein-losing enteropathy: successful treatment with budesonide. Dig Liver Dis 2006; 38: 55–59

9 *Russel MG, Zeijen RN, Brummer RJ et al.* Eosinophilic enterocolitis diagnosed by means of technetium-99 m albumin scintigraphy and treated with budesonide (CIR). Gut 1994; 35: 1490–1492

10 *Tan ACITL, Kruimel JW, Naber THJ.* Eosinophilic gastroenteritis treated with non-enteric-coated budesonide tablets. Europ J Gastroenterol Hepatol 2001; 13: 425–427

Dr. Falk Pharma Ex. 1013
IPR Petition - USP 8,771,729