Check for updates

ORIGINAL ARTICLE

Development and Description of a New Multifidus-Sparing Radiofrequency Neurotomy Technique for Facet Joint Pain

Marc A. Russo, MBBS, DA(UK), FANZCA, FFPMANZCA*,†; Danielle M. Santarelli, PhD†

*Hunter Pain Specialists, Broadmeadow, New South Wales, Australia; †Genesis Research Services, Broadmeadow, New South Wales, Australia

■ **Abstract**

Introduction: The technique of radiofrequency neurotomy (RFN) of the facet joints has been used for decades to treat persistent low back pain to good effect in carefully selected patients. Traditionally, the target is the medial branches of the dorsal root supplying the facet joint. An alternative denervation target is the facet joint capsule. Capsule-targeting techniques may spare the multifidus muscle, a possible unintended target of traditional RFN that is thought to be important in recovering from low back pain, and have shown promising results.

Methods: A modified RFN technique that targets the capsule and spares the multifidus (multifidus-sparing RFN) is described here, along with a brief report of its application in patients with symptomatic facet joint low back pain as compared to traditional medial branch RFN (MBRF).

Results: Over a 2-year period, a total of 401 initial multifidus-sparing RFN and 94 initial MBRF procedures were performed on patients attending a multidisciplinary pain clinic. The proportion of repeat procedures was similar: 28.4% of multifidus-sparing procedures and 23.4% of MBRF procedures. The median repeat interval was 12 months for both groups and interquartile range was 10 months (8–18 months) for multifidus-sparing RFN and 4 months (11–15 months) for MBRF. Effectiveness and safety profiles appear to be similar, although limited, retrospective outcome information prevented robust analysis.

Conclusion: Multifidus-sparing RFN represents an intriguing technique to denervate the facet joint pain generator while maintaining normal multifidus function. Further study is warranted, particularly in order to identify the appropriate patient criteria and long-term outcomes. ■

Key Words: capsule, denervation, facet joint, low back pain, radiofrequency ablation, radiofrequency neurotomy

KEY POINTS

- The facet joint capsule appears to be an attractive denervation target to treat symptomatic facet joint pain whilst preserving multifidus function
- A modified multifidus-sparing radiofrequency neurotomy (RFN) technique was devised that uses a laterally deploying multi-tined electrode to target the facet joint capsule
- The modified technique displayed a similar response profile to traditional medial branch RFN and appeared well tolerated
- The technique seems best suited to patients under 70 years without spondylolisthesis and in whom multifidus preservation is desired

Address correspondence and reprint requests to: Marc A. Russo, MBBS, DA(UK), FANZCA, FFPMANZCA, Hunter Pain Specialists, 91 Chatham Street, Broadmeadow, NSW 2292, Australia.
Email: algoguy@gmail.com

Submitted: November 16, 2020; Revised March 16, 2021; Revision accepted: March 22, 2021
DOI. 10.1111/papr.13010

© 2021 World Institute of Pain, 1530-7085/20/$15.00

IPR2024-01211
Avanos v. Stratus
Stratus Ex. 2005

INTRODUCTION

Traditional radiofrequency neurotomy

The procedure of percutaneous rhizolysis for chronic low back pain was promulgated by Welsh surgeon W.E. Skyrme-Rees.[1,2] In attempting to improve on limited results when the technique was tried, pioneering neurosurgeon C. Norman Shealy developed the technique of radiofrequency neurotomy (RFN) of the facet joints.[3–5] A dedicated electrode was developed by C.D. Ray and a commercial kit was developed in partnership with Cosman Medical, Inc. and manufactured by Radionics.[6]

Formal anatomic dissection and procedural documentation were determined by Bogduk and Long.[7] The traditional target for RFN of a facet joint is the relevant medial branches of the dorsal root supplying that facet joint.[8,9] Critically, the length of the active tip of the electrode must lie adjacent and approximately parallel to the medial branch in order to have both the highest likelihood of denervating the nerve and the longest duration of pain relief.[10] The technique quickly became a mainstay of treatment in patients over 40 years of age with persistent low back pain and a positive response to diagnostic local anesthetic blocks. High levels of pain relief have been observed when ≥ 50% pain relief is met with 2 diagnostic blocks, or ≥ 80% pain relief is met with a single block.[11–13]

Studies on the effectiveness of RFN to treat chronic lumbar pain have produced variable results. This may be attributed to heterogeneity in study protocols, patient selection, RFN technique (ie, conventional RFN, cooled radiofrequency [RF]), and target structure (facet joint and sacroiliac joint). Two notable meta-analyses have attempted to address this. Lee et al. emphasized the use of a consistent RFN protocol and included 7 randomized controlled trials (RCTs) involving 454 patients.[14] Greater efficacy was found for conventional RFN compared to sham or epidural steroid injection at 1-year post-treatment, with the mean pain score reduction exceeding the minimally important clinical difference. A more recent meta-analysis of 15 RFN trials, with a total of 528 patients who underwent RFN procedures for sacroiliac joint pain or lumbar facet joint pain and 457 patients in the control/comparison group (11 sham procedure, 3 steroid injection, and 1 medication), showed significantly greater improvements in pain score, disability, and quality of life in the RFN groups.[15] Individual studies have consistently shown that some patients have return of pain at 1 year, with good results from repeat RFN.[16–20]

Concerns with radiofrequency neurotomy

Medial branch RFN is a procedure that has stood the test of time, with an excellent track record of safety and maintained stability, however, there are some theoretical concerns worth noting.

The medial branches supply the neural innervation of the facet joint, but they also supply other structures. These include the multifidus muscle and half of the supply to the interspinous bursa.[21,22] Successful denervation of the medial branch would be expected to denervate these structures as well as the facet joint. There is good evidence that denervation of the multifidus muscle occurs with this technique. Wu et al.[23] presented electrophysiological evidence of multifidus atrophy after medial branch RFN. Dreyfuss et al. observed diffuse multifidus atrophy after successful RFN on MRI scans.[24] Of concern are the results of Smuck et al.,[25] who showed a significantly greater degree of disc degeneration at facet joint denervated levels compared with control levels. It has traditionally been surmised that partial or full atrophy of the multifidus muscle, even bilaterally, is of little concern, and authors have pointed to the polysegmental innervation of the muscle as a reason to be sanguine.[23,26,27] There is a paucity of data to provide this reassurance. At least one commentator has expressed concerns that "we may help patients in the short term, yet make them more susceptible to further episodes of low back pain in the future."[28] There is evolving evidence that the multifidus muscle is critical for recovery from chronic low back pain and ideally it should be preserved when treating low back pain.[29–35]

There are additional concerns that would, in an ideal world, be addressed in any modified technique.[8] First is the need for multiple angled fluoroscopic images to be obtained in an anteroposterior (AP), 30 degrees ipsilateral oblique and true lateral position for confirmation of correct probe placement to the bony landmarks. This requires additional procedure time and increased exposure to radiation, especially in the lateral fluoroscope angle. Second is the occasional difficulty of ascertaining the bony anatomy in advanced cases of lumbar spondylosis. Third is the rare case of neurological injury from anatomic misplacement of the active tip of the probe onto the spinal nerve root. Fourth is the not uncommon temporary pain flare postoperatively either as regard to low back pain or leg pain. The role of the local anesthetic (injected before lesioning) acting as a fluid bridge between electrode tip and remote spinal nerve

IPR2024-01211
Avanos v. Stratus
Stratus Ex. 2005

root and a possible subsequent mild thermal injury to nerve root has been raised by some practitioners (N. Christelis 2017, personal communication, December 7, 2017).

These theoretical concerns and procedural issues prompted us to re-examine the anatomy and pathophysiology of facet joint pain and develop a modified procedure to preserve the multifidus.

Anatomy of the facet joint

By 1976, the facet joint was recognized as a source of chronic low back pain.[36] It was assumed that the pain arose from osteoarthritis of the articular surface that was transmitted to the peripheral nerves subserving the joint, namely the medial branches of the dorsal root. This was implied in early reviews of the condition, although not actually experimentally substantiated.[37–41]

The facet joint is surrounded by a capsule, the purpose of which is to constrain motions of the vertebrae during loading.[42] Anatomic dissections have shown that the tendons of the multifidus muscle cover the posterior facet joint capsule (Figure 1), which supports the function of the multifidus in preventing entrapment of the menisci and capsule during spinal movements.[43] The facet joint capsule is richly innervated by sensory and autonomic nerve fibers,[44] and there is evidence that it contains nociceptive fibers.[45] Virtually identical findings have been reported (Figure 2).[46] A comprehensive study by Kim et al. showed advanced degeneration in cartilage and capsule in samples obtained from patients undergoing spinal reconstruction surgery.[47] Increased inflammation, neovascularization, and expression of pain-related axonal promoting factors was observed in co-cultured dorsal root ganglia in the presence of degenerative facet joint capsule (Figures 3 and 4).[47] Note the well-preserved articular surface of the facet joint until grade 4 degeneration and the early capsular degeneration in grades 0 to 3. From these points, one can hypothesize that the source of pain is primarily the facet joint capsule and possibly only involves the facet joint articular surface in the end stages of the arthritic process. If this were to be the case, then the facet joint capsule would appear to be an attractive denervation target to treat symptomatic facet joint pain while sparing the multifidus.

Development of a modified radiofrequency neurotomy technique

In lieu of the above considerations, the author set about devising a modified technique that would denervate the facet joint capsule, protect innervation to the multifidus muscle, provide possible heat-induced shrinkage of the

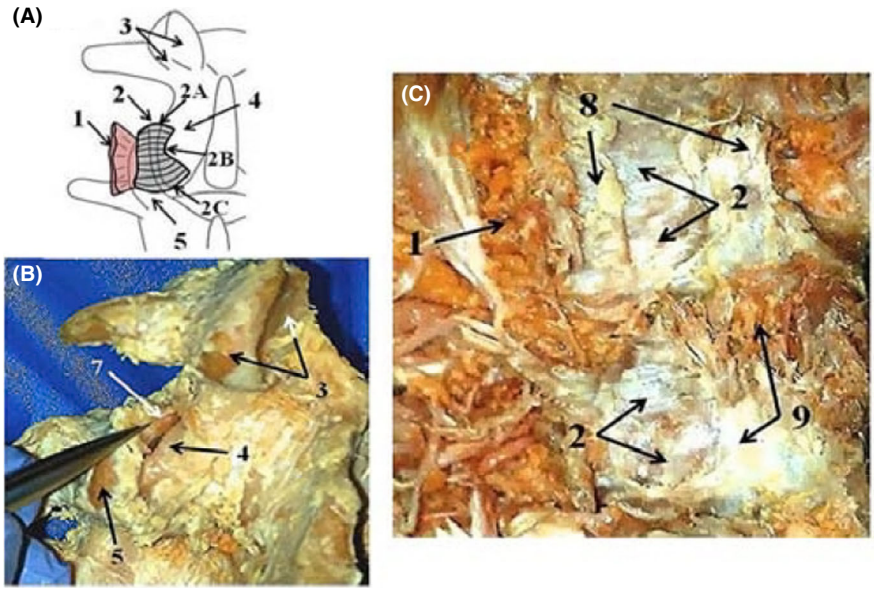

FIGURE 1. Posterior facet joint capsule and multifidus muscle. (A) Lumbar facet joint diagram showing: (1) multifidus; (2) facet joint capsule (A–C) superior, middle, and inferior capsule fibers); (3) superior articular process; and (4, 5) inferior and superior articular process. (B) Cephalad meniscus of a cut joint capsule (7). (C) Two lumbar facet joints showing: (2) capsules; (8) multifidus muscle fascia covering the posterior joint capsule; and (9) muscle fiber and tendon of the deep interlaminar layer of the multifidus. Reproduced from Gorniak and Conrad.[51]

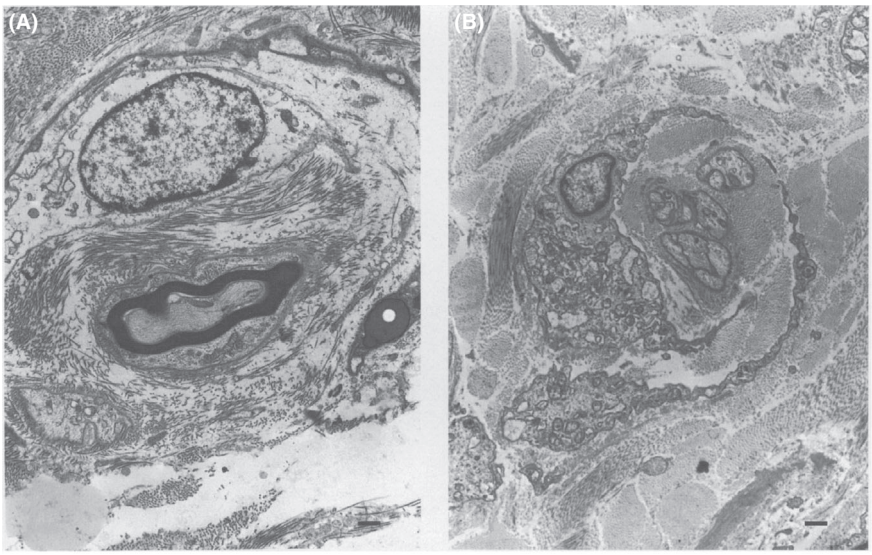

FIGURE 2. Posterior facet joint capsule tissue. (A) Small myelinated nerve fiber. (B) Bundle of unmyelinated nerve fibers. Reproduced from Vandenabeele et al.[46] with permission from the publisher.

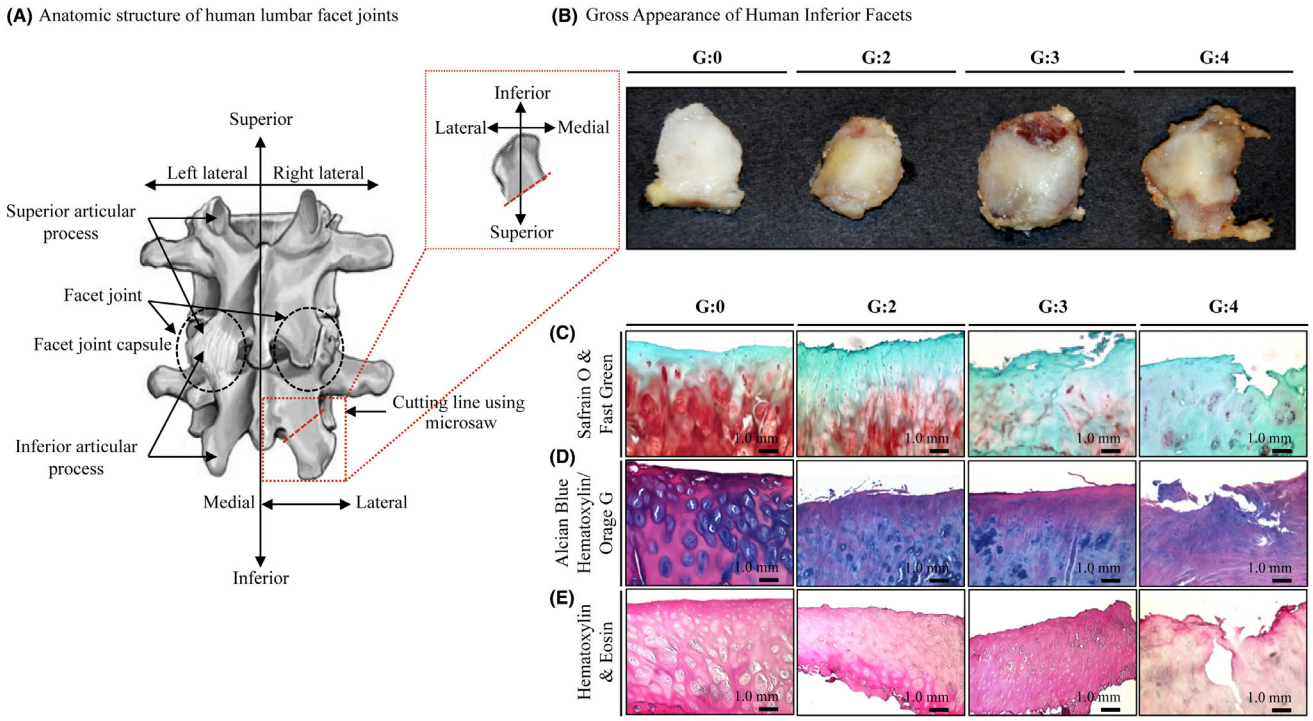

FIGURE 3. Human lumbar facet joints. (A) Anatomic diagram. (B) Degenerative changes in inferior facet joints and capsule tissue with assigned grading (G:0–G:4): G:0 = healthy facet joint, and G:3–4 = degenerative facet joints. Note the well-preserved articular surface until grade 4 facet joint degeneration. (C–E) Histological staining of facet joint cartilage showing degenerative changes (ie, decreased proteoglycan and fibrillation). Reproduced from Kim et al.[47] with permission from the publisher.

capsule to better protect the facet joint from excessive excursions of its articulating surface, and to decrease the chance of spinal nerve root remote heating. The technique uses a laterally deploying tined electrode that has been commercially released for RFN, both thermal and pulsed (Nimbus Concepts, LLC; Figure 5).[48] It has

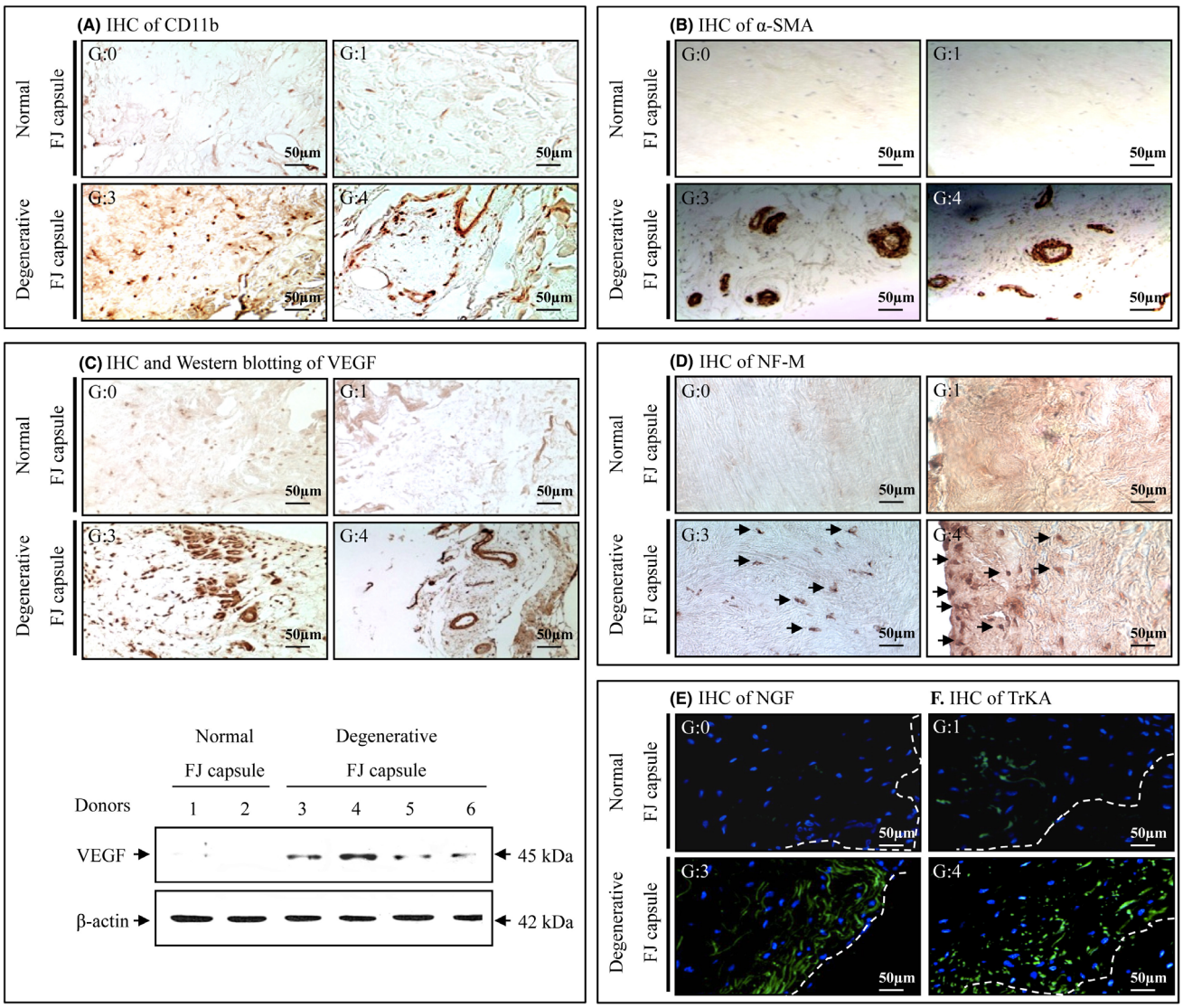

FIGURE 4. Immunohistochemical (IHC) staining of facet joint capsule tissues: normal (G:0) and degenerative (G:3–4). (A) Infiltration of inflammatory cells is seen in G:3–4. (B) Marked angiogenesis is seen in G:3–4. (C) Increased angiogenesis factor (VEGF) is observed in G:3–4. (D–F) Increased neurite formation, neuronal growth-promoting factor (NGF) and its receptor (TrkA) is seen in G:3–4. Reproduced from Kim et al.[47] with permission from the publisher.

been assessed in a lesion size study.[49] The senior author has extensive experience with this electrode both clinically and in discussions with the patent holder (R.E. Wright). Original clinical use has included both parallel and perpendicular approaches to the medial branch for thermal RFN. Additional features of this technique include single-plane fluoroscopic interpretation and minimization of ionizing radiation exposure to the patient and practitioner. The technique is described below, along with a brief report of its application in patients with symptomatic facet joint low back pain.

METHODS

Study design

Retrospective data collection and analysis were performed with approval from the Bellberry Human Research Ethics Committee. The data comes from a single multidisciplinary pain clinic in New South Wales, Australia. All patients provided informed written consent to the use of their de-identified data for research purposes prior to receiving treatment at the pain clinic.

Patients were informed that they would receive a modification of the traditional technique that

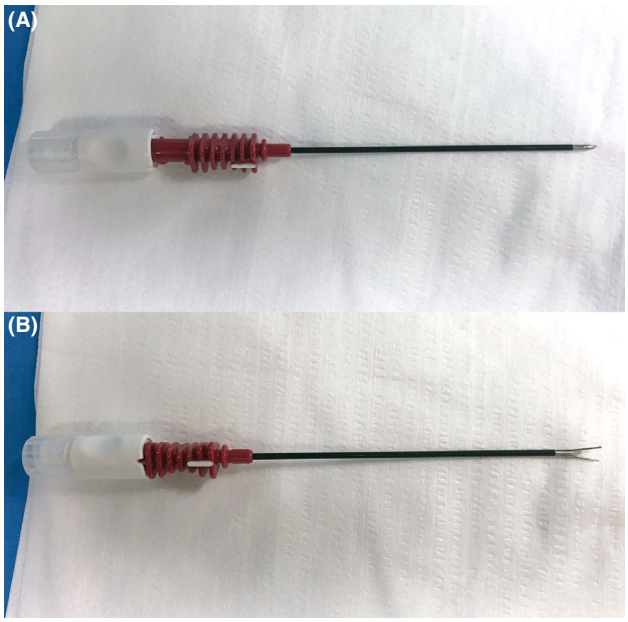

FIGURE 5. The Nimbus Multi-Tined Expandable Electrode. (A) Active tip (non-deployed). (B) Locked hub, insulated shaft, and tines (Nimbus Concepts, LLC).

denervated the adjacent muscle by having an end point "burn" right near the facet joint and that this technique had been validated in the literature in different formats but all achieving essentially the same outcome of preserving the muscle. Simply, an existing commercially available needle was being adapted to this technique (Nimbus needle). All patients had the opportunity to request the traditional technique if they desired it but none of the cohort requested this.

Multifidus-sparing radiofrequency neurotomy technique

The patient is placed prone on an examination table with a pillow underneath the hips to remove excessive lumbar lordosis, and receives light sedation, monitored anesthesia care, and supplemental oxygen. The target facet joint (eg, L4/5) is identified in the 30 degrees oblique fluoroscopic plane. Local anesthetic is injected subdermally and subcutaneously. An 18-gauge Nimbus multi-tined cannula is placed in the "gun barrel" view to touch the facet joint capsule exactly midway vertically and midway horizontally of the joint itself. The locking collar is rotated closed to deploy the tines while downward pressure is exerted on the cannula to ensure that the tines embed themselves into the tissue of the facet joint capsule. The tines are orientated to be in the vertical plane of the facet joint line. This is confirmed on the fluoroscopic image, with particular care taken to ensure the tines are not to either side of the joint line in the oblique view (for examples of fluoroscopic image-guided needle placement, see Figure 6). Then, 0.5 mL of local anesthetic is injected down the cannula. A percutaneous RF electrode is placed inside the cannula and a single lesion is made using a 30 second ramp from 60 to 90°C, then held at 90°C for 2 minutes. The electrode is removed, the locking collar of the cannula is unwound, the cannula is removed, pressure applied momentarily, and a dressing is applied if desired. This completes the procedure.

The technique aims to provide a neurotomy to the terminal end branches of the medial branch of the dorsal root. For coding purposes, a neurotomy is the correct allocation. Given the somewhat divergent nature of the technique from traditional medial branch RFN (MBRF), we suggest a specific name to allow correct identification of the procedural technique used. The term multifidus-sparing RF neurotomy is proposed.

Data collection

A database of procedure bookings was searched to generate a list of traditional MBRF and multifidus-sparing RFN procedures performed by a single pain physician on patients with symptomatic lumbar facet joint pain between January 1, 2017, and December 31, 2018. A second search was performed to identify repeat procedures performed up to June 15, 2020.

Thoracic, thoracolumbar, and sacroiliac joint RFN procedures were excluded. Single occasion bilateral procedures were recorded as separate left-side and right-side procedures to accommodate for instances in which repeat treatment was performed on the one side only.

As the data comes from a real-world clinic setting, with patients undergoing RFN procedures as the standard of care, bookings with co-procedures (whether on the same or separate occasion[s]) were not excluded, and patients may have been receiving additional treatments, including medication and physical therapy.

Medical records were accessed to collect basic patient demographics and review procedure outcomes (if available).

Data analysis

Data were grouped into MBRF or multifidus-sparing RFN groups based on first (initial) procedure. For each

IPR2024-01211
Avanos v. Stratus
Stratus Ex. 2005

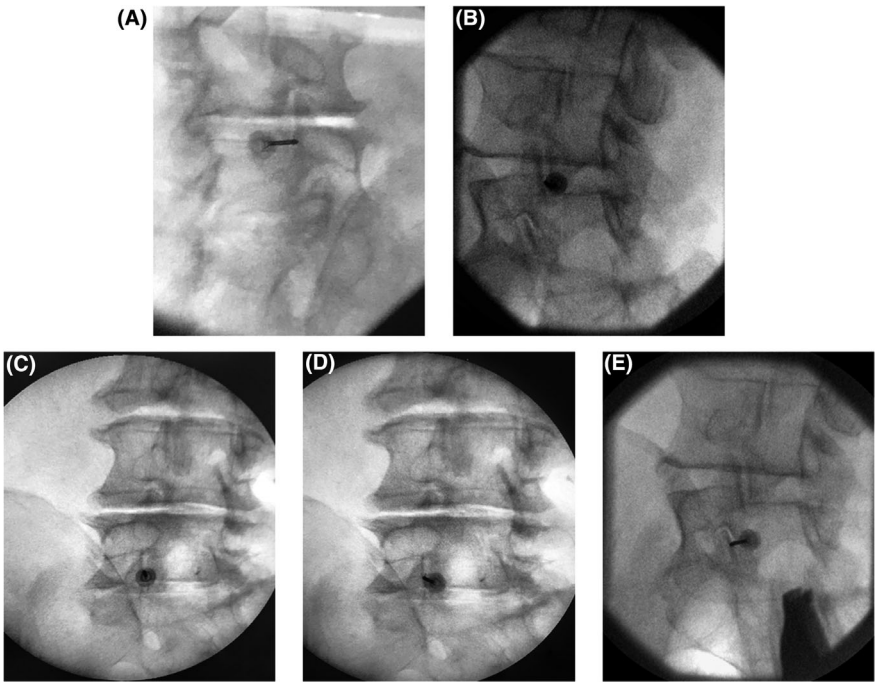

FIGURE 6. Fluoroscopic image-guided needle placement during multifidus-sparing radiofrequency neurotomy (RFN) procedure examples. (A, B) Needle placed over facet joint "cleft" L4/5. (C–E) Needle placed over facet joint "cleft" L5/S1.

procedure group, the percentage of repeat procedures and the median time in months between initial and repeat procedures (repeat interval) was calculated.

Procedure outcomes (if available) were categorized into positive result (significant/≥ 50% pain relief), partial response (< 50% pain relief/short-term relief), negative result (no/minimal relief), or not reported.

RESULTS

Initial procedures

The initial search found 495 RFN procedures that were suitable for analysis: 94 traditional MBRF and 401 multifidus-sparing RFN. The mean age was 70.7 ± 10.3 years for the MBRF group and 61.7 ± 13.1 years for the multifidus-sparing RFN group. The proportion of women was 68.1% (MBRF) and 52.4% (multifidus-sparing RFN).

Repeat procedures

The proportion of repeat procedures was comparable between groups: 23.4% of the MBRF group and 28.4% of the multifidus-sparing RFN group (Figure 7A). Mean age was 66.3 ± 7.5 years (MBRF repeats) and 62.2 ± 12.3 years (multifidus-sparing RFN repeats). The proportion of women was 77.3% (MBRF repeats) and 53.5% (multifidus-sparing RFN repeats).

The median repeat interval was 12 months for both groups and interquartile range (IQR) was 4 months (11–15 months) for MBRF and 10 months (8–18 months) for multifidus-sparing RFN (Figure 7B). The Mann-Whitney *U* test reported no significant difference between groups ($P = 0.5$). However, group variances were significantly different ($P = 0.01$; Levene's test).

Procedure outcomes

Initial procedure outcomes (categorized) are presented in Figure 8. Percentages were similar for initial MBRF and multifidus-sparing RFN groups, with 58.5% of MBRF procedures and 56.1% of multifidus-sparing RFN procedures having a positive outcome. The majority of repeat procedures were performed after an initial positive result (86.4% of MBRF repeats and 82.5% of multifidus-sparing RFN repeats).

Safety

One patient in the MBRF group reported ongoing pain and paraesthesia post-initial procedure, possibly related

IPR2024-01211
Avanos v. Stratus
Stratus Ex. 2005

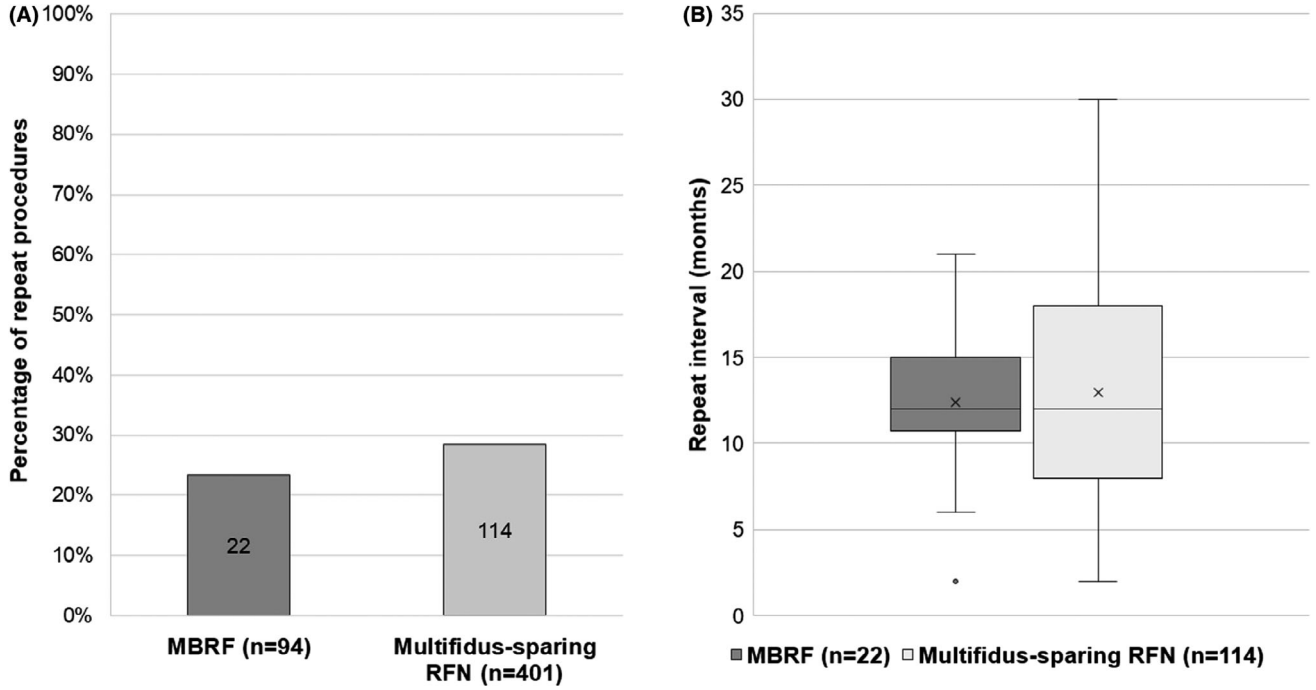

FIGURE 7. Medial branch radiofrequency neurotomy (MBRF) versus multifidus-sparing radiofrequency neurotomy (RFN) repeat procedures. (A) Percentage of procedures repeated for each RFN group. (B) Repeat interval in months for each RFN group (×'s represent group means).

to lumbar spondylosis. One patient in the multifidus-sparing RFN group reported increased pain and numbness post-initial procedure, which was thought to be related to ongoing worsening spondylolisthesis. Another patient in the multifidus-sparing RFN group reported painful flank spasm post-initial procedure that was attributed to psoas muscle spasm, which was later treated.

DISCUSSION

This modified technique meets the criteria of a defined anatomic target, single RF lesion, quick procedure, single fluoroscopic view, minimal ionizing radiation, and well tolerated procedure. It seems best suited to patients under the age of 70 years without spondylolisthesis in whom multifidus preservation is desired to allow core muscle stabilization with subsequent exercise physiology input. Our retrospective analysis of clinic data provides support for noninferiority of the multifidus-sparing technique to traditional MBRF, with a similar incidence of repeat procedures, similar repeat interval, and a similar response profile. Definitive comparative studies to traditional medial branch RFN would seem warranted and should include observation points out to 2 years to look for efficacy beyond the typical 12-month timepoint of MBRF. It is doubtful that there would be any superiority of the technique in terms of duration of analgesic response if the patient did not formally engage the preserved multifidus muscle in an exercise program.

It should be stated that close observation of outcomes early in the development of the multifidus-sparing technique (contained in this data set) showed that patients with spondylolisthesis responded poorly and were subsequently not selected for this technique. Patients over the age of 70 years of age had a more variable success rate with the modified technique, and over the first year of data collection they were increasingly offered the standard MBRF technique. It was anecdotally noted that in elderly patients over the age of 70 years that some of these patients had such hypertrophied facet joints that the angle of the facet joint line was covered over by bony hyperostosis and it is surmised that this may represent a mechanism of failure of the technique in this subset.

At this stage, the concept of the capsule shrinking due to applied heat to better support facet joint motion is a theoretical one. Capsular shrinkage with heat application has been observed when applied to the

IPR2024-01211
Avanos v. Stratus
Stratus Ex. 2005

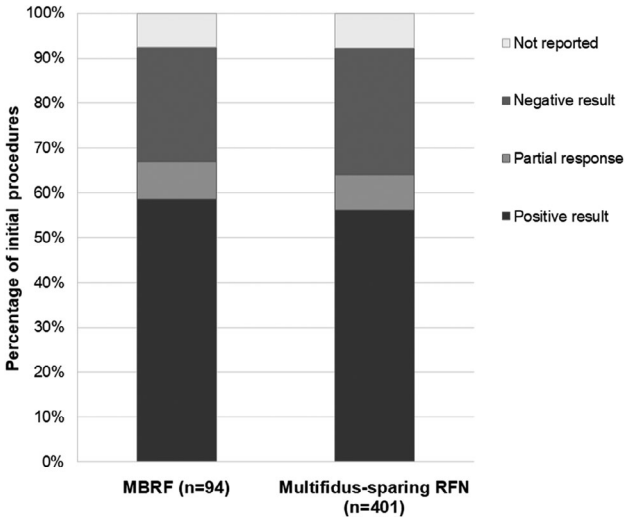

FIGURE 8. Categorical medial branch radiofrequency neurotomy (MBRF) and multifidus-sparing radiofrequency neurotomy (RFN) procedure outcomes.

glenohumeral joint.[50–52] Specific documentation of the heat effect on the capsule should be explored.

Alternative radiofrequency neurotomy techniques

Endoscopic placement of an RF probe has been described by several authors.[53–55] Whereas direct visualization of the target structure seems appealing, it still targets the medial branch. A technique of endoscopic complete capsulectomy was performed in 114 patients with lumbar pain, with 68% of patients experiencing a ≥ 50% reduction in baseline pain.[53] Surgical time was up to 42 minutes and blood loss up to 100 mL. The technique described is more neurosurgical than percutaneous in manner (use of pituitary rongeurs and holmium laser).

An alternative technique of laser denervation to the dorsal surface of the facet capsule was performed in 21 patients with a positive response to diagnostic facet blocks by Iwatsuki et al.[56] After 1 year, 81% of patients reported ≥ 70% pain relief. The technique was unsuccessful in patients who had previous spinal surgery.

A 4-lesion radiofrequency cauterization (Surgi-Max RF generator—elliquence, LLC) has been described targeting the superior, inferior, medial, and lateral edges of the facet joint capsule. Average VAS reduction was 5.6 from baseline at 1 year, indicating robust clinical results (92% of patients had good to excellent results at 1 year utilizing modified Macnab criteria).[57]

A simpler procedure was described by Moussa and Khedr, in which 2 RF lesions were performed, one to the medial aspect of the facet joint edge and one to the lateral aspect of the facet joint edge, both adjacent to facet joint capsule.[58] This technique was compared against standard medial branch RFN and sham procedure in a prospective RCT of 120 patients with chronic low back pain. Only the facet joint capsule RFN group maintained significant improvement in pain at the 2-year study end point.

A modified version of the above technique has been described whereby the electrodes are placed over the medial and lateral joint edges and bipolar RFN is performed to denervate the space between the electrodes.[59] As this is performed in the vertical midpoint of the joint, it does not take into account the entry points of the superior and inferior medial branch nerves, which enter from the superior and inferior aspect of the joint, respectively, and may be less than optimally denervated with a horizontally focused approach. This technique was developed as an add-on to conventional RFN and has been applied to lumbar[59] and cervical[60] facet joints.

In the development process of wishing to achieve an end-terminal RFN technique, these alternative techniques were reviewed, and in order to achieve the optimum outcome of minimal radiation, single plane visualization, single neurotomy lesion, confirmed end point placement, and protection from inadvertent nerve root injury, the modified technique was developed using a multi-tined needle placed in a specific manner with a single lesion. We feel this approach has a number of advantages as it meets the pre-set criteria that we have defined for an optimal RF neurotomy procedure (ie, potentially faster and potentially less procedural pain).

Caveats for the modified technique

To date, 3 caveats seem to apply to the multifidus-sparing technique. The first involves ensuring that the tined cannula does not enter the facet joint proper if there is distraction of the joint and a large gap is appreciated on the fluoroscopic image. In cases such as these, the tines should first touch either the medial or lateral edge of the joint and the depth should be noted. The tines are then moved to the middle of the joint line in the gap area but at no greater depth than first placed. This will ensure that the tines remain embedded in the facet joint capsule and not inside the joint. The second involves not using the technique in cases of spondylolisthesis. In spondylolisthesis, the 2 edges of the facet joint

will not be in the same plane but one forward, one backward, although this cannot be appreciated on the oblique fluoroscopic image. The tines, if deployed, will not reach into the facet joint capsule at the correct angle and only a small part of the capsule is likely to be affected by the RF lesion. This theoretical limitation has been born out in clinical practice with a lack of VAS reduction in 6 patients with spondylolisthesis (grades 1–3; data not presented). The third involves the treatment of very severe advanced cases of facet joint arthropathy at the L5/S1 level only. In some severely degenerative joints at this level, a facet joint line can no longer be appreciated on the fluoroscopic image due to virtual fusion of the opposing joint surfaces. In these cases, the anatomic target point is not determinable and a more traditional technique should be sought.

We do not feel that this 1-needle technique invalidates the potential efficacy of a 2-needle technique (lesion immediately either side of the end-on facet joint), but that for some proceduralists, it may also represent a quicker and less technically challenging placement. Specifically, use of a tined cannula allows embedment of the tines within the facet joint capsule, which may allow a unique lesion spread to terminal afferents. This hypothesis should be tested in an animal preparation before being accepted as the "mechanism of action." In cases where the modified technique is thought to be inapplicable (eg, spondylolisthesis), we would view the 2-needle placement technique as an optimal treatment to lesion end terminal afferents of the facet joint.

It is highly likely that the results obtained with multifidus-sparing RFN will be wholly dependent on the correct selection of patients with facet joint pain, as determined by correct use of diagnostic medial branch blocks. Failure to have patients with the index condition will cause a lack of analgesia from the procedure to be observed.

Limitations

There are several limitations to the investigation, mainly owing to the real-world setting and that this is a single practitioner retrospective data collection investigation. Formal, quantitative procedure outcomes were not collected and hence analysis of effectiveness was significantly limited. Qualitative assessment of outcomes was based on patient follow-up notes, and for a small number of patients, procedure outcomes were not reported, despite some being repeated. For this reason, we chose to report repeat procedure incidence and interval and compare that to traditional MBRF as an indication of comparative effectiveness.

CONCLUSION

Over the last 40 years, the technique of neurotomy of the nerve supply to the facet joint has continued to evolve. From anatomic evidence of the course of the medial branch, to documentation of lesion size with 16-gauge cannula, to tined leads, to multifidus sparing techniques. Its efficacy is supported by meta-analysis of available studies and it has continued to be one of the major techniques used to minimize opioid prescription and repeat spine surgery. The proposed technique may represent an intriguing opportunity to provide denervation of the facet joint pain generator while maintaining normal spinal muscle function. We believe it would be worthwhile to conduct a small pilot study to identify the appropriate patient criteria and evaluate the long-term outcomes.

CONFLICTS OF INTEREST

None of the authors have any conflicts of interest to disclose.

REFERENCES

1. Rees W. Multiple bilateral subcutaneous rhyzolysis of segmental nerves in the treatment of the intervertebral disc syndrome. *Ann Gen Pract*. 1971;26:126–7.

2. Rees WS. Multiple bilateral percutaneous rhizolysis. *Med J Aust*. 1975;1:536–7.

3. Shealy CN. Facets in back and sciatic pain. A new approach to a major pain syndrome. *Minn Med*. 1974;57:199–203.

4. Shealy CN. Percutaneous radiofrequency denervation of spinal facets. Treatment for chronic back pain and sciatica. *J Neurosurg*. 1975;43:448–51.

5. Shealy CN. Facet denervation in the management of back and sciatic pain. *Clin Orthop Relat Res*. 1976;115: 157–64.

6. Cosman ER, Cosman ER. Radiofrequency lesions. In: Lozano AM, Gildenberg PL, Tasker RR, editors. *Textbook of stereotactic and functional neurosurgery*. Berlin, Heidelberg: Springer Berlin Heidelberg, 2009; p. 1359–82.

7. Bogduk N, Long DM. The anatomy of the so-called "articular nerves" and their relationship to facet denervation in the treatment of low-back pain. *J Neurosurg*. 1979;51:172–7.

8. Bogduk N, Dreyfuss P, Govind J. A narrative review of lumbar medial branch neurotomy for the treatment of back pain. *Pain Med*. 2009;10:1035–45.

IPR2024-01211
Avanos v. Stratus
Stratus Ex. 2005

9. Bogduk N, Long DM. Percutaneous lumbar medial branch neurotomy: a modification of facet denervation. *Spine (Phila Pa 1976)*. 1980;5:193–200.

10. Bogduk N, Macintosh J, Marsland A. Technical limitations to the efficacy of radiofrequency neurotomy for spinal pain. *Neurosurgery*. 1987;20:529–35.

11. Bokov A, Perlmutter O, Aleynik A, Rasteryaeva M, Mlyavykh S. The potential impact of various diagnostic strategies in cases of chronic pain syndromes associated with lumbar spine degeneration. *J Pain Res*. 2013;6:289–96.

12. Manchikanti L, Hirsch JA, Falco FJ, Boswell MV. Management of lumbar zygapophysial (facet) joint pain. *World J Orthop*. 2016;7:315–37.

13. Manchikanti L, Pampati S, Cash KA. Making sense of the accuracy of diagnostic lumbar facet joint nerve blocks: an assessment of the implications of 50% relief, 80% relief, single block, or controlled diagnostic blocks. *Pain Physician*. 2010;13:133–43.

14. Lee CH, Chung CK, Kim CH. The efficacy of conventional radiofrequency denervation in patients with chronic low back pain originating from the facet joints: a meta-analysis of randomized controlled trials. *Spine J*. 2017;17:S119.

15. Chen CH, Weng PW, Wu LC, Chiang YF, Chiang CJ. Radiofrequency neurotomy in chronic lumbar and sacroiliac joint pain: a meta-analysis. *Medicine (Baltimore)*. 2019;98: e16230.

16. Schofferman J, Kine G. Effectiveness of repeated radiofrequency neurotomy for lumbar facet pain. *Spine (Phila Pa 1976)*. 1976;2004(29):2471–3.

17. Son JH, Kim SD, Kim SH, Lim DJ, Park JY. The efficacy of repeated radiofrequency medial branch neurotomy for lumbar facet syndrome. *J Korean Neurosurg Soc*. 2010;48:240–3.

18. Smuck M, Crisostomo RA, Trivedi K, Agrawal D. Success of initial and repeated medial branch neurotomy for zygapophysial joint pain: a systematic review. *PM&R*. 2012;4:686–92.

19. McCormick ZL, Marshall B, Walker J, McCarthy R, Walega DR. Long-term function, pain and medication use outcomes of radiofrequency ablation for lumbar facet syndrome. *Int J Anesth Anesth*. 2015;2:028

20. Husted DS, Orton D, Schofferman J, Kine G. Effectiveness of repeated radiofrequency neurotomy for cervical facet joint pain. *J Spinal Disord Tech*. 2008;21:406–8.

21. Macintosh JE, Valencia F, Bogduk N, Munro RR. The morphology of the human lumbar multifidus. *Clin Biomech*. 1986;1:196–204.

22. Bogduk N. The innervation of the lumbar spine. *Spine (Phila Pa 1976)*. 1976;1983(8):286–93.

23. Wu PB, Date ES, Kingery WS. The lumbar multifidus muscle in polysegmentally innervated. *Electromyogr Clin Neurophysiol*. 2000;40:483–5.

24. Dreyfuss P, Stout A, Aprill C, Pollei S, Johnson B, Bogduk N, et al. The significance of multifidus atrophy after successful radiofrequency neurotomy for low back pain. *PM&R*. 2009;1:719–22.

25. Smuck M, Crisostomo RA, Demirjian R, Fitch DS, Kennedy DJ, Geisser ME, et al. Morphologic changes in the lumbar spine after lumbar medial branch radiofrequency neurotomy: a quantitative radiological study. *Spine J*. 2015;15:1415–21.

26. Kottlors M, Glocker FX. Polysegmental innervation of the medial paraspinal lumbar muscles. *Eur Spine J*. 2008;17:300–6.

27. Wu PB, Kingery WS, Frazier ML, Date ES. An electrophysiological demonstration of polysegmental innervation in the lumbar medial paraspinal muscles. *Muscle Nerve*. 1997;20:113–5.

28. Gossner J. The lumbar multifidus muscles are affected by medial branch interventions for facet joint syndrome: potential problems and proposal of a pericapsular infiltration technique. *AJNR Am J Neuroradiol*. 2011;32:E213.

29. Deckers K, De Smedt K, Mitchell B, Vivian D, Russo M, Georgius P, et al. New therapy for refractory chronic mechanical low back pain-restorative neurostimulation to activate the lumbar multifidus: one year results of a prospective multicenter clinical trial. *Neuromodulation*. 2018;21:48–55.

30. Chung S, Lee J, Yoon J. Effects of stabilization exercise using a ball on mutifidus cross-sectional area in patients with chronic low back pain. *J Sports Sci Med*. 2013;12:533–41.

31. Deckers K, De Smedt K, van Buyten J-P, Smet I, Eldabe S, Gulve A, et al. Chronic low back pain: restoration of dynamic stability. *Neuromodulation*. 2015;18:478–86; discussion 486.

32. Freeman MD, Woodham MA, Woodham AW. The role of the lumbar multifidus in chronic low back pain: a review. *PM&R*. 2010;2:142–6; quiz 141 p following 167.

33. Hides JA, Stanton WR, McMahon S, Sims K, Richardson CA. Effect of stabilization training on multifidus muscle cross-sectional area among young elite cricketers with low back pain. *J Orthop Sports Phys Ther*. 2008;38:101–8.

34. Sions JM, Coyle PC, Velasco TO, Elliott JM, Hicks GE. Multifidi muscle characteristics and physical function among older adults with and without chronic low back pain. *Arch Phys Med Rehabil*. 2017;98:51–7.

35. Woodham M, Woodham A, Skeate JG, Freeman M. Long-term lumbar multifidus muscle atrophy changes documented with magnetic resonance imaging: a case series. *J Radiol Case Rep*. 2014;8:27–34.

36. Mooney V, Robertson J. The facet syndrome. *Clin Orthop Relat Res*. 1976;115: 149–56.

37. Carrera GF, Williams AL. Current concepts in evaluation of the lumbar facet joints. *Crit Rev Diagn Imaging*. 1984;21:85–104.

38. Giles LG, Taylor JR. Osteoarthrosis in human cadaveric lumbo-sacral zygapophyseal joints. *J Manipulative Physiol Ther*. 1985;8:239–43.

39. Lewinnek GE, Warfield CA. Facet joint degeneration as a cause of low back pain. *Clin Orthop Relat Res*. 1986;213: 216–22.

40. Taylor JR, Twomey LT. Age changes in lumbar zygapophyseal joints. Observations on structure and function. *Spine (Phila Pa 1976)*. 1986;11:739–45.

41. Yang KH, King AI. Mechanism of facet load transmission as a hypothesis for low-back pain. *Spine (Phila Pa 1976)*. 1984;9:557–65.

42. Little JS, Khalsa PS. Material properties of the human lumbar facet joint capsule. *J Biomech Eng*. 2005;127:15–24.

43. Gorniak G, Conrad W. Lower lumbar facet joint complex anatomy. *Austin J Anat*. 2015;2:1032.

44. Ashton IK, Ashton BA, Gibson SJ, Polak JM, Jaffray DC, Eisenstein SM, et al. Morphological basis for back pain: the demonstration of nerve fibers and neuropeptides in the lumbar facet joint capsule but not in ligamentum flavum. *J Orthop Res*. 1992;10:72–8.

45. El-Bohy A, Cavanaugh JM, Getchell ML, Bulas T, Getchell TV, King AI, et al. Localization of substance P and neurofilament immunoreactive fibers in the lumbar facet joint capsule and supraspinous ligament of the rabbit. *Brain Res*. 1988;460:379–82.

46. Vandenabeele F, Creemers J, Lambrichts I, Robberechts W. Fine structure of vesiculated nerve profiles in the human lumbar facet joint. *J Anat*. 1995;187(Pt 3):681–92.

47. Kim J-S, Ali MH, Wydra F, Li X, Hamilton JL, An HS, et al. Characterization of degenerative human facet joints and facet joint capsular tissues. *Osteoarthritis Cartilage*. 2015;23:2242–51.

48. Wright RE, Brandt SA. S725 in vivo temperature measurement during lumbar medial branch neurotomy using a novel multitined expandable electrode. *Eur J Pain Suppl*. 2011;5:292.

49. Finlayson RJ, Thonnagith A, Elgueta MF, Perez J, Etheridge J-P, Tran DQH, et al. Ultrasound-guided cervical medial branch radiofrequency neurotomy: can multitined deployment cannulae be the solution? *Reg Anesth Pain Med*. 2017;42:45–51.

50. Hayashi K, Markel MD. Thermal capsulorrhaphy treatment of shoulder instability: basic science. *Clin Orthop Relat Res*. 2001;390:59–72.

51. Luke TA, Rovner AD, Karas SG, Hawkins RJ, Plancher KD. Volumetric change in the shoulder capsule after open inferior capsular shift versus arthroscopic thermal capsular shrinkage: a cadaveric model. *J Shoulder Elbow Surg*. 2004;13:146–9.

52. Victoroff BN, Deutsch A, Protomastro P, Barber JE, Davy DT. The effect of radiofrequency thermal capsulorrhaphy on glenohumeral translation, rotation, and volume. *J Shoulder Elbow Surg*. 2004;13:138–45.

53. Haufe SM, Mork AR. Endoscopic facet debridement for the treatment of facet arthritic pain – a novel new technique. *Int J Med Sci*. 2010;7:120–3.

54. Yeung A, Gore S. Endoscopically guided foraminal and dorsal rhizotomy for chronic axial back pain based on cadaver and endoscopically visualized anatomic study. *Int J Spine Surg*. 2014;8:23.

55. Li ZZ, Hou SX, Shang WL, Song KR, Wu WW. Evaluation of endoscopic dorsal ramus rhizotomy in managing facetogenic chronic low back pain. *Clin Neurol Neurosurg*. 2014;126:11–7.

56. Iwatsuki K, Yoshimine T, Awazu K. Alternative denervation using laser irradiation in lumbar facet syndrome. *Lasers Surg Med*. 2007;39:225–9.

57. Leon JF, Ortiz JG, Fonseca EO, Martinez CR, Cuellar GO. Radiofrequency neurolysis for lumbar pain using a variation of the original technique. *Pain Physician*. 2016;19:155–61.

58. Moussa WM, Khedr W. Percutaneous radiofrequency facet capsule denervation as an alternative target in lumbar facet syndrome. *Clin Neurol Neurosurg*. 2016;150:96–104.

59. Jacobson RE, Palea O, Granville M. Bipolar radiofrequency facet ablation of the lumbar facet capsule: an adjunct to conventional radiofrequency ablation for pain management. *Cureus*. 2017;9:e1635.

60. Palea O, Andar HM, Lugo R, Granville M, Jacobson RE. Direct posterior bipolar cervical facet radiofrequency rhizotomy: a simpler and safer approach to denervate the facet capsule. *Cureus*. 2018;10:e2322.

IPR2024-01211
Avanos v. Stratus
Stratus Ex. 2005