Mechanical Manipulation of Thrombus: Coronary Thrombectomy, Intracoronary Clot Displacement, and Transcatheter Aspiration

Jacob Shani, MD, Meyer Abittan, MD, Francesca Gallarello, MD, and Robert Frankel, MD

Recanalization of occluded arteries during acute myocardial infarction has been proven to prolong life and improve left ventricular function. Patients who could not receive thrombolytic therapy for failed thrombolysis and/or angioplasty were treated by mechanical manipulation of the thrombus. Three techniques were used: transcatheter aspiration, clot displacement, and thrombectomy. Five patients in shock had the thrombus aspirated from the left main and right coronary arteries. Eight patients had the clot pushed by the balloon from the mid-left anterior descending (LAD) to the apical LAD in order to reduce the area of ischemic myocardium, and 13 patients underwent a thrombectomy of the right coronary artery. These procedures enjoyed a high rate of success in reestablishing patency and a favorable long-term clinical and angiographic follow-up. Although the applicability and role of these interventions in acute myocardial infarction are not yet defined, we conclude that they are feasible and have an acceptable success and complication rate.

(Am J Cardiol 1993;72:116G–118G)

From the Division of Cardiology, Department of Medicine, Maimonides Medical Center & Health Science Center at Brooklyn SUNY, Brooklyn, New York.

Address for reprints: Jacob Shani, MD, Cardiac Cath Laboratory, Maimonides Medical Center, 4802 Tenth Avenue, Brooklyn, New York 11219.

Since the report of DeWood et al[1] in 1980 that the majority of patients with acute myocardial infarction have a thrombotic occlusion, different antithrombotic therapies have been developed. The most commonly used methods are thrombolytic therapy and balloon angioplasty. Early revascularization usually improves left ventricular function[2] and survival.[3] However, in some patients treated with thrombolysis and/or angioplasty, the thrombus is not disrupted and other methods of arterial recanalization should be considered. We report several alternative approaches to coronary recanalization in patients with acute myocardial infarction who failed thrombolysis and/or percutaneous transluminal coronary angioplasty (PTCA), had a contraindication to thrombolysis, or were hemodynamically compromised to the point that thrombolysis could not be administered and be effective in a reasonable amount of time. The procedures we describe are coronary thrombectomy, clot aspiration, and mechanical displacement of thrombus.

MATERIALS AND METHODS

Clot aspiration: Since 1986 we have performed this procedure in 5 patients (4 men and 1 woman) with acute myocardial infarction complicated by cardiogenic shock. Three patients had a clot in the left main coronary artery, and 2 patients had a clot at the origin of the right coronary artery.

The clots were aspirated successfully in all 5 patients by advancing an 8 F guiding catheter to the vicinity of the thrombus and applying manual suction with a 20 mL syringe. The catheter was then removed and flushed vigorously before reinsertion into the patient. The procedure was always followed by PTCA. Clots were present and confirmed histologically in all 5 patients.

Mechanical displacement of thrombus: This procedure was performed in 8 patients with evidence of thrombus in the mid or interventricular left anterior descending (LAD) artery (Table I). Of the 8, 4 patients had acute anterior wall myocardial infarction and the other 4 had severe

IMPERATIVE Ex. 1024
IPR Petition - US 11,744,691

ischemia as a result of thrombus formation and/or disruption during PTCA. The 4 patients with the acute myocardial infarction had an occluded artery that was only partially recanalized by PTCA because of a large clot burden. All 8 patients had severe chest pain associated with ischemic electrocardiographic changes.

The procedure was performed in the following way: the left main coronary was cannulated with an 8 F guiding catheter and a 0.014 High Torque floppy wire (Advanced Cardiovascular Systems, Santa Clara, CA) was advanced into the distal LAD. A balloon angioplasty catheter was advanced proximally to the thrombus and inflated to 1–2 atm of pressure. The balloon was then advanced all the way to the apical LAD, dragging the thrombus with it and relocating it in the apical LAD. Once the thrombus was deposited in the apical segment of the LAD, urokinase 250,000–500,000 IU was infused through the balloon in the vicinity of the thrombus over 30–60 minutes.

Coronary thrombectomy: Since 1986 we have performed this procedure on 13 patients who had either a contraindication to thrombolysis, failed thrombolysis and/or PTCA, or when rapid intervention was essential because of hemodynamic compromise. The procedure was performed only in the right coronary artery (Table II). Thrombus removal was accomplished by advancing the balloon over the wire to a point distal to the thrombus. The guiding catheter was then seeded deeply in the right coronary artery and the balloon was inflated to 1–2 atm and slowly withdrawn into the guiding catheter. The entire system was then removed and flushed vigorously. Clots were removed in 9 patients. In some of the patients, the procedure was followed by the administration of intracoronary urokinase.

TABLE I Mechanical Displacement of Thrombus

	No.	%
Patients	8	—
Males	7	88
LAD	8	100
Age (yr)	63 ± 11	—
Acute MI	4	50
PTCA complication	4	50
Urokinase infusion	8	100
Emergency CABG	0	0
Death	0	0
Procedural success	8	100
Clot displacement	6	75

CABG = coronary artery bypass grafting; LAD = left anterior descending artery; MI = myocardial infarction; PTCA = percutaneous transluminal coronary angioplasty.

TABLE II Coronary Thrombectomy

Patients (n)	13
Age (yr)	58–84 (mean, 69)
Males (n)	10
RCA (n)	13
EF	0.24–0.48,0,36
Acute MI (n)	11 (85%)
Shock (n)	6 (46%)
During PTCA (n)	2 (15%)
Thrombolysis (n)	10 (77%)
IABP (n)	11 (85%)
Primary success (n)	10 (77%)

EF = ejection fraction; IABP = intra-aortic balloon pump; MI = myocardial infarction; PTCA = percutaneous transluminal coronary angioplasty; RCA = right coronary artery disease.

TABLE III Thrombectomy Complications

	No.	%
Unsuccessful thrombectomy	3	23
Mortality	2	15
Recurrent thrombosis within 24 hours	3	23
V TACH/V FIB	4	31
Emergency CABG	1	7
Vascular repair	1	7

CABG = coronary artery bypass surgery; V FIB = ventricular fibrillation; V TACH = ventricular tachycardia.

RESULTS

Clot aspiration: The clot was removed successfully in all 5 patients (Figure 1 demonstrates a clot being aspirated from the left main coronary artery). Of the 3 patients with left main thrombosis, 1 died 4 days after the procedure and another had sudden death 3 months after discharge. The other 3 patients are alive after elective bypass surgery at a follow-up period of 32, 43, and 67 months.

Mechanical displacement of thrombus: The clot was removed from its original site in the mid or interventricular LAD in 6 of the 8 patients (Table I). The other 2 patients required additional balloon inflations and thrombolysis at the original site in order to achieve patency. All of the patients were successfully discharged from the hospital. During a follow-up period extending over 6–43 months, 1 patient underwent coronary artery bypass grafting (CABG), 2 patients had repeat PTCA, and in 3 patients coronary angiography demonstrated a widely patent artery with no evidence of restenosis. The remaining 2 patients are clinically stable, 1 with stable exertional angina and the other is symptom free.

Coronary thrombectomy: This procedure was attempted in 13 patients, achieving success in 10 (77%) (Table II). The in-hospital mortality was 16% (2 patients). Three patients had recurrent thrombosis (23%) and 1 required emergency CABG (7%) (Table III). One patient died 14 months after discharge. In a follow-up period of 3–64 months (mean, 30 ± 16 months), there are 9 (69%) survivors. Repeat coronary angiography in 6 of the 9 survivors revealed restenosis in 2 (both underwent successful PTCA) and no evidence of restenosis in 4 patients.

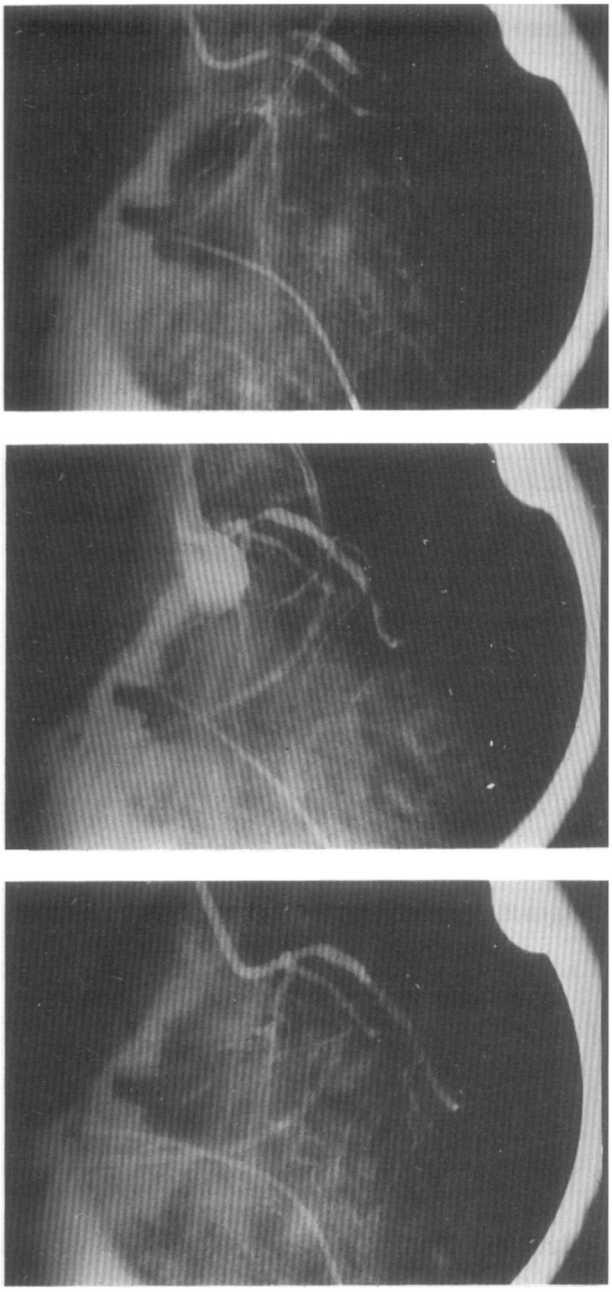

FIGURE 1. *Top:* Catheter aspiration of a large thrombus in the left main coronary artery. *Middle:* The left main coronary artery after clot aspiration. *Bottom:* A widely patent left main coronary artery after angioplasty.

DISCUSSION

The concept of removing emboli with a catheter was introduced by Fogarty et al in 1963.[4] Since then, several reports of transcatheter aspiration thromboembolectomy from peripheral vessels,[5,6] vein grafts,[7,8] and the right coronary artery[9,10] have been published. All the reports in the literature consist of case reports[11] or descriptions of small retrospective series. The pooled data, however, suggest that transcatheter aspiration thromboembolectomy or intracoronary thrombectomy is reasonably successful and has a low complication rate. Risks that should be considered for this procedure include systemic embolization, intimal damage that may predispose to future thrombus formation and restenosis, distal embolization, and spasm. It is worthwhile to note that none of our patients who were restudied revealed new lesions in the areas that were exposed to friction by the advancing (mechanical displacement) or withdrawing (thrombectomy) balloon.

Although in some cases, the thrombus is actually removed, it is possible that residual thrombus remains in the coronary and is not evident angiographically. This is particularly true when the thrombus mass is being debulked by forward displacement. Therefore, it is important, when possible, to treat the patients also with thrombolytic therapy and long-term anticoagulation. The forward displacement of the clot to the apical LAD achieves a secondary goal, i.e., decreasing the area of ischemic myocardium by occluding a distal end artery instead of the midsegment of the LAD.

Coronary thrombectomy and aspiration thrombectomy are procedures that were not studied in a prospective comparative study and, therefore, the general applicability of the procedure is uncertain. However, in a particular patient, especially one in shock, when rapid recanalization is essential, these procedures should be considered. As evident from the results in this small retrospective series, mechanical manipulation of thrombus is feasible, has a good success rate, and leads to rapid recanalization.

REFERENCES

1. DeWood MA, Spores J, Notske R, Mouser LT, Burrough R, Golden MS, Long HT. Prevalence of coronary occlusion during the early hours of transmural myocardial infarction. *N Engl J Med* 1980;303:897–902.
2. White MD, Norris RM, Brown MA. Effect of intravenous streptokinase on left ventricular function and early survival after acute myocardial infarction. *N Engl J Med* 1987;317:850–855.
3. Gruppo Italiano per lo Studio della Streptochinasi nell'Infarto Miocardico (GISSI). Effectiveness of intravenous thrombolytic treatment in acute myocardial infarction. *Lancet* 1986;i:397–401.
4. Fogarty TJ, Cranley JJ, Krause RJ, Strasser ES, Hafner CD. A method for extraction of arterial emboli and thrombi. *Surg Gynecol Obstet* 1963;116:241–244.
5. Sniderman KW, Boduen L, Saddeknis, Srur MI, Sos TA. Percutaneous embolectomy by transcatheter aspiration. *Radiology* 1984;150:357–361.
6. Starck EE, McDermott JC, Crummy AB, Turnipseed WD, Acher CW. Percutaneous aspiration thromboembolectomy. *Radiology* 1985;156:61–66.
7. Feldman RC. Transcatheter aspiration of thrombus in an aortocoronary saphenous vein graft. *Am J Cardiol* 1987;60:379–380.
8. Kahn JK, Hartzler GO. Thrombus aspiration in acute myocardial infarction. *Cathet Cardiovasc Diagn* 1990;20:54–57.
9. Broun SE, Segar DS, Weinberg BA, Bourdillon PDV, Dillon JC. Transcatheter aspiration of intracoronary thrombus after myocardial infarction. *Am Heart J* 1990;120:688–690.
10. Reeder GS, Lapeyre AC, Edwards WD, Holmes DR Jr. Aspiration thrombectomy for removal of coronary thrombus. *Am J Cardiol* 1992;70:107–110.
11. Kipperman RM, Feit AS, Einhorn MA, Co JA. Intracoronary thrombectomy: a new approach to total occlusion. *Cathet Cardiovasc Diagn* 1989;18:244–248.