GASTROENTEROLOGY 2002;122:1216–1225

Eosinophilic Esophagitis in Children: Immunopathological Analysis and Response to Fluticasone Propionate

JONATHAN E. TEITELBAUM,* VICTOR L. FOX,* FRANK J. TWAROG,† SAMUEL NURKO,* DON ANTONIOLI,§ GERALD GLEICH,‖ KAMRAN BADIZADEGAN,§ and GLENN T. FURUTA*

*Combined Program in Pediatric Gastroenterology and Nutrition, §Department of Pathology, and †Division of Allergy and Immunology, Children's Hospital, Harvard Medical School, Boston, Massachusetts; and ‖Department of Dermatology, University of Utah, Salt Lake City, Utah

Background & Aims: **Eosinophilic esophagitis (EE) shares symptoms with gastroesophageal reflux disease but has distinctive pathologic features and unknown immunopathology. Treatments with antigen restriction or systemic immunosuppression pose problems with compliance and side effects. Topically applied steroids offer an attractive alternative treatment. The aims of this study were to determine the immunopathologic features of EE and the effectiveness of antigen-specific diet restriction (DR) and topical immunosuppression.** ***Methods:*** **A prospective trial was conducted examining the impact of DR and swallowed fluticasone propionate (FP) on pediatric patients with EE. Clinicopathologic features, including immunohistochemical analysis of the esophageal mucosa, were measured before and after treatment.** ***Results:*** **Immunohistochemical analysis of 11 prospectively identified children showed a significantly greater number of mucosal CD3 and CD8 lymphocytes, as well as CD1a antigen-presenting cells compared with normal controls. DR did not induce clinical improvement in any patients, whereas all children who completed treatment with FP had resolution of symptoms. Posttreatment analysis of proximal and distal esophageal mucosa showed a significant reduction in the number of eosinophils, as well as $CD3^+$ and $CD8^+$ lymphocytes compared with pretreatment sections.** ***Conclusions:*** **EE is characterized by immunologically active esophageal mucosa. FP, not DR, effectively relieves symptoms. FP significantly reduces mucosal inflammation associated with EE.**

Eosinophilic esophagitis (EE) is an increasingly recognized clinicopathologic entity.[1] Since 1995, at least 81 pediatric patients have been reported in the literature, and clinical practice suggests that the number of affected patients is increasing.[2–7] Symptoms are similar to those seen with gastroesophageal reflux disease (GERD) and include vomiting, dysphagia, refusal of food, and abdominal pain. These symptoms are not completely responsive to acid blockade and/or prokinetic treatment of GERD. In fact, patients with EE are often referred to a gastroenterologist for refractory GERD symptoms either before or after fundoplication. Further clinical evaluation shows normal pH probe monitoring of the distal esophagus and often a characteristic endoscopic appearance with furrowing or rings of the proximal and/or distal esophagus.[6,8] Distinctive pathologic features occur in the proximal as well as distal esophagus and include mucosal eosinophilia, defined as large numbers of eosinophils (>15/high-power field) in the squamous epithelium, superficial layering of the eosinophils, and/or superficial eosinophil microabscesses (>4 eosinophils in a cluster) after at least 2 months of acid blockade.[7] Despite increasing knowledge regarding the clinicopathologic features of this condition, little is presently known about its pathogenesis. Clinical and laboratory evidence suggests that food and/or aeroallergens may be the etiologic agents.[3,9] We hypothesize that this disease is a disorder of immune dysregulation and that the use of a topical steroid would alleviate its symptoms and improve its histologic features.

Several treatments, including a strict elemental diet and systemic corticosteroids, effectively resolve symptoms and eliminate histopathologic features of EE.[3,4] However, both of these treatments pose problems for pediatric patients. Compliance with a strict elemental diet is often difficult, and systemic corticosteroids can impair growth, increase susceptibility to infections, suppress adrenal function, and cause cataracts. In 1998, Faubion et al. reported the successful use of a novel treatment method in which patients swallowed metered doses of a trifluorinated steroid preparation, fluticasone propionate (FP).[2] This treatment resulted in improvement in symptoms and reduction of esophageal eosino-

Abbreviations used in this paper: DR, diet restriction; EE, eosinophilic esophagitis; FP, fluticasone propionate; GERD, gastroesophageal reflux disease.

© 2002 by the American Gastroenterological Association
0016-5085/02/$35.00
doi:10.1053/gast.2002.32998

Dr. Falk Pharma v. Ellodi Pharmaceuticals
IPR2025-00052
Dr. Falk Pharma Ex. 1033

philia. Several features make FP desirable for use in children. It is easily administered, has low gastrointestinal absorption, and is rapidly metabolized in the liver by first-pass effect, thus limiting systemic side effects.[10]

In this study, we begin to define the immunotypical features of the mucosa affected with EE. In addition, we performed an open-label, prospective trial to determine whether the use of diet restriction (DR) or swallowed FP metered-dose units would diminish symptoms and induce a histologic remission.

Materials and Methods

Patient Selection

To identify children with EE, patients were enrolled in a prospective manner from the outpatient clinic population of the Division of Gastroenterology and Nutrition at Children's Hospital in Boston according to an institutional review board–approved protocol. Informed consent was obtained on enrollment. Children aged 1–19 years were enrolled if they met the following inclusion criteria: (1) upper intestinal symptoms including chest pain, food impaction, dysphagia, feeding refusal, or vomiting; and (2) lack of clinical response to an 8-week trial of a proton pump inhibitor (omeprazole 10 mg orally twice daily if $<$20 kg, 20 mg orally twice daily if $\geq$20 kg). Exclusion criteria included developmental delay or the use of systemic or inhaled corticosteroids in the preceding 6 months.

Following enrollment, patients underwent esophagogastroduodenoscopy and biopsy specimens were obtained from the proximal and lower thirds of the esophagus. The distal esophageal biopsy specimen was obtained at least 2 cm above the gastroesophageal junction. Routine biopsy specimens were also obtained from the antrum and duodenum. Twenty-four–hour distal esophageal pH monitoring was performed after the cessation of acid-suppressive therapy for at least 2 days. Proper placement of the pH probe catheter was confirmed radiologically. Normal 24-hour pH probe monitoring results were defined by a reflux index (the total percentage of time during which the esophageal pH is $<$4) $\leq$7%.[11] All patients underwent contrast radiographic testing (upper GI) to rule out anatomic obstruction. A diagnosis of GERD was made if pH probe monitoring was abnormal.

Children with EE, defined by the presence of a normal pH probe and the histologic findings in esophageal mucosal biopsy specimens as previously summarized, were referred to a pediatric allergist (F. J. T.) who sought to determine any relation between intake of specific foods and onset of gastrointestinal symptoms. In addition, he obtained a detailed personal and family history focused on atopic diseases. Immuno-Cap radioimmunosorbent testing (Phadiatop, Uppsala, Sweden) and/or skin-prick testing was performed for pertinent foods and/or inhalant allergens on some patients, depending on the association of symptoms with specific foods. Patients who were skin tested by the allergist received 32 common food antigens, including beef, chicken, lamb, pork, codfish, turkey, salmon, tuna, lobster, corn, clam, shrimp, rice, wheat, cashew, cocoa, almond, string bean, walnut, soybean, peanut, pea, potato, orange, egg white, apple, whole milk, peach, casein, and strawberry by skin-prick testing. A complete blood count with differential was obtained. Peripheral eosinophilia was defined as a total eosinophil count $>$350/mm^3. If radioimmunosorbent test or skin-prick test results were abnormal, the patient was referred to a pediatric dietitian for complete exclusion of that food from the diet. DR for foods was based on these test results as well as any historical factors that became evident during this evaluation. If no allergen was identified during the visit with the allergist, the patient was referred back to the gastroenterologist for medical treatment as defined.

After 8 weeks of DR, all patients were reevaluated. If they had persistence of symptoms despite strict adherence to the diet, they were placed on FP (2–4 years old, 44 μg/puff; 5–10 years old, 110 μg/puff; 11 years and older, 220 μg/puff) 2 puffs by mouth twice daily swallowed without inhaling and without use of a spacing device. Patients were instructed not to eat or drink for 30 minutes after taking the medication. All patients underwent repeat esophagoscopy and biopsy after 8 weeks of FP treatment for visual assessment of the mucosa and procurement of mucosal pinch biopsy specimens.

Compliance was assessed by self-reporting from the parents and, when appropriate, by the patient. Inhaler monitoring units (Meditrac, Hudson, MA) were used to assess the compliance of FP inhalations administered to some patients. These units monitor the daily dosing on a computer chip and can be downloaded to determine day-to-day compliance.

Histologic Analysis

All specimens were formalin-fixed, paraffin-embedded, cut serially in 5-μm sections, and either stained with H&E or used for immunohistochemical studies. For immunohistochemical staining, sections were dewaxed in xylene, rehydrated in graded solutions of ethanol, and equilibrated in aqueous buffer. Endogenous peroxidase activity was quenched with 3% aqueous hydrogen peroxide for 15 minutes at room temperature. The sections were then incubated with 10% nonimmune goat serum (Signet, Dedham, MA) for 10 minutes; primary antibody, CD1a (undiluted; Immunotech, Marseille, France), CD8 (1:100 dilution; Dako, Carpinteria, CA), CD3 (undiluted; Biogenex, San Ramon, CA), and cutaneous lymphocyte antigen (1:100; Boehringer Mannheim, Basel, Switzerland) for 1 hour; biotinylated secondary antibody (Signet) for 15 minutes; and avidin-biotin complex (Signet) for 15 minutes. All incubations were performed at room temperature, and sections were washed with buffer between steps. Color reaction was then developed using the diaminobenzidine method according to the manufacturer's instructions (Zymed, South San Francisco, CA). Sections were counterstained with hematoxylin, dehydrated, and mounted. Appropriate positive and negative controls were included in each staining reaction. Biopsy specimens obtained from patients undergoing evaluation for abdominal pain or other upper intestinal symptoms as a part of

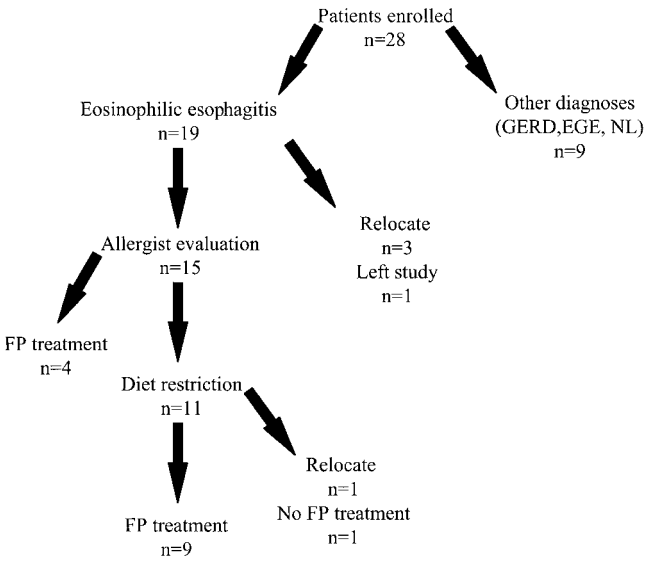

Figure 1. Flowchart of patients.

a separate institutional review board–approved protocol with histologically normal mucosa were used as negative controls. The control group consisted of 3 boys and 4 girls (ages 10 ± 1.5 years). One had a history of asthma and allergic rhinitis.

Mucosal biopsy specimens obtained at esophagogastroduodenoscopy were reviewed in a blinded fashion using coded slides without knowledge of the history, mode of therapy, or endoscopic appearance. Histologic evaluation of those esophageal biopsy specimens stained with H&E was undertaken using the methods previously described.[7] Quantification of eosinophil number and immunoreactive cells for the above antigens was performed by 2 of the investigators (G. T. F. and K.B.), who counted the number of cells in each biopsy specimen in 5 consecutive high-power fields in the area with the densest infiltrate. Findings were reviewed and discrepancies noted. Data were expressed as the mean number of eosinophils per high-power field (Nikon Optiphot-2, Plan 40 lens; Melville, NY) or as the mean number of lymphocytes per high-power field (Olympus BH2- Splan 40 lens; Melville, NY). Ocular magnification was 10, and the area of the microscopic field was 0.196 mm^2 (Nikon) and 0.12 mm^2 (Olympus). The distribution of the eosinophils within the squamous epithelium was also assessed. Measurements of the epithelial thickness and papillary height were made only on specimens in which at least 3 well-oriented papillae could be identified. Measurements were considered abnormal if there was basal zone hyperplasia >20% of the total epithelial thickness or lengthening of the papillae to ≥75% of the epithelial height. Quantification of positively stained cells for each of the selected antibodies was performed in the same manner as described for quantification of eosinophil numbers.

Statistical Analysis

Results are reported as mean ± standard error. Student *t* test for paired data was used to assess the differences between the mean data obtained from each group. Statistical significance was determined by an α level *P* value <0.05.

Results

Clinical Features

Twenty-eight patients were enrolled in this study from November 1998 to March 2001 (Figure 1). Nineteen patients had a normal pH probe, >15 eosinophils/high-power field in the esophageal mucosa after at least 2 months of acid blockade, and no evidence of eosinophilia on gastric or duodenal biopsy specimens; these patients were considered the index population with EE (see Table 1 for clinical features). The remaining 9 patients received diagnoses of GERD (n = 7) or eosinophilic gastroenteritis (n = 1), and studies were normal in 1 patient. These patients (n = 9) were excluded from the final analysis. Of the 19 patients with EE, 3 relocated before completion of the study and 1 decided not to complete the study.

Presenting symptoms of the 19 children with EE are noted in Table 1. Vomiting and dysphagia were most commonly reported. Food allergy, reactive airway disease, allergic rhinitis or conjunctivitis, or atopic dermatitis were identified in the personal history (84%) or family history (58%) of affected patients. Peripheral eosinophilia was noted in 58% (mean total eosinophil count, 555 ± 88 eosinophils/mm^3). Before enrollment in the study, 1 patient underwent fundoplication for GERD symptoms refractory to medical management. One patient had a history of culture-proven herpes esophagitis without esophageal eosinophilia 2 months before the onset of EE. On entry into the study, his biopsy specimens showed no viral inclusions and cultures were negative for herpes simplex virus. Upper gastrointestinal series was normal in all patients studied.

Table 1. Clinical Features of 19 Pediatric Patients With EE

Mean age at presentation (*yr*)	8 ± 0.9 (range, 1–16)
Sex (M/F)	14/5
Duration of symptoms before diagnosis of EE (*yr*)	2.3 ± 0.6
Presenting complaints[a] (%)	
Dysphagia	11 (58)
Vomiting	8 (42)
Heartburn	7 (37)
Abdominal pain	6 (32)
Food impaction	2 (11)
Failure to thrive	2 (11)
Diarrhea	1 (5)
Family history of allergic disease (%)	11 (58)
Personal history of allergic disease (%)	16 (84)
Peripheral eosinophilia (%)	11 (58)

[a]Some patients had more than 1 presenting symptom.

Table 2. Summary of Allergic Evaluations for 15 Patients With EE

	History of reaction	Skin test positive	RAST test positive	Food eliminated
1	none	egg, orange	milk	egg, orange
2	peanut, milk, soy, shellfish, watermelon			peanut, milk, soy, shellfish, watermelon
3	none		peanut, wheat	peanut, wheat
4	none	cocoa		chocolate
5	peanut	peanut, soy		peanut, soy
6	none	peanut, soy, milk, wheat, corn, almond, beef	peanut	peanut, milk, soy, wheat
7	peanut, soy, wheat, carrot	soy, wheat	positive for all tested foods	restricted peanut, soy, wheat and carrot—primarily ate potatoes, bacon, and chocolate
8	none			
9	tree nuts	peanuts, soy, tree nuts, carrots, pear, grapes, rice, green beans, mustard seed, onion, kidney beans	peanuts, soy, tree nuts	peanuts, soy, tree nuts, carrots, green beans
10	peanuts	soy, egg, wheat, potato	peanut, soy	peanut, soy
11	shellfish		shellfish, tree nuts, fish	shellfish, tree nuts
12	none			
13		egg, wheat, chicken, barley, oats		egg, wheat, chicken, barley, oats
14	none			
15	none			

RAST, radioimmunosorbent.

Evaluation by the allergist was completed in 15 patients, and 11 had specific food(s) identified that were associated with gastrointestinal symptoms (Table 2). Positive skin tests were found in 8 patients, and 7 had elevated radioimmunosorbent analysis. Two patients reported anaphylactic symptoms to specific foods (shellfish and peanuts). From this group, 11 patients were treated with DR. When multiple food allergens were identified, common food antigens or foods associated with symptoms were excluded. No food allergens were identified in 4 patients, and they were treated with FP directly. All patients receiving DR underwent counseling with a pediatric dietician to strictly remove the food(s), and compliance was documented to be complete by self-reporting. Two patients (9 and 10) were unable to adhere to a diet restricted of all allergenic foods identified; the diet with which they complied appears in Table 2. An 8-week trial of specific food elimination did not improve clinical features of EE in any patient in this series.

FP

Of the 11 patients who did not respond to DR, 9 received FP, 1 relocated before the end of the study, and 1 was not interested in FP treatment despite ongoing symptoms. Patients received instructions from a clinician to ensure proper administration of FP using the swallowing technique. Two patients used the Meditrac monitor during the study. Both patients demonstrated proper and complete use. In the remaining patients, compliance (as assessed by self-reporting from the parents and patient) was reported to be complete.

All 13 patients completing treatment with FP had resolution of their presenting symptom. Two patients did not have an endoscopy after treatment with FP. Posttreatment endoscopy of the remaining 11 patients completing treatment with FP showed an abnormal visual appearance of the esophagus in 9 patients, with loss of vascular pattern or thickened longitudinal folds suggesting ongoing inflammation. However, the microscopic findings were improved in all patients. These findings show that the macroscopic appearance does not predict the microscopic features of EE, consistent with previous pediatric studies.[12,13]

The only side effect of FP identified in those completing treatment was esophageal *Candida* infection (2 patients). Of these patients, 1 was asymptomatic and 1 had recurrence of previous upper intestinal symptoms at the end of treatment with FP. In these patients, endoscopy performed at the end of treatment with FP showed histologic improvement of EE but the presence of *Candida* plaques. Both patients were treated with fluconazole without adverse effect.

Immunopathologic Features of EE Before Treatment With FP

Eleven patients completed treatment with FP and underwent both pretreatment and posttreatment endoscopy. Immunopathologic analysis was performed on

esophageal sections from all 11 patients. The pretreatment esophageal specimens contained large numbers of eosinophils in the proximal and distal esophageal mucosa (22.5 ± 4.9 and 23 ± 2.7, respectively; Figure 2*A* and *C*), consistent with previous reports. Mucosal specimens showed superficial localization of eosinophils in 6 (54%) and eosinophil abscesses in 5 (45%), consistent with our previous findings.[7] A representative example of the proximal esophagus is shown in Figure 2*A*.

We next characterized the lymphocyte population of the affected esophagus. Previous reports have suggested that lymphocytes normally reside in the esophageal epithelium and this population can fluctuate according to states of either immunodeficiency or inflammation.[14] Immunohistochemical staining in the proximal esophageal mucosa of patients affected by EE showed significantly greater numbers of CD3 lymphocytes, often termed "cells with irregular nuclear contours," compared with the normal controls (28.2 ± 4.5 vs. 5.5 ± 2.3, respectively; $P < 0.05$) (Figure 3*A* and *C*). CD3 lymphocytes were diffusely scattered throughout the esophageal mucosa in no obvious pattern. In an effort to identify specific T-cell populations in the EE group, tissue sections were stained for CD8. Affected tissues showed a significant increase in CD8 cells compared with normal controls (20.2 ± 8.1 vs. 5.9 ± 2.8, respectively; $P < 0.05$) (Figure 3*D* and *F*). CD8 lymphocytes were diffusely scattered throughout the esophageal mucosa in no obvious pattern.

We next looked at the numbers of CD1a dendritic cells, or Langerhans-type cells. $CD1a^+$ cells are primarily located at mucosal surfaces. These cells likely function as antigen-presenting cells and in allergic conditions participate in host sensitization.[15,16] We found a significant increase in the CD1a in the EE group compared with normal mucosa (9.4 ± 1.5 vs. 5.7 ± 2.1, respectively; $P < 0.05$) (Figure 3*G* and *I*).

Atopic dermatitis is an allergic condition associated with eosinophilia of the squamous epithelium of the skin.[17] Because the esophagus is lined with squamous cells and patients with EE can be affected by atopic dermatitis, we examined the esophagus for the expression of cutaneous lymphocyte antigen. Cutaneous lymphocyte antigen is the memory T-cell marker that increases in the skin affected with atopic dermatitis and decreases after treatment with corticosteroids.[18] Immunohistochemical staining showed no differences between the naive, untreated mucosa affected with EE and the normal squamous epithelium (2.6 ± 1.6 vs. 2.6 ± 1.3, respectively; not significant).

Impact of FP Treatment on Esophageal Histology

We next examined the impact of FP on the esophageal eosinophilia associated with EE. The use of FP for 8 weeks resulted in a significant decrease in the eosinophilia in both the proximal and distal esophagus (Table 3 and Figure 2*B* and *C*). After treatment with FP, a decrease in the $CD3^+$, $CD8^+$, and $CD1a^+$ cells was seen in the proximal and distal esophagus. These differences reached statistical significance in the proximal esophagus for all examined cell types and in the distal esophagus for $CD3^+$ and $CD8^+$ cells (Table 3 and Figure 3*B*, *C*, *E*, *F*, *H*, and *I*). In addition, cell counts returned to that of normal esophageal sections except for $CD3^+$ cells in the proximal esophagus. No significant differences were identified between observers in cell counting of eosinophils or immunostained cells.

Discussion

This study defined certain immunophenotypic characteristics of EE and determined the impact of FP on clinical and immunopathologic features. Histologic examination of the untreated esophageal mucosa showed not only an increase in the number of eosinophils but also a significant increase in the numbers of CD8 lymphocytes and CD1a antigen-presenting cells. Swallowing of metered-dose units of aerosolized FP not only improved clinical symptoms but also significantly reduced the numbers of activated inflammatory cells. However, DR, guided by skin testing and radioimmunosorbent analysis, did not improve symptoms. These results suggest that the anti-inflammatory agent FP is an effective treatment in reducing the clinical features and inflammatory lesions associated with EE.

Although the esophagus has been traditionally considered a conduit for oral contents to the stomach, little is known about the immunotypical features of the normal and the inflamed esophageal mucosa.[19–22] Previous reports identified the presence of dendritic cells/Langerhans cells and lymphocytes within the normal esophageal mucosa and showed that lymphocytes do not significantly increase during states of peptic inflammation.[19] In contrast, the squamous mucosa from patients with acquired immunodeficiency syndrome contains decreased CD1a lymphocytes compared with controls.[23] In the present study, CD3, CD8, and CD1a lymphocytes are increased within the affected mucosa compared with normal tissue. Taken together, these results suggest that the esophagus is an immunologically active organ that may respond differently to a variety of stimuli.

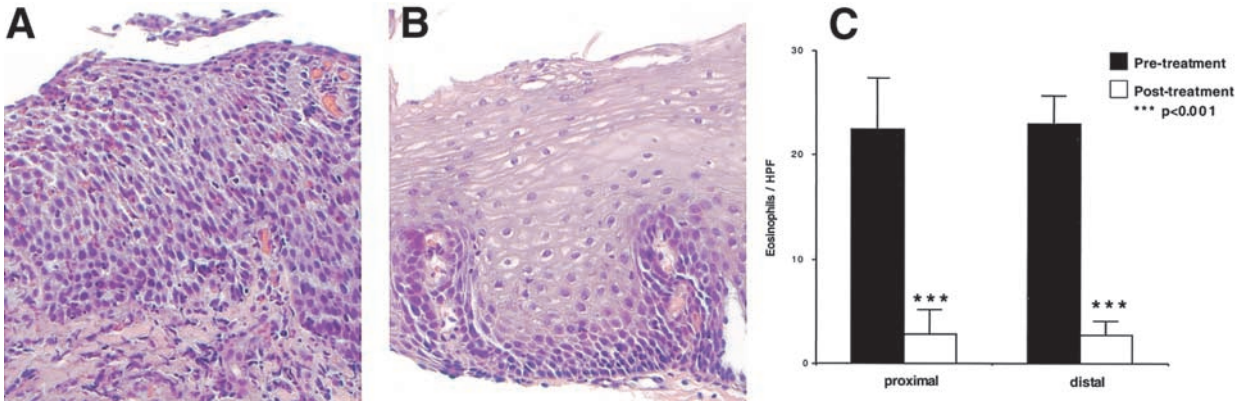

Figure 2. Impact of FP on esophageal eosinophilia. Mucosal pinch biopsy specimen of proximal esophageal mucosa affected with EE. The section is stained with H&E, and (*A*) is taken from an untreated patient. (*B*) The same patient after 8 weeks of treatment with FP. (*C*) The mean eosinophil counts before and after treatment. (Original magnification 200×.)

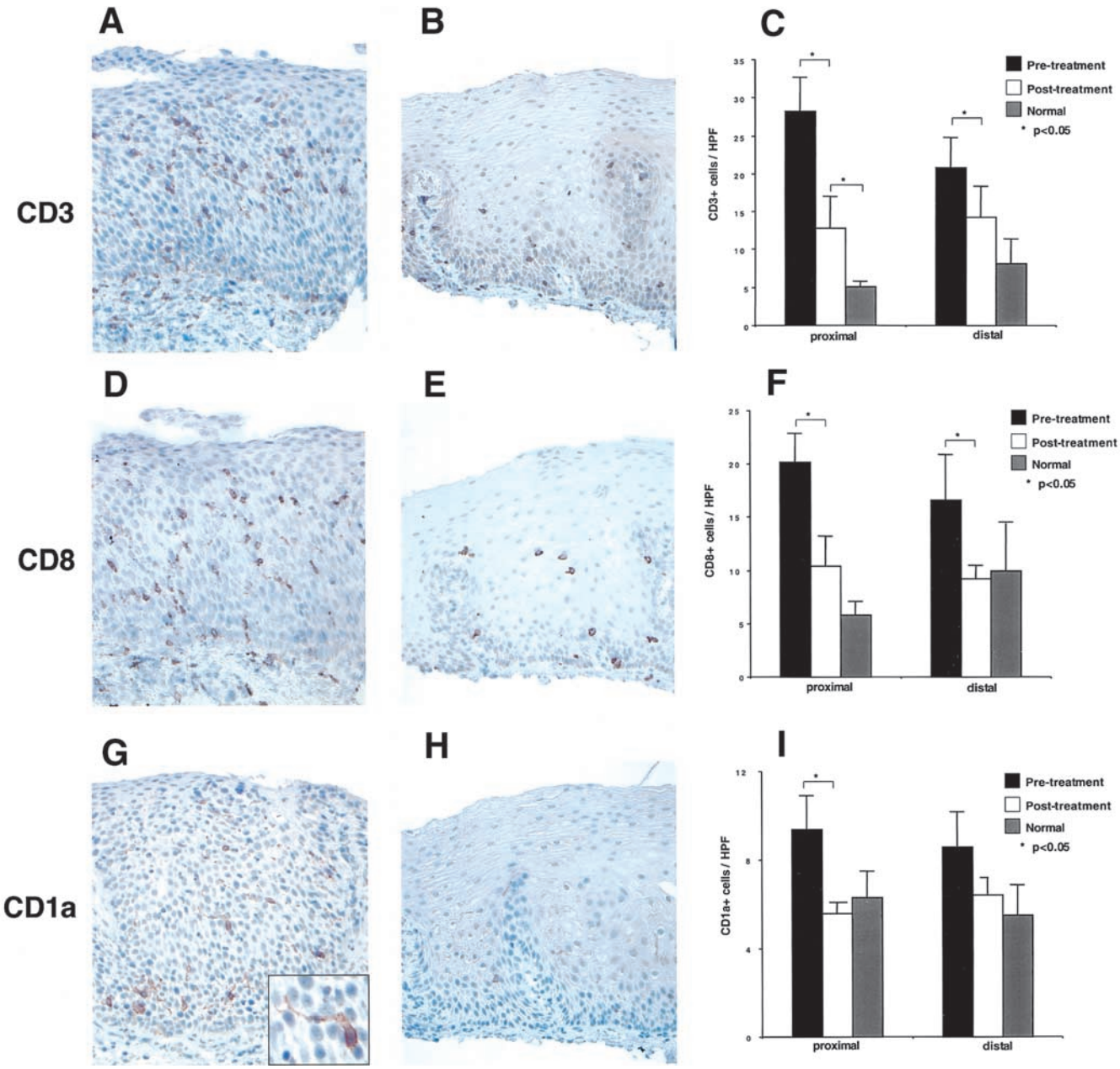

Figure 3. Impact of FP on (*A–C*) CD3, (*D–F*) CD8, and (*G–I*) CD1a lymphocytes. Mucosal pinch biopsy specimen of proximal esophageal mucosa showing (*A–C*) CD3, (*D–F*) CD8, and (*G–I*) CD1a lymphocytes. Paraffin-embedded sections were stained with (*A–C*) CD3, (*D–F*) CD8, and (*G–I*) CD1a by avidin-peroxidase methods. *A*, *D*, and *G* were taken from an untreated patient. *B*, *E*, and *H* are from the same patient after 8 weeks of treatment with FP. *C*, *F*, and *I* represent the mean CD3, CD8, and CD1a counts, respectively, from pretreatment and posttreatment sections and counts from unaffected controls. (Original magnification 200×.)

Table 3. Eosinophil and CD Counts From Proximal and Distal Esophageal Sections Before and After Treatment With FP

	Pretreatment (cells/HPF ± SE)	Posttreatment (cells/HPF ± SE)	*P* value
Eosinophils			
Proximal	22.5 ± 4.9	2.8 ± 2.4	0.001
Distal	23.0 ± 2.7	2.7 ± 1.4	0.001
CD3+			
Proximal	28.2 ± 4.5	12.8 ± 4.2	0.05
Distal	20.8 ± 4.1	14.3 ± 4.1	0.05
CD8+			
Proximal	20.2 ± 2.7	10.4 ± 2.8	0.05
Distal	16.6 ± 4.3	9.2 ± 1.3	0.05
CD1a+			
Proximal	9.4 ± 1.5	5.6 ± .5	0.05
Distal	8.6 ± 1.6	6.4 ± .8	NS
CLA+			
Proximal	2.7 ± 1.6	2.2 ± 1.9	NS

HPF, high-power field.

We identified the CD8 lymphocyte as the predominant T cell within the affected squamous epithelium. CD8 lymphocytes are conventionally associated with the production of Th1-type cytokines such as tumor necrosis factor α.[24] Although not classically considered a proallergic cytokine, tumor necrosis factor α has been shown to induce eosinophilia in certain animal models. In addition, a growing body of literature shows that, in the appropriate immunologic milieu, CD8 lymphocytes are also morphologically associated with Th2 diseases and secrete Th2-type cytokines.[25–27] For instance, while atopic dermatitis is typically characterized by the predominance of CD4 lymphocytes and the production of Th2-associated cytokines such as interleukin 5, recent studies have also shown that CD8 lymphocytes present within affected tissues are an abundant source of Th2-type cytokines.[18] Although it is true that many allergic reactions are associated with CD4 cells, our results suggest the participation of CD8 lymphocytes in this eosinophil response.

Following maturation, dendritic Langerhans cells efficiently present antigen to lymphocytes.[28] We speculate that in this condition, an antigen is presented to the Langerhans cell, crosses the squamous mucosa, and stimulates T-cell proliferation and production of eosinophil chemokines such as eotaxin. Eotaxin is an eosinophil-specific chemokine that has been shown to play a critical role in homing of eosinophils to sites of intestinal allergic inflammation.[29,30] Eosinophils migrate into the tissues and, on activation, can release a variety of biologically active mediators, including cytokines, leukotrienes, and granule proteins such as major basic protein.[17,31–33] Experimental models of esophagitis have shown the presence of leukotrienes and, in patients with EE, eosinophil-derived major basic protein. Eosinophil-derived granule proteins have not only cytotoxic properties but also have been shown to stimulate superoxide generation from neutrophils,[34] smooth muscle contraction in animal models of airway hyperreactivity,[35] production of tumor necrosis factor α from mast cells,[36] and interleukin-8 release from eosinophils and intestinal fibroblasts.[37,38] Thus, the release of these eosinophil-derived granule proteins may initiate or perpetuate the inflammatory reaction seen in the esophageal mucosa. We and other investigators speculate that major basic protein initiates esophageal smooth muscle contraction leading to the symptoms of dysphagia and food impaction.[39]

The specific antigen(s) that induce this eosinophilic response remains obscure, but hypotheses suggest a food allergen, an inhaled or swallowed airborne allergen, or an infectious particle.[40,41] Kelly showed that a strict elemental diet with Neocate formula induced a clinicopathologic remission; however, symptoms recurred after the reintroduction of foods. Interestingly, the preliminary results from a recent study detail the use of an elemental diet in more than 100 children with EE. The investigators document clinicopathologic improvement; long-term follow-up of 9 months suggests continued remission.[42] In an attempt to make dietary treatment more palatable, we tried to identify specific food items that were associated with symptoms. Efforts to use this method of DR as treatment of this disease were unsuccessful. Potential reasons for this finding include incomplete DR, insensitive methods to identify the proper dietary allergen, the presence of multiple unidentified dietary allergens capable of inciting the response, or the presence of a non–food-related antigen. To address this last cause, investigators recently designed a novel murine model of EE.[9] Mice sensitized and challenged with an ubiquitous aeroallergen, *Aspergillus fumigatus*, developed not only esophageal eosinophilia but also eosinophil degranulation within the squamous epithelium. This interleukin-5–dependent response was not seen in other parts of the gastrointestinal tract. These findings present the intriguing possibility that sensitization and challenge of an inhaled allergen may result in the homing of eosinophils to the esophageal squamous epithelium. Finally, a bacterial superantigen may stimulate the T-cell–dependent influx of eosinophils as seen in atopic dermatitis.[43] Several features of EE are similar to atopic dermatitis, including the common predilection for the squamous epithelium, the characteristic epithelial eosinophilia, and the similar response to systemic and topical corticosteroids and/or a severely restricted diet. Although

our immunohistochemical staining did not show evidence of increased cutaneous lymphocyte antigen, the memory T cell associated with atopic dermatitis, we speculate that a bacterial superantigen could incite the activation of the cascade of inflammatory events seen in EE in a fashion similar to that in atopic dermatitis.

We were interested in determining the impact of FP in the treatment of EE for several reasons. First, this medication was previously used successfully in 3 pediatric patients with EE.[2] Investigators theorized that aerosolized steroid administrated into the oropharynx without a spacer would be swallowed and eventually delivered to the esophageal epithelium. In that retrospective case series, this unique technique provided prompt relief and no reported side effects. All studied patients were boys between the ages of 12 and 13 years, and none had an allergic history. The dose of FP was 220 μg by mouth, 4 puffs twice a day; duration of treatment ranged from 6 weeks to 4 months, and posttreatment biopsy specimens were obtained in 2 of 3 patients. Our prospective study used this novel treatment method to study a broader age range of both male and female patients for a defined treatment course and dose, with a more detailed analysis of the affected tissue. Our findings expand the previous findings by showing the effectiveness of FP in treating a wide range of patients with a consistent treatment plan.

The second reason we were interested in examining this treatment method is that the other effective therapies, elemental diet and systemic corticosteroids, have several disadvantages. Although the benefits of an elemental diet are clear, we have found compliance to be a major obstacle in its use. Our study patients found FP easy to administer, and compliance was good. Systemic corticosteroids are effective in treating the symptoms and reducing eosinophilia, but the fact that EE seems to be a relapsing disease prompted us to defer to a treatment with fewer side effects, such as FP. Lower doses of FP were used than in the previous trial. Proximal and distal eosinophilia was significantly reduced, indicating the likely deposition along the esophageal length. None of the studied patients developed a major complication; *Candida* esophagitis was easily cured.

Third, the impact of FP in eosinophilic disease in other organ systems has been well established. FP, a synthetic trifluorinated glucocorticoid, binds to the glucocorticoid receptor with an affinity 18 times greater than dexamethasone and twice as great as budesonide. It is primarily metabolized in the liver, and $<1\%$ of the orally administered dose is bioavailable due to presystemic metabolism and low absorption.[10] Identified side effects when the medication is used for the treatment of asthma include reduction in growth velocity (0.43 cm/yr) and adrenal suppression.[44] FP reduces not only allergic symptoms and mucosal eosinophilia but also inhibits eosinophilic chemokine and eosinophilic cationic protein release in allergic rhinitis.[45] In addition, it reduces allergic symptoms, mucosal eosinophilia, dendritic cell infiltration, adhesion molecule expression, and leukotriene C4 secretion.[46,47] Our findings show similar results with reduction in eosinophil and lymphocyte infiltrates. Although symptoms abated and esophageal eosinophilia was significantly impacted by FP, a slight degree of esophageal eosinophilia was still present in treated tissues. This is consistent with findings in other tissues affected by allergic diseases that have undergone corticosteroid treatment. For instance, asthmatic patients treated with oral prednisone have improved symptoms and reduction, but not resolution, of tissue eosinophilia.[48]

Several factors continue to pose questions and difficulty in the management of EE. First, the symptoms associated with EE are often short-lived and occur sporadically, making management problematic. This is one reason for the large number of patients who did not complete the study. When patients were asymptomatic, whether in the midst of treatment or in the untreated state, they and their parents were understandably reluctant to proceed with a second endoscopy to document histologic improvement. However, follow-up endoscopy of completely asymptomatic, untreated patients with EE shows persistent and often severe mucosal eosinophilia (unpublished data). Second, the long-term outcome of this condition is not yet clear. In the adult literature, unbridled esophageal eosinophilia can result in fibrosis and stricture.[49–51] Whether or not most pediatric patients will "outgrow" this disease as they do some other allergic diseases of childhood is a question that will only be answered by close follow-up of affected patients. Our clinical experience and the published literature suggests that this is a relapsing entity; at least 4 of the patients in this series have required subsequent courses of FP.[2–5] Third, the long-term treatment of these patients is not certain. We believe that EE is a disease characterized by an immunologically active esophageal mucosa and that FP is an effective and well-tolerated treatment. Future studies will determine the pathogenesis, long-term management, and outcome of this condition.

References

1. Attwood SEA, Smyrk TC, Demeester TR, Jones JB. Esophageal eosinophilia with dysphagia: a distinct clinicopathologic syndrome. Dig Dis Sci 1993;38:109–116.
2. Faubion WA, Perrault J, Burgart LJ, Zein NN, Clawson M, Freese DK. Treatment of eosinophilic esophagitis with inhaled corticosteroids. J Pediatr Gastroenterol Nutr 1998;27:90–93.

3. Kelly KJ, Lazenby AJ, Rowe PC, Yardley JH, Perman JA, Sampson HA. Eosinophilic esophagitis attributed to gastroesophageal reflux: improvement with an amino acid-based formula. Gastoenterology 1995;109:1503–1512.
4. Liacouras CA, Wenner WJ, Brown K, Ruchelli E. Primary eosinophilic esophagitis in children: successful treatment with oral corticosteroids. J Pediatr Gastroenterol Nutr 1998;26:380–385.
5. Orenstein SR, Shalaby TM, DiLorenzo C, Putnam PE, Sigurdsson L, Kocoshis SA. The spectrum of pediatric eosinophilic esophagitis beyond infancy: a clinical series of 30 children. Am J Gastroenterol 2000;95:1422–1430.
6. Siafakas CG, Ryan CK, Brown MR, Miller TL. Multiple esophageal rings: an association with eosinophilic esophagitis. Am J Gastroenterol 2000;95:1572–1575.
7. Walsh SV, Antonioli DA, Goldman H, Fox VL, Bousvaros A, Leichtner AM, Furuta GT. Allergic esophagitis in children: a clinicopathological entity. Am J Surg Pathol 1999;23:390–396.
8. Gupta SK, Fitzgerald JF, Chong SKF, Croffie JM, Collins MH. Vertical lines in distal esophageal mucosa (VLEM): a true endoscopic manifestation of esophagitis in children? Gastrointest Endosc 1997;45:485–489.
9. Mishra A, Hogan S, Brandt E, Rothenberg M. An etiological role for aeroallergens and eosinophils in experimental esophagitis. J Clin Invest 2001;107:83–90.
10. Harding S. The human pharmacology of fluticasone propionate. Respir Med 1990;84(Suppl A)25–29.
11. Kahrilas P, Quigley E. Clinical esophageal pH recording: a technical review for practice guideline development. Gastroenterology 1996;110:1982–1996.
12. Biller JA, Winter HS, Grand RJ, Allred EN. Are endoscopic changes predictive of histologic esophagitis in children? J Pediatr 1983; 103:215–218.
13. Shub MD, Ulshen MH, Hargrove CB, Siegal GP, Groben PA, Askin FB. Esophagitis: a frequent consequence of gastroesophageal reflux in infancy. J Pediatr 1985;107:881–884.
14. Wilcox CM. Esophagitis in the immunocompromised host. In: Castell DO, Richter JE, eds. The esophagus. Philadelphia: Lippincott Williams and Wilkins, 1999:539–555.
15. Till S, Jacobson M, O'Brien F, Durham SR, KleinJan A, Fokkens WJ, Juliusson S, Lowhagen O. Recruitment of CD1a+ Langerhans cells to the nasal mucosa in seasonal allergic rhinitis and effects of topical corticosteroids. Allergy 2001;56:126–131.
16. Lambrecht B, DeVeerman M, Coyle A, Gutierrez-Ramos J, Thielemans K, Pauwels R. Myeloid dendritic cells induce Th2 responses to inhaled antigen, leading to eosinophilic airway inflammation. J Clin Invest 2000;106:551–559.
17. Leiferman KM. Eosinophils in atopic dermatitis. J Allergy Clin Immunol 1994;94:1310–1317.
18. Akdis M, Simon H, Weigl L, Kreyden O, Blaser K, Akdis C. Skin homing (cutaneous lymphocyte-associated antigen-positive) CD8+ T cells respond to superantigen and contribute to eosinophilia and IgE production in atopic dermatitis. J Immunol 1999; 163:466–475.
19. Wang HH, Mangano MM, Antonioli DA. Evaluation of T-lymphocytes in esophageal mucosal biopsies. Mod Pathol 1994;7:55–58.
20. Yassin T, Toner P. Langerhans cells in the human oesophagus. J Anat 1976;122:435–445.
21. Terris B, Potet F. Structure and role of Langerhans cells in the human oesophageal epithelium. Digestion 1995;56:9–14.
22. Mangano M, Antonioli D, Schnitt S, Wang H. Nature and significance of cells with irregular nuclear contours in esophageal mucosal biopsies. Mod Pathol 1992;5:191–196.
23. Charton-Bain M, Terris B, Dauge M, Marche C, Walker F, Bouchaud O, Xerri L, Potet F. Reduced numbers of Langerhans cells in oesophageal mucosa from AIDS patients. Histopathology 1999;34:399–404.
24. Abbas A, Murphy K, Sher A. Functional diversity of helper T lymphocytes. Nature 1996;383:787–793.
25. Schwarze J, Cielewicz G, Joetham A, Ikemura T, Hamelmann E, Gelfand E. CD8 T cells are essential in the development of respiratory syncytial virus-induced lung eosinophilia and airways hyperresponsiveness. J Immunol 1999;162:4207–4211.
26. Schwarze J, Makela M, Cieslewicz G, Dakhama A, Lahn M, Ikemura T, Joetham A, Gelfand EW. Transfer of enhancing effect of respiratory syncytial virus infection on subsequent allergic airway sensitization by T lymphocytes. J Immunol 1999;163:5729–5734.
27. Ying S, Humbert M, Barkans J, Corrigan CJ, Pfister R, Menz G, Larche M, Robinson DS, Durham SR, Kay AB. Expression of IL-4 and IL-5 mRNA and protein product by CD4+ and CD8+ T cells, eosinophils, and mast cells in bronchial biopsies obtained from atopic and nonatopic asthmatics. J Immunol 1997;158:3539–3944.
28. Lambrecht B, Salomon B, Klatzmann D, Pauwels R. Dendritic cells are required for the development of chronic eosinophilia airway inflammation in response to inhaled antigen in sensitized mice. J Immunol 1998;160:4090–4097.
29. Hogan S, Mishra A, Brandt E, Foster P, Rothenberg M. A critical role for eotaxin in experimental oral antigen-induced eosinophilic gastrointestinal allergy. Proc Natl Acad Sci U S A 2000;97:6681–6686.
30. Hogan S, Mishra A, Brandt E, Royalty MP, Pope SM, Zimmermann N, Foster PS, Rothenberg ME. A pathological function for eotaxin and eosinophils in eosinophilic gastrointestinal inflammation. Nat Immunol 2001;2:353–360.
31. Bousquet J, Chanez P, Lacoste JY, Barneon G, Ghavanian N, Enander I, Venge P, Ahlstedt S, Simony-Lafontaine J, Godard P. Eosinophilic inflammation in asthma. N Engl J Med 1990;323: 1033–1039.
32. Levy A, Gleich G, Sandborn W, Tremaine W, Steiner B, Phillips S. Increased eosinophil granule proteins in gut lavage fluid from patients with inflammatory bowel diseases. Mayo Clin Proc 1997;72:117–123.
33. Dvorak AM, Monahan RA, Osage JE, Dickersin GR. Crohn's disease: transmission electron microscopic studies-immunologic inflammatory response. Alterations of mast cells, basophils, eosinophils, and the microvasculature. Hum Pathol 1980;11:606–619.
34. Haskell M, Moy J, Gleich G, Thomas L. Analysis of signaling events associated with activation of neutrophil superoxide anion production by eosinophil granule major basic protein. Blood 1995;86:4627–4637.
35. Flavahan NA, Slifman NR, Gleich GJ, Vanhoutte PM. Human eosinophil major basic protein causes hyperactivity of respiratory smooth muscle. Am Rev Respir Dis 1988;138:685–688.
36. Furuta GT, Ackerman SJ, Williams RE, Wershil BK. Eosinophil major basic protein induces the release of TNF-alpha and arachidonic acid mediators from mouse bone marrow derived mast cells grown in stem cell factor. Blood 1998;92:1055–1061.
37. Furuta GT, Ackerman SJ, Varga J, Spiess AM, Wang MY, Wershil BK. Eosinophil granule-derived major basic protein induces IL-8 expression in human intestinal myofibroblasts. Clin Exp Immunol 2000;122:35–40.
38. Kita H, Abu-Ghazaleh RA, Sur S, Gleich GJ. Eosinophil major basic protein induces degranulation and IL-8 production by human eosinophils. J Immunol 1995;154:4749–4758.
39. Landres R, Kuster G, Strum W. Eosinophilic esophagitis in a patient with vigorous achalasia. Gastroenterology 1978;74:1298–1301.
40. Kelly K. Eosinophilic gastroenteritis. J Pediatr Gastroenterol Nutr 2000;30:S28–S35.
41. Sondheimer J. What are the roles of eosinophils in esophagitis? J Pediatr Gastroenterol Nutr 1998;27:90–93.

42. Liacouras CA, Markowitz JE, Spergel J. Eosinophilic esophagitis in children: a 5 year review. J Pediatr Gastroenterol Nutr 2001; 33:418.
43. Akdis M, Simon HU, Weigl L, Kreyden O, Blaser K, Akdis CA. Skin homing (cutaneous lymphocyte-associated antigen-positive) CD8+ T cells respond to superantigen and contribute to eosinophilia and IgE production in atopic dermatitis. J Immunol 1999; 163:466–475.
44. Sharek P, Bergman D. The effect of inhaled steroids on the linear growth of children with asthma: a meta-analysis. Pediatrics 2000;106:E8.
45. Ventura M, Piccinni T, Matino M, Giuliano G, Di Corato R, Di Napoli P, Tursi A. Retrospective study on fluticasone propionate aqueous nasal spray efficacy in patients with allergic rhinitis: evaluation of clinical and laboratory parameters. Allergy 2001; 56:29–34.
46. Johnson M. Development of fluticasone propionate and comparison with other inhaled corticosteroids. J Allergy Clin Immunol 1998;101:S434–S439.
47. Hoogsteden H, Berhoeven G, Lambrecht B, Prins J. Airway inflammation in asthma and chronic obstructive pulmonary disease with special emphasis on the antigen presenting dendritic cell: influence of treatment with fluticasone proprionate. Clin Exp Allergy 1999;29:116–124.
48. Liu MC, Proud D, Lichtenstein LM, Hubbard WC, Bochner BS, Stealey BA, Breslin L, Xiao H, Freidhoff LR, Schroeder JT, Schleimer RP. Effects of prednisone on the cellular responses and release of cytokines and mediators after segmental allergen challenge of asthmatic subjects. J Allergy Clin Immunol 2001; 108:29–38.
49. Feczko PJ, Halpert RD, Zonca M. Radiographic abnormalities in eosinophilic esohagitis. Gastrointest Radiol 1985;10:321–324.
50. Mahajan L, Wyllie R, Petras R, Steffan R, Kay M. Idiopathic eosinophilic esophagitis with stricture formation in a patient with long-standing eosinophilic gastroenteritis. Gastrointest Endosc 1997;46:557–560.
51. Vitellas KM, Bennett WF, Bova JG, Johnston JC, Caldwell JH, Mayle JE. Idiopathic eosinophilic esophagitis. Radiology 1993; 186:789–793.

Received October 11, 2001. Accepted January 3, 2002.

Address requests for reprints to: Glenn T. Furuta, M.D., 300 Longwood Avenue, Hunnewell Ground Floor, Boston, Massachusetts 02115. e-mail: gfuruta@zeus.bwh.harvard.edu; fax: (617) 739-5871.

Supported by grants K08 DK 02564 and P30 DK40561 (to G.T.F.).

The authors thank Thomas Kupper, James Rheinwald, Thomas Macgee, Gerald Gleich, and Barry Wershil for insightful discussions; the endoscopic nursing staff for their efficiency and diligence, including Lisa Heard, Mary Mclaughlin, Carol Schuman, Pat Kittrel, Kate Donovan, and Carol Bradshaw, without whose help this study could not have been completed; and Christopher Duggan, Athos Bousvaros, Laurie Fishman, and Alan Leichtner for referring patients to this study protocol.