Eosinophilic gastroenteritis treated with non-enteric-coated budesonide tablets

Adriaan C. I. T. L. Tan, Johanna W. Kruimel and Ton H. J. Naber

A patient who presented with upper abdominal pain, nausea and ascites together with peripheral eosinophilia is described. Based on a surgical full-thickness biopsy of the antrum, the diagnosis of eosinophilic gastroenteritis was made. Treatment with prednisone resulted in a clinical response, but the prednisone dose could not be lowered below 5 mg. We preferred to treat the patient with corticosteroids with minimal systemic side effects. As there was gastric involvement, we could not give enteric-coated budesonide capsules. Therefore, we treated the patient with budesonide tablets, which were designed originally for use as a clysma but now are given orally. With this treatment regimen, the patient has been in remission for more than 2 years. *Eur J Gastroenterol Hepatol* 13:425–427 © 2001 Lippincott Williams & Wilkins

European Journal of Gastroenterology & Hepatology 2001, **13**:425–427

Keywords: budesonide, corticosteroids, eosinophilic gastroenteritis, treatment

Department of Gastroenterology and Hepatology, University Medical Center, Nijmegen, The Netherlands

Correspondence to Dr A. C. I. T. L. Tan, Department of Gastroenterology and Hepatology, University Medical Center, PO Box 9101, 6500 HB Nijmegen, The Netherlands
Tel: +31 24 3614760; fax: +31 24 3540103;
e-mail: a.tan@hccnet.nl

Received 9 May 2000 **Revised** 3 July 2000
Accepted 25 October 2000

Introduction

Eosinophilic gastroenteritis is an uncommon disorder that may involve any area of the gastrointestinal tract [1,2]. Treatment consists of corticosteroids, which induce a quick response. Often, maintenance therapy with corticosteroids is needed to prevent relapse. In view of the many side effects of corticosteroids, other medications have been tried. Budesonide is a locally acting corticosteroid with a high first-pass effect, which minimizes systemic side effects. We describe a patient with eosinophilic gastroenteritis that responded well to budesonide.

Case report

A 32-year-old Caucasian woman was admitted to hospital with complaints of recurrent cramping pain in the upper abdomen associated with nausea and non-bloody diarrhoea. She had lost 4 kg in weight. Previous medical history was unremarkable. There was no history of food intolerance, allergy, travel to tropical areas, or prior medication. Physical examination was normal, except for a slightly enlarged belly with normal bowel sounds. Laboratory data revealed a haemoglobin concentration of 8.1 mmol/l, with a leucocyte count of 29×10^9/l and a peripheral eosinophilia of 69%. Total serum protein was 67.3 g/l. Immunoglobulins were normal. Echography revealed ascitic fluid. Upper gastrointestinal endoscopy (including biopsies) did not reveal abnormalities. In view of the pronounced eosinophilia and the ascitic fluid, there was a strong suspicion of eosinophilic gastroenteritis of the serosal type. Treatment with prednisone 40 mg was initiated, which resulted in a rapid dissolution of complaints and a decrease in the eosinophilic count. After tapering and eventually stopping the prednisone medication, the patient remained without complaints for over 1 year. Then she experienced more complaints of diarrhoea and ascites. Total eosinophilic count was markedly increased. Autoantibody profile was normal. Albumin was 40 g/l, and xylose test was normal. Upper and lower gastrointestinal tract examinations, including small bowel X-ray, were normal. Extensive investigations (parasitological and bacteriological studies of the stool, bone marrow biopsy, cytogenetic analysis of leucocytes, radiography and echocardiography) did not reveal parasitic infestations, vasculitis, systemic mastocytosis or idiopathic hypereosinophilic syndrome. Echo-endoscopy revealed a thickened submucosal stomach wall, but multiple endoscopic biopsies were negative. To ascertain the diagnosis of eosinophilic gastroenteritis, a full-thickness surgical antrum biopsy was taken. Histology revealed eosinophilic granulocytic infiltration in the muscular mucosa (Fig. 1). In the ascitic fluid, an inflammatory response with eosinophilic granulocytes was seen. This confirmed the diagnosis of eosinophilic gastroenteritis with localization in the stomach. Prednisone was started at a dose of 25 mg, with rapid dissolution of complaints and peripheral eosinophilia. However, when the prednisone dose was tapered to 5 mg/day, the patient complained of crampy abdominal pain and diarrhoea. As long-term maintenance medication was needed, we gave budesonide tablets, normally used for the preparation of the budesonide clysma. These tablets were taken orally, not dissolved in fluid

0954–691X © 2001 Lippincott Williams & Wilkins

Dr. Falk Pharma Ex. 1010
IPR Petition - USP 9,486,407

Fig. 1

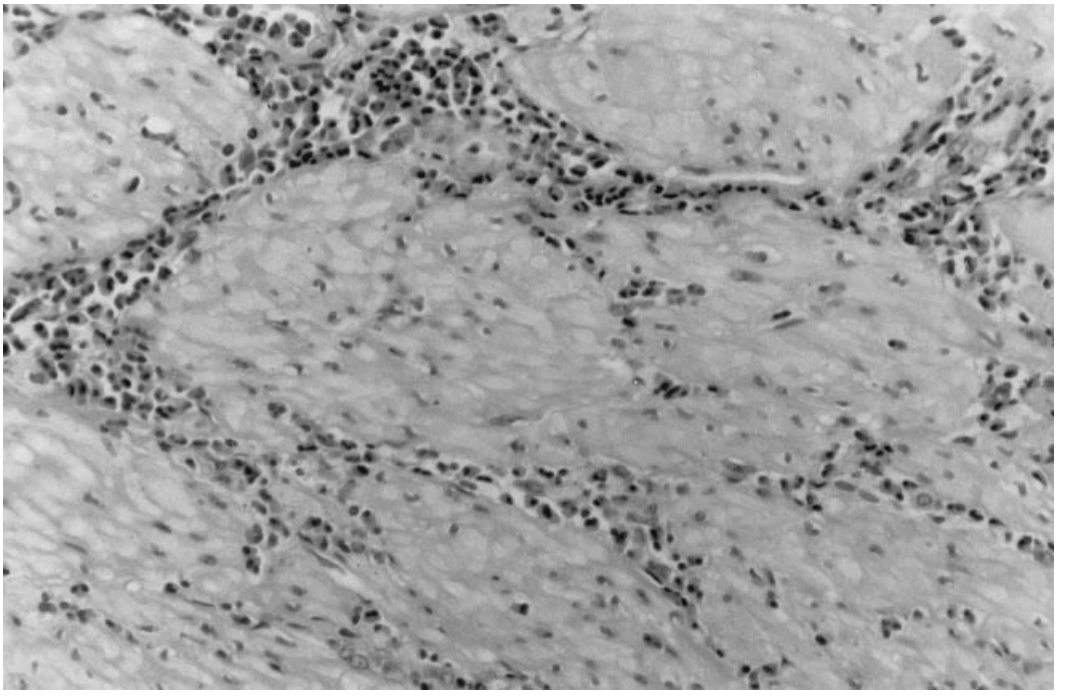

Marked infiltration of eosinophils in the muscular mucosa of a full-thickness antrum biopsy.

but swallowed with water. Starting dose was 4 mg daily, with a good clinical effect. Peripheral blood eosinophilia decreased. No side effects were observed. One year later, the patient complained of diarrhoea four to five times a day. Peripheral eosinophilia was increased. Budesonide was increased to 6 mg daily, with a marked effect on complaints and peripheral blood counts. The patient has now been free of complaints for more than 2 years. Blood eosinophilia is 1.32×10^9/l. Budesonide is gradually tapered to a dose of 2 mg/day.

Discussion

In eosinophilic gastroenteritis, the damage to the gastrointestinal tract wall is caused by eosinophilic infiltration and degranulation, with subsequent tissue damage. The infiltration may involve one or more layers of the gastrointestinal wall. The clinical features depend on the layer and the location involved. Mucosal involvement leads to protein-losing enteropathy and malabsorption. Muscle layer involvement can cause abdominal pain, vomiting, epigastric tenderness, and obstruction of gastric outlet or small bowel. Ascites is a predominant feature of subserosal involvement [1,2]. The cause of this chain of events is poorly understood. One hypothesis involves a type 1 hypersensitivity reaction to certain (unidentified) food products [3]. This results in mast cell degranulation, with release of eosinophil chemotactic factor and platelet activating factor. This attracts other eosinophils, which then release the contents of their granules – major basic protein, eosinophilic peroxidase and eosinophil cationic protein – which produces tissue destruction [4,5]. In addition, tumour necrosis factor alpha (TNF-α) could be released, leading to tissue inflammation [6].

Symptoms include abdominal pain, nausea, vomiting, diarrhoea and weight loss. Often there is a family history of allergy. Sometimes iron deficiency anaemia, protein-losing enteropathy or malabsorption occurs. In 80% of cases, peripheral blood eosinophilia is found. Endoscopic findings show prominent mucosal folds, hyperaemia, nodularity or ulceration, but often no endoscopic abnormalities are found. Diagnosis is made on infiltration of eosinophils in the submucosa without accumulation of other inflammatory cells. Often, bowel involvement is patchy, requiring multiple biopsies. Other diseases, such as parasitic infestations, vasculitis, systemic mastocytosis and hypereosinophilic syndrome, must be excluded [7].

In our patient, eosinophilic gastroenteritis with at least involvement of the stomach muscle layer as well as subserosal layer was proven. The latter can explain the ascites. The diarrhoea points to small bowel involvement, which, although not histologically proven, seems logical.

Dr. Falk Pharma Ex. 1010
IPR Petition - USP 9,486,407

Treatment of eosinophilic gastritis consists of steroids. Prednisone is initiated at a dose of 20–40 mg, which rapidly causes amelioration of symptoms. In some patients, maintenance therapy has to be instituted to prevent relapse [1,7]. Cromoglycate can sometimes be given with reasonable effect [8]. In our patient, maintenance therapy with corticosteroids had to be instituted. In view of the well-known side effects of long-term steroid therapy, we wanted to give another medication with the same local immunosuppressive but fewer systemic effects. Budesonide is a locally acting corticosteroid with an efficacy comparable to prednisone. Its main advantage is its high first-pass metabolism, with little risk of adrenal suppression. Other systemic corticosteroid side effects are attenuated significantly when using budesonide. Budesonide is used mainly in Crohn's disease, where it acts on the small bowel and the first part of the colon [9,10]. We are aware of only one other case report in which budesonide was administered in a patient with eosinophilic enterocolitis. This patient differs from ours because of the site of involvement (colonic rather than upper digestive tract), and because enteric-coated rather than plain budesonide was given [11]. As budesonide is absorbed by the mucosa and transported to the liver where it is inactivated, it is logical to assume both a mucosal and subserosal action of the drug. The latter can explain its beneficial effect on ascites in our patient.

Oral budesonide is available only in a delayed-release form (CIR). Budesonide is not inactivated by gastric acid. The purpose of the CIR form is therefore not to protect the budesonide from gastric inactivation but rather to ensure release of the drug in the last part of the small bowel and the first part of the colon [9]. In our patient, the drug had to be released more proximal, in the stomach and the proximal small bowel. Therefore we gave the plain budesonide tablet (originally designed for dissolution in fluid to be given as an enema) orally. This tablet is absorbed mainly in the stomach and proximal small bowel [12]. A documented clinical and biochemical remission was observed after this treatment. Although maintenance therapy with budesonide is needed, it has far less systemic side effects as compared with other orally acting corticosteroids.

In conclusion, we describe a case report of eosinophilic gastritis that was treated with prednisone initially (with marked side effects). After relapse, the patient was treated with budesonide tablets. As the systemic side effects of this treatment are minimal, it could well become standard treatment for this disease.

References

1 Talley NT, Shorter RG, Phillips SF, Zinsmeister AR. Eosinophilic gastroenteritis: a clinicopathological study of patients with disease of the mucosa, muscle layer, and subserosal tissues. *Gut* 1990; **31**:54–58.

2 Steffen RM, Wyllie R, Petras RE, Caulfield ME, Michener WM, Firor HV, *et al.* The spectrum of eosinophilic gastroenteritis. Report of six pediatric cases and review of the literature. *Clin Pediatr (Phila)* 1991; **30**:404–411.

3 Jaffe JS, James SP, Mullings GE, Braun-Elwert L, Lubensky I, Metcalfe DD. Evidence for an abnormal profile of interleukin-4 (IL-4), IL-5 and gamma-interferon (gamma-IFN) in peripheral blood T cells from patients with allergic eosinophilic gastroenteritis. *J Clin Immunol* 1994; **14**:299–309.

4 Keshavarzian A, Saverymuttu SH, Tai PC, Thompson M, Barter S, Spry CJ, *et al.* Activated eosinophils in familial eosinophilic gastroenteritis. *Gastroenterology* 1985; **88**:1041–1049.

5 Torpier G, Colombel JF, Mathieu-Chandelier C, Capron M, Dessaint JP, Cortot A, *et al.* Eosinophilic gastroenteritis: ultrastructural evidence for a selective release of eosinophilic major basic protein. *Clin Exp Immunol* 1988; **74**:404–408.

6 Beil WJ, Weller PF, Tzizik DM, Galli SJ, Dvorak AM. Ultrastructural immunogold localization of tumor necrosis factor-alpha to the matrix compartment of eosinophil secondary granules in patients with idiopathic hypereosinophilic syndrome. *J Histochem Cytochem* 1993; **41**: 1611–1615.

7 Lee CM, Changchien CS, Chen PC, Lin DY, Sheen IS, Wang CS, *et al.* Eosinophilic gastroenteritis: 10 years experience. *Am J Gastroenterol* 1993; **88**:70–74.

8 Di Gioacchino M, Pizzicannella G, Fini N, Falasca F, Antinucci R, Masci S, *et al.* Sodium dicromoglycate in the treatment of eosinophilic gastroenteritis. *Allergy* 1990; **45**:161–166.

9 Hamedani R, Feldman RD, Feagan BG. Review article: drug development in inflammatory bowel disease: budesonide – a model of targeted therapy. *Aliment Pharmacol Ther* 1997; **11**:98–107.

10 Thomsen O, Cortot A, Jewell D, *et al.* Budesonide CIR is more effective than mesalazine in active Crohn's disease. A 16 week, international randomised, double-blind multicentre trial. *N Engl J Med* 1999; **339**: 370–374.

11 Russel MGVM, Zeijen RNM, Brummer RJM, de Bruine AP, van Kroonenburgh MJPG, Stockbrugger RW. Eosinophilic enterocolitis diagnosed by means of technetium-99m albumin scintigraphy and treated with budesonide (CIR). *Gut* 1994; **35**:1490–1492.

12 Wikberg M, Ulmius J, Ragnarsson G. Review article: targeted drug delivery in treatment of intestinal diseases. *Aliment Pharmacol Ther* 1997; **11(suppl 3)**:109–115.

Dr. Falk Pharma Ex. 1010
IPR Petition - USP 9,486,407