Available online at www.sciencedirect.com
SCIENCE DIRECT®

Digestive and Liver Disease 38 (2006) 55–59

Digestive and Liver Disease

www.elsevier.com/locate/dld

Brief Clinical Observation

Eosinophilic gastroenteritis with severe protein-losing enteropathy: Successful treatment with budesonide

E. Siewert [a,*], F. Lammert [b], P. Koppitz [a], T. Schmidt [c], S. Matern [a]

[a] *Department of Medicine III, University Hospital Aachen, Aachen University (RWTH), Pauwelsstrasse 30, 52074 Aachen, Germany*
[b] *Department Medicine I, University Hospital Bonn, University of Bonn, Bonn, Germany*
[c] *Department of Diagnostic Radiology, University Hospital Aachen, Aachen University (RWTH), Aachen, Germany*

Received 31 January 2005; accepted 9 June 2005
Available online 1 December 2005

Abstract

We report the clinical, laboratory, endoscopic and histopathological findings in a 40-year-old woman with watery diarrhoea and hypoproteinaemia. Elevated α_1-antitrypsin clearance confirmed massive protein-losing enteropathy. Gastroscopic and colonoscopic biopsies showed abundant infiltration of the small bowel wall with eosinophils in proximal duodenum and terminal ileum, respectively. These findings established the diagnosis of eosinophilic gastroenteritis. Both the inflammatory alterations and the severe intestinal protein loss were successfully treated with budesonide, a topically active corticosteroid preparation with controlled small bowel release. The case report illustrates that remission of protein-losing enteropathy secondary to eosinophilic gastroenteritis can be achieved with budesonide, thus supporting its use for this uncommon disease characterised by inflammatory intestinal lesions.
© 2005 Editrice Gastroenterologica Italiana S.r.l. Published by Elsevier Ltd. All rights reserved.

Keywords: Budesonide; Eosinophilic gastroenteritis; Glucocorticoids; Protein-losing enteropathy

1. Introduction

Eosinophilic gastroenteritis (EGE) is an uncommon disease that is characterised by eosinophil-rich inflammation in the gastrointestinal tract. The most common symptoms include abdominal pain (90%), diarrhoea (60%), vomiting (60%), nausea (50%) and abdominal distension due to ascites (see Table 1) [1]. Hence, clinicians should be aware of this condition because it may mimic a broad spectrum of other intestinal diseases from irritable bowel syndrome to acute gastrointestinal obstruction, thereby directing therapy in the wrong direction.

2. Case report

A 40-year-old Caucasian woman was admitted to a teaching hospital due to severe watery diarrhoea lasting for more than 2 weeks. She reported a slight weight loss from 43 to 41 kg. The patient did not recall previous allergic reactions or similar symptoms. She had returned from holidays in France and Poland 2 and 3 months ago, respectively.

During the hospital stay recurrent episodes of fever occurred, but no infectious agents could be detected in repeated blood or stool samples. Furthermore, an empirical antibiotic therapy showed no effect. Secondary to diarrhoea, serum protein levels (particularly albumin concentrations) decreased, and the patient developed massive oedema of arms and legs. She received 20 g albumin tid without any increase in serum albumin levels. After 2 weeks, the patient was transferred to our department at the university hospital for further treatment of the intestinal protein loss and intermittent fever.

The *physical examination* revealed a slightly anxious woman. Despite normal heart and lung exams, the patient presented with massive oedema, which impaired the patient's mobility. Except for increased bowel sounds, the abdomen was normal. Body temperature was 36.6 °C.

* Corresponding author. Tel.: +49 241 80 88634; fax: +49 241 80 82455.
E-mail address: siewert@rwth-aachen.de (E. Siewert).

1590-8658/$30 © 2005 Editrice Gastroenterologica Italiana S.r.l. Published by Elsevier Ltd. All rights reserved.
doi:10.1016/j.dld.2005.06.013

Dr. Falk Pharma Ex. 1012
IPR Petition - USP 9,486,407

Table 1
Symptoms of EGE and treatment options

Symptoms	Treatment options
Involvement of mucosa:	Elimination diet
Abdominal pain	
Diarrhoea and steatorrhoea	Cromoglycate
Hypoproteinaemia with oedema	Ketotifen
Malabsorption	
Weight loss	Glucocorticosteroids
Anaemia	(+azathioprine?)
Involvement of muscularis:	Experimental:
Motility disorder	Monteluklast
Nausea and vomiting	Imatinib mesylate
Intestinal obstruction	Anti-IgE antibody (e.g. omalizumab)
Involvement of (sub)serosa:	Additional symptomatic therapy:
Ascites	H2 blockers
Perforation	Proton pump inhibitors

2.1. Laboratory data (confer Table 2)

On admission, serum levels of protein and albumin were severely reduced. Pseudocholine esterase activity and serum immunoglobulin (Ig) concentrations including IgE were also reduced. Serum osmolality was increased. Except for an initial blood film showing a minor rise in the number of eosinophils, white and red blood counts were normal. Serum iron and transferrin levels were low. Aminotransferases were slightly elevated. C-reactive protein and routine coagulation tests were normal, but 1,25-Vitamin D3 and Vitamin B12 levels were reduced.

Autoantibodies (anti-nuclear antibodies, anti-neutrophil cytoplasmatic antibodies, antibodies against transglutaminase, endomysium or gliadin) and serological markers for viral infections (hepatitis A–D, cytomegaly, Epstein–Barr and human immunodeficiency virus) were negative.

2.2. Diagnostic work-up

The further work-up demonstrated a strikingly elevated α_1-antitrypsin clearance (124,000 ml/day, normal range < 35 ml/day), which is a marker for intestinal malabsorption [2]. Stool examinations for parasites and ova were negative. Abdominal ultrasound showed thickened small bowel walls and a lot of intraluminal fluid, whereas the other organs appeared normal. Colonoscopy revealed a thickened and patchy ileal mucosa but no macroscopic changes of the colonic mucosa. Gastroduodenoscopy demonstrated alterations similar to the ileum in the proximal duodenum, whereas stomach and oesophagus appeared normal.

Table 2
Pathological laboratory findings on admission

Parameter	Value	Normal range
Serum protein (g/l)	27	66–83
Serum albumin (g/l)	15	35–52
Pseudocholine esterase activity (U/l)	1870	5,320–12,920
Serum Ig (g/l)	1.9	6.6–15.5
IgE (kU/l)	4.5	7.4–100
Serum osmolality (mosmol/l)	311	280–295
Blood eosinophils (G/l)	1.0	0.01–0.5
Serum iron (μmol/l)	9	11–31
Serum transferrin (g/l)	1.1	2.0–3.6
Aspartate aminotransferase (U/l)	25	5–15
Alanine aminotransferase (U/l)	23	5–19
1,25-Vitamin D3 (ng/l)	15	16–57
Vitamin B12 (pmol/l)	126	130–700

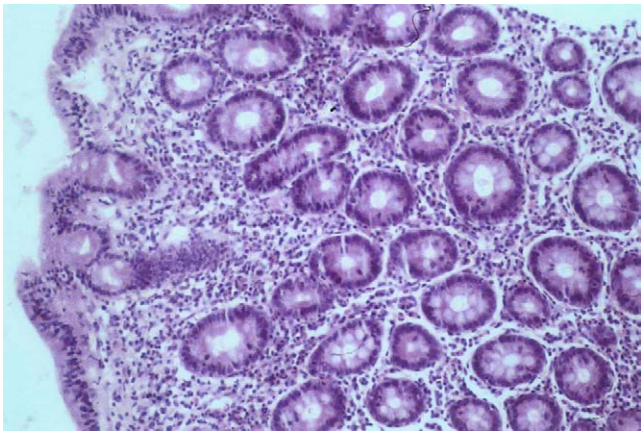

Fig. 1. Histological specimen from proximal duodenum showing inflammation and eosinophilic infiltration (HE stain, magnification ×100).

Fig. 1 shows the histology of small bowel biopsies, which confirmed severe chronic eosinophilic and lymphocytic enteritis with complete absence of villi. Fig. 2 displays double contrast enteroclysis: thickened intestinal walls with separation of small bowel loops and rarefication of intestinal villi. The contrast-enhanced spiral computer tomography (Fig. 3) revealed multiple distended and slightly thickened small bowel loops with a homogeneously enhanced intestinal wall. Ascites could also be detected in the pouch of Douglas (not shown in Fig. 3). There were no signs of malignancy.

Taken together, our findings supported the diagnosis of EGE with massive protein-losing enteropathy.

2.3. Further hospital course

On the day of admission, we started total parenteral nutrition and electrolyte supply. The patient was treated with 9 mg budesonide od (coated form with preferential release in the ileum and proximal colon [Budenofalk®]), a corticosteroid dose that is equivalent to approximately 30–45 mg prednisolone. We observed a marked improvement of the clinical condition, and diarrhoea ceased completely within 10 days. Serum albumin concentrations returned to normal without further substitution, and oedema regressed.

2.4. Follow-up

On outpatient visits 4 and 9 months later, the patient was symptom-free. She had regained normal weight and the oedema had resolved. On abdominal ultrasound, no ascites

Dr. Falk Pharma Ex. 1012
IPR Petition - USP 9,486,407

Fig. 2. Double contrast enteroclysis with barium and methylcellulose shows discontinuous wall thickening of the jejunum and ileum resulting in separation of bowel loops (arrow). Intestinal villi are rarefied, and a central loop shows discrete distortion (arrowhead).

could be detected. Endoscopic and histological follow-up examination at 4 months demonstrated complete regression of the eosinophilic infiltrates in the ileal mucosa and only minimal residual patchy areas with eosinophils in the duodenal mucosa. We reduced the budesonide dose from 9 to 6 mg od. At 9 months of follow-up, endoscopic and histological examination could not detect any eosinophilic infiltrates in the ileal and duodenal mucosa. Hence, the budesonide dose was further decreased to 3 mg od, and treatment was stopped 1 year later. No relapse has occurred within the follow-up period of 2 years.

3. Discussion

Since EGE was first described by Kaijser in 1937 [3], about 300 cases of EGE have been reported in the literature [4–12]. The diagnosis is based on (i) gastrointestinal symptoms, (ii) eosinophilic infiltration in the intestinal wall or typical radiological findings plus blood eosinophilia, (iii) no extraintestinal manifestations and (iv) exclusion of parasites or other extraintestinal diseases (e.g. connective tissue diseases, lymphoma, Churg–Strauss syndrome). The characteristic eosinophilic infiltration of the gastrointestinal wall with subsequent degranulation causes the tissue damage. The clinical features depend on the layer(s) and the location(s) affected (see Table 1) [5,13–16]. Based on the maximal depth of the eosinophilic infiltration of the intestinal wall,

Fig. 3. Abdominal CT with intravenous and oral contrast administration detects multiple distended small bowel loops with pronounced contrast enhancement and thickening of the bowel wall (upper panel, arrow). In the lower panel, dilated *vasa recta* are visualised at the mesenteric border of small bowel loops (arrow) as a sign of hypervascularisation. Although oral contrast medium was administered, mainly low-attenuation intraluminal fluid is apparent due to increased bowel wall secretions and acutely hampered intestinal passage at time of scan.

three EGE types have been defined [5,6]. EGE can display eosinophilic infiltration of the mucosa and/or macroscopic evidence of mucosal oedema. Predominant eosinophilic infiltration of the *tunica muscularis* can lead to (in)complete bowel obstruction. Finally, in rare cases the presence of eosinophilic infiltrates in the subserosa and serosa is associated with systemic eosinophilia and eosinophilic ascites [5,6]. The duodenum is frequently involved in EGE with inflammatory changes in mucosa and *muscularis propria*. Like in the present case, common symptoms include abdominal pain, nausea, vomiting and diarrhoea (see Table 1). Significant weight loss has been reported in only about a third of all cases [1]. In patients with diffuse mucosal involvement, protein loss, malabsorption, steatorrhoea and iron deficiency complicate the clinical course [10].

The aetiology of this condition has not yet been accurately defined, but it is believed to be a primarily polygenic aller-

Dr. Falk Pharma Ex. 1012
IPR Petition - USP 9,486,407

gic disorder involving mechanisms that fall between pure IgE-mediated and delayed Th_2-type responses. About 50% of patients have associated allergic diseases, such as asthma, rhinitis, eczema or food intolerance [9,14,17]. Initial descriptions of EGE often focused on possible relationships with food allergies, and there are reports of food allergies that include positive skin tests and positive responses to provocative testing [18–20]. In these patients, various mechanisms have been postulated, including Arthus-type immediate hypersensitivity reactions, cell-mediated immunity with sensitised T cells releasing lymphokines and antigen-associated mast cell degranulation with eosinophils as inflammatory modulators [15,16,21,22]. However, in patients with specific food allergies, the avoidance of suspected foods often shows little or no clinical benefit, and relapses after elimination diet are common [23]. Although blood eosinophilia is common, it is not a universal finding and does not seem to be a necessary diagnostic criterion [4,8]. However, other diseases associated with peripheral eosinophilia, such as parasitic infection, lymphoma, carcinoma or inflammatory bowel diseases, should be ruled out. Although serum IgE levels – particularly in children [13,16] – may be elevated, our case illustrates that they can also be decreased due to associated protein-losing enteropathy.

Treatment options for EGE are summarised in Table 1. Corticosteroids are the mainstay of EGE treatment with good symptomatic responses [1,6,8,15,24]. Most patients receive prednisolone in doses from 20 to 40 mg/day with various schemes of dose tapering. However, no randomised controlled trials have been performed in this rare disease. Successful treatment with histamine H1 receptor antagonists or mast cell stabilising drugs (like cromoglycate or ketotifen) has been described in selected cases [15,25,26]. Along with the cytokines interleukin 3, interleukin 5, interleukin 13 and granulocyte macrophage-colony stimulating factor, cysteinyl leukotrienes and, particularly, the eotaxin chemokines play a crucial role in the recruitment of eosinophils into the inflamed tissue [15,16], and Neustrom and Friesen [27] and Schwartz et al. [28] successfully treated patients with EGE with the leukotriene receptor antagonist monteluklast, which actively and selectively blocks the leukotriene D4 receptor of eosinophilic granulocytes. However, monteluklast-induced Churg–Strauss syndrome has been reported, and further trials are required to assess the long-term benefit of monteluklast therapy in EGE. Imatinib mesylate, an inhibitor of the tyrosine kinase c-kit, which is required for normal mast cell growth and development, may be of benefit [15]. Additionally given, proton pump inhibitors or H2 blockers may improve symptoms by neutralising gastric acidity [15].

In the interesting study by Russel et al. [29], scintigraphy with ^{99m}technetium-labelled albumin in a patient with EGE localised intestinal protein loss to the terminal ileum, and after initial prescription of prednisolone, the authors administered the topically active corticosteroid budesonide with controlled ileal release. Another group described the use of non-coated budesonide tablets for treatment of eosinophilic gastritis [30] to ensure early release of the drug at the site of eosinophilic infiltration. The present case report supports the use of budesonide for EGE of the small bowel with severe protein-losing enteropathy. Nevertheless, ultimate demonstration of successful treatment of EGE with budesonide can only be obtained in controlled clinical trials. Budesonide was well tolerated without any systemic side effects, consistent with the known first pass hepatic metabolism of the drug. Nevertheless, possible side effects comprise headache (20%), respiratory infections (10%) and nausea (10%). These side effects occur more frequently when drugs that block the action of liver enzymes catabolising budesonide are used additionally. Such medications include ketoconazole, fluconazole, clarithromycin, verapamil, diltiazem and anti-viral agents.

Interestingly, control biopsies confirmed resolution of ileal and duodenal eosinophilic infiltration, although the patient did not receive any topical corticosteroid therapy for the upper gastrointestinal tract, indicating beneficial effects of rather low systemic steroid concentrations as can be observed during therapy with budesonide. Pharmacokinetic studies in healthy subjects and patients with active Crohn's disease determined systemic bioavailability to range from 9 to 11% after oral administration of coated budesonide capsules (Budenofalk®) with preferential ileal release (35–69%) [31,32]. The presented case illustrates that therapy limited to the topically active corticosteroid budesonide can be effective even in cases of EGE with severe protein-losing enteropathy and thus provides an alternative to the usual systemic therapy with prednisone or prednisolone, thereby minimising steroid doses and systemic side effects.

Conflict of interest statement

None declared.

References

[1] Lee CM, Changchien CS, Chen PC, Lin DY, Sheen IS, Wang CS, et al. Eosinophilic gastroenteritis: 10 years experience. Am J Gastroenterol 1993;88:70–4.

[2] Strygler B, Nicar MJ, Santangelo WC, Porter JL, Fordtran JS. Alpha 1-antitrypsin excretion in stool in normal subjects and in patients with gastrointestinal disorders. Gastroenterology 1990;99: 1380–7.

[3] Kaijser R. Zur Kenntnis der allergischen Affektionen des Verdauungskanals vom Standpunkt des Chirurgen aus. Arch Klin Chir 1937;188:36–64.

[4] Caldwell JH, Tennenbaum JI, Bronstein HA. Serum IgE in eosinophilic gastroenteritis. Response to intestinal challenge in two cases. N Engl J Med 1970;292:1388–90.

[5] Klein NC, Hargrove RL, Sleisenger MH, Jeffries GH. Eosinophilic gastroenteritis. Medicine 1970;49:299–319.

[6] Talley NJ, Shorter RG, Phillips SF, Zinsmeister AR. Eosinophilic gastroenteritis: a clinicopathological study of patients with disease of the mucosa, muscle layer, and subserosal tissues. Gut 1990;31:54–8.

[7] Steffen RM, Wyllie R, Petras RE, Caulfield ME, Michener WM, Firor HV, et al. The spectrum of eosinophilic gastroenteritis. Report of six pediatric cases and review of the literature. Clin Pediatr 1991;30:404–11.

Dr. Falk Pharma Ex. 1012
IPR Petition - USP 9,486,407

[8] Dorlars D, von Bubnoff AC, Riemann JF. Eosinophilia and the digestive tract. Eosinophilic gastroenteritis and its differential diagnosis. Dtsch Med Wochenschr 1997;122:1353–7.
[9] Fenoglio LM, Benedetti V, Rossi C, Anania A, Wulhfard K, Trapani M, et al. Eosinophilic gastroenteritis with ascites. A case report and review of the literature. Dig Dis Sci 2003;48:1013–20.
[10] Caldwell JH, Mekhjian HS, Hurtubise PE, Beman FM. Eosinophilic gastroenteritis with obstruction. Immunological studies of seven patients. Gastroenterology 1978;74:825–8.
[11] Uenishi T, Sakata C, Tanaka S, Yamamoto T, Shuto T, Hirohashi K, et al. Eosinophilic enteritis presenting as acute intestinal obstruction: a case report and review of the literature. Dig Surg 2003;20: 326–9.
[12] Charalabopoulos A, Charalabopoulos K, Avuzuklidou M, Charalabopoulos AK, Ioachim E, Lebren F, et al. Eosinophilic gastroenteritis: presentation of two patients with unusual affect of terminal ileum and caecum with manifestations of acute abdomen and literature review. Int J Clin Pract 2004;58:413–6.
[13] Khan S, Orenstein SR. Eosinophilic gastroenteritis: epidemiology, diagnosis and management. Paediatr Drugs 2002;4:563–70.
[14] Heatley RV, Harris A, Atkinson M. Treatment of a patient with clinical features of both eosinophilic gastroenteritis and polyarteritis nodosa with oral sodium cromoglycate. Dig Dis Sci 1980;25: 470–2.
[15] Rothenberg ME. Eosinophilic gastrointestinal disorders (EGID). J Allergy Clin Immunol 2004;113:11–28.
[16] Ngo P, Furuta G, Burks W. The pathobiology of eosinophilic gastroenteritis of childhood: is it really the eosinophil, allergic mediated, or something else? Curr Gastroenterol Rep 2004;6:436–40.
[17] Leinbach GE, Rubin CE. Eosinophilic gastroenteritis: a simple reaction to food allergens? Gastroenterology 1970;59:874–89.
[18] Katz AJ, Goldman H, Grand RJ. Gastric mucosal biopsy in eosinophilic (allergic) gastroenteritis. Gastroenterology 1977;73:705–9.
[19] Park HS, Kim HS, Jang HJ. Eosinophilic gastroenteritis associated with food allergy and bronchial asthma. J Korean Med Sci 1995;10:216–9.
[20] Kweon MN, Kiyono H. Eosinophilic gastroenteritis: a problem of the mucosal immune system? Curr Allergy Asthma Rep 2003;3:79–85.
[21] Martin LB, Kita H, Leiferman KM, Gleich GJ. Eosinophils in allergy: role in disease, degranulation, and cytokines. Int Arch Allergy Immunol 1996;109:207–15.
[22] Talley NJ, Kephart GM, McGovern TW, Carpenter HA, Gleich GJ. Deposition of eosinophil granule major basic protein in eosinophilic gastroenteritis and celiac disease. Gastroenterology 1992;103:137–45.
[23] Justinich C, Katz A, Gurbindo C, Lepage G, Chad Z, Bouthillier L, et al. Elemental diet improves steroid-dependent eosinophilic gastroenteritis and reverses growth failure. J Pediatr Gastroenterol Nutr 1996;23:81–5.
[24] Hartmann D. How should eosinophilic gastroenteropathy be treated? Dtsch Med Wochenschr 2002;127:2464–5.
[25] Di Gioacchino M, Pizzicannella G, Fini N, Falasca F, Antinucci A, Masci S, et al. Sodium cromoglycate in the treatment of eosinophilic gastroenteritis. Allergy 1990;45:161–6.
[26] Melamed I, Feanny SJ, Sherman PM, Roifman CM. Benefit of ketotifen in patients with eosinophilic gastroenteritis. Am J Med 1991;90:310–4.
[27] Neustrom MR, Friesen C. Treatment of eosinophilic gastroenteritis with monteluklast. J Allergy Clin Immunol 1999;104: 506.
[28] Schwartz DA, Pardi DS, Murray JA. Use of monteluklast as steroid-sparing agent for recurrent eosinophilic gastroenteritis. Dig Dis Sci 2001;46:1787–90.
[29] Russel MG, Zeijen RN, Brummer RJ, de Bruine AP, van Kroonenburgh MJ, Stockbruegger RW. Eosinophilic enterocolitis diagnosed by means of technetium-99m albumin scintigraphy and treated with budesonide (CIR). Gut 1994;35:1490–2.
[30] Tan AC, Kruimel JW, Naber TH. Eosinophilic gastroenteritis treated with non-enteric-coated budesonide tablets. Eur J Gastroenterol Hepatol 2001;13:425–7.
[31] Lundin PD, Edsbacker S, Bergstrand M, Ejderhamn J, Linander H, Hogberg L, et al. Pharmacokinetics of budesonide controlled ileal release capsules in children and adults with active Crohn's disease. Aliment Pharmacol Ther 2003;17:85–92.
[32] Fedorak RN, Bistritz L. Targeted delivery, safety, and efficacy of oral enteric-coated formulations of budesonide. Adv Drug Deliv Rev 2005;57:303–16.

Dr. Falk Pharma Ex. 1012
IPR Petition - USP 9,486,407