JECT. 2003;35:274–283
The Journal of The American Society of Extra-Corporeal Technology

Original Articles

The MicroMed DeBakey VAD—Part I: The Pump and the Blood Flow

Evgenij V. Potapov, MD;* Andreas Koster, MD;† Matthias Loebe, MD, PhD;‡
Ewald Hennig, PhD;* Thomas Fischer, MD;† Ralf Sodian MD;* Roland Hetzer, MD, PhD*

*Department of Cardiothoracic and Vascular Surgery, Deutsches Herzzentrum, Berlin, Germany, †Department of Anesthesiology, Deutsches Herzzentrum, Berlin, Germany, ‡Michael E. DeBakey Department of Surgery, Division of Transplantation and Assist Devices, Baylor College of Medicine, Houston, Texas

Heart failure is a disease with many different etiologies. The prevalence of heart failure is approximately 1% (1), but it is one of the leading causes of death in the developed countries. In the USA, 3 million people present symptoms of heart failure and ca. 400,000 new diagnoses are registered each year (2). There are a number of guidelines for the treatment of heart failure, published for example by the World Health Organization and the American Heart Association, which include ACE-inhibitors, β-blockers, diuretics, digitalis, and pacemaker implantation (3). Despite a significant improvement of long-term follow-up in patients treated with ACE-inhibitors and hybrid β-blockers affecting the α-adrenoreceptors (4–7), 35,000 patients die annually in the US because of end-stage heart failure (8). The first heart transplantation (HTx) was performed in 1967 and, since the introduction of cyclosporin in clinical practice in 1980, heart transplantation has become an established therapy for heart failure with good outcome (9). However, HTx is limited because there are an increasing number of patients on the waiting list and a decrease in the number of available donor hearts. Our experience shows that approximately one-third of patients awaiting transplantation could by kept alive until HTx only by the use of ventricular assist devices (VADs).

The development of VADs began in the early 1960s. The first successful LVAD implantation was performed by DeBakey in 1966 (10). In 1970 the National Heart and Lung Institute started a support program for implantable VADs, and in 1978 the first patient was successfully bridged to HTx. In 1982 the extracorporeal Thoratec Ventricular Assist Device (11) and in 1988 the Berlin Heart were introduced in clinical use (12). At this time, implantable LVADs were developed, and in 1984 the Novacor System and in 1986 the HeartMate System were clinically used for the first time (13,14). Both these systems are vented and electrically driven and are now in clinical use worldwide. All these devices are capable of supporting the failed heart for several years (15–18). In patients in whom transplantation cannot be carried out, long-term support may be an alternative to HTx. Since 2000 the Arrow Lion Heart, a fully implantable LVAD, and since 2001 the Abicor, a fully implantable BVAD, both with transcutaneous energy transfer and an implantable compliance chamber, have been implanted in patients for permanent use.

The vented, electrically driven implantable or pneumatically driven extracorporeal systems produce pulsatile blood flow by compression of the blood reservoir and need biological or mechanical valves (two or four, depending on whether the configuration is univentricular or biventricular). The blood reservoir and driving system of the currently used implantable pulsatile devices have a large artificial surface and are bulky and heavy. Therefore, they need a large space for pre- or intraperitoneal implantation. The large wound created leads to an increased risk of bleeding and infections with subsequently increased morbidity (15,16,19–29). The extracorporeal systems have an elevated risk for infection because of large skin incisions for the cannulas, and the extracorporeal blood pumps and cannulas represent an additional psychological strain for the patients (30).

THE MICROMED DEBAKEY™ VAD

The MicroMed DeBakey VAD was developed in collaboration between the NASA Johnson Space Center and Baylor College of Medicine. The DeBakey VAD is a small axial pump weighing 93 g and is 86 mm long and 25 mm

Address correspondence to: Evgenij V. Potapov, MD, Deutsches Herzzentrum, Berlin, Augustenburger Platz 1, 13353 Berlin, Germany Telephone: +49 30 4593 1000; Fax. +49 30 4593 2100; e-mail: potapov@dhzb.de
Received September 30, 2001; accepted December 18, 2002.

Article available at https://ject.edpsciences.org or https://doi.org/10.1051/ject/2003354274

Abbott v. Miracor, IPR2025-00116
Abbott Ex. 1050, p. 1 of 10

wide. Within the flow tube, the titanium components consist of an impeller, a fixed flow straightener that acts as a front bearing for the impeller, and a fixed rear diffuser, which provides a rear bearing for the impeller. The diffuser retards the highly tangential blood flow velocity by redirecting it axially, this action resulting in a fluid pressure build. Rare earth magnets, which are embedded in the blades of the impeller, act as a rotor in the brushless motor, causing it to spin in a magnetic field (31,32). The computer-designed components (33,34) of the pump are shown in Figure 1. The pump is connected with the apex of the left ventricle via a titanium inflow cannula and with the ascending aorta by a Dacron graft (Figure 2). It is implanted into a pericardial space above the diaphragm. The impeller is the only moving part of the pump. Moreover, because of the axial flow, the pump does not need any valves. The rotations of the impeller can be set between 7500 and 12,000 per minute. The pump produces in vitro a flow of 5 to 6 L/min against 100 mmHg pressure at 10,000 rpm. In the clinical setting, the rpm were set between 9500 and 10,000, depending on the filling of the left ventricle, to provide a cardiac index of 2.8 to 3.5 L/min/m^2 and to avoid excessive suction on the inflow cannula and collapse of the left ventricle with subsequent cessation of the pump flow. The speed adjustment was necessary only in the early postoperative period. In patients the pump requires 10–14 W of power (35). The energy transfer and control are performed transcutaneously via a small cable. The ultrasonic flow meter around the outflow cannula controls the pump flow. The measurement of the pump flow is displayed either on the external controller or, when connected, on the data acquisition system (DAS) together with pump speed, power consumption, and current of the pump. The controller has audio and visual alarms for low pump flow, battery status, and technical problems. The power is supplied from 12 V batteries or from the DAS, which is a little larger than a laptop computer and is used in the early period after implantation or for rpm adjustment. The DAS allows online recording of all parameters and alarm history.

The MicroMed DeBakey VAD has advantages compared with pulsatile LVADs. These are:

- no blood sack
- small artificial surface
- no artificial valves
- only one moving part
- low power consumption
- small weight and size
- no noise
- possible use in small adults and children

Because of the high speed rotations of the impeller, hemolysis could be expected. In experimental studies, however, no significant hemolysis has been noted (36,37). In a clinical setting, Wieselthaler et al. reported increased serum activity of lactate dehydrogenase (LDH) (38,39). Compared with patients in whom the Novacor LVAD was implanted, we also found increased LDH levels after implantation of the MicroMed DeBakey VAD, as well as increased levels of β-thromboglobulin (40), which indicated some evidence of trauma of blood cells by the rotating impeller. In our patients and in patients in Vienna reported on by Wieselthaler et al. (38,39), the serum free hemoglobin level remained low. The need for transfusions of platelets or red blood cells was similar in patients with Novacor and DeBakey VADs (39,41). Probably attribut-

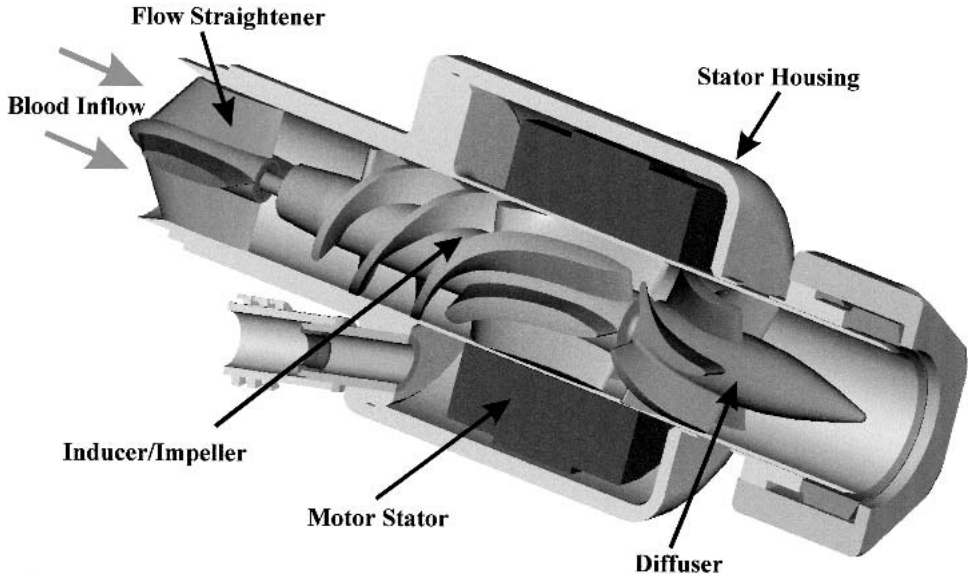

Figure 1. Inside view of the computer-designed pump of the MicroMed DeBakey VAD (published with permission of MicroMed Inc., Woodlands, TX).

Abbott v. Miracor, IPR2025-00116
Abbott Ex. 1050, p. 2 of 10

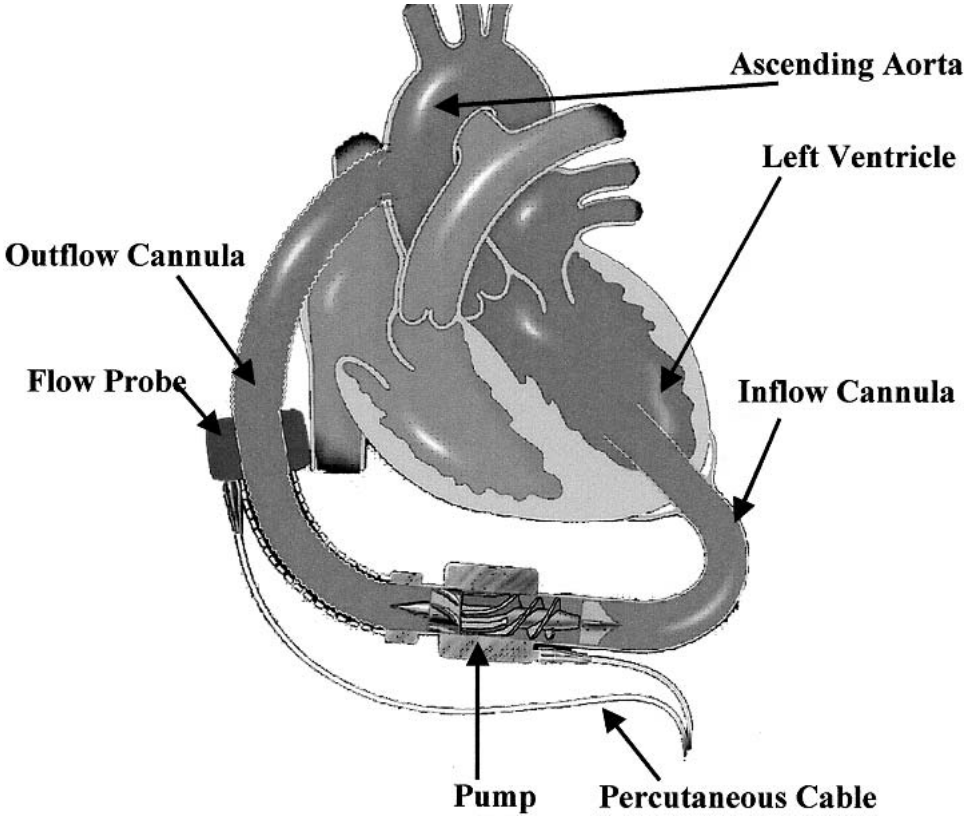

Figure 2. Implantation of the MicroMed DeBakey VAD. The titanium inflow cannula is connected to the apex of the left ventricle and the Dacron outflow cannula to the ascending aorta (published with permission of MicroMed Inc., Woodlands, TX).

able to the small artificial surface and the absence of valves, the MicroMed DeBakey VAD does not cause any microembolic signals (42), which are common for devices with valves such as the Novacor or HeartMate and occur in relation to clinically relevant thromboembolism (43–45). However, comparison of the thromboembolism rate in patients supported by pulsatile and by continuous flow devices should be performed.

DOES THE MICROMED DEBAKEY VAD PRODUCE NONPULSATILE BLOOD FLOW?

From the pathophysiological point of view, the continuous flow form produced by the axial pump is nonphysiological. Discussion of the effects of nonpulsatile flow on organ function during short-term and long-term use of mechanical circulatory support has been underway since the cardiopulmonary bypass became routinely used (46–52) and the number of publications is huge. Despite numerous experimental and clinical studies, the pathophysiology of nonpulsatile flow is poorly understood. Pulsatility is an attribute of species at a high stage of evolution. The principle "Nature knows best" is widely accepted (53–56). The benefit of pulsatility is probably mediated by its effect on systemic vascular resistance and on the microcirculation (57) as a result of less endothelial damage (58) and normal NO release (59). Some reports have suggested that pulsatile flow improves splanchnic perfusion (60), brain microcirculation and cerebrospinal fluid movement (61), and the maintenance of capillary patency through prevention of sludging. Other authors have suggested an improvement of aerobic tissue metabolism (50). These phenomena have been explained by decreased stimulation of carotid receptors because of the absence of pressure peaks and by increased renin release with subsequent angiotensin II dependent vasoconstriction. However, the effect on the renin–angiotensin system remains controversial (47,52).

It is well known that most of the time the blood flows through the capillaries and veins, where the flow is nonpulsatile. The gas and metabolic exchange between blood and tissue takes place in the capillaries. A number of studies showed no differences between pulsatile and nonpulsatile flow forms (62,63), especially if the flow was over 95 mL/min/kg (64). These findings mean that the flow volume is more important than the flow form.

Immediately after implantation of the MicroMed DeBakey VAD the following were all nonpulsatile: the blood flow measured by flow meter installed around the outflow canula, the tracings from an invasive arterial pressure catheter in the radial or femoral arteries and from the sensor of peripheral O_2 saturation, as well as signals from transcranial Doppler measured in the middle cerebral ar-

Abbott v. Miracor, IPR2025-00116
Abbott Ex. 1050, p. 3 of 10

teries (Figure 3). During this period, only one patient showed a mild orthostatic reaction. Wieselthaler et al. reported good experience with exercise training without any orthostatic reactions (39). Figure 4 shows systolic and diastolic pressures during the first 2 weeks after implantation of the DeBakey VAD. For comparison, the systolic and diastolic pressures in patients after implantation of the pulsatile LVAD of the Novacor type are shown. Interestingly, after 2 weeks, the amplitude of the blood pressure in patients with DeBakey VAD has already risen to the preoperative amplitude. The normal circulatory regulation during the first few weeks could be explained by adaptation of central reflexes to low systolic pressure, while the mean pressure was in the normal range of between 70 and 80 mmHg. However, the regulation of macro- and microcirculation and adaptation mechanisms in patients after implantation of continuous flow VADs merits further investigation.

Some time after implantation, the flow becomes pulsatile, with pulsatility increasing continuously in all patients (Figures 5, 6) (35), so that in some patients, a "pulse wave" could be detected in the peripheral arteries, and Korotkoff's sound could even be heard during noninvasive blood pressure measurement. The simultaneous echocardiography studies demonstrated closed aortic valve and good unloading of the left ventricle at all times. Opening of the aortic valve could be achieved while the rpm were slowed for echocardiographic examinations or during physical exercise (39).

The question then arises as to what could be the origin of this pulsation. The MicroMed DeBakey VAD, being an axial pump, is pressure dependent. That means that the output of the pump is dependent on the pressure difference (Δp) between the inflow (p_{in}) and outflow cannulas (p_{out}) during the cardiac cycle. The constant Δp during the cardiac cycle leads to nonpulsatile flow through the pump.

After unloading on the MicroMed DeBakey VAD and recovery to some extent of the left ventricle (not lasting recovery but an increase in contractility of the unloaded left ventricle), the contractions of the left ventricle caused pressure changes at the inflow cannula (i.e., different Δp between the inlet and the outlet of the pump during one cardiac cycle), and the flow became pulsatile with high flow during the systole and low flow during the diastole (Figure 7). The pulsatility was independent of the afterload of the pump. Our experience with pulsatile LVADs shows that, after unloading of the ventricle, some patients demonstrate good left ventricular function, which remains stable after LVAD explantation (65).

A brief example of the development of pulsatiliy follows. Immediately after implantation of the MicroMed DeBakey VAD the end diastolic and end systolic pressures in the badly damaged and poorly contracting left ventricle are nearly identical; for example, 10 mmHg. Given that the MAP is 70 mmHg, the Δp between the pump's inlet and outlet is 60 mmHg during a whole cardiac cycle, and the pump flow and subsequent blood pressure are nonpulsatile. After a period of unloading (in some patients this takes some weeks) the nearly empty left ventricle begins to contract. With constant rpm, the end diastolic pressure in the left ventricle remains 10 mmHg ($\Delta p = 60$ mmHg), but the end systolic pressure in the recovered and now contracting left ventricle rises to up to 40 mmHg. This pressure is not sufficient to open the aortic valve (mean arterial pressure 70 mmHg) but the Δp at the end of the systole is 70–40 = 30 mmHg. Because the axial pump is a pressure-dependent pump, and the rpm remain unchanged, the pump pumps more blood at the end of the systole because of lower Δp, and the flow becomes pulsatile (Figure 8).

This hypothesis has been proved in a mock circulation with a pneumatically driven pulsatile pump and with pulsatile and nonpulsatile Δp with large numbers of fluids, hydrodynamics, and pumping parameters (66). In vitro, on the basis of the flow characteristic chart [$F = f(\Delta p)$, rpm] with given rpm, p_{in} and p_{out} and their curvature, the flow pulsatility can be calculated and is comparable to clinical findings. Figure 9 shows the mock circulation with a "left ventricle" (Berlin Heart, 80 mL) and the MicroMed DeBakey VAD connected to the side of the Berlin Heart

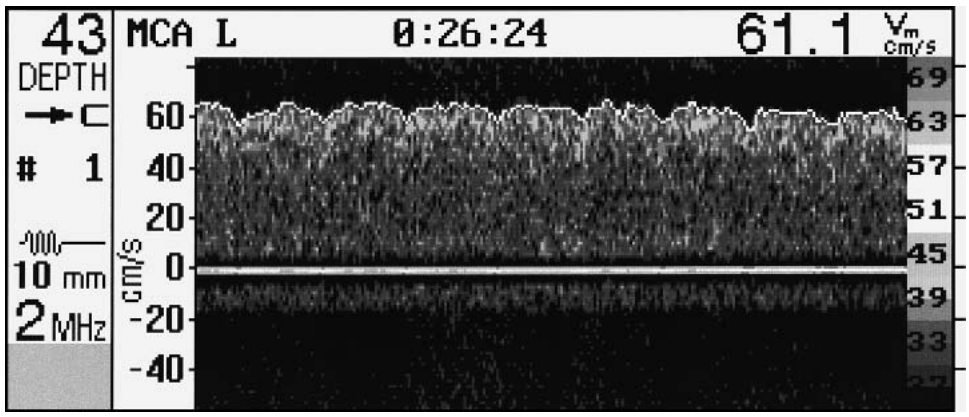

Figure 3. The transcranial Doppler signal showed nonpulsatile flow in the middle cerebral artery 3 days after implantation of the MicroMed DeBakey VAD.

Abbott v. Miracor, IPR2025-00116
Abbott Ex. 1050, p. 4 of 10

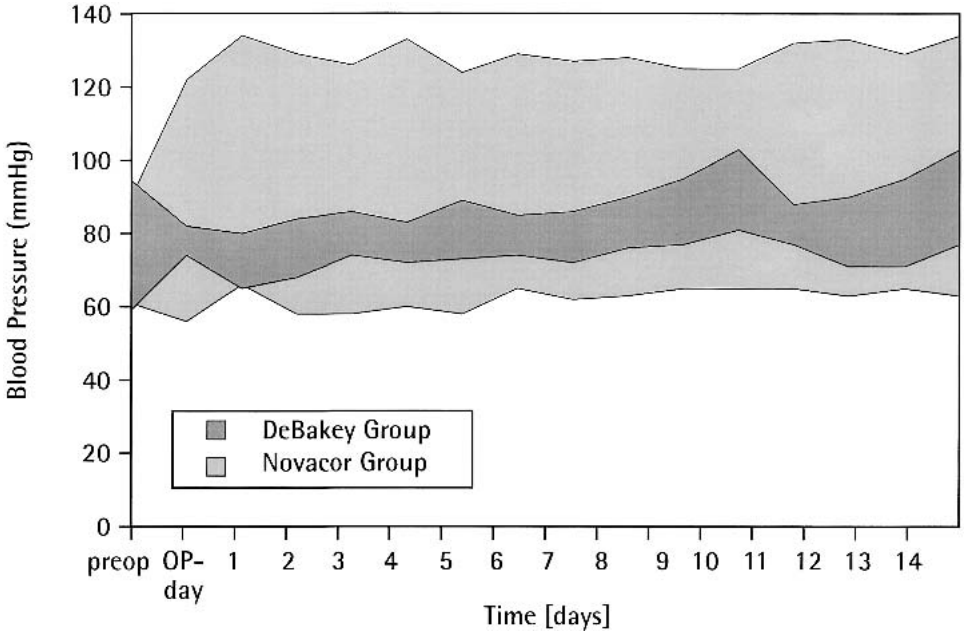

Figure 4. Systolic and diastolic pressures in patients with the MicroMed DeBakey VAD and the Novacor LVAD during the first 2 weeks. Data are given as mean values. The DeBakey VAD group consisted of eight patients; the Novacor group also consisted of eight consecutive patients. In patients with the MicroMed DeBakey VAD, only results of invasive blood pressure measurements were included in the analysis.

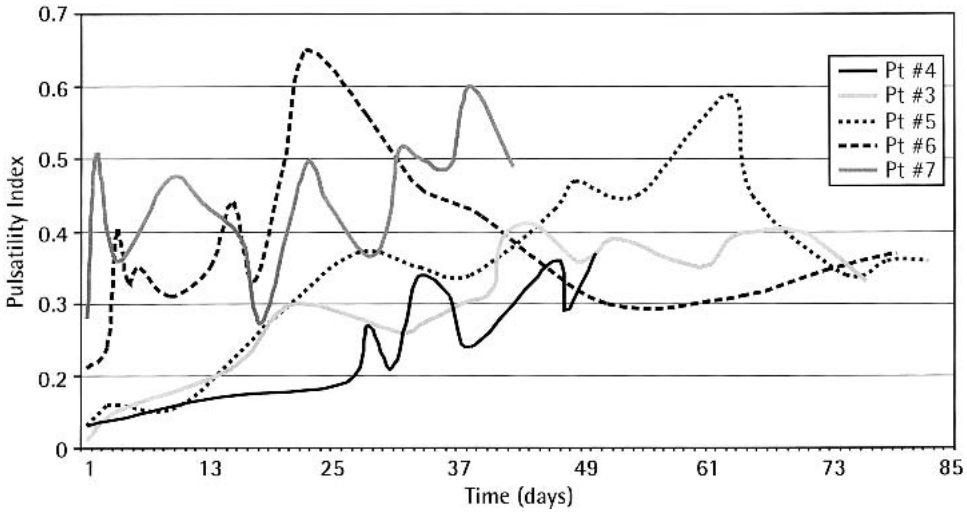

Figure 5. The courses of pulsatility indices (PI: pulsatility index; V: blood flow velocity; $PI=(V_{max}-V_{min})/V_{mean}$) measured in the middle cerebral artery using transcranial Doppler in five patients after implantation of the MicroMed DeBakey VAD.

pump. The MicroMed DeBakey VAD acts as a pressure amplifier for a low ventricular pulsatile pressure. Figure 10 presents changes of flow by different Δp with a group of characteristic curves evaluated by different rpm. Figure 8 explains the pulsatility in vitro as a pressure amplification by pulsatile Δp and shows the pulsatile flow produced by the MicroMed DeBakey VAD.

During the early period after implantation, the MicroMed DeBakey VAD produces a low pulsatile blood flow. The pulsatility rises with recovery of the left ventricle and almost reaches physiological levels in some patients. These findings accordingly preclude the use of the term "nonpulsatile pump" in connection with the MicroMed DeBakey VAD. In our opinion, the term "continuous flow" better reflects the flow form produced by the device.

CLINICAL IMPLICATIONS

The DeBakey VAD provides an output of up to 8 L/min depending on right ventricular function and volume status. The pump output is sufficient to maintain body perfusion and enable mobility in daily life, physical exercise (39,67), and even sexual activities.

The internal organs can function satisfactorily only if their perfusion and tissue metabolism are preserved. During the period of low pulsatility, patients presented normal liver and kidney function (Figures 11, 12). Similar results have been reported by other authors (39,68).

Wieselthaler et al. reported an elevation of LDH without correlation with the plasma free hemoglobin level. The concomitant administration of antibiotics in these patients

Abbott v. Miracor, IPR2025-00116
Abbott Ex. 1050, p. 5 of 10

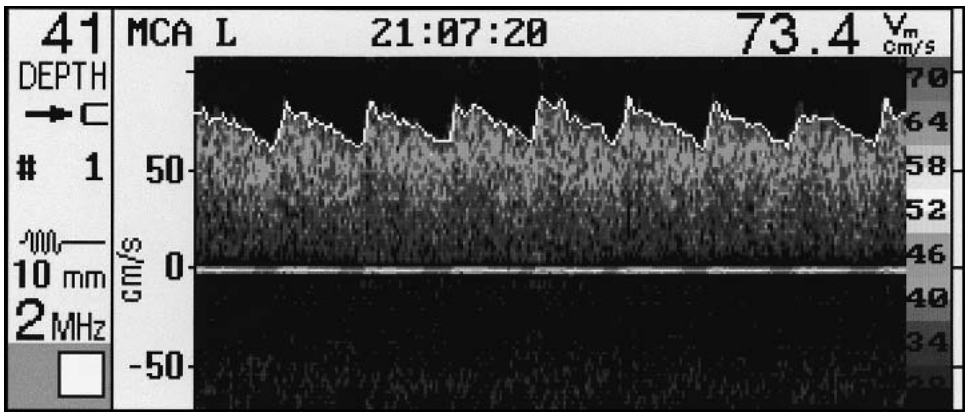

Figure 6. Transcranial Doppler signal from the middle cerebral artery 4 weeks after implantation of the MicroMed DeBakey VAD with nearly normal relationship between systolic and diastolic blood flow acceleration.

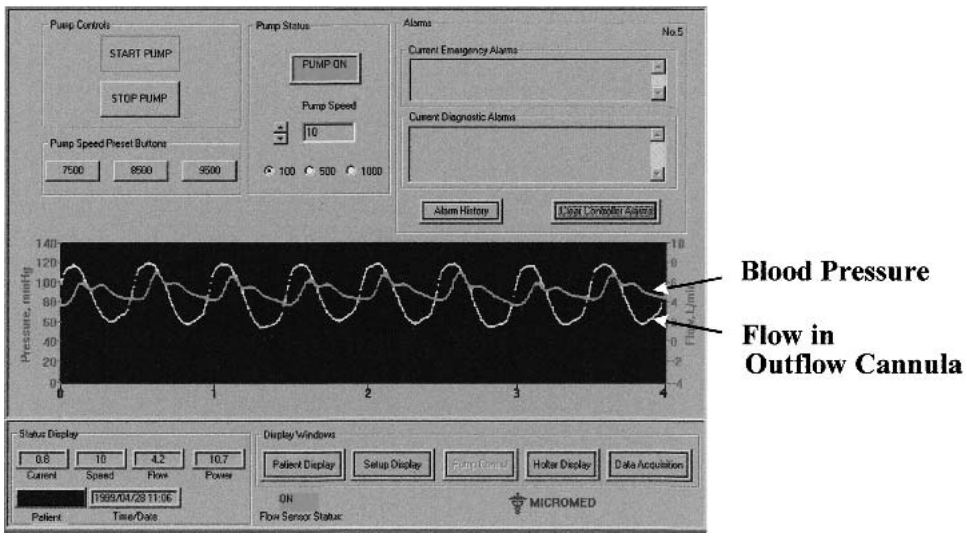

Figure 7. The monitor of the data acquisition system of the Debakey VAD showed pulsatile blood flow in the outflow graft and in the radial artery 6 weeks after implantation.

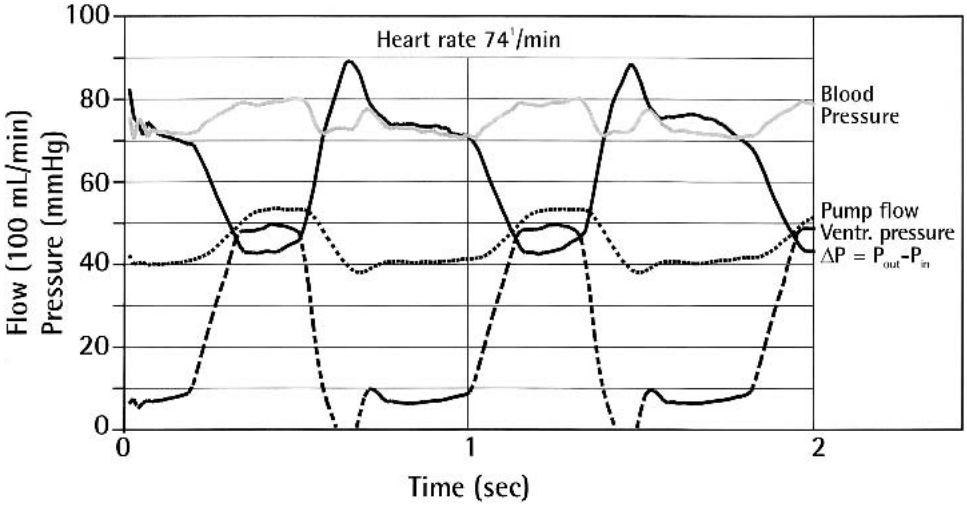

Figure 8. The in vitro example (mock circulation) of pressure amplification by pulsatile Δp resulting in pulsatility of the flow produced by the MicroMed DeBakey VAD.

was discussed as a possible origin (39). We observed LDH elevation over 800 U/L in one patient 1 month after surgery. This elevation was probably caused by hypovolemia. After IV rehydration, the LDH level decreased to values between 250 and 300 U/L. A slight elevation of the free hemoglobin level was observed during this period.

After removal of the intraarterial catheter, blood pressure measurement in patients supported with continuous

Abbott v. Miracor, IPR2025-00116
Abbott Ex. 1050, p. 6 of 10

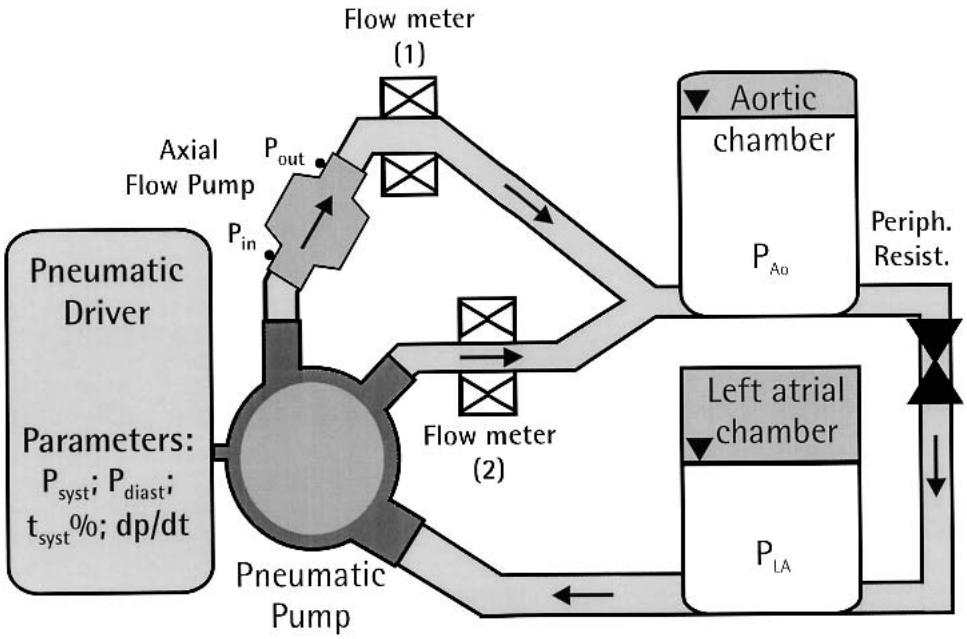

Figure 9. The mock circulation simulating the left ventricle (Berlin Heart pulsatile pump with two polyurethane valves) with side connected MicroMed DeBakey VAD pump.

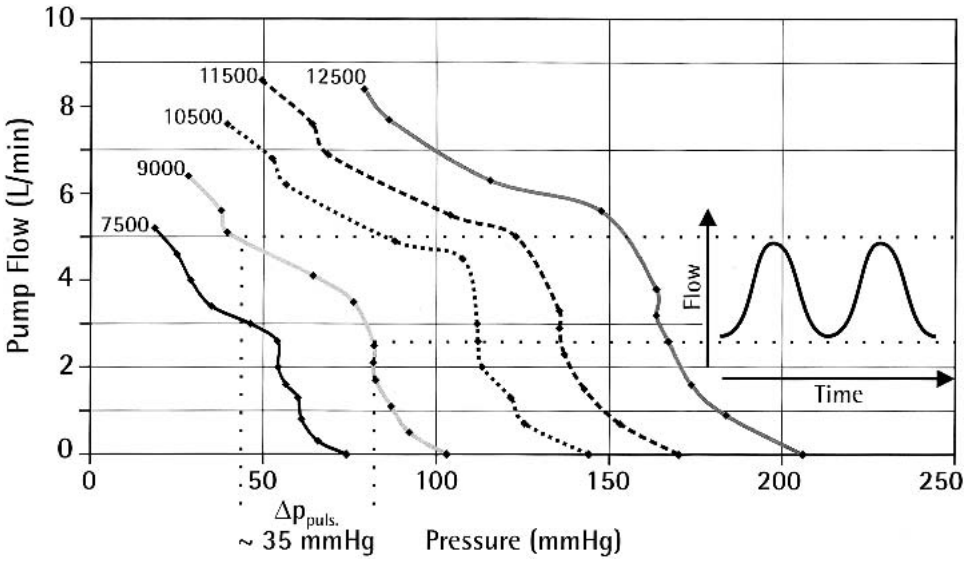

Figure 10. Group of curves evaluated by different rpm showed changes of flow by different Δp.

flow pumps becomes a significant problem. We used the commercially available blood pressure cuff and a pocket Doppler device. First, the position of the radial artery was marked with a pen; then the cuff was inflated, and the Doppler signal corresponded with the systolic blood pressure. A similar experience has been reported by Wieselthaler et al. (38).

Stoppage of the MicroMed DeBakey VAD, if the automatic restart fails, leads to a back flow of between 1.5 and 2 L/min. In some patients, the recovered left ventricle tolerated the back flow and provided adequate output for some minutes to some hours. However, ligation of the outflow graft through a small subxyphoidal incision should be immediately performed (39). A broken cable connector caused pump stops in the Berlin and Vienna patients (39) in the early experience. Following use of a new cable connector, it never happened again. The other cause of pump stops was thrombus in the pump. The advantage of the axial pump is that, if it is blocked by a large thrombus, systemic thromboembolism is prevented. Successful thrombolysis has been reported (69).

The study protocol allowed individual anticoagulation management according to each center's previous experience. Therefore, different anticoagulation protocols are in clinical use (39,40), and no definitive management has been established up until now. Recently, a proposal for anticoagulation management in patients with the DeBakey VAD has been published (70).

Abbott v. Miracor, IPR2025-00116
Abbott Ex. 1050, p. 7 of 10

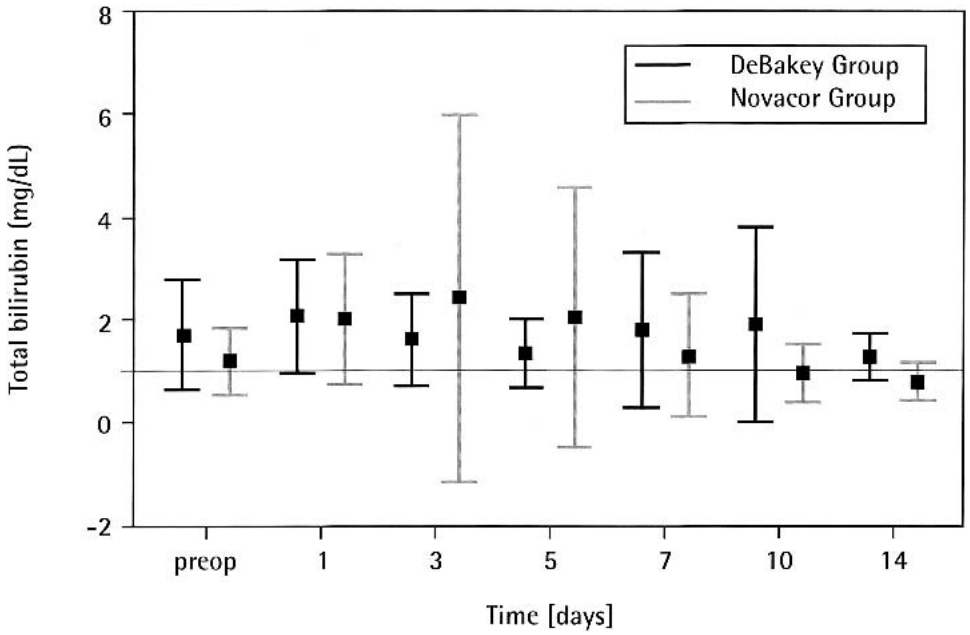

Figure 11. Total bilirubin level in patients with MicroMed DeBakey VAD and Novacor LVAD as a parameter for hepatic function. Data are given as mean ± standard deviation. The horizontal line represents the reference value. The DeBakey VAD group consisted of eight patients; the Novacor group also consisted of eight consecutive patients.

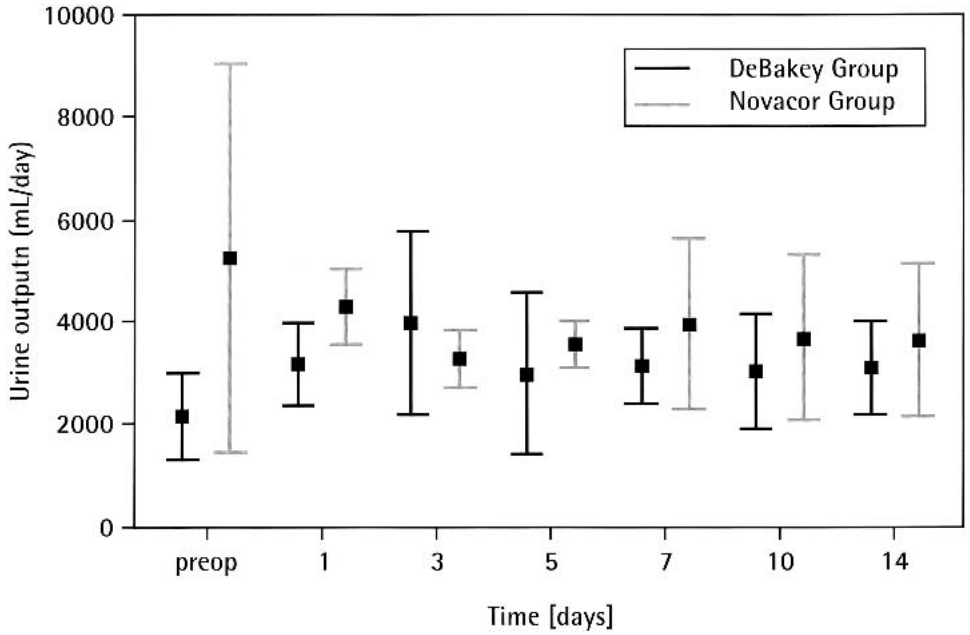

Figure 12. Urine output in patients with MicroMed DeBakey VAD and Novacor LVAD as a parameter for renal function. Data are given as mean ± standard deviation. The DeBakey VAD group consisted of eight patients; the Novacor group also consisted of eight consecutive patients.

The patients supported with the MicroMed DeBakey VAD showed faster recovery than patients on the implantable pulsatile systems. Patients with the MicroMed DeBakey VAD may be discharged from the hospital, but they need to participate in the outpatient care program (39,67,71). Special attention should be given to the anticoagulation regime. Use of a self-testing device (Coagu Chek, Boehringer Mannheim, Mannheim, Germany) and regular testing of platelet function (40) are necessary.

SUMMARY

The results obtained in over 100 patients implanted with the MicroMed DeBakey VAD in several centers in Europe and USA (September 2001, M. Loebe, personal communication) demonstrate that the effectiveness of the MicroMed DeBakey VAD is comparable to that of the pulsatile devices and that it also shows some superior properties. Recently, other axial pumps—the Jarvic 2000 (72) and HeartMate II (73)—have come into clinical use. Because the patients show good tolerance of the nonpulsatile blood flow in the early postoperative period, and pulsatility increased with recovery of the left ventricle because of unloading, we believe that the axial pumps will gain wide acceptance and provide a new option in the treatment of heart failure.

Abbott v. Miracor, IPR2025-00116
Abbott Ex. 1050, p. 8 of 10

Acknowledgments

The authors would like to thank K. Hoffman for data collection and A. Gale for editorial assistance.

REFERENCES

1. Frist B. Foreword. In: Cardiac Assist Devices. Goldstein DJ, Oz MC, eds. Armonk,New York: Future Publishing Co., Inc., 2000:v–vi.
2. Funk M. Epidemiology of end-stage heart disease. In: Hogness J, Vanantwerp M, eds. The Artificial Heart: Prototypes, Policies, and Patients. Washington: National Academic Press, 1991:251–61.
3. Erdmann E. Die Behandlung der Herzinsuffizienz: eine Übersicht. In: Betablocker im neuen Jahrtausend. Dominiak P, G.Heusch, eds. Darmstadt: Steinkopff Darmstadt, 2001:2–10.
4. The CONSENSUS Trial Study Group. Effects of enalapril on mortality in severe congestive heart failure. Results of the Cooperative North Scandinavian Enalapril Survival Study (CONSENSUS). N Engl J Med. 1987;316:1429–35.
5. The SOLVD Investigators. Effect of enalapril on survival in patients with reduced left ventricular ejection fractions and congestive heart failure. N Engl J Med. 1991;325:293–302.
6. Pfeffer MA, Braunwald E, Moye LA, et al. Effect of captopril on mortality and morbidity in patients with left ventricular dysfunction after myocardial infarction. Results of the survival and ventricular enlargement trial. The SAVE Investigators. N Engl J Med. 1992;327: 669–77.
7. Packer M, Greenberg B, Massie B, Dash H. Deleterious effects of hydralazine in patients with pulmonary hypertension. N Engl J Med. 1982;306:1326–31.
8. Hogness J. Preface. In: The Artificial Heart: Prototypes, Policies, and Patients. Hogness J, Vanantwerp M, eds. Washington: National Academic Press, 1991:i–x.
9. Hosenpud JD, Bennett LE, Keck BM, Boucek MM, Novick RJ. The Registry of the International Society for Heart and Lung Transplantation: Seventeenth official report—2000. J Heart Lung Transplant. 2000;19:909–31.
10. DeBakey ME. Left ventricular bypass pump for cardiac assistance. Clinical experience. Am J Cardiol. 1971;27:3–11.
11. Farrar DJ, Lawson JH, Litwak P, Cederwall G. Thoratec VAD system as a bridge to heart transplantation. J Heart Transplant. 1990; 9:415–22; discussion 422–3.
12. Hennig E, Zartnack F, Schiessler A, Hetzer R. The Berlin heart assist system. Biomed Tech (Berl). 1990;35(Suppl 3):294–6.
13. Goldstein D. Intracorporeal support: Thermo cardiosystems ventricular assist devices. In: Cardiac Assist Devices. Goldstein D, Oz M, eds. Amonk, NY: Futura Publishing Co., Inc., 2000:307–22.
14. Ramasamy N, Vargo RL, Kormos RL, Portner PM. Intracorporeal support: The Novacor left ventricular assist system. In: Cardiac Assist Device. Goldstein D, Oz M, eds. Armonk, NY: Futura Publishing Co., Inc., 2000:323–39.
15. El-Banayosy A, Arusoglu L, Kizner L, et al. Novacor left ventricular assist system vs. Heartmate vented electric left ventricular assist system as a long-term mechanical circulatory support device in bridging patients: A prospective study. J Thorac Cardiovasc Surg. 2000;119: 581–7.
16. El-Banayosy A, Deng M, Loisance DY, et al. The European experience of Novacor left ventricular assist (LVAS) therapy as a bridge to transplant: A retrospective multicentre study. Eur J Cardiothorac Surg. 1999;15:835–41.
17. Loebe M, Weng Y, Muller J, et al. Successful mechanical circulatory support for more than two years with a left ventricular assist device in a patient with dilated cardiomyopathy. J Heart Lung Transplant. 1997;16:1176–9.
18. Loebe M, Hennig E, Muller J, Spiegelsberger S, Weng Y, Hetzer R. Long-term mechanical circulatory support as a bridge to transplantation, for recovery from cardiomyopathy, and for permanent replacement. Euro J Cardio-Thorac Surg. 1997;11(Suppl):S18–24.
19. El-Banayosy A, Arusoglu L, Kizner L, Fey O, Minami K, Korfer R. Complications of circulatory assist. Perfusion. 2000;15:327–31.
20. Goldberg SP, Baddley JW, Aaron MF, Pappas PG, Holman WL. Fungal infections in ventricular assist devices. Asaio J. 2000;46:S37–40.
21. Grossi P, Dalla Gasperina D, Pagani F, Marone P, Vigano M, Minoli L. Infectious complications in patients with the Novacor left ventricular assist system. Transplant Proc 2001;33:1969–71.
22. Holman WL, Fix RJ, Foley BA, McGiffin DC, Rayburn BK, Kirklin JK. Management of wound and left ventricular assist device pocket infection. Ann Thorac Surg. 1999;68:1080–2.
23. Holman WL, Skinner JL, Waites KB, Benza RL, McGiffin DC, Kirklin JK. Infection during circulatory support with ventricular assist devices. Ann Thorac Surg. 1999;68:711–6.
24. McBride LR, Swartz MT, Reedy JE, Miller LW, Pennington DG. Device-related infections in patients supported with mechanical circulatory support devices for greater than 30 days. ASAIO Trans. 1991;37:M258–9.
25. McBride LR, Naunheim KS, Fiore AC, et al. Risk analysis in patients bridged to transplantation. Ann Thorac Surg. 2001;71:1839–44.
26. Myers TJ, Khan T, Frazier OH. Infectious complications associated with ventricular assist systems. Asaio J. 2000;46:S28–36.
27. Prendergast TW, Todd BA, Beyer AJ, et al. Management of left ventricular assist device infection with heart transplantation. Ann Thorac Surg. 1997;64:142–7.
28. Tjan TD, Asfour B, Hammel D, Schmidt C, Scheld HH, Schmid C. Wound complications after left ventricular assist device implantation. Ann Thorac Surg. 2000;70:538–41.
29. Weyand M, Hermann M, Kondruweit M, et al. Clinical impact of infections in left ventricular assist device recipients: The importance of site and organism. Transplant Proc 1997;29:3327–9.
30. Albert W, Kiekbusch S, Köller K, Hetzer R. Quality of life with ventricular assist devices. In: Mechanical Circulatory Support. Hetzer R, Hennig E, Loebe M, eds. Darmstadt: Springer and Steinkopff; 1997:191–205.
31. Noon G, Morley D, Irwin S, DeBakey M. The DeBakey ventricular assist device. In: Cardiac Assist Devices. Goldstein D, Oz M, eds. Armonk, NY: Futura Publishing Co., Inc., 2000:375–86.
32. DeBakey ME. A miniature implantable axial flow ventricular assist device. Ann Thorac Surg. 1999;68:637–40.
33. Wernicke JT, Meier D, Mizuguchi K, et al. A fluid dynamic analysis using flow visualization of the Baylor/NASA implantable axial flow blood pump for design improvement. Artific Organs. 1995;19:161–77.
34. Noon GP, Morley D, Irwin S, Benkowski R. Development and clinical application of the MicroMed DeBakey VAD. Curr Opin Cardiol. 2000;15:166–71.
35. Potapov EV, Loebe M, Nasseri BA, et al. Pulsatile flow in patients with a novel nonpulsatile implantable ventricular assist device. Circulation. 2000;102(19 Suppl 3):III 183–7.
36. Fossum TW, Morley D, Olsen DB, et al. Complications common to ventricular assist device support are rare with 90 days of DeBakey VAD support in calves. Asaio J. 2001;47:288–92.
37. Fossum TW, Morley D, Benkowski R, et al. Chronic survival of calves implanted with the DeBakey ventricular assist device. Artific Organs. 1999;23:802–6.
38. Wieselthaler GM, Schima H, Hiesmayr M, et al. First clinical experience with the DeBakey VAD continuous-axial-flow pump for bridge to transplantation. Circulation. 2000;101:356–9.
39. Wieselthaler GM, Schima H, Lassnigg AM, et al. Lessons learned from the first clinical implants of the DeBakey ventricular assist device axial pump: A single center report. Ann Thorac Surg. 2001;71(3 Suppl):S139–43; discussion S144–6.
40. Koster A, Loebe M, Hansen R, et al. Alterations in coagulation after implantation of a pulsatile novacor LVAD and the axial flow MicroMed DeBakey LVAD. Ann Thorac Surg. 2000;70:533–7.
41. Potapov EV, Loebe M, Abdul-Khaliq H, et al. Postoperative course of S-100B protein and neuron-specific enolase in patients after implantation of continuous and pulsatile flow LVADs. J Heart & Lung Transplant. 2001;20:1310–6.

Abbott v. Miracor, IPR2025-00116
Abbott Ex. 1050, p. 9 of 10

42. Potapov EV, Nasseri BA, Loebe M, et al. Transcranial detection of microembolic signals in patients with a novel nonpulsatile implantable LVAD. Asaio J. 2001;47:249–53.
43. Nabavi DG, Georgiadis D, Mumme T, et al. Clinical relevance of intracranial microembolic signals in patients with left ventricular assist devices. A prospective study. Stroke. 1996;27:891–6.
44. Schmid C, Weyand M, Nabavi DG, et al. Cerebral and systemic embolization during left ventricular support with the Novacor N100 device. Ann Thorac Surg. 1998;65:1703–10.
45. Wilhelm CR, Ristich J, Knepper LE, et al. Measurement of hemostatic indexes in conjunction with transcranial Doppler sonography in patients with ventricular assist devices. Stroke. 1999;30:2554–61.
46. Shevde K, DeBois WJ. Pro: Pulsatile flow is preferable to nonpulsatile flow during cardiopulmonary bypass. J Cardiothorac Anesth. 1987;1:165–8.
47. Taenaka Y, Tatsumi E, Nakamura H, et al. Physiologic reactions of awake animals to an immediate switch from a pulsatile to nonpulsatile systemic circulation. ASAIO Trans. 1990;36:M541–4.
48. Taylor K, Bain W, Davidson K, Turner M. Comparative clinical study of pulsatile and nonpulsatile perfusion in 350 consecutive patients. Thorax. 1982;37:324–30.
49. Yada I, Golding LR, Harasaki H, et al. Physiopathological studies of nonpulsatile blood flow in chronic models. Trans Am Soc Artif Intern Organs. 1983;29:520–5.
50. Mori F, Ivey T, Itoh T, Thomas R, Breazeale D, Misbach G. Effect of pulsatile reperfusion on postischemic recovery of myocardial function after global hypotermic cardiac arrest. J Thorac Cardiovasc Surg. 1987;93:719–27.
51. Finlayson D. Con: Nonpulsatile flow is preferable to pulsatile flow during cardiopulmonary bypass. J Cardiothorac Anesthesia. 1987;1:169–70.
52. Canivet J, Larbusson R, Damas P, et al. Plasma renin activety and urine b2-microglobulin during and after cardiopulmonary bypass: pulsatile vs nonpulsatile perfusion. Euro Heart J. 1990;11:1079–82.
53. Wright G. The assesment of pulsatile blood flow. Circulation. 1995;10:135–40.
54. Wright G. Hemodynamic analysis could resolve the pulsatile blood flow controversy. Ann Thorac Surg. 1994;58:1199–204.
55. Wright G, Furness A. What is pulsatile flow? Ann Thorac Surg. 1985;39:401–2.
56. Wilkens H, Regelson W, Hoffmeister F. The physiologic importance of pulsatile blood flow. N Engl J Med. 1962;267:443–6.
57. Fukae K, Tominaga R, Tokunaga S, Kawachi Y, Imaizumi T, Yasui H. The effects of pulsatile and nonpulsatile systemic perfusion on renal sympathetic nerve activity in anesthetized dogs. J Thorac Cardiovasc Surg. 1996;111:478–84.
58. Waaben J, Wulf H, Wettermark G, Andersen K, Husum B. ATP content in muscular interstitial fluid during pulsatile and nonpulsatile cardiopulmonary bypass in pigs. Biomed Biochem Acad. 1985;44:1113–8.
59. Busse R, Fleming I. Pulsatile stretch and shear stress: Physical stimuli determining the production of endothelium-derived relaxing factors. J Vasc Res. 1998;35:73–84.
60. Gaer J, Shaw A, Wild R, et al. Effect of cardiopulmonary bypass on gastrointestinal perfusion and function. Ann Thorac Surg. 1994;57:371–5.
61. Vainshtein G, Moskalenko Y. The significance of pulsation factor for functioning of the cerebral circulation system. Fisiol Zh Im I M Sechenova. 1995;81:54–8.
62. Golding LR, Murakami G, Harasaki H, et al. Chronic nonpulsatile blood flow. Trans Am Soc Artif Intern Organs. 1982;28:81–5.
63. Johnston GG, Hammill F, Marzec U, et al. Prolonged pulseless perfusion in unanesthetized calves. Arch Surg. 1976;111:1225–30.
64. Satoh H, Miyamoto Y, Shimazaki Y, et al. Comparison between pulsatile and nonpulsatile circulatory assist for the recovery of shock liver. Asaio J. 1995;41:M596–600.
65. Muller J, Wallukat G, Weng YG, et al. Weaning from mechanical cardiac support in patients with idiopathic dilated cardiomyopathy. Circulation. 1997;96:542–9.
66. Potapov EV, Loebe M, Hennig E, et al. Pulsatile flow in patients with a novel nonpulsatile implantable LVAD. In: Swain JA, Utley JR, eds. Proceedings of the 20th San Diego Cardiothoracic Surgery Symposium: Pathophysiology & Techniques of Cardiopulmonary Bypass; 2000, San Diego, California, USA., 2000:61.
67. Wieselthaler GM, Schima H, Dworschak M, et al. First experiences with outpatient care of patients with implanted axial flow pumps. Artif Organs. 2001;25:331–5.
68. Noon GP, Morley DL, Irwin S, Abdelsayed SV, Benkowski RJ, Lynch BE. Clinical experience with the MicroMed DeBakey ventricular assist device. Ann Thorac Surg. 2001;71(3 Suppl):S133–8; discussion S144–6.
69. Wilhelm MJ, Hammel D, Schmid C, et al. Clinical experience with nine patients supported by the continuous flow Debakey VAD. J Heart Lung Transplant. 2001;20:201.
70. Thompson LO, Noon GP. Combined anticoagulation protocol for the MicroMed DeBakey VAD: A proposal. J Heart Lung Transplant. 2001;20:798–802.
71. Loebe M, Potapov E, Drews T, Weng Y, Ngo W. Grafin zu Dohna R, et al. Advances and perspectives in mechanical heart assist. Z Kardiol. 2000;89(Suppl 7):91–8.
72. Westaby S, Banning AP, Jarvik R, et al. First permanent implant of the Jarvik 2000 Heart. Lancet. 2000;356(9233):900–3.
73. Griffith BP, Kormos RL, Borovetz HS, et al. HeartMate II left ventricular assist system: From concept to first clinical use. Ann Thorac Surg. 2001;71(3 Suppl):S116–20; discussion S114–6.

Abbott v. Miracor, IPR2025-00116
Abbott Ex. 1050, p. 10 of 10