ELSEVIER

Seminars in Cutaneous Medicine and Surgery

Superficial Chemical Peels and Microdermabrasion for Acne Vulgaris

Stephan John Kempiak, MD, PhD,* and Nathan Uebelhoer, DO†

Superficial chemical peels and microdermabrasion are used for many dermatologic conditions. A common condition treated with these modalities is acne vulgaris. In this review, we discuss the theory behind the technique of these procedures and describe the application and complications of each of these procedures in the office setting. The evaluation of patients before proceeding with the procedure and discuss pre- and postpeel regimens used for patients is discussed. We also analyze studies on both of these in-office procedures and comparative studies between the 2 most commonly used superficial chemical peeling agents, glycolic and salicylic acid.
Semin Cutan Med Surg 27:212-220 **© 2008 Elsevier Inc. All rights reserved.**

Chemical peels have been used in society for centuries. The earliest descriptions were from the ancient Egyptians who used sour milk, which contains lactic acid, for facial smoothening.[1,2] This treatment was introduced into the medical society by Unna and did not explode until the 1980s when glycolic acid demonstrated success in cosmetic and acne treatment.[3] This explosion is mainly a result of the ease of application of this compound, low complication rate, and positive patient perception of effectiveness.[4]

Acne is influenced by 3 factors generating comedonal and inflammatory papule formation. They are the formation of a keratinous plug, increased sebum production, and increased growth of commensurate microorganism, in particular *Propionibacterium acnes*.[5-8] The keratinous plug forms at the follicular infundibulum, which initiates the formation of comedones. Androgens help to stimulate sebaceous gland activity, leading to filling of the comedones with sebaceous material, which provides a medium for endogenous bacteria to grow. These events of distortion of the natural pilosebaceous architecture result in inflammation. Many acne treatments are available to physicians for treating acne that specifically interfere with any of the 3 aforementioned processes. In this article, we focus on 2 commonly used nonlaser therapeutic options for superficial exfoliation: superficial chemical peels and microdermabrasion.

Because the resolve of comedones ranges between 2 and 6 weeks,[9] superficial chemical peeling is used in those patients desiring to speed up this process. Chemical peels cause corneocyte adhesion or epidermolysis to the stratum granulosum layer. The intensity of the effect depends on the pH and concentration of the product used.[10,11] These changes are believed to result in improved elasticity of stratum corneum as new cells are produced and stimulate collagen production in the superficial dermis.[11] Therefore, superficial peeling will hasten the transition of closed comedones to the surface of the epidermis resulting in a quicker clearance of the lesions.

Superficial Chemical Peels for Acne Vulgaris

Glycolic Acid

The most commonly used chemical peel is glycolic acid (Table 1). This is an alpha-hydroxy acid, which has a hydroxyl group located at the first carbon after the carboxyl group. Although the Food and Drug Administration (FDA) has not issued a pregnancy rating on glycolic acid, epidemiological studies have not detected any fetal abnormalities when glycolic acid was used on pregnant patients.[12] It is supplied for home use at lower concentrations (5-20%) and pH 4-6 compared with office use, where it is used at its highest soluble concentration of 70% and a pH of 1 to 2.[11] Typical home use applications are as a wash used once or twice a day. The office procedure involves multiple steps in the preparation of the patient to after skin care.

This process is common for most superficial peels (Fig. 1). Patients are seen at first office visit to asses their current acne regimen and any previous treatments. Furthermore, the type of acne the patient has must be assessed. As mentioned previously, the purpose of superficial peels is to clear comedones

*University of California, San Diego, Division of Dermatology, San Diego, CA.
†Department of Dermatology, Naval Medical Center San Diego, San Diego, CA.
Reprint requests and correspondence: Dr. Nathan Uebelhoer, Department of Dermatology, Naval Medical Center San Diego, San Diego, CA 92134. E-mail: nathan.uebelhoer@med.navy.mil

 1085-5629/08/$-see front matter © 2008 Elsevier Inc. All rights reserved.
doi:10.1016/j.sder.2008.06.003

Sinclair et al v. HydraFacial
IPR2025-00145
HydraFacial Ex. 2013

Table 1 Comparison of Superficial Chemical Peeling Compounds

Acid Class	Compound	Concentration (%)		Epidermolysis Depth	Frequency of Office Application (d)	Erythema	Risk of Systemic Toxicity	Requires Neutralization	Other
		Home	Office						
Alpha	Glycolic Acid	5 to 15	50 to 70	Sratum Basale	7 to 14	+		+	
Beta	Salicylic Acid	2 to 15	20 to 50	Stratum Granulosum	7 to 14	+	+		
Alpha-keto	Pyruvic Acid	N/A	40 to 50	Stratum Granulosum	14	++	+	+	Pugent irritating vapors
Phenol	Resorcinol	N/A	10 to 50	Stratum Basale	14 to 28	++			Time consuming compared to other peels; May penetrate to dermis

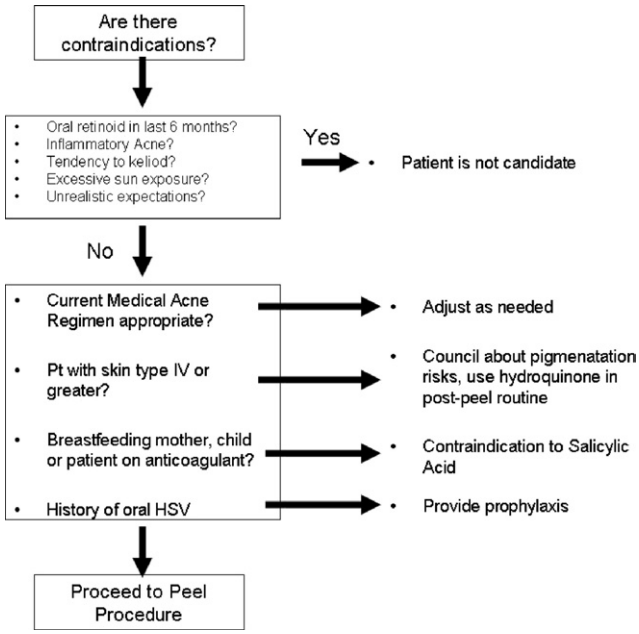

Figure 1 Flow diagram for determining candidacy of patients for superficial chemical peeling.

quickly, so patient's acne should preferably be of the comedonal type. If patients have no current medical acne regimen, an appropriate topical antibiotic and/or topical retinoid should be supplemented. Patients on oral retinoids are not recommended to undergo superficial peeling procedures because there may be severe irritation.[13] Furthermore, we caution on using peels in patients with inflammatory acne. These patients are more prone to develop postpeel worsening of papular and pustular lesions secondary to the postoperative wound care. Patient perception of successful treatment and realistic expectations also are addressed. The risk of transient hyperpigmentation or permanent hypopigmentation in patients of type IV or greater skin types should be discussed. If these patients desire to proceed with the procedure, a test site could be peeled to check for possible reactions or the peeling compound may be started at lower concentrations and titrated up as tolerated. The physician should also assess if the patient has any history of oral herpes simplex virus infections and start appropriate antiviral prophylaxis[14] to ensure no cutaneous eruptions develop after the ensuing exfoliation (Fig. 2). After the physician determines that the patient is a good candidate for superficial peeling, one option is to initiate treatment at home with a glycolic acid solution for home use as well as either topical retinoid and/or topical or oral antibiotic treatment depending on their current regimen (Table 2). The adherence of the patient to this initial therapy indicates future compliance and will demonstrate how well the individual can tolerate the peeling compound and likely chance of hyper- or hypopigmentation, especially for patients with skin type IV or greater.[2]

All patients desiring an in-office peel should be counseled regarding the potential side effects and then sign an informed consent. The peel is performed by cleaning the face with a gentle cleanser, followed by stripping away any surface oils

Figure 2 Complication of herpes simplex labialis in patient after glycolic acid peeling. This figure was published in Mark Rubin (ed): Procedures in Cosmetic Dermatology Series: Chemical Peels (Procedures in Cosmetic Dermatology), Volume 1. Philadelphia, Elsevier, Saunders, 2006, pp 36.

with isopropyl alcohol. The glycolic acid is then applied using a soaked gauze pad on the face, starting on the forehead, moving to cheeks, nose, and then chin. The goal is for the glycolic peel to penetrate down to the stratum granulosum layer, which is indicated when the skin frosts. A "frosting" event may occur where a red-spotted pattern or blanching develops indicating epidermolysis and detachment from the papillary dermis.[13,15] This is usually achieved between 2 and 10 minutes after application. At this moment, the glycolic acid is neutralized with a buffered bicarbonate solution or cool water. This neutralization of the acid prevents further corneocyte adhesion, which prevents peeling to deeper layers of the epidermis. During the procedure, most patients develop a burning sensation, which is normally relieved after washing off the solution and made bearable during application by using a fan to blow cool air over the face. Although no rigorously controlled studies have been performed, there have been clinical trials demonstrating the efficacy of this technique on Caucasian[16,17] as well as darker skin types (Fig. 3).[18]

The study by Atzori and coworkers[16] observed 80 female patients undergoing 70% glycolic peeling every 10 days for 6 or more treatments. They demonstrated a quicker physician's assessment of lesional improvement in patients with comedonal compared with those with nodulocystic acne. In general, it took the former group 3 to 4 peels to achieve a decrease of 50% of acne lesions, whereas the latter required up to 9 treatments to obtain a similar general response. In this study, 20% of patients experienced some worsening of their acne after treatments associated with the erythema and discomfort as described above, but in general most patients were very satisfied with their results. The study by Wang and coworkers[18] observed glycolic peeling with 30% to 50% concentration every 3 weeks to patients with skin types III to IV. They used the greater concentration in patients with oilier skin types and achieved an objective improvement in the majority of patients examined after 11 treatments. These patients developed similar complications as mentioned previously without any noted hyperpigmentation. These studies demonstrate that superficial chemical peels can benefit many different skin types.

After the procedure, the patient undergoes a postpeel regimen of an emollient for dryness and crusting and a combination of sunscreen and/or occlusive moisturizer (white petrolatum) to prevent any further irritation (Table 3). Complications after the peel of which to be aware are urticarial eruptions or perioral dermatitis (Fig. 4). The patient should know these complications and notify the treating physician if they develop so appropriate treatment can be started. For urticarial eruptions, we recommend starting treatment with an oral antihistamine, such as hydroxyzine or loratadine. If

Table 2 Glycolic Acid Peel/Acne Wash Procedure Instructions

- 1. After your initial consultation, start washing your face routinely with a skin regimen that includes your glycolic acid cleanser. DO NOT use regular soap and water as it will not correctly prepare your skin for the procedure.
- 2. Avoid extensive sun exposure. Apply a sunscreen with SPF 15 or hreater as part of your daily regimen.
- 3. Two weeks prior to your peel you should begin a skin given to you by your physician.
- 4. For 1 week prior to the peel, STOP the use of the following treatments and products:
  - Retin-A or Renova (tretinoin), Tazorac or Ayage (tazarotene), Diferin (adapalene) and any other retinoids, such as retinol
  - Waxing, depilatories, electrolysis
  - Masques, loofahs and other sponges
  - Hair dyeing, permanent wave or straightening treatments
  - Other resurfacing or exfoliating treatments
- Use of the above products/treatments prior to your peel may increase the reactivity of the skin to the glycolic acid and should therefore be avoided.
- 5. We have reviewed your medical history and discussed the following areas:
  - Allergies
  - Whether you have a history of atopic dermatitis, eczema, seborrheic dermatitis, viral infections, collagen disease, autoimmune disease
  - Medications used at present
  - Photosensitivity (sun sensitivity)
- If there is any additional information that has not been discussed, please contact your physician prior to you peel. As a reminder, if you do have a history of herpes simplex (cold sores) you whould be on a preventive oral antiviral medication. The peel procedure can induce an episode of herpes lesions on patients who have had them previously.
- 6. At the day of your appointment to have the peel, please come to the office fully cleansed face; no makeup, aftershave or cologne should be applied. Avoid shaving on the day of the peel.

Superficial Chemical Peel/Acne Wash Postprocedure Instructions. This table was adapted from a section published in Procedures in Cosmetic Dermatology Series: Chemical Peels (Procedures in Cosmetic Dermatology), Volume 1, Mark Rubin, Page 32, Copyright Elsevier (2006).

Figure 3 Patient with type V skin comparing baseline (A) with skin after 3 glycolic acid peels, one at 20% and the other two at 35% (B). This figure was published in Mark Rubin (ed): Procedures in Cosmetic Dermatology Series: Chemical Peels (Procedures in Cosmetic Dermatology), Volume 1. Philadelphia, Elsevier, Saunders, 2006, pp 41.

they do not improve the condition, a brief course of a systemic corticosteroid may be added. Patients that develop perioral dermatitis can be treated with oral tetracyclines till the eruption clears. We generally avoid application of topical medications for postpeel complications because they may irritate or further exacerbate these sequelae. Furthermore, if either of these complications is encountered, we generally recommend discontinuation of any future glycolic acid containing products.

Table 3 Glycolic Acid Peel/Acne Wash Postprocedure Instructions

- It may take up to 1 week for the appearance of your skin to return to normal. During the repair/renewal period, you may experience some of the following: stinging, itching, burning, and mild to moderate pain, tightness, and peeling along with scabbing of the superficial layer of the skin. These sensations will gradually diminish over the course of the week as the skin returns to its normal appearance. If swelling occurs, use cold compress with ice for 15 minutes on and 15 minutes off, intermittently as needed.
- Following these guidelines will help accelerate the renewal process:
- Apply the postprocedure moisturizer twice daily for 3 to 7 days until the skin returns to its normal appearance and then restart your maintenance regimen.
- Wash the treated area very gently, using the products or treatment given to you by your physician
- Do not use abrasive or exfoliating sponges on the treated area(s).
- Avoid extensive sun exposure.
- Continue to apply sunscreen, as tolerated, beginning the day after the peel because you are more sensitive to the sunlight.
- To avoid the possibility of scarring DO NOT:
- Peel the skin
- Scratch the skin
- Pick the skin
- Use a masque on the skin
- Scrape the skin.

Superficial Chemical Peel/Acne Wash Postprocedure Instructions. This table was adapted from a section published in Cosmetic Dermatology Series: Chemical Peels (Procedures in Cosmetic Dermatology), Volume 1, Mark Rubin, Page 35, Copyright Elsevier (2006).

The procedures are typically repeated every 7 to 14 days for 2 to 3 months (Fig. 5). In between office peels, the patient is encouraged to continue glycolic acid topically as well as any other acne regimen. Peeling usually occurs over the first day after treatment (Figs. 6 and 7), and is followed by erythema over the next 2 to 3 days. Some patients see benefits of post peel procedures for up to 5 months (Fig. 7).

Salicylic Acid

The other commonly used office peel is salicylic acid. It is incorrectly labeled as a beta-hydroxy acid, which would indicate a hydroxyl group at the second carbon from the carboxyl group in a carboxylic acid. Instead, it is a benzoic acid with a hydroxyl group at the atom adjacent to the carboxyl containing carbon. This compound would more appropriately be termed *o*-hydroxybenzoic acid. It is ingested orally without complications in its acetylated form, aspirin. This association poses a theoretical risk of Reye's syndrome in children, if the compound can become systemically absorbed through the skin.[19] Reye's syndrome is the development of encephalopathy and fatty degeneration of the liver after salicylate consumption, usually aspirin, during a viral infection, most often influenza or varicella. Although no studies have demonstrated topical salicylic acid use in pregnant patients, it is considered FDA Pregnancy Class C for its association with aspirin and its systemic absorption causing birth defects in animal models.[20] Furthermore, systemic salicylic acid causes platelet coagulation problems in nursing infants of women undergoing salicylic acid peels or patients of anticoagulation.[19] Thus, patients presenting in these situations require a cautious approach.

In-office salicylic acid peels are generally performed at 20% to 30% concentration with home use between 0.5% and 10%.[19] The regimen for salicylic acid is similar to glycolic

Figure 4 Patients with urticarial (A) and perioral dermatitis (B and C) after glycolic acid peeling. This figure was published in Mark Rubin (ed): Procedures in Cosmetic Dermatology Series: Chemical Peels (Procedures in Cosmetic Dermatology), Volume 1. Philadelphia, Elsevier, Saunders, 2006, pp 36.

acid as previously mentioned except for a few differences. Like glycolic acid, patients are prescreened before treatment (Table 1) and placed on an optimized acne regimen. The patients are sent home with a salicylic acid solution-based product to test compliance and safety of applying the product. Before the in-office peel, the patient's skin is cleansed with a gentle cleanser and then the surface oils are striped away with isopropyl alcohol. A fan may be used during this procedure to allow patients some comfort with the burning sensation of superficial peeling as with glycolic acid application. Unlike the glycolic peel, salicylic acid precipitates on the skin, leaving behind a white frost to the areas applied. Furthermore, salicylic acid is a volatile compound; therefore, after 4 minutes of topical application, there is usually no more active compound remaining.[21] A patient treated with this modality does not require the buffering step and the practitioner can quantify the topical application amount to the amount of white precipitate left behind. After this 4-minute application, the substrate may then be easily washed off with either water or a gentle cleansing solution. Areas that are less white may be retouched in the same sitting, thus allowing the physician to apply a more homogenous application. Just like glycolic acid, salicylic acid can be used in all skin types.[22,23]

Although these peels can lighten patient's skin tone,[24] many physicians recommend hyperpigmentation prophylaxis for both glycolic and salicylic acid peels with topical hydroquinone. This is especially important for patients of

Figure 5 Patient 2 weeks after 70% glycolic acid peel (B) compared with baseline (A). This figure was published in Mark Rubin (ed): Procedures in Cosmetic Dermatology Series: Chemical Peels (Procedures in Cosmetic Dermatology), Volume 1. Philadelphia, Elsevier, Saunders, 2006, pp 39.

Figure 6 Baseline (A) compared with postprocedure day 1 (B) after 70% glycolic acid peel. This figure was published in Mark Rubin (ed): Procedures in Cosmetic Dermatology Series: Chemical Peels (Procedures in Cosmetic Dermatology), Volume 1. Philadelphia, Elsevier, Saunders, 2006, pp 39.

darker skin types. As discussed earlier in this text, it is imperative to assess skin types before chemical peeling and discuss with patients the risk of hyperpigmentation associated postpeel changes and the likelihood of permanent hypopigmentation.

Comparison of Glycolic With Salicylic Acid Peels in Acne

There have been many studies in which the authors observed the efficacy of both glycolic and salicylic acid peels for either in home or office use,[16,18,22-27] but there have been relatively few comparative clinical trials or those that observe clinical response outside of 1 month from last peel. A recent, split-faced, double-blind trial compared a 30% concentration of each compound on 20 individuals every other week for 3 months.[17] There was a decrease of acne lesions in the salicylic acid group, which persisted 2 months after the last peel, compared with glycolic acid, which displayed new acne lesions after discontinuation of peeling. However, this difference in lesional counts was small and not significant, and patients did not favor salicylic acid over glycolic acid.

There were limits to this trial, as some patients were allowed to continue topical acne medications, and it did not compare a 70% glycolic acid product, the more commonly used concentration. However, it demonstrated both products' effectiveness in decreasing lesional counts of acne (Fig. 8) and that salicylic acid may provide longer-lasting effects compared with a low concentration of glycolic acid. Another trial compared 70% glycolic acid to Jessner's solution, which contains only 14% salicylic acid, lactic acid (an alpha-hydroxy acid) and resorcinol in a split face trial of three treatments total. Both sides decreased lesions by 25%, with a nonsignificant increased preference to glycolic acid.[28] Two patients in the glycolic acid treated side developed eczematous crusts with oozing, otherwise patients generally experienced scaling and

Figure 7 Patient at baseline (A), immediately after (B), and 5 months (C) after a 70% glycolic acid peel. This figure was published in Mark Rubin (ed): Procedures in Cosmetic Dermatology Series: Chemical Peels (Procedures in Cosmetic Dermatology), Volume 1. Philadelphia, Elsevier, Saunders, 2006, pp 40.

Figure 8 Half face comparison between glycolic and salicylic acid at baseline (A), 3 peels (B), 5 peels (C), and 2 months after last peel (D). Reprinted by permission from Kessler E, Flanagan K, Chia C, et al: Comparison of α- and β-hydroxy acid chemical peels in the treatment of mild to moderately severe facial acne vulgaris Dermatologic Surgery 34:45-51, 2008.

erythema as described above with both treatment modalities. Although this study did not observe patients over a longer period, it was well controlled with no patients on other acne therapies. These studies indicate that superficial peels using either glycolic acid or salicylic acid are well-tolerated and can improve acne, but do not suggest one superior to the other.

Other Superficial Chemical Peeling Agents

Besides salicylic and glycolic acids there are numerous other types of superficial peels: resorcinol, lactic acid, trichloracetic acid, and pyruvic acid.[10] Resorcinol, which commonly is used in Jessner's solution at a 14% concentration, has shown success at 50% alone in patients concurrently on topical or oral antibiotics.[29] Pyruvic acid, an alpha-keto acid that converts to lactic acid on application, is used in concentrations up to 50%.[13] It can decrease sebum production and decrease the amount and size of lesions in patients with mild-to-severe acne; however, the vapors from this volatile compound are irritating to the respiratory tract.[30] Although anything stronger than a superficial peel is not recommended for acne,[2,10] one report of direct injection of comedones with 50% trichloroacetic acid claimed therapeutic clearance at 6 months after treatment.[31] Although these products have shown success in patients, there have been no rigorous comparative trials like those described previously between glycolic and salicylic acid. It has been suggested that some patients be treated with combinations of peeling regimens, ie, glycolic acid and pyruvic acid or glycolic acid with acetic acid.[32] With such a variety

of choices, it is best to proceed with the procedure that the practitioner is most familiar.

Microdermabrasion for the Treatment of Acne Vulgaris

Like chemical peels, there are multiple types of dermabrasion. Dermabrasion involves either manual dermasanding with sandpaper or wallscreen or with mechanized handheld units. These units are attached with either a wire brush or diamond fraise. These techniques often use refrigerant spray cooling, like Freon, to impart transient anesthesia and hardening of the skin and also provide a rigid surface amenable to resurfacing. This type of dermal restructuring usually results in removal of tissue to the level of the papillary dermis and can result in scarring if not used appropriately.[33] Therefore, many authors recommend this type of dermabrasion for acne scarring, not for primary lesions.[34-37] However, there were 2 case reports that demonstrated this technique being useful in patients with Favre-Racouchot/nodular cutaneous elastosis.[38,39]

More recently, many physicians and esthetic spas are using a more superficial abrasion known as microdermabrasion. This technique was originally shown to be beneficial in patients in acne.[40,41] Microdermabrasion involves propelling polyester or nylon bristles or an element (eg, aluminum oxide crystals) onto the face at various speeds, then vacuuming off the debris using a specialized wand or handpiece. The vacuum suction can be operated at various pressures, giving the operator the ability to control both the particle speed and suction at the skin surface. Although chronic aluminum oxide exposure is associated with respiratory disease, pulmonary fibrosis, interstitial pneumonia and papillomas of the larynx and trachea, there have been no such reports of these afflictions associated with dermabrasion use or operation.[42] A common complication is caused by eye irritation, which ranges from chemosis and tearing to photophobia to punctate keratitis if crystals adhere to the corneal epithelium.[43] There was one case of an urticarial reaction that cleared with systemic corticosteroids and an antihistamine.[42] Therefore, the practitioner must be aware of these complications and provide eye protection to each patient as well as wear a protective mask themselves when operating with this product.

The microdermabrasion tool is an FDA type 1 device, which does not require the achievement of performance standards for approval. Unfortunately, the initial encouraging results were not in rigorous-controlled trials and did not observe quantitative measures. One study demonstrated patients' lesional count decreasing by 50% or lower in almost three-quarters of the patients studied after 8 microdermabrasion procedures spaced 7 to 10 days apart.[44] This study's patient population was on both an oral antibiotic and topical retinoid (except for one patient, who was only on an oral antibiotic) and the protocol allowed adjustment of acne therapy as needed. Therefore, it is difficult to assess whether the changes the author recorded was caused by the microdermabrasion or better acne management/compliance as the result of frequent office visits, because there was no control group or strict adherence to medication regimen in the protocol. Furthermore, histopathological studies of patients treated with this technique demonstrate thinning of the stratum corneum and dermal edema and perivascular inflammation.[45] These data indicate that the changes appreciated by previous publications may be secondary to dermal changes rather then the abrasion which was minimal. Furthermore, a comparison of mild dermabrasion using a nylon brush at the mild setting to 20% glycolic acid peeling for 6 treatments separated by over 1 week at a time demonstrated that the majority of patients preferred the peel over the dermabrading technique.[46] These studies on superficial dermabrasion have demonstrated it as a "mild treatment that produces mild results,"[47] which may be beneficial in patients when used concurrently with medical acne treatment.

In the authors' experience, the role of microdermabrasion in acne is best used in combination with superficial chemical peels or as a pretreatment adjunct with red-light aminolevulinic acid photodynamic therapy (ALA-PDT). This process has been shown to decrease the incubation requirement of ALA in inducing erythema.[48] By removing the superficial stratum corneum before the application of topical ALA, the PDT effect is greater[48] and the improvement in comedonal and inflammatory acne, anecdotally, appears greater. Furthermore, we prefer a vacuum-assisted bristled microdermabrator (DermaSweep, Roseville, CA) in combination with glycolic or salicylic acid peels for augmentation of chemical efficiency. Studies are ongoing to demonstrate efficacy of this combination for actinic keratoses and follow-on investigations for acne treatment are anticipated.

Conclusions

In summary, chemical or mechanical exfoliation resulting in the reduction of keratotic plugs serves as a second-line treatment used as an adjunct to topical antiacne agents and systemic antibiotics. Specifically, glycolic acid has been used and studied extensively, demonstrating its beneficial effects when used within a combination approach. The improvement in postinflammatory acne-induced hyperpigmentation as well as the modest improvement in some fine textural irregularities are additional roles. When considering a patient for cosmetic, superficial resurfacing of acne lesions, it is important to keep in mind the objective of each individual patient. Consideration of the patient's current medical acne regimen should be addressed.[5-7] Those that desire or require enhanced comedone extraction and do not have any contraindications to this therapy may be considered for superficial peeling. As clinical trials and patients' opinions demonstrate, most patients treated with chemical exfoliation as an adjunct to acne therapy are satisfied with their treatment and achieve a sense of skin rejuvenation. A series of glycolic or salicylic acid peels in varying concentration or pH will generally be sufficient to meet these demands. Once a realistic goal has been communicated and agreed on the treatment can be started with meticulous assessment between peels to evaluate success and when to continue, stop or change their regimen.

References

1. Brody HJ, Monheit GD, Resnik SS, et al: A history of chemical peeling. Dermatol Surg 26:405-409, 2000
2. Godin DA, Graham HD 3rd: Chemical peels. J La State Med Soc 150: 513-520, 1998
3. Berardesca E, Cameli N, Primavera G, et al: Clinical and instrumental evaluation of skin improvement after treatment with a new 50% pyruvic acid peel. Dermatol Surg 32:526-531, 2006
4. Clark CP 3rd: Office-based skin care and superficial peels: The scientific rationale. Plast Reconstr Surg 104:854-864; discussion 865-856, 1999
5. James WD: Clinical practice. Acne N Engl J Med 352:1463-1472, 2005
6. Bergfeld WF: The pathophysiology of acne vulgaris in children and adolescents, part 2: Tailoring treatment. Cutis 74:189-192, 2004
7. Gollnick H, Cunliffe W, Berson D, et al: Management of acne: A report from a Global Alliance to Improve Outcomes in Acne. J Am Acad Dermatol 49:S1-S37, 2003
8. Cunliffe WJ, Holland DB, Clark SM, et al: Comedogenesis: some aetiological, clinical and therapeutic strategies. Dermatology 206:11-16, 2003
9. Cunliffe WJ, Holland DB, Jeremy A: Comedone formation: Etiology, clinical presentation, and treatment. Clin Dermatol 22:367-374, 2004
10. Monheit GD, Chastain MA: Chemical peels. Facial Plast Surg Clin North Am 9:239-255, viii, 2001
11. Clark CP 3rd: Alpha hydroxy acids in skin care. Clin Plast Surg 23:49-56, 1996
12. Nussbaum R, Benedetto AV: Cosmetic aspects of pregnancy. Clin Dermatol 24:133-141, 2006
13. Zakopoulou N, Kontochristopoulos G: Superficial chemical peels. J Cosmet Dermatol 5:246-253, 2006
14. Gilbert S: Improving the outcome of facial resurfacing–prevention of herpes simplex virus type 1 reactivation. J Antimicrob Chemother 47: 29-34, 2001 (suppl T1)
15. Yu RJ, Van Scott EJ: Alpha-hydroxyacids and carboxylic acids. J Cosmet Dermatol 3:76-87, 2004
16. Atzori L, Brundu MA, Orru A, et al: Glycolic acid peeling in the treatment of acne. J Eur Acad Dermatol Venereol 12:119-122, 1999
17. Kessler E, Flanagan K, Chia C, et al: Comparison of alpha- and beta-hydroxy acid chemical peels in the treatment of mild to moderately severe facial acne vulgaris. Dermatol Surg 34:45-50; discussion 51, 2008
18. Wang CM, Huang CL, Hu CT, et al: The effect of glycolic acid on the treatment of acne in Asian skin. Dermatol Surg 23:23-29, 1997
19. Akhavan A, Bershad S: Topical acne drugs: review of clinical properties, systemic exposure, and safety. Am J Clin Dermatol 4:473-492, 2003
20. Yokoyama A, Takakubo F, Eto K, et al: Teratogenicity of aspirin and its metabolite, salicylic acid, in cultured rat embryos. Res Commun Chem Pathol Pharmacol 46:77-91, 1984
21. Kligman D: Technologies for cutaneous exfoliation using salicylic acid. Dermatol Ther 14:225-227, 2001
22. Grimes PE: The safety and efficacy of salicylic acid chemical peels in darker racial-ethnic groups. Dermatol Surg 25:18-22, 1999
23. Lee HS, Kim IH: Salicylic acid peels for the treatment of acne vulgaris in Asian patients. Dermatol Surg 29:1196-1199; discussion 1199, 2003
24. Ahn HH, Kim IH: Whitening effect of salicylic acid peels in Asian patients. Dermatol Surg 32:372-375; discussion 375, 2006
25. Fulghum DD, Catalano PM, Childers RC, et al: Abrasive cleansing in the management of acne vulgaris. Arch Dermatol 118:658-659, 1982
26. Lee SH, Huh CH, Park KC, et al: Effects of repetitive superficial chemical peels on facial sebum secretion in acne patients. J Eur Acad Dermatol Venereol 20:964-968, 2006
27. Hashimoto Y, Suga Y, Mizuno Y, et al: Salicylic acid peels in polyethylene glycol vehicle for the treatment of comedogenic acne in Japanese patients. Dermatol Surg 34:276-279; discussion 279, 2008
28. Kim SW, Moon SE, Kim JA, et al: Glycolic acid versus Jessner's solution: Which is better for facial acne patients? A randomized prospective clinical trial of split-face model therapy. Dermatol Surg 25:270-273, 1999
29. Karam PG: 50% resorcinol peel. Int J Dermatol 32:569-574, 1993
30. Cotellessa C, Manunta T, Ghersetich I, et al: The use of pyruvic acid in the treatment of acne. J Eur Acad Dermatol Venereol 18:275-278, 2004
31. Thappa DM: Comedone extraction with trichloracetic acid. J Dermatol 21:61, 1994
32. Briden ME: Alpha-hydroxy acid chemical peeling agents: Case studies and rationale for safe and effective use. Cutis 73:18-24, 2004
33. Robertson KM: Acne vulgaris. Facial Plast Surg Clin North Am 12:347-355, vi, 2004
34. Eller JJ, Walsh WR: Dermal abrasion in the treatment of acne. GP 24:89-91, 1961
35. Farrior RT: Dermabrasion in facial surgery. Laryngoscope 95:534-545, 1985
36. Fulton JE Jr: Dermabrasion, chemabrasion, and laserabrasion. Historical perspectives, modern dermabrasion techniques, and future trends. DermatolSurg 22:619-628, 1996
37. Cunliffe WJ: Acne vulgaris. Br Med J 4:667-669, 1973
38. Plewig G: Dermabrasion for nodular cutaneous elastosis with cysts and comedones. Arch Dermatol 105:294-296, 1972
39. English DT, Martin GC, Reisner JE: Dermabrasion for nodular cutaneous elastosis with cysts and comedones. Favre-Racouchot syndrome. Arch Dermatol 104:92-93, 1971
40. Cohen EL: Treatment of acne vulgaris with graded abrasion. Med World 96:101-102, 1962
41. Tsai RY, Wang CN, Chan HL: Aluminum oxide crystal microdermabrasion. A new technique for treating facial scarring. Dermatol Surg 21: 539-542, 1995
42. Grimes PE: Microdermabrasion. Dermatol Surg 31:1160-1165; discussion 1165, 2005
43. Morgenstern KE, Foster JA: Advances in cosmetic oculoplastic surgery. Curr Opin Ophthalmol 13:324-330, 2002
44. Lloyd JR: The use of microdermabrasion for acne: A pilot study. Dermatol Surg 27:329-331, 2001
45. Tan MH, Spencer JM, Pires LM, et al: The evaluation of aluminum oxide crystal microdermabrasion for photodamage. Dermatol Surg 27:943-949, 2001
46. Alam M, Omura NE, Dover JS, et al: Glycolic acid peels compared to microdermabrasion: A right-left controlled trial of efficacy and patient satisfaction. Dermatol Surg 28:475-479, 2002
47. Spencer JM: Microdermabrasion. Am J Clin Dermatol 6:89-92, 2005
48. Katz BE, Truong S, Maiwald DC, et al: Efficacy of microdermabrasion preceding ALA application in reducing the incubation time of ALA in laser PDT. J Drugs Dermatol 6:140-142, 2007