American Journal of Ophthalmology Case Reports 8 (2017) 58–61

Contents lists available at ScienceDirect

American Journal of Ophthalmology Case Reports

journal homepage: www.elsevier.com/locate/ajoc

One-year outcomes of ziv-aflibercept for macular edema in central retinal vein occlusion

Mohab Eldeeb[a], Errol W. Chan[a,b], Chintan J. Dedhia[c], Ahmad Mansour[d,e], Jay Chhablani[c,*]

[a] Montreal Retina Institute, Montreal, QC, Canada
[b] Department of Ophthalmology, McGill University, Montreal, QC, Canada
[c] Smt Kanuri Santhamma Centre for Vitreoretinal Diseases, LV Prasad Eye Institute, Hyderabad, Andhra Pradesh, India
[d] Department of Ophthalmology, American University of Beirut, Beirut, Lebanon
[e] Department of Ophthalmology, Rafic Hariri University Hospital, Beirut, Lebanon

ARTICLE INFO

Keywords:
Ziv-aflibercept
Anti-vascular endothelial factor (anti-VEGF)
Macular edema
Central retinal vein occlusion (CRVO)
Optical coherence tomography (OCT)

ABSTRACT

Purpose: To report the 12-month efficacy and safety outcomes of intravitreal ziv-aflibercept in macular edema secondary to central retinal vein occlusion (CRVO).

Methods: Interventional case series documenting 12-month outcomes of intravitreal ziv-aflibercept (1.25 mg in 0.05 mL) in 6 patients with treatment-naive macular edema secondary to CRVO. All patients had comprehensive ophthalmic examination, spectral domain optical coherence tomography at baseline and all follow-up visits, and fluorescein. Retreatment decisions were based on recurrence or persistence of intraretinal or subretinal fluid, deterioration in visual acuity (VA), increase in central subfield thickness (CST) by ≥ 50 μm from the previous visit, or lowest recorded CST.

Results: Participants had (2 males, 4 females) an average age of 53.5 years. From baseline to 12 months, the mean logMAR VA improved from 0.86 (Snellen ≈ 20/145) to 0.33 (Snellen ≈ 20/40), central macular thickness decreased from 519 μm to 255 μm, and total macular volume decreased from 14.7 mm^3 to 7.1 mm^3. No eyes had uveitis, cataract progression, intraocular pressure (IOP) elevations, or systemic adverse events.

Conclusions and importance: Ziv-aflibercept achieves favorable intermediate-term functional and structural outcomes in macular edema secondary to CRVO. No safety concerns were raised. Low-cost ziv-aflibercept may thus be useful for CRVO in resource-poor countries. Further prospective studies in larger cohorts are needed further establish the efficacy and safety of this agent.

1. Introduction

Central retinal vein occlusion (CRVO), is a common cause of vision loss affecting an estimated 2.5 million people globally.[1] A key pathogenic mechanism of retinal ischemia consequent to venous occlusion involves the upregulation of hypoxia regulated genes, including vascular endothelial growth factor-A (VEGF-A), a primary mediator in CRVO-associated macular edema.[2–4] The most common cause of visual impairment in patients with CRVO is macular edema.[5]

Over the last 3 decades, significant improvements in visual acuity (VA) outcomes for macular edema secondary to CRVO have been achieved owing to the advent of novel pharmacologic therapeutic modalities. Intravitreal steroid injections were the initial standard of care for CRVO-associated macular edema owing to the results of the SCORE and GENEVA trials.[6,7] However, the current mainstay of treatment is intravitreal anti-VEGF agents. One of these is aflibercept (Eylea; Regeneron Pharmaceuticals, Inc., Tarrytown, NY), which showed excellent functional and structural outcomes.[8,9]

Ziv-aflibercept (Zaltrap; Regeneron, New York, USA) is structurally isomeric with aflibercept, and acts on all VEGF subtypes, as well as placental growth factor. It is currently FDA-approved for metastatic colorectal cancer,[10] and is thus potentially available for ocular use by compounding pharmacies at a much lower cost than aflibercept. Intravitreal ziv-aflibercept has been used in a single patient with treatment-naïve branch retinal vein occlusion (BRVO), with favorable visual and structural response, and no signs of retinal toxicity or any ocular adverse events.[11] Similar findings were noted in treatment-resistant patients with BRVO.[12] Currently, there are no reports on the intermediate-term outcomes and safety of ziv-aflibercept in treatment-naïve CRVO, which would be important for further studies investigating a broader use of this agent. We report its use in 6 consecutive patients using a pro re nata (PRN) schedule.

* Corresponding author. Smt. Kanuri Santhamma Centre for Vitreoretinal Diseases, LV Prasad Eye Institute, Hyderabad, TS 500034, India.
E-mail address: jay.chhablani@gmail.com (J. Chhablani).

http://dx.doi.org/10.1016/j.ajoc.2017.10.011
Received 2 February 2017; Received in revised form 19 July 2017; Accepted 2 October 2017
Available online 06 October 2017
2451-9936/ © 2017 The Authors. Published by Elsevier Inc. This is an open access article under the CC BY-NC-ND license (http://creativecommons.org/licenses/BY-NC-ND/4.0/).

Table 1
Patients' characteristics and clinical data prior to and after treatment with intravitreal ziv-aflibercept.

Patient No.	Age	Gender	Lens status	Systemic illness	Snellen BCVA		CST (μm)		Total Macular Volume (mm^3)		IOP (mmHg)		Number of injections
					Baseline	Final	Baseline	Final	Baseline	Final	Baseline	Final	
1	55	F	Mild NS	HTN	20/200	20/100	417	229	11.9	6.3	21	20	6
2	44	M	Clear	Smoking, DM	20/320	20/30	708	231	19.8	6.4	19	14	8
3	56	F	Mild NS	DM	20/100	20/30	602	274	17.3	7.8	13	16	5
4	65	F	Clear	DM, HTN	20/100	20/25	490	243	13.6	6.8	15	17	6
5	48	M	Mild NS	HTN	20/200	20/50	574	256	16.2	7.3	20	20	7
6	53	F	Clear	DM, HTN	20/70	20/50	325	298	9.2	8.2	22	18	5

Abbreviations: BCVA, best-corrected visual acuity; CST, central subfield thickness; DM, diabetes mellitus; HTN, hypertension; IOP, intraocular pressure; NS, nuclear sclerosis.

Table 2
Baseline and one-year clinical and optical coherence tomography characteristics.

Variable	Baseline (n = 6)	12 months (n = 6)	P-value
logMAR VA, mean ± SD (range)	0.86 ± 0.25 (0.54–1.20)	0.33 ± 0.22 (0.09–0.69)	0.007
CST, mean ± SD (range), μm	519 ± 137 (325–708)	255 ± 27 (229–298)	0.008
Total Macular Volume, mean ± SD (range), mm^3	14.7 ± 3.9 (9.2–19.8)	7.1 ± 0.8 (6.3–8.2)	0.007
IOP, mean ± SD (range), mm Hg	18.3 ± 3.6 (13–22)	17.5 ± 2.3 (14–20)	0.55

Abbreviations: CST, central subfield thickness; IOP, intraocular pressure; logMAR, logarithm of the minimum angle of resolution; SD, standard deviation; VA, visual acuity.

2. Methods

2.1. Study design and subjects

This was a prospective single-center interventional case series conducted at Rafic Hariri University Hospital, Lebanon, between January 2015 and July 2016. This study was approved by the institutional review board and ethics committee, and adhered to the tenets of the Declaration of Helsinki. Informed consent was also obtained from patients.

Six treatment-naïve patients with CRVO and macular edema were included. Inclusion criteria included age ≥18 years and VA between ≤20/40 and ≥ 20/320. Exclusion criteria included previous treatment with intravitreal steroids or other anti-VEGF agents, laser photocoagulation, intraocular pressure (IOP) ≥25 mm Hg, iris neovascularization, coexisting ocular conditions affecting VA, and poor-quality spectral domain optical coherence tomography (SDOCT) scans.

2.2. Patient evaluation

At each follow up visit, best corrected visual acuity (BCVA) assessment with Snellen charts, slit lamp and dilated fundus examinations, and SDOCT (Cirrus; Carl Zeiss Meditec, Dublin, California, USA) macula scans, were performed. The participants were treated with 0.05 mL ziv-aflibercept (1.25 mg) at baseline, followed monthly, and managed on a pro re nata (PRN) protocol for at least 12 months. Retreatment criteria included recurrence or persistence of intraretinal or subretinal fluid, deterioration in VA by Snellen equivalent of 1 ETDRS line, increase in central subfield thickness (CST) by ≥ 50 μm from the previous visit or the lowest recorded CST. Fluorescein angiography was performed for all cases to detect significant ischemia requiring panretinal photocoagulation (PRP), i.e., more than 10 disc diameters of capillary non-perfusion.

The primary outcomes were changes in BCVA, CST, and total macular volume from baseline to the 12-month visit. Secondary outcomes were the number of injections received, and incidence of intraocular side effects (including cataract progression, ocular inflammation, and increase in IOP). The occurrence of systemic adverse events, including nasopharyngitis, headaches, hypertension, cardiovascular events, cerebrovascular accidents, if any, were noted.

2.3. Statistical analysis

Statistical analyses were conducted with SPSS V.22 (IBM Corporation, Chicago, Illinois, USA). Snellen VA readings were converted into logarithm of the minimum angle of resolution (logMAR) VA values. P-values were generated using paired t-tests comparing baseline and the 1-year outcomes.

3. Results

All eyes were phakic (3 with mild cataracts). Patients (4 females and 2 males) had an average age of 53.5 ± 7.23 years (range, 44–65). Three patients had systemic hypertension (50%), 4 patients had diabetes (66.7%) and only 1 patient was a smoker (16.7%). Demographic and clinical characteristics are shown in Table 1.

The mean logMAR BCVA improved by 0.53 ± 0.30 from baseline 0.86 ± 0.25 (Snellen equivalent ≈ 20/145) to 0.33 ± 0.22 (Snellen equivalent ≈ 20/40) at the 12-month visit ($p = 0.007$), equivalent to gaining +26.5 letters on the ETDRS scale. The mean CST decreased from 519 ± 137 μm at baseline to 255 ± 27 μm at 12 months ($p = 0.008$). Similarly, the total macular volume decreased from 14.7 ± 3.9 mm^3 at baseline to 7.1 ± 0.8 mm^3 at 12 months ($p = 0.007$). During this period, study participants received an average of 6.2 ± 1.2 injections (range 5–8 injections). IOP remained stable between baseline (18.3 mmHg) and 12-month visits (17.5 mmHg) ($p = 0.55$) (Table 2). No eyes had significant capillary non-perfusion requiring PRP. Structural response to ziv-aflibercept treatment is illustrated in Fig. 1.

No signs of intraocular inflammation, cataract progression, or systemic side effects were detected or reported by patients at all follow-up visits.

4. Discussion

Ziv-aflibercept achieves promising structural and VA outcomes at 1 year in treatment-naïve CRVO-associated macular edema, comparable to that obtained with fixed-dosing regimens of anti-VEGF agents. In this series, 1.25 mg of ziv-aflibercept dosed PRN achieved a mean VA gain of +26.5 letters and a CST decrease of 264 ± 151 μm over a treatment interval of 12 months. No safety concerns were raised in this pilot study. In the COPERNICUS and GALILEO trials involving fixed monthly injections of aflibercept in CRVO, 2 mg of aflibercept achieved an

Samsung Bioepis Exhibit 1044
Page 2

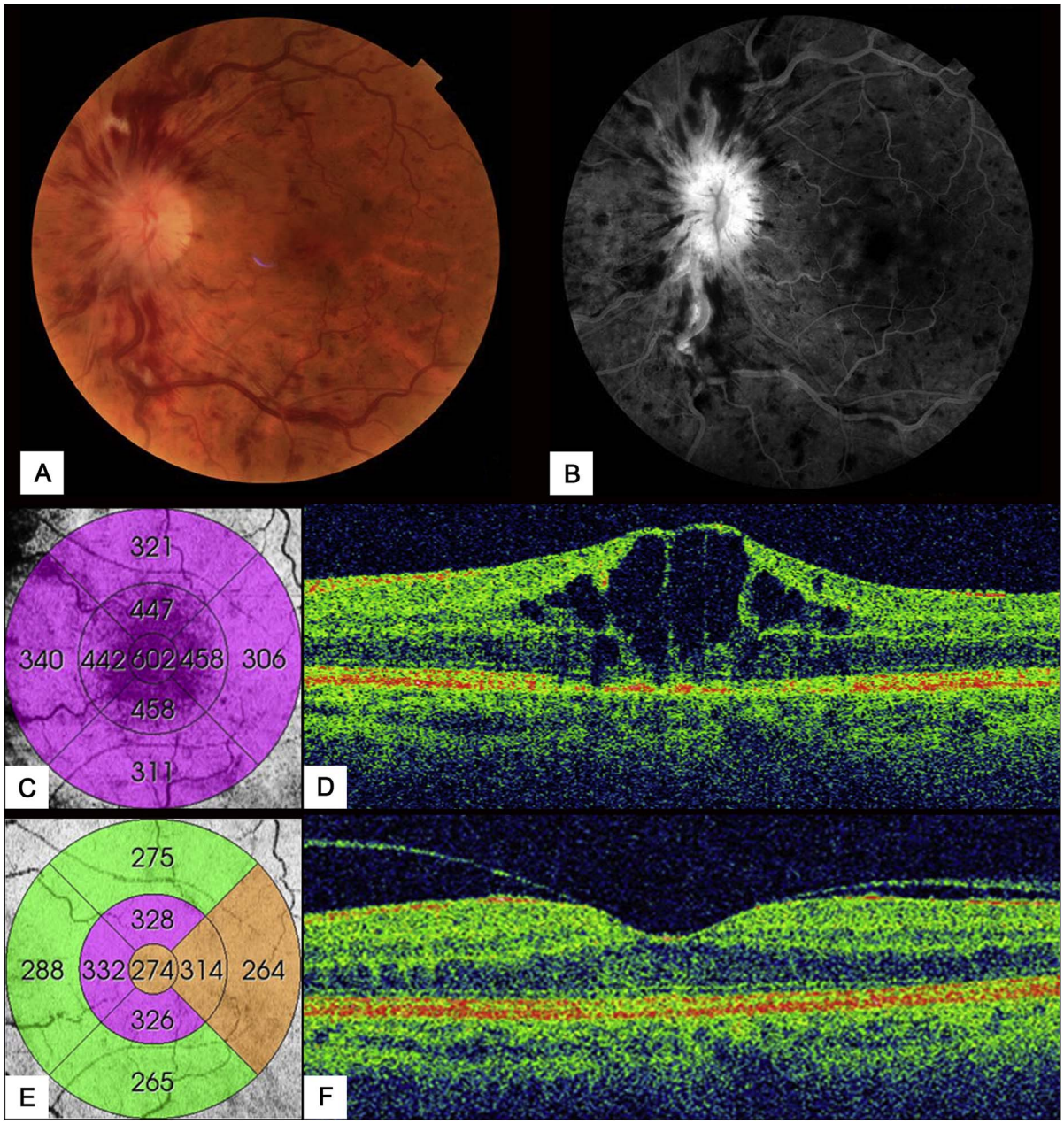

Fig. 1. A, Baseline fundus photography of the left eye of a 56-year-old female (patient #3) shows flame-shaped hemorrhages in the distribution of the central retinal vein and its tributaries, indicating a diagnosis of central retinal vein occlusion. **B,** Late-phase fluorescein angiography at 2 months after presentation revealed macular ischemia, in addition to other non-foveal areas of retinal ischemia. The "petalloid" of chronic cystoid macular edema was not observed. **C-D,** At baseline, visual acuity (VA) was 20/100. Spectral domain optical coherence tomography showed macular edema with central subfield thickness (CST) of 602 μm. The first intravitreal ziv-aflibercept was administered at this visit. **E-F,** At 12 months, macular edema had resolved, CST was 274 μm, and VA improved to 20/30. The patient received a total of 5 injections over the course of the 12 months.

average of +17.8 and + 18 letters gained, respectively. These trials achieved mean CST reductions from baseline to 12 months of 457.2 μm and 448.6 μm, respectively.[8,9] Caution should be applied in these comparisons, as our study involved a small sample of only 6 patients. However, the younger age profile and earlier presentation could explain the better VA gains in our population.

The patients in our series did not develop any adverse ocular effects of increased inflammation or IOP. Initial ocular safety concerns arose based on in-vitro studies showing mitochondrial toxicity on human retinal pigment epithelial (RPE) cells with ziv-aflibercept and bevacizumab, but not for aflibercept and ranibizumab.[13] No further studies were conducted using electro-oculogram on eyes injected with ziv-aflibercept, so its effect on the RPE in vivo remains unknown. Additionally, electroretinogram (ERG) analysis in a small group of patients with wet age-related macular degeneration (AMD) and diabetic macular edema (DME) demonstrated no alterations through 6 months of ziv-aflibercept therapy.[14–16] No ERG changes were reported in a single case of BRVO treated with ziv-aflibercept for 3 months.[11] A second concern arose owing to an osmolality difference between the different buffers used. Ziv-aflibercept has an osmolality of 1000 mOsm/kg (hyperosmotic due to the addition of sucrose), while aflibercept has an osmolality of 300 mOsm/kg (isosmotic to vitreous fluid). However, it is estimated that a 0.05 mL aliquot injection of 1000 mOsm/kg ziv-aflibercept would modestly increase vitreous cavity osmolality by only 4%, thus still registering within normal physiological limits.[13,17]

Our study also provides support for the intermediate-term systemic safety of ziv-aflibercept in CRVO. Short-term systemic safety has been documented by the absence of systemic effects in patients with wet

Samsung Bioepis Exhibit 1044
Page 3

AMD, DME, and BRVO.[11,14–16] Of note, no systemic safety issues with aflibercept in CRVO have been raised in the COPERNICUS and G-ALILEO trials to date. This is despite pharmacokinetic studies after a single aflibercept injection showing higher circulating systemic levels of aflibercept, which were 5-fold (peak level), 37-fold (trough level) and 9-fold higher (area under the curve) than ranibizumab.[18] Aflibercept was also found to suppress circulating plasma-free VEGF, with mean levels below the lower limit of quantitation from 3 h after administration, and lasting ≥7 days.[18] Studies with a longer follow-up interval in a larger patient cohort is indicated to further establish the systemic safety of ziv-aflibercept.

The compounded ziv-aflibercept drug appeared to be stable for 4 weeks as indirectly demonstrated by good clinical response in this series. VEGF assays also demonstrated no loss of VEGF blockade with use of ziv-aflibercept which had been stored for 1 month.[17]

Bevacizumab is currently the most cost-effective treatment for macular edema secondary to CRVO. Likewise, the low cost of ziv-aflibercept would likely make it an attractive option in resource-poor countries. The actual compounded cost is approximately 30 times less for ziv-aflibercept than for aflibercept. Thus, if the 4 mL ziv-aflibercept vial is divided into 40 aliquots of 0.05 mL (1.25 mg of ziv-aflibercept), the approximate cost of each aliquot would be US $25, which is significantly lower than a single Eylea® vial costing US $700 in Lebanon. Extrapolated over the course of multiple injections in CRVO, this would translate into considerable monetary savings.

Limitations of this study include the small sample size and one-armed open label design. No electrophysiologic information was available to ascertain local toxicity. Despite this, our study provides satisfactory initial data on the intermediate-term efficacy and safety of PRN ziv-aflibercept in eyes with macular edema due to CRVO.

5. Conclusion

Off-label use of PRN ziv-aflibercept over a 12-month period demonstrates good structural and functional outcomes for macular edema secondary to CRVO, without evident ocular or systemic adverse events. Low-cost ziv-aflibercept may potentially be a viable substitute for aflibercept, particularly in countries where aflibercept is unavailable, and in resource-poor regions. Larger studies are warranted to confirm our findings.

Patient consent

Informed consent was obtained in writing from the patients before enrollment in the study and for publishing the results.

Funding

No funding or grant support.

Conflict of interest

The following authors have no financial disclosures: (ME, EC, CD, AM, JC).

Authorship

All authors attest that they meet the current ICMJE criteria for Authorship.

Acknowledgements

None.

References

1. Rogers S, McIntosh RL, Cheung N, et al. The prevalence of retinal vein occlusion: pooled data from population studies from the United States, Europe, Asia, and Australia. *Ophthalmology.* 2010;117(2):313–319.
2. Campochiaro PA, Bhisitkul RB, Shapiro H, Rubio RG. Vascular endothelial growth factor promotes progressive retinal nonperfusion in patients with retinal vein occlusion. *Ophthalmology.* 2013;120(4):795–802.
3. Jaulim A, Ahmed B, Khanam T, Chatziralli IP. Branch retinal vein occlusion: epidemiology, pathogenesis, risk factors, clinical features, diagnosis, and complications. An update of the literature. *Retina.* 2013;33(5):901–910.
4. Noma H, Funatsu H, Mimura T, Eguchi S, Hori S. Soluble vascular endothelial growth factor 280 receptor-2 and inflammatory factors in macular edema with branch retinal vein occlusion. *Am J Ophthalmol.* 2011;152(4):669–677.
5. McIntosh RL, Rogers SL, Lim L, et al. Natural history of central retinal vein occlusion: an evidence-based systematic review. *Ophthalmology.* 2010;117(6):1113–1123.
6. Ip MS, Scott IU, VanVeldhuisen PC, et al. A randomized trial comparing the efficacy and safety of intravitreal triamcinolone with observation to treat vision loss associated with macular edema secondary to central retinal vein occlusion: the standard care vs corticosteroid for retinal vein occlusion (SCORE) study report 5. *Arch Ophthalmol.* 2009;127(9):1101–1114.
7. Haller JA, Bandello F, Belfort Jr R, et al. Randomized, sham controlled trial of dexamethasone intravitreal implant in patients with macular edema due to retinal vein occlusion. *Ophthalmology.* 2010;117(6):1134–1146.
8. Heier JS, Clark WL, Boyer DS, et al. Intravitreal aflibercept injection for macular edema due to central retinal vein occlusion: two-year results from the COPERNICUS study. *Ophthalmology.* 2014;121(7):1414–1420.
9. Korobelnik JF, Holz FG, Roider J, et al. Intravitreal aflibercept injection for macular edema resulting from central retinal vein occlusion: one-year results of the phase 3 GALILEO study. *Ophthalmology.* 2014;121(1):202–208.
10. Chung C, Pherwani N. Ziv-aflibercept: a novel angiogenesis inhibitor for the treatment of metastatic colorectal cancer. *Am J Health Syst Pharm.* 2013;70(21):1887–1896.
11. Andrade GC, Dias JR, Maia A, et al. Intravitreal injections of ziv-aflibercept for the treatment of a patient with macular edema secondary to branch retinal vein occlusion. Retin Cases Brief Rep. doi: 10.1097/ICB.0000000000000449.
12. Paulose R, Chhablani J, Dedhia CJ, et al. Intravitreal ziv-aflibercept for macular edema following retinal vein occlusion. *Clin Ophthalmol.* 2016;22(10):1853–1858.
13. Malik D, Tarek M, Caceres del Carpio J, et al. Safety profiles of anti-VEGF drugs: bevacizumab, ranibizumab, aflibercept and ziv-aflibercept on human retinal pigment epithelium cells in culture. Br J Ophthalmol. doi: 10.1136/bjophthalmol-2014-305302.
14. de Oliveira Dias JR, de Andrade GC, Kniggendorf VF et al. Clinical and electrophysiological evaluation after intravitreal ziv-aflibercept for exudative age-related macular degeneration. Retina. doi:10.1097/IAE.0000000000001385.
15. Andrade GC, Dias JR, Maia A, et al. Intravitreal injections of ziv-aflibercept for diabetic macular edema: a pilot study. *Retina.* 2016;36(9):1640–1645.
16. Chhablani J, Narayanan R, Mathai A, et al. Short-term safety profile of intravitreal ziv-aflibercept. *Retina.* 2016;36(6):1126–1131.
17. Mansour AM, Al-Ghadban SI, Yunis MH, El-Sabban ME. Ziv-aflibercept in macular disease. *Br J Ophthalmol.* 2015;99(8):1055–1059.
18. Avery RL, Castellarin AA, Steinle NC, et al. Systemic pharmacokinetics following intravitreal injections of ranibizumab, bevacizumab or aflibercept in patients with neovascular AMD. *Br J Ophthalmol.* 2014;98(12):1636–1641.

Samsung Bioepis Exhibit 1044
Page 4