Maximum Tolerated Dose of a Humanized Anti–Vascular Endothelial Growth Factor Antibody Fragment for Treating Neovascular Age-Related Macular Degeneration

Philip J. Rosenfeld, MD, PhD,[1] Steven D. Schwartz, MD,[2] Mark S. Blumenkranz, MD,[3] Joan W. Miller, MD,[4] Julia A. Haller, MD,[5] James D. Reimann, PhD,[6] William L. Greene, MD,[6] Naveed Shams, MD, PhD[6]

Purpose: To investigate the maximum tolerated dose of ranibizumab administered as a single intravitreal injection.

Design: Open-label, 5-center, uncontrolled, prospective, dose-ranging, interventional case series.

Participants: Twenty-seven patients with subfoveal choroidal neovascularization (CNV) secondary to age-related macular degeneration (AMD) with best-corrected Snellen equivalent visual acuity (VA) of 20/100 or worse and considered ineligible for laser photocoagulation or photodynamic therapy.

Methods: A single intravitreal injection of ranibizumab was to be administered at 1 of 6 escalating doses (50, 150, 300, 500, 1000, and 2000 μg), with escalation to the next dose level occurring only after the safety and tolerability of the lower dose level was established through postinjection day 14. Follow-up examinations were performed on postinjection days 1, 3, 7, 14, 42, and 90. Enrollment was stopped if $\geq$2 patients experienced dose-limiting toxicity.

Main Outcome Measures: The primary safety measures were changes from baseline in VA, intraocular pressure (IOP), intraocular inflammation, and production of antiranibizumab antibody. Dose-limiting toxicity was defined by intraocular inflammation, elevated IOP, reduced VA, or hemorrhage within 90 days after injection.

Results: All patients completed this single intravitreal injection study, and 500 μg of ranibizumab was the maximum tolerated dose. At the higher dose of 1000 μg, significant intraocular inflammation was noted. All adverse events were self-limited, and no infectious endophthalmitis occurred. Aqueous or vitreous ocular inflammation occurred in 12 subjects, with complete resolution within 42 days. In 9 of the subjects, the inflammation was graded as trace to 1+ and required no treatment; in 3 of the subjects, the inflammation was graded as 2+ or 3+, and 2 of the 3 were treated with topical 1% prednisolone acetate. No serum antiranibizumab antibodies were detected. All patients had VA similar or improved compared with baseline values.

Conclusion: The maximum tolerated single dose of ranibizumab in neovascular AMD patients was 500 μg. Single intravitreal injections of ranibizumab up to a dose of 500 μg were safe and well tolerated in this small group of patients. *Ophthalmology 2005;112:1048–1053 © 2005 by the American Academy of Ophthalmology.*

Originally received: July 1, 2004.
Accepted: January 10, 2005. Manuscript no. 240525.

[1] Department of Ophthalmology, Bascom Palmer Eye Institute, University of Miami, Miami, Florida.

[2] Department of Ophthalmology, Jules Stein Eye Institute, UCLA, Los Angeles, California.

[3] Department of Ophthalmology, Stanford University School of Medicine, Stanford, California.

[4] Department of Ophthalmology, Massachusetts Eye and Ear Infirmary, Harvard Medical School, Boston, Massachusetts.

[5] Wilmer Ophthalmological Institute, Johns Hopkins University, Baltimore, Maryland.

[6] Genentech, Inc., South San Francisco, California.

The phase I Ranibizumab Study Group's principal investigators and clinical sites are Drs Rosenfeld, Schwartz, Blumenkranz, Miller, and Haller and their respective affiliations.

Presented in part at: Association for Research in Vision and Ophthalmology annual meeting, May, 2001; Fort Lauderdale, Florida; Vitreous Society annual meeting, November, 2001; Fajardo, Puerto Rico; and the 4th International Symposium on Ocular Pharmacology and Pharmaceutics, March, 2002; Seville, Spain.

This study was supported financially by Genentech, Inc., South San Francisco, California.

Drs Rosenfeld, Schwartz, Blumenkranz, Miller, and Haller have received clinical research grants from Genentech, Inc. to perform this study; have indicated support for scientific presentations at meetings and reimbursement for travel expenses from Genentech or competing companies; and have participated in scientific advisory boards to and received honoraria and reimbursement for travel expenses from Genentech, Inc. or competing companies. Drs Reimann, Greene, and Shams are current or former employees of Genentech, Inc. Full financial disclosures have been submitted to the *Ophthalmology* editorial office.

Correspondence to Philip J. Rosenfeld, MD, PhD, Bascom Palmer Eye Institute, Department of Ophthalmology, University of Miami School of Medicine, 900 NW 17th Street, Miami, FL 33136. E-mail: prosenfeld@med.miami.edu.

© 2005 by the American Academy of Ophthalmology
Published by Elsevier Inc.

ISSN 0161-6420/05/$–see front matter
doi:10.1016/j.ophtha.2005.01.043

Regeneron Ex. 2022
Samsung v. Regeneron
IPR2025-00176
Page 1 of 10

Age-related macular degeneration (AMD) is the leading cause of irreversible severe vision loss among the elderly in North America and Europe.[1–3] Most of the severe vision loss results from the neovascular or exudative form of AMD.[4] Neovascularization in AMD is referred to as choroidal neovascularization (CNV) because it primarily arises from the choroidal circulation under the macula, and the term *retinal angiomatous proliferation* is used to refer to a variant of CNV with a component of neovascularization within the retina.[5] Initially, the vision loss attributable to neovascularization in AMD is thought to be due to the leakage of blood and serum components under the retina (subretinal fluid), into the retina (macular edema), and under the retinal pigment epithelium (RPE detachment).[6] This type of vision loss from fluid accumulation is potentially reversible. Eventually, the progression of AMD and the accumulation of serous fluid and blood from neovascularization result in the loss of photoreceptors and RPE, the formation of a disciform scar, and permanent vision loss. To date, results of controlled clinical trials have led to only 2 recommended options for the treatment of subfoveal CNV in AMD: thermal laser photocoagulation and photodynamic therapy.[7–12] Neither of these options is effective for all patients with neovascular AMD, and improved or even stabilized visual acuity (VA) is achieved uncommonly, even with treatment.

Ocular neovascularization and increased vascular permeability have been associated with vascular endothelial growth factor (VEGF), a diffusible, secreted protein that is central to the sequence of events leading to vascular leakage and angiogenesis.[13,14] Animal studies have shown that VEGF expression is sufficient to induce neovascularization in the eye,[15–17] whereas inhibition reduces this effect.[18] Moreover, the presence of VEGF is temporally and spatially correlated with ocular angiogenesis in the primate model.[19] Patients with ocular neovascularization secondary to proliferative diabetic retinopathy have elevated vitreous levels of VEGF,[20,21] and elevated levels of VEGF have been detected within CNV.[22,23]

One possible strategy for treating retinal neovascularization, CNV, and macular edema is to inhibit VEGF activity by competitively binding VEGF with a specific neutralizing anti-VEGF antibody. One such molecule, ranibizumab, is a novel humanized anti-VEGF antibody fragment produced by recombinant antibody production techniques. Ranibizumab is derived from bevacizumab, a full-length humanized monoclonal antibody against human VEGF currently being studied for the treatment of several solid organ tumors[24–26] and approved in the United States for use in combination with 5-fluorouracil–based chemotherapy in treatment of metastatic colorectal cancer.

Because most of the neovascularization in AMD occurs under the retina or within the retina, the antibody fragment has an advantage over a full-length antibody when both are injected into the vitreous cavity. The smaller fragment can penetrate through all layers of the retina, whereas the full-length antibody penetrates only into the inner retinal layers.[27] Thus, the antibody fragment has greater therapeutic potential. Preclinical studies in animal models have demonstrated the safety, tolerability, and biological activity of ranibizumab. In a monkey model, pretreatment of eyes with intravitreal ranibizumab prevented development of laser-induced CNV, and ranibizumab treatment of established experimental CNV reduced vascular leakage.[28]

This study was designed primarily to evaluate the safety, tolerability, and maximum tolerated dose of a single intravitreal injection of ranibizumab, the anti-VEGF antibody fragment, in patients with neovascular AMD.

Patients and Methods

This was a prospective, open-label, uncontrolled, multicenter, phase 1 study designed to investigate the safety and tolerability of 6 escalating doses of ranibizumab (50, 150, 300, 500, 1000, and 2000 μg) administered as a single intravitreal injection in patients with primary or recurrent CNV secondary to AMD. The study protocol was reviewed and approved by the institutional review boards of the 5 participating centers. All subjects provided written informed consent. The study was completed before implementation of the Health Insurance Portability and Accountability Act of 1996.

Patients were enrolled at 5 university-affiliated clinical centers from February 2000 through January 2001. The principal eligibility criteria are listed in Table 1. Because of lesion size and/or lesion type, these patients were not eligible for laser photocoagulation, based on the Macular Photocoagulation Study criteria, and also were not eligible for photodynamic therapy. All entry examinations and testing were performed within 14 days of treatment. The protocol called for the enrollment of 6 patients per dose group, with enrollment in each escalating dose group only if there was no evidence of any dose-limiting toxicity at the lower doses (Table 2). The enrollment was stopped if ≥2 patients within a dose group experienced dose-limiting toxicity within 14 days after ranibizumab injection. No more than 2 patients could be enrolled into the study on any day, and no more than 3 patients could be enrolled into the study per week.

The study was divided into a 14-day screening period, a 1-day treatment period, and a 90-day follow-up period. On day 0, eligible patients received an intravitreal injection of ranibizumab (Lucentis [formerly rhuFab V2], Genentech, Inc., South San Francisco, CA). Ranibizumab was supplied as a lyophilized powder requiring reconstitution and dilution with sterile water before intravitreal injection. Local lidocaine anesthetic and antimicrobial agents were applied to the study eye before treatment using preparatory methods that were the standard of care at the participating sites. A retinal specialist, using a 30-gauge 0.5-inch needle attached to a 1-ml tuberculin syringe, injected a total of 0.05 ml (50 μl) of ranibizumab solution through the pars plana. Follow-up examinations were performed on postinjection days 1, 3, 7, 14, 42, and 90.

The primary outcome measurements focused on the safety and tolerability of ranibizumab and the injection procedure. Safety was assessed by measuring the following parameters after each injection: light perception was measured at 5 and 30 minutes; intraocular pressure (IOP) was measured at 30 minutes; and if the IOP was ≥10 mmHg higher than the preinjection IOP, then another measurement was taken at 60 minutes. Visual acuity was assessed using a standardized 2-m refraction protocol with the Early Treatment Diabetic Retinopathy Study chart on postinjection days 1, 3, 7, 14, 42, and 90; ocular inflammation was assessed using a slit-lamp examination and dilated ophthalmoscopy on postinjection days 1, 3, 7, 14, 42, and 90 (Table 3 [available at http://aaojournal.org]).[29] Ocular and nonocular adverse events were assessed during the follow-up period by obtaining medical histories, with a review of concomitant medications and physical examina-

Regeneron Ex. 2022
Samsung v. Regeneron
IPR2025-00176
Page 2 of 10

Table 1. Principal Inclusion and Exclusion Criteria

Inclusion criteria
Clinical signs and angiographic evidence of primary or recurrent subfoveal CNV
Not eligible for laser photocoagulation or photodynamic therapy, based on lesion size and lesion type
Fluorescein angiography performed within 7 days of study drug administration
Best-corrected visual acuity of 20/100 or worse in study eye*
Age ≥50 yrs
Exclusion criteria
Presence of ocular conditions other than AMD (e.g., diabetic retinopathy or any grade of ocular inflammation)
Cataract surgery within 3 mos of enrollment
Verteporfin (Visudyne, Novartis AG, Basel, Switzerland) therapy within 1 mo of enrollment in the study eye or 7 days in the fellow eye
Previous submacular surgery or external beam radiation therapy
Enrollment in another investigational drug study within 3 mos of study entry
Use of anticoagulants or antiplatelet therapy other than aspirin/NSAIDs within 14 days of enrollment
Presence of a nonhealing wound, ulcer, fracture, or any medical condition associated with bleeding
Use of antimitotic or antimetabolite therapy within 30 days or 5 elimination half-lives of enrollment
Premenopausal women
History of fluorescein allergy
Any medical/physical/laboratory/metabolic disorder that contraindicated the use of an investigational drug
Inability to comply with the study protocol or follow-up procedures

AMD = age-related macular degeneration; CNV = choroidal neovascularization; NSAIDs = nonsteroidal antiinflammatory drugs.
*Visual acuity was determined using a standardized Early Treatment Diabetic Retinopathy Study refraction protocol, and Snellen equivalent visual acuity was used as the inclusion criterion.

tions with vital signs, hematological profiles, and urinalyses. Serum antiranibizumab antibody levels were measured on postinjection days 14, 42, and 90 by enzyme-linked immunosorbent assay at Genentech, Inc.

Secondary outcome measurements included the change in fluorescein angiographic characteristics of CNV. Fluorescein angiography was performed at baseline and on postinjection days 7 and 90 to assess CNV. Lesion size and characteristics of CNV were assessed initially by the study investigator and retrospectively by the Fundus Photograph Reading Center of the University of Wisconsin. *Lesion* refers to the area encompassing all lesion components such as CNV (classic, occult, or combined), blood, hypofluorescence not from visible blood, serous detachment of the RPE, and hyperfluorescent staining from fibrous tissue.

Results

Twenty-seven patients enrolled in the study. Enrollment was stopped after the first 2 patients in the 1000-μg group experienced dose-limiting toxicity. The baseline demographic characteristics for the 27 patients are shown in Table 4 (available at http://aaojournal.org). Most patients were Caucasian (96%), and more than half were female (56%). The mean age was 78 years. Baseline assessment of study-eye characteristics indicated that 67% of patients had primary CNV, and the median baseline VA was 20/250 (approximate Snellen equivalent). The CNV lesions were classified as predominantly classic (15% of patients), mixed classic and occult CNV (56%), and occult with no classic component (30%). With the exception of a single subject with a juxtafoveal lesion, all CNV lesions were subfoveal. Neovascular AMD was present in the fellow eye in 59% of patients. To ensure consistent evaluation, the fundus photographs and fluorescein angiograms were retrospectively reviewed at a central reading facility, the Wisconsin Fundus Photograph Reading Center. With respect to baseline characteristics, all enrolled subjects were determined by the investigator to have active CNV at screening. The reading center was unable to confirm the presence of CNV in 2 cases.

Safety and Adverse Events

No patient withdrew from the study, and there were no important protocol deviations. Ranibizumab was well tolerated up to a maximum single dose of 500 μg. Most adverse events were related to the injection procedure and not related to the study drug (Table 5 [available at http://aaojournal.org]), with 78% of patients experiencing subconjunctival hemorrhaging, conjunctival edema, or

Table 2. Definitions of Dose-Limiting Toxicity within 14 Days of Injection*

- A change in ocular inflammation of 2 units on a standard grading scale, as assessed on days 1, 3, 7, and 14†
- Sustained elevation of intraocular pressure characterized by an increase of 10 mmHg over baseline value for greater than 30 min
- Acute marked reduction in visual acuity unrelated to inflammatory reactions, defined as any of the following:
  - At least a 5-line (25-letter) decrease, as assessed on postinjection days 1, 3, 7, and 14
  - At least a 4-line (20-letter) decrease within the first 7 days after injection that is still present at the next scheduled visit
  - At least a 3-line (15-letter) decrease within the first 7 days that persists until day 14
- Vitreous hemorrhage of grade 2 or worse according to a hemorrhage density grading scale
- Major systemic hemorrhage, such as an intracranial hemorrhage or other clinically significant hemorrhages
- Other serious adverse event that, in the opinion of the investigator, is related to the study drug

*Patients were evaluated on postinjection days 1, 3, 7, and 14.
†Use of topical corticosteroids for the treatment of intraocular inflammation was left to the discretion of the investigator.

Regeneron Ex. 2022
Samsung v. Regeneron
IPR2025-00176
Page 3 of 10

Table 6. Ocular Inflammation Events

Dose Group	Maximum Aqueous Grade	Duration of Aqueous Cell/Flare	Maximum Vitreous Grade	Duration of Vitreous Cell/Haze
150 μg	None	0	1+ cell	Day 42 only
300 μg	None	0	2-3+ cell*†	Days 7–14
	None	0	1+ cell	Day 14 only
	1+ cell	Days 1–3	1+ cell	Days 1–42
	Trace cell	Day 1 only	None	0
500 μg	1+ cell/flare	Days 1–3	None	0
	Trace cell	Days 1–3	None	0
	1+ cell	Day 1 only	1+ cell	Day 1 only
	None	0	Minimal cell	Day 7 only
	Trace cell	Day 1 only	1+ floaters	Days 3–7
1000 μg	2+ cell*‡	Days 1–7	3+ cell/floaters*‡	Days 3–14
	2+ cell*	Day 3 only	2+ cell*	Days 3–14

*These patients had dose-limiting inflammation, defined as a change in ocular inflammation of ≥2 units on a scale of 0 to 4+.
†Patient was treated with 1 drop of topical 1% prednisolone acetate 4 times a day beginning on day 8 after injection and continuing through day 15.
‡Patient was treated with 1 drop of topical 1% prednisolone acetate every hour beginning on day 2 after injection and continuing through day 3, then 3 times a day through day 8, and then 2 times a day through day 85.

pain. In all but 1 of these patients the sign or symptom was rated as mild, and all events were self-limited.

Ocular inflammation related to intravitreal injection of the study drug was reported in 12 patients (44%) and is summarized in Table 6. This inflammation was generally asymptomatic and graded as trace to 1+ in 75% of the events, and did not require further treatment. Three patients experienced clinically significant (grades 2–3+) ocular inflammation. One patient in the 300-μg group exhibited significant vitreous cell; the inflammation resolved during topical corticosteroid therapy (Table 6). Two patients in the 1000-μg group also experienced significant ocular inflammation. In 1 patient, 2+ aqueous cell and vitreous cell resolved without treatment and with no loss of VA (Table 6). In the second patient, 2+ aqueous cell and significant vitreous inflammation were associated with a transient 8-line (40 letters) reduction in VA, which resolved (Table 6). At the discretion of the investigator, this latter patient received a course of topical corticosteroids. According to the study protocol, these 2 cases of ocular inflammation within the 1000-μg dose group represented dose-limiting toxicity. Consequently, the maximum tolerated dose in this single-injection setting was determined to be 500 μg.

Other self-limited ocular adverse events reported that were probably related to the ranibizumab injection were 7 cases of transient abnormal vision, 3 of mild eye pain, and 1 of severe eye pain, and 1 case of clinically significant IOP elevation (another case of clinically significant IOP elevation occurred, but was not reported by the investigator as an adverse event). The average IOP immediately before ranibizumab injection was 16.3 mmHg, with a mean increase of 2.2 mmHg at 30 minutes after the injection (range, −4 to 10 mmHg). The average IOP was slightly below baseline levels at 24 hours. Of the 27 subjects who received intravitreal administration of ranibizumab, 2 had IOP elevations of ≥10 mmHg in the study, as described below. Measurements of IOP were confounded by anterior chamber paracentesis in 9 subjects at a single study center.

With respect to VA, an intravitreal injection of ranibizumab seemed safe, as measured by the change in letters identified on the Early Treatment Diabetic Retinopathy Study eye chart. Changes in study-eye VA are summarized in Table 7 (available at http://aaojournal.org) and Figure 1. At the end of the study, mean VA scores were similar to those at baseline, with an increase of 7 letters in the study eyes and 2.5 letters in the fellow eyes. In 3 patients (11%), 1 each from the 300-, 500-, and 1000-μg dose groups, the study eye exhibited a transient decline in VA of at least 15 letters, which reached a nadir by postinjection day 3. All 3 cases were associated with ocular inflammation. The time course of the inflammation correlated with the decreased vision. Visual acuity returned to near-baseline levels for all 3 patients by day 14.

Direct ophthalmoscopy and fundus imaging demonstrated no significant changes in neovascular lesions during the study. The majority of patients exhibited no significant change in the area of CNV or total lesion as determined by fluorescein angiography (Table 8 [available at http://aaojournal.org]). In 74% of patients, lesion size was unchanged or decreased, whereas in 26% the lesion size increased at least 0.3 disc areas. Similarly, the area of CNV was either unchanged or decreased in 73% of patients, but was increased in 27%.

Twenty-six nonocular adverse events were noted, but none was considered related to the study drug. Two patients experienced major nonocular events: a diagnosis of cholangiocarcinoma and a case of recurrent bladder and prostate cancer. Minor nonocular adverse events included a transient ischemic cerebral event, muscle weakness, and 2 episodes of presumed fluorescein contact dermatitis.

There were no substantial changes in any of the laboratory test results (blood chemistry, hematology, and urinalysis) and no changes in vital signs or physical examination findings during the study. Light perception remained normal at 5 and 30 minutes after each injection, and no patient developed an abnormal pupillary response. No serum antibodies to ranibizumab were detected after treatment.

Discussion

In this study, ranibizumab, a fragment of a genetically engineered humanized monoclonal antibody against human VEGF, was well tolerated when administered by intravitreal injection at doses of 50 to 500 μg in a volume of 50 μl (0.05 ml). Overall, the most common adverse events were subconjunctival hemorrhage at the injection site (20/27 patients [74%]) and transient, sterile intraocular inflammation (12/27 patients [44%]).

The cause of the inflammatory response after intravitreal injection of ranibizumab is unknown. Although the inflammation may be a nonspecific response associated with an intravitreal injection, there seems to be at least some com-

Regeneron Ex. 2022
Samsung v. Regeneron
IPR2025-00176
Page 4 of 10

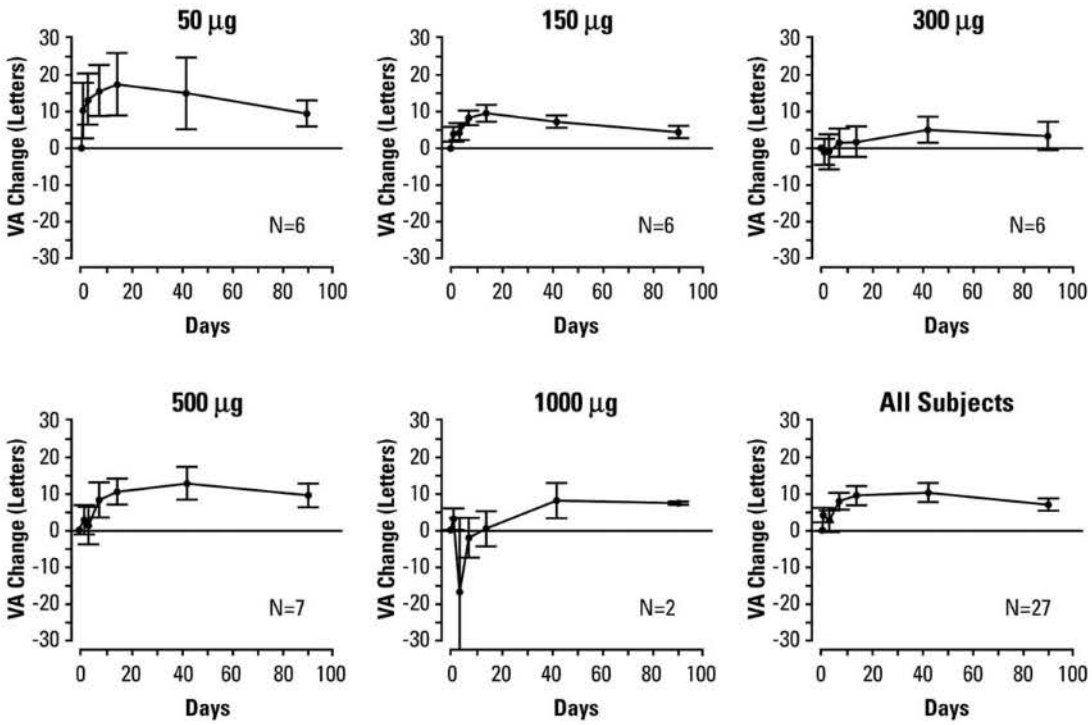

Figure 1. Profile of the mean visual acuity (VA) changes for each dose group after a single intravitreal injection of ranibizumab through day 90. The vertical bars at each visit represent the standard error of the mean.

ponent related to the drug, because the severity of inflammation seemed to increase as the dose increased. This observation is similar to those in animal studies, in which the severity of inflammatory responses was clearly dose related (Genentech, unpublished data).[28] Because this was a single-dose study, it remains to be seen whether the inflammatory response will be attenuated with repeated dosing, as in the animal studies, or whether the inflammatory response worsens with repeated dosing.

The inflammatory response after a single dose was well tolerated and self-limited. At the day 90 follow-up visit, intraocular inflammation persisted in only 1 patient (1000-μg group); this inflammation was mild and required no treatment. Infectious endophthalmitis was not diagnosed in this study. None of the patients underwent anterior chamber or vitreous sampling for microbiological cultures, nor did they receive any intravitreal injections of antibiotics. Two patients received topical steroid drops after developing inflammation, but it is unclear whether this helped to resolve the inflammation. In animal studies, it seemed that neither systemic nor topical steroids significantly affected the duration or extent of the inflammation (data not shown).

A low number of systemic adverse events was observed, and none (with the exception of cerebral ischemia) was suggestive of an anti-VEGF effect. This may be attributed, in part, to the very minute quantities of the drug (50–1000 μg) injected into the vitreous and, therefore, the extremely low amounts of drug reaching the systemic circulation, combined with rapid clearance of the drug.

In conclusion, a single intravitreal injection of ranibizumab seems safe and well tolerated, with a maximum tolerated single dose of 500 μg in a volume of 50 μl. Dose-limiting toxicity in this single-dose study was identified at the 1000-μg dose and was characterized by ocular inflammation involving both the anterior chamber and vitreous cavity.

Acknowledgments. The authors acknowledge the contribution of Diane C. Davies, RN (Genentech, Inc.), who served as study coordinator, and Edward R. McCluskey, MD, PhD (Genentech, Inc.), who helped write early drafts.

References

1. Klein R. Epidemiology. In: Berger JW, Fine SL, Maguire MG, eds. Age-Related Macular Degeneration. St. Louis: Mosby; 1999:31–55.
2. Age-Related Eye Disease Study Research Group. Potential public health impact of Age-Related Eye Disease Study results: AREDS report no. 11. Arch Ophthalmol 2003;121: 1621–4.
3. Eye Diseases Prevalence Research Group. Prevalence of age-related macular degeneration in the United States. Arch Ophthalmol 2004;122:564–72.
4. Ferris FL III, Fine SL, Hyman L. Age-related macular degeneration and blindness due to neovascular maculopathy. Arch Ophthalmol 1984;102:1640–2.
5. Yannuzzi LA, Negrao S, Iida T, et al. Retinal angiomatous proliferation in age-related macular degeneration. Retina 2001;21:416–34.
6. Ting TD, Oh M, Cox TA, et al. Decreased visual acuity associated with cystoid macular edema in neovascular age-related macular degeneration. Arch Ophthalmol 2002;120: 731–7.

Regeneron Ex. 2022
Samsung v. Regeneron
IPR2025-00176
Page 5 of 10

7. Macular Photocoagulation Study Group. Laser photocoagulation of subfoveal neovascular lesions of age-related macular degeneration. Updated findings from two clinical trials. Arch Ophthalmol 1993;111:1200–9.
8. Macular Photocoagulation Study Group. Persistent and recurrent neovascularization after laser photocoagulation for subfoveal choroidal neovascularization of age-related macular degeneration. Arch Ophthalmol 1994;112:489–99.
9. Macular Photocoagulation Study Group. Visual outcome after laser photocoagulation for subfoveal choroidal neovascularization secondary to age-related macular degeneration. The influence of initial lesion size and initial visual acuity. Arch Ophthalmol 1994;112:480–8.
10. Treatment of Age-Related Macular Degeneration with Photodynamic Therapy (TAP) Study Group. Photodynamic therapy of subfoveal choroidal neovascularization in age-related macular degeneration with verteporfin: one-year results of 2 randomized clinical trials—TAP report. Arch Ophthalmol 1999; 117:1329–45.
11. Verteporfin in Photodynamic Therapy Study Group. Verteporfin therapy of subfoveal choroidal neovascularization in age-related macular degeneration: two-year results of a randomized clinical trial including lesions with occult with no classic choroidal neovascularization—Verteporfin in Photodynamic Therapy report 2. Am J Ophthalmol 2001;131:541–60.
12. Treatment of Age-Related Macular Degeneration with Photodynamic Therapy (TAP) Study Group. Photodynamic therapy of subfoveal choroidal neovascularization in age-related macular degeneration with verteporfin: two-year results of 2 randomized clinical trials—TAP report 2. Arch Ophthalmol 2001;119:198–207.
13. Ferrara N. Vascular endothelial growth factor and the regulation of angiogenesis. Recent Prog Horm Res 2000;55:15–35, discussion 35–6.
14. Ferrara N, Davis-Smyth T. The biology of vascular endothelial growth factor. Endocr Rev 1997;18:4–25.
15. Tolentino MJ, Miller JW, Gragoudas ES, et al. Vascular endothelial growth factor is sufficient to produce iris neovascularization and neovascular glaucoma in a nonhuman primate. Arch Ophthalmol 1996;114:964–70.
16. Miller JW. Vascular endothelial growth factor and ocular neovascularization. Am J Pathol 1997;151:13–23.
17. Cleland JL, Duenas ET, Park A, et al. Development of poly-(D,L-lactide-coglycolide) microsphere formulations containing recombinant human vascular endothelial growth factor to promote local angiogenesis. J Control Release 2001;72:13–24.
18. Adamis AP, Shima DT, Tolentino MJ, et al. Inhibition of vascular endothelial growth factor prevents retinal ischemia-associated iris neovascularization in a nonhuman primate. Arch Ophthalmol 1996;114:66–71.
19. Miller JW, Adamis AP, Shima DT, et al. Vascular endothelial growth factor/vascular permeability factor is temporally and spatially correlated with ocular angiogenesis in a primate model. Am J Pathol 1994;145:574–84.
20. Aiello LP, Avery RL, Arrigg PG, et al. Vascular endothelial growth factor in ocular fluid of patients with diabetic retinopathy and other retinal disorders. N Engl J Med 1994;331: 1480–7.
21. Adamis AP, Miller JW, Bernal MT, et al. Increased vascular endothelial growth factor levels in the vitreous of eyes with proliferative diabetic retinopathy. Am J Ophthalmol 1994; 118:445–50.
22. Kliffen M, Sharma HS, Mooy CM, et al. Increased expression of angiogenic growth factors in age-related maculopathy. Br J Ophthalmol 1997;81:154–62.
23. Lip PL, Blann AD, Hope-Ross M, et al. Age-related macular degeneration is associated with increased vascular endothelial growth factor, hemorheology and endothelial dysfunction. Ophthalmology 2001;108:705–10.
24. Presta LG, Chen H, O'Connor SJ, et al. Humanization of an anti-vascular endothelial growth factor monoclonal antibody for the therapy of solid tumors and other disorders. Cancer Res 1997;57:4593–9.
25. Hurwitz H, Fehrenbacher L, Novotny W, et al. Bevacizumab plus irinotecan, fluorouracil, and leucovorin for metastatic colorectal cancer. N Engl J Med 2004;350:2335–42.
26. Yang JC, Haworth L, Sherry RM, et al. A randomized trial of bevacizumab, an anti-vascular endothelial growth factor antibody, for metastatic renal cancer. N Engl J Med 2003;349: 427–34.
27. Mordenti J, Cuthbertson RA, Ferrara N, et al. Comparisons of the intraocular tissue distribution, pharmacokinetics, and safety of 125I-labeled full-length and Fab antibodies in rhesus monkeys following intravitreal administration. Toxicol Pathol 1999;27:536–44.
28. Krzystolik MG, Afshari MA, Adamis AP, et al. Prevention of experimental choroidal neovascularization with intravitreal anti-vascular endothelial growth factor antibody fragment. Arch Ophthalmol 2002;120:338–46.
29. Hogan MJ, Kimura SJ, Thygeson P. Signs and symptoms of uveitis. I. Anterior uveitis. Am J Ophthalmol 1959;47:155–70.

Regeneron Ex. 2022
Samsung v. Regeneron
IPR2025-00176
Page 6 of 10

Table 3. Grading Scales for Ocular Inflammation

Flare	
0	No protein is visible in the anterior chamber when viewed by an experienced observer using slit-lamp biomicroscopy; a small, bright, focal slit-beam of white light; and high magnification.
Trace	Trace amount of protein detectable in the anterior chamber. This protein is visible only with careful scrutiny by an experienced observer using slit-lamp biomicroscopy; a small, bright, focal slit-beam of white light; and high magnification.
1+	Mild amount of protein detectable in the anterior chamber. The presence of protein in the anterior chamber is immediately apparent to an experienced observer using slit-lamp biomicroscopy and high magnification, but such protein is detected only with careful observation with the naked eye and a small, bright, focal slit-beam of white light.
2-3+	Moderate amount of protein detectable in the anterior chamber. These grades are similar to 1+, but the opacity would be readily visible to the naked eye of an observer using any source of a focused beam of white light. This is a continuum of moderate opacification, with 2+ being less apparent than 3+.
4+	A large (severe) amount of protein is detectable in the anterior chamber. Similar to 3+, but the density of the protein approaches that of the lens. Additionally, frank fibrin deposition is frequently seen in acute circumstances. It needs to be noted that because fibrin may persist for a time after partial or complete restoration of the blood-aqueous barrier, it is possible to have resorbing fibrin present with lower numeric assignations for flare (e.g., 1+ flare with fibrin).
Cells	
0	No cells are seen in any optical section when a large slit-lamp beam is swept across the anterior chamber.
Trace	Rare (1–3) cells are observed when the slit-lamp beam is swept across the anterior chamber. When the instrument is held stationary, not every optical section contains circulating cells.
1+	Three to 10 cells/optical section are seen when the slit-beam of light sweeps across the anterior chamber. When the instrument is held stationary, every optical section contains circulating cells.
2+	Ten to 25 cells are seen when the slit-beam of light sweeps across the anterior chamber. When the instrument is held stationary, every optical section contains circulating cells.
3+	Twenty five to 50 cells are seen when the slit-beam of light sweeps across the anterior chamber. When the instrument is held stationary, every optical section contains circulating cells. Keratic precipitates or cellular deposits on the anterior lens capsule may be present.
4+	More than 50 cells are seen when the slit-beam of light sweeps across the anterior chamber. When the instrument is held stationary, every optical section contains cells, or hypopyon is noted. As for fibrin deposition, hypopyon may persist for some time after the active exudation of cells into the anterior chamber has diminished or ceased entirely, making it possible to have 1+ circulating cells in the anterior chamber with a resolving hypopyon.

This is a modification of the grading system described by Hogan et al (Hogan MJ, Kimura SJ, Thygeson P. Signs and symptoms of uveitis. I. Anterior uveitis. Am J. Ophthalmol 1959;47:155–70.

Table 4. Baseline Characteristics of the 27 Enrolled Patients

Characteristic	Dose Group					
	50 μg (n = 6)	150 μg (n = 6)	300 μg (n = 6)	500 μg (n = 7)	1000 μg (n = 2)	Total (n = 27)
Age (yrs)						
Mean (± SD)	75.0±4	83.8±7	75.5±9	74.1±5	86.0±3	77.7±7
Range	68–80	73–92	63–85	68–80	84–88	63–92
Gender						
Female	4	3	5	2	1	15 (56%)
Male	2	3	1	5	1	12 (44%)
Duration of AMD (yrs)						
Mean (± SD)	2.4±3	3.1±5	1.9±2	1.9±2	6.1±2	2.6±3
Range	0.1–7.9	0.0–11.0	0.3–4.0	0.2–5.1	4.5–7.6	0.0–11.0
Recurrent disease						
No	3	5	5	5	0	18 (67%)
Yes	3	1	1	2	2	9 (33%)
CNV type (investigator assessment)						
Classic	2	1	0	1	0	4 (15%)
Classic and occult	4	1	4	5	1	15 (56%)
Occult	0	4	2	1	1	8 (30%)
Total lesion size (DAs)						
Mean (± SD)	7.8±7	6.9±4	11.3±7	12.0±10	7.3±3	9.6±7
Range	3–20	3–14	1–21	3–28	5–10	1–28
Visual acuity in study eye*						
20/100	0	2	2	0	0	4 (15%)
<20/100–20/200	0	2	1	4	1	8 (30%)
<20/200–20/320	2	1	1	0	1	5(19%)
<20/320–20/400	2	0	0	2	0	4 (15%)
<20/400	2	1	2	1	0	6 (22%)
Median						20/250
Neovascular AMD in fellow eye						
No	2	2	2	5	0	11 (41%)
Yes	4	4	4	2	2	16 (59%)
Visual acuity in fellow eye*						
20/20–20/40	1	2	2	4	0	9 (34%)
20/50–20/100	2	2	2	1	0	7 (26%)
<20/100–20/320	1	1	—	2	1	5 (18%)
<20/320–20/400	2	1	1	0	1	5 (18%)
<20/400	0	0	1	0	0	1 (4%)
Median						20/80

AMD = age-related macular degeneration; CNV = choroidal neovascularization; DA = disc area (relative measurement of size comparing total size of lesion and size of optic disc); SD = standard deviation
*Visual acuity in Snellen equivalent.

Regeneron Ex. 2022
Samsung v. Regeneron
IPR2025-00176
Page 8 of 10

Table 5. Ocular Adverse Events (Study Eye)

Adverse Event	Dose Group					
	50 μg (n = 6)	150 μg (n = 6)	300 μg (n = 6)	500 μg (n = 7)	1000 μg (n = 2)*	Total (n = 27)
Injection-site events	4	5	5	5	2	21 (78%)
Edema	0	0	0	1	0	1 (4%)
Hemorrhage	4	5	5	4	2	20 (74%)
Pain	1	0	0	0	0	1 (4%)
Aqueous/vitreous inflammation	0	1	4	5	2	12 (44%)
Aqueous cell/flare	0	0	2	4	2	8 (30%)
Vitreous cell/haze	0	1	3	3	2	9 (33%)
Abnormal vision/amblyopia	2	2	2	0	1	7 (26%)
Conjunctivitis	0	1	1	1	1	4 (15%)
Eye pain†	1	1	1	1	0	4 (15%)
Pruritus†	1	1	1	0	0	3 (11%)
Vitreous disorder (floaters or detachment)†	0	0	0	2	0	2 (7%)
Increased IOP	0‡	0	0	1	0	1 (4%)
Dry eyes	0	0	0	1	0	1 (4%)
Eye disorder (gray film)†	1	0	0	0	0	1 (4%)
Lacrimation disorder†§	0	0	1	0	0	1 (4%)
Paresthesia†	1	0	0	0	0	1 (4%)
Vasodilation (mild hyperemia)†	1	0	0	0	0	1 (4%)
Any adverse event‖	6	6	5	6	2	25 (93%)

IOP = intraocular pressure.
*Patient enrollment was halted after 2 cases of significant ocular inflammation occurred in this dose group.
†Events considered not related to ranibizumab administration.
‡A subject experienced a transient clinically significant increase in IOP, but the investigator did not report this as an adverse event.
§Mild tearing.
‖The total number of patients who had any adverse event.

Table 7. Mean (± Standard Deviation) Visual Acuity (VA) Changes from Baseline

Study Day*	Dose Group					
	50 μg (n = 6)	150 μg (n = 6)	300 μg (n = 6)	500 μg (n = 7)	1000 μg (n = 2)	Total (n = 27)
1	10.6±17	4.2±6	−1.2±8	3.1±10	3.0±10	4.0±10
3	13.4±15	4.5±6	−1.0±12	1.1±14	−17.0±28	2.4±15
7	15.5±17	8.3±5	1.3±9	8.1±12	−2.5±8	7.5±12
14	17.3±21	9.3±6	1.7±10	10.4±9	0.0±7	9.0±13
42	15.0±23	7.3±3	5.0±9	12.6±12	8.0±7	9.9±13
90	9.8±9	4.3±5	3.3±10	9.6±10	7.6±1	6.9±8

Changes in study-eye VA measured by best-corrected change in letter score compared with baseline, using the Early Treatment Diabetic Retinopathy Study eye chart. Three subjects had significant (≥15 letters) transient decreases in VA, whereas 7 subjects experienced significantly increased VA.
*Posttreatment day follow-up period.

Table 8. Change from Baseline in Lesion Size

Lesion Size	Total Lesion* (n = 27)	
	Posttreatment Day 7	*Posttreatment Day 90*
Area of lesion [n (%)]		
Increase	2 (7%)	7 (26%)
No change	25 (93%)	16 (62%)
Decrease	0	3 (12%)
Area of CNV [n (%)]		
Increase	2 (7%)	7 (27%)
No change	23 (85%)	13 (50%)
Decrease	1 (4%)	6 (23%)
Could not be graded	1 (4%)	0

CNV = choroidal neovascularization.
Independent assessment performed retrospectively by the Fundus Photograph Reading Center.
*Lesion refers to the area encompassing all lesion components, such as CNV (classic, occult, or both), blood, hypofluorescence not from visible blood, a serous detachment of the retinal pigment epithelium, and fluorescent staining from fibrous tissue.

Regeneron Ex. 2022
Samsung v. Regeneron
IPR2025-00176
Page 10 of 10