ASRS

21

ANNUAL MEETING

AMERICAN SOCIETY OF RETINA SPECIALISTS

NEW YORK 2003

August 16 - 20, 2003

The Waldorf=Astoria Hotel

New York City

ASRS

AMERICAN SOCIETY OF RETINA SPECIALISTS

Saturday, August 16, 2003

12:00pm-9:00pm **Registration** - Lower Level

2:00pm-8:00pm **Speaker Ready Room Open** – West Foyer

5:00pm-7:00pm **Fluorescein Angiography & Surgical Case Conference** - Grand Ballroom
Moderators: Neil M. Bressler, MD, & William F. Mieler, MD

7:00pm-10:00pm **Welcome Reception & Dinner** – Empire & Hilton Rooms

Sunday, August 17, 2003

6:30am-3:00pm **Speaker Ready Room Open** - West Foyer

7:00am-1:30pm **Registration** - Lower Level

7:00am-7:45am **Breakfast** - Exhibition Halls

7:00am-1:30pm **Exhibition Halls Open** - Jade Room, Astor Room, and East Foyer

7:00am-1:30pm **Fifth Annual Film Festival** - Louis XVI Suite

7:00am-1:30pm **Vitreous Foundation Silent Auction** - Exhibition Halls

7:00am- 1:30pm **Scientific & Practice Pearl Poster Display** - Basildon Room

7:00am-1:30pm **Preferences and Trends (PAT) Survey Results Display** - Grand Ballroom Foyer

7:15am-7:45am **Poster Session 1: Macular Holes, Macular Puckers/Prostheses** - Basildon Room

7:15am-7:45am **Poster Session 2: Practice Management/Socio-Economic Issues** - Basildon Room

7:45am-8:00am **Opening Remarks** - Grand Ballroom
Paul E. Tornambe, MD, President & Eugene de Juan, Jr., MD, Vice-President and Program Chairperson

8:00am-9:48am **Symposium 1: Macular Holes & Macular Puckers/Prostheses** - Grand Ballroom
Moderators: Kirk H. Packo, MD & Paul E. Tornambe, MD

9:48am-10:35am **Symposium 2: Practice Management/Socio-Economic Issues** - Grand Ballroom
Moderators: William L. Rich, III, MD & Trexler M. Topping, MD

10:35am-11:05am **Break & Refresments** - Exhibition Halls

10:35am-11:05am **Poster Session 3: Instrumentation, Technologies, Devices, and Surgical Complications** - Basildon Room

10:35am-11:05am **Poster Session 5: Photodynamic Therapy for AMD** - Basildon Room

11:05am-12:26pm **Symposium 3: Instrumentation, Technologies, Devices, and Surgical Complications** - Grand Ballroom
Moderators: Carl C. Awh, MD & Steve T. Charles, MD

12:26pm-1:20pm **Symposium 4: Ophthalmic Literature/Quality of Life** - Grand Ballroom
Moderators: Carl C. Awh, MD & Steve T. Charles, MD

1:20pm-1:30pm **AAO Presentation** - Grand Ballroom
Michael R. Redmond, MD, President

3:00pm **Broadway Show "Hairspray"** (Optional Event - Pre-Purchased Ticket Required)

7:00pm-11:00pm **An Evening at B.B. King's Blues Bar & Grill** - Dinner and Entertainment (Optional Event - Ticket Required)

Monday, August 18, 2003

6:30am-5:00pm **Speaker Ready Room Open** - West Foyer

6:30am-5:30pm **Registration** - Lower Level

6:45am-7:45am **"Breakfast with the Masters" Roundtable Discussions** - Empire Room
Organizer: David S. Boyer, MD

7:00am-7:45am **Breakfast** - Exhibition Halls

7:00am-5:00pm **Exhibition Halls Open** – Jade Room, Astor Room, and East Foyer

7:00am-5:00pm **Fifth Annual Film Festival** - Louis XVI Suite

7:00am-5:00pm **Vitreous Foundation Silent Auction** - Exhibition Halls

7:00am-5:00pm **Scientific & Practice Pearl Poster Display** - Basildon Room

7:00am-5:00pm **Preferences and Trends (PAT) Survey Results Display** - Grand Ballroom Foyer

8:00am-10:00am **Symposium 5: Photodynamic Therapy for AMD** - Grand Ballroom
Moderators: Michel E. Farah, MD & Richard F. Spaide, MD

10:00am-10:30am **Break & Refreshments** - Exhibition Halls

10:00am-10:30am **Poster Session 6: CNV & AMD - Treatments & Therapies/Steroid and Drug Therapies** - Basildon Room

10:30am-12:30pm **Award Lectures & Business Meeting** - Grand Ballroom
Moderators: Eugene de Juan, Jr., MD & Paul E. Tornambe, MD

12:30pm-1:45pm **Young Physicians Section Meeting/Lunch** - Metropolitan Suite
Moderators: Sharon Fekrat, MD & John S. Pollack, MD

2:00pm-5:00pm **Symposium 6: CNV & AMD - Treatments & Therapies/Steroid and Drug Therapies** - Grand Ballroom
Moderators: Roy A. Levit, MD & Robert P. Murphy, MD

2:59pm-3:30pm **Break & Refreshments** - Exhibition Halls

3:30pm-5:00pm **Symposium 6 (continued): CNV & AMD - Treatments & Therapies/Steroid and Drug Therapies** - Grand Ballroom
Moderators: Roy A. Levit, MD & Robert P. Murphy, MD

Tuesday, August 19, 2003

6:30am-5:00pm **Speaker Ready Room Open** - West Foyer

7:00am-5:30pm **Registration** - Lower Level

7:00am-8:00am **Breakfast** - Exhibition Halls

7:00am-1:00pm **Fifth Annual Film Festival** - Louis XVI Suite

7:00am-1:00pm **Exhibition Halls Open** – Jade Room, Astor Room, and East Foyer

7:00am-1:00pm **Vitreous Foundation Silent Auction** - Exhibition Halls

7:00am-5:00pm **Scientific & Practice Pearl Poster Display** - Basildon Room

7:00am-5:00pm **Preferences and Trends (PAT) Survey Results Display** - Grand Ballroom Foyer

7:30am-8:00am **Poster Session 7: Diabetic Retinopathy** - Basildon Room

8:00am-10:00am	**Symposium 7: Diabetic Retinopathy** - Grand Ballroom Moderators: Suber S. Huang, MD & John T. Thompson, MD
10:00am-10:30am	**Break & Refreshments** - Exhibition Halls
10:00am-10:30am	**Poster Session 8: Retinal Detachment/Endophthalmitis** - Basildon Room
10:00am-10:30am	**Poster Session 9: Retinal Vascular Disease** - Basildon Room
10:30am-12:30pm	**Symposium 8: Retinal Detachment/Endophthalmitis** - Grand Ballroom Moderators: Tarek S. Hassan, MD & Hugo Quiroz-Mercado, MD
1:30pm-2:30pm	**Course 1: Advanced Approaches to OCT, Dynamic ICG Angiography, Infra-red Photography, and Autofluorescence Imaging** - Bert M. Glaser, MD
1:30pm-3:00pm	**Course 2: The Art of the Digital Presentation** - Kirk H. Packo, MD
1:30pm-3:30pm	**Course 3: 25-Gauge Vitrectomy: Current Concepts and Instrumentation** - Carl C. Awh, MD
1:30pm-3:30pm	**Course 4: What's New in Fundus Tumors?** - Jerry A. Shields, MD
3:00pm-4:00pm	**Course 5: Endoscopic Vitrectomy** - Martin Uram, MD, MPH
3:30pm-5:30pm	**Course 6: New Technology & Controversies in Vitreous Surgery Instrumentation** - Kirk H. Packo, MD
4:00pm-5:00pm	**Course 7: Retinal Coding** - G. Philip Matthews, MD, PhD
7:00pm-8:00pm	**Cocktail Reception** - Exibition Halls
8:00pm-Midnight	**Gala Dinner Banquet** - Grand Ballroom

Wednesday, August 20, 2003

6:30am-11:00am	**Speaker Ready Room Open** - West Foyer
7:00am-8:00am	**Breakfast**- Exhibition Halls
7:00am-11:00am	**Exhibition Halls Open** – Jade Room, Astor Room, and East Foyer
7:00am-12:30am	**Scientific & Practice Pearl Poster Display** - Basildon Room
7:00am-12:30am	**Preferences and Trends (PAT) Survey Results Display** - Grand Ballroom Foyer
7:00am-12:30pm	**Fifth Annual Film Festival** - Louis XVI Suite
7:30am-12:30pm	**Registration** - Lower Level
7:30am-8:00am	**Poster Session 11: Imaging/Trauma/Ocular Oncology** - Basildon Room
8:00am-9:30am	**Symposium 9: Retinal Vascular Disease** - Grand Ballroom Moderators: Mark S. Blumenkranz, MD & Julia A. Haller, MD
9:30am-10:30am	**Symposium 10: Pediatric Retina - ROP** - Grand Ballroom Moderators: Michael T. Trese, MD & Allen Z. Verne, MD
10:30am-11:00am	**Break & Refreshments** - Exhibition Halls
11:00am-12:30pm	**Symposium 11: Imaging/Trauma/Ocular Oncology** - Grand Ballroom Moderators: Jerry A. Shields, MD & David F. Williams, MD, MBA
12:30pm-12:45pm	**Closing Remarks** - Grand Ballroom
12:45pm	**Meeting Adjourns**

ASRS

Evolution
Mission Statement
Board of Directors
Committees
PAT Survey
R&D Report
Young Physicians Section
Future Meetings
Vitreous Foundation

Symposium 6: CNV & AMD - Treatments & Therapies/Steroid and Drug Therapies

Moderators: Roy A. Levit, MD & Robert P. Murphy, MD – Monday 2:00pm-5:00pm

Results:
Patients presented with initial visual acuities ranging from 20/32 to 20/640. 100 % of patients had intraretinal edema and subretinal fluid on presentation. Static angiography demonstrated occult neovascularization without a clear leakage source. An ill defined ICG hot spot was present in all cases. High speed ICG imaging was required in all patients to clearly define the intraretinal neovascularization. High speed ICG was essential for localization of early, small RAP lesions. A mean of 2.1 laser treatments per eye was required. With an average follow up of 4.8 months 92 % had a reduction or resolution of subretinal fluid and retinal edema. 84 % had stabile or improvement of visual acuity. 42 % of patients gained 1 or more line of visual acuity. No significant complications were encountered.

Conclusion:
High speed ICG imaging is an important method for the identification of retinal angiomatous proliferations. High speed ICG is able to localize early RAP lesions that are not well defined with traditional imaging techniques. Focal laser ablation of RAP lesions appears to be a safe and effective method of management. Earlier therapy may offer improved visual outcomes.

2:24pm

Retinal Angiomatous Proliferation: Diagnosis by Digital ICG Video Angiography and Treatment with Pulsed Green Laser

Robert P. Murphy, MD (Fairfax, VA)

One Sentence Objective:
Retinal Angiomatous Proliferation: Identification with digital ICG video angiography and treatment with pulsed 532 nm diode laser.

Purpose:
To assess the ability to close the retinal vascular supply of RAP lesions diagnosed by ICG angiography by treating with pulsed green laser and to monitor the short term anatomic and visual benefits.

Methods:
Fifteen eyes of thirteen consecutive patients with age-related macular degeneration and stage I retinal angiomatous proliferation (RAP) were identified by digital video ICG (Heidelberg Engineering) and fluorescein angiography. Six of 15 eyes had a pigment epithelial detachment. The mean patient age was 79 years. Repetitive milli-pulsed 532 nm (green) treatment using the Iridex OcuLight laser effected closure of blood flow to the RAP lesion. Laser treatment was applied in the automatic pulse mode (0.03 seconds on and 0.03 seconds off) with bursts of approximately twelve lesions per application using a 50 micron spot size. The power was gradually increased during treatment from 50 milliwatts to approximately 120 milliwatts. The aiming beam was placed at the point at which the retinal arteriole entered the RAP. Treatment response was monitored with clinical examination, fluorescein and ICG angiography.

Results:
Fourteen of fifteen eyes had complete initial closure of all RAP lesions. Seven of these fourteen eyes subsequently developed either new RAP lesions or reperfusion of the original lesion requiring further treatment. With a mean follow-up of four months, 11/15 eyes had a final visual acuity within two lines of baseline, 1 eye improved more than 3 lines, and 3 decreased 3 or more lines. No eyes developed worse than 20/400 visual acuity and none developed severe visual loss.

Conclusion:
Transit digital video ICG angiography is an effective way to diagnose RAP. Pulsed 532 nm laser effectively closes the RAP lesions with minimal adverse effects. With short term follow-up most eyes are stable or improved; this outcome compares favorably with published natural history reports and with results from other treatments of RAP. However eyes with RAP lesions remain active with reperfusion following treatment and development of new lesions.

2:31pm

rhuFab V2 for Exudative AMD: 6-months Results of a Multi-center, Controlled Trial

Jeffrey S. Heier, MD (Boston, MA)*, J.P. Sy, PhD (S. San Francisco, CA)*, Edward R. McCluskey, MD (S. San Francisco, CA)*, Andrew N. Antoszyk, MD (Charlotte, NC)*, Peter Reed Pavan, MD (Tampa, FL)*, Steven R. Leff, MD (New Brunswick, NJ)*, Philip J. Rosenfeld, MD, PhD (Miami, FL)*, Thomas A. Ciulia, MD (Indianapolis, IN)*, Richard F. Dreyer, MD (Portland, OR)*, Ronald C. Gentile, MD (New York, NY)*

One Sentence Objective:
To explore the continued safety and tolerability of rhuFab V2, a monoclonal antibody fragment designed to inactivate all isoforms of VEGF and block vessel permeability and angiogenesis in AMD.

Symposium 6: CNV & AMD - Treatments & Therapies/Steroid and Drug Therapies

Moderators: Roy A. Levit, MD & Robert P. Murphy, MD – Monday 2:00pm-5:00pm

Purpose:
To investigate the continued safety, tolerability, and efficacy of 4-8 intravitreal injections of 300µg or 500µg rhuFab V2, a monoclonal antibody fragment directed against VEGF, administered to subjects with neovascular age-related macular degeneration (AMD).

Methods:
Sixty-four subjects with primary or recurrent subfoveal choroidal neovascularization (CNV) secondary to AMD were enrolled in this open-label, randomized, controlled study in three strata: minimally classic CNV, predominantly classic CNV, and active lesion after photodynamic therapy. The mean subject age was 77 years (range 59-91); 52% were female and 94% Caucasian. In the first 12-week treatment period of the study, subjects were randomized to receive either 300 ug rhuFab V2 q 4 weeks (n=25), 500 ug in an escalating dose regimen (n = 28), or "usual care" (UC) (n = 11). At the end of the first period (Day 98), subjects were permitted to cross over between UC and rhuFab V2; all but 2 UC subjects elected to cross over to rhuFab V2. The treatment regimens in the second period followed that of the first period, for a total of 4-8 rhuFab V2 injections in both periods. All subjects underwent ETDRS visual acuity testing, ophthalmologic examination, fluorescein angiography, and fundus photography at baseline, during treatment, and at follow-up. Endpoints investigated included safety assessments, visual acuity, and angiographic biologic activity for up to 6 months.

Results:
Preliminary analysis showed that subjects receiving 4 rhuFab V2 injections (n=53) achieved a mean improvement of 9.0 (+ 2 SE) letters in ETDRS visual acuity score at the end of the first period (Day 98) compared with baseline. Subjects that elected to continue with this regimen for the second period (n = 40) showed a further improvement to 12.8 (+3) letters in the 300/300 group and 15.0 (+3) letters in the 500/500 group. The UC group demonstrated an average loss in visual acuity of 5.1 (±3) letters at the end of the first period; however, those who crossed over to rhuFab V2 showed an improvement of 7.3 letters (n=4) in the UC/300 group and 3.2 letters (n=5) in the UC/500 group. Overall, the response rate to rhuFab V2 was extremely high with 45.0% of subjects treated with rhuFab V2 for 6 months showing an improvement of 15 letters or more, 52.5% with stable VA and 2.5% with worsened VA (by >15 letters) by Day 210. Multiple doses of rhuFab V2 were safe and well tolerated in the 62 subjects who were treated in this study. The most common adverse event was mild reversible ocular inflammation. Full data will be presented.

Conclusion:
rhuFab V2 at 300 ug and 500 ug demonstrated a continued improvement in visual acuity with continued treatment and was well tolerated for up to 6 months. Regardless of the initial starting dose, subjects continued to benefit from therapy.

* Financial Interest Disclosed

2:38pm

rhuFab V2 Dose-escalation Trial: Safety and Tolerability of 3 Escalating Dosing Regimens in Subjects with Age-related Macular Degeneration (AMD)

Philip J. Rosenfeld, MD, PhD (Miami, FL)*, Jeffrey S. Heier, MD (Boston, MA)*, Carol Y. Chung, PhD (South San Francisco, CA)*, Edward R. McCluskey, MD, PhD (South San Francisco, CA)*

One Sentence Objective:
To explore the safety and tolerability of rhuFab V2, a monoclonal antibody fragment designed to inactivate all isoforms of VEGF and block vessel permeability and angiogenesis in AMD

Purpose:
To explore the safety and tolerability of rhuFab V2, a monoclonal antibody fragment directed against VEGF, when administered as multiple dose-escalating regimens in subjects with primary or secondary subfoveal choroidal neovascularization (CNV) secondary to AMD.

Methods:
Twenty-nine subjects with primary or recurrent subfoveal CNV secondary to AMD were enrolled in an open-label, dual-center, randomized investigative study of 3 rhuFabV2 dose-escalation regimens. All subjects received 16 weeks of treatment and were followed through 20 weeks. The dose-escalating regimens comprised doses in the 300mg-2000mg range, administered intravitreally as frequently as every 2 weeks. Group 1 received doses escalating from 300µg to 1000mg every 2 weeks over 8 weeks followed by 1000mg of rhuFab V2 every 4 weeks. Group 2 received doses escalating from 300µg to 2000mg every 2 weeks over 14 weeks with a final 2000mg dose at week 16. Group 3 received doses escalating from 300µg to 2000mg every 4 weeks over 16 weeks. Throughout the study, subjects underwent EDTRS visual acuity testing, ophthalmologic examination, and adverse event assessment. Fluorescein angiography and fundus photography were conducted during screening and at Weeks 8 and 20, and OCT analyses were performed at one site at selected visits.

Symposium 6: CNV & AMD - Treatments & Therapies/Steroid and Drug Therapies

Moderators: Roy A. Levit, MD & Robert P. Murphy, MD – Monday 2:00pm-5:00pm

RESULTS:

Overall, rhuFab V2 was well tolerated even when dose escalated to 2000mg. Three subjects experienced a grade 2+ or higher intraocular inflammation after the first and/or second injection at 300µg or 500µg. Only one subject experienced a grade 2+ intraocular inflammation at a dose higher than 500µg. The mean improvement (at Week 20 [Day 140], compared with baseline) in ETDRS visual acuity letters was 13.6 +2.9 (sem) (n=9) in Group 1, 11.9 +3.5, (n=9) in Group 2, and 5.2 +5.9 (n=9) in Group 3. Overall, 44.4% of subjects had an improvement of 15 letters or more, 48.1% had stable visual acuity and 7.4% had worsened VA (by >15 letters) at Day 140 compared with baseline. Thus, up to 2000µg of rhuFab V2 could be administered as frequently as every 2 weeks without intolerable effects. No cases of endophthalmitis were observed, and the most frequent adverse event was mild, reversible inflammation.

CONCLUSION:

Regimens using frequent dosing and higher doses of rhuFab V2 were well tolerated with a beneficial effect on visual acuity.

** Financial Interest Disclosed*

2:45pm

RHUFAB V2 IN WET AMD: CHANGES IN OCT MEASURES OF THE OCULAR EDEMA

Andrew N. Antoszyk, MD (Charlotte, NC)*, Judy P. Sy, MD, PhD (South San Francisco, CA)*,
Edward R. McCluskey, MD, PhD (South San Francisco, CA)*, rhuFabV2 Study Group (San Francisco, California)*

ONE SENTENCE OBJECTIVE:

To describe the changes in foveal OCT characteristics in patients with wet AMD treated with rhuFab V2.

PURPOSE:

Purpose: To describe the changes in OCT characteristics of the foveal regions of a subset of patients with wet age-related macular degeneration (AMD) treated in a Phase I/II study with 4-8 intravitreal injections of rhuFab V2, a monoclonal antibody fragment designed to block VEGF-induced vascular permeability changes in the macula.

METHODS:

Methods: OCT scans were performed on a subset (19) of subjects enrolled in an open-label, randomized, controlled study of 64 subjects with wet AMD randomized (4:1) to rhuFab V2 (one of two dose groups: 300mg or 500mg every 28 days) or to "usual care". Eligible subjects were enrolled into three strata: minimally classic CNV, predominantly classic CNV (a photodynamic therapy–eligible lesion), or an active lesion after treatment with photodynamic therapy. OCT scans were performed at baseline and on days 14, 28, 56, and 84. In addition, all subjects underwent ETDRS visual acuity testing, fluorescein angiography, and fundus photography. Endpoints investigated include central macular thickness and retinal volume.

RESULTS:

Results: In the subjects who received rhuFab V2 (n=16), the average central retinal thickness was 300 microns ±92 (SD) at baseline, 228 microns ±75 at day 14, 262 microns ±164 at day 28, 237 microns ±126 at day 56, and 201 microns ±33 at day 84 (Figure 1). The average central retinal thickness decreased 33% from baseline to day 84. The average retinal volume decreased by 25%, from 3.55 ± 2.86 mm3 at baseline to 2.68 mm3 ± 1.42 at day 84. Subjects in the usual care group (n=3) showed only a minimal change in central retinal thickness (313 microns ± 101 at baseline to 309 microns ± 111 at day 84). Full data will be presented.

CONCLUSION:

Conclusions: rhuFab V2 appears to decrease central retinal thickness and central retinal volume quickly (within 28 days) following intravitreal injection. The changes in OCT measurements appear to be clinically correlated with an improvement in visual acuity. Further study is warranted.

** Financial Interest Disclosed*

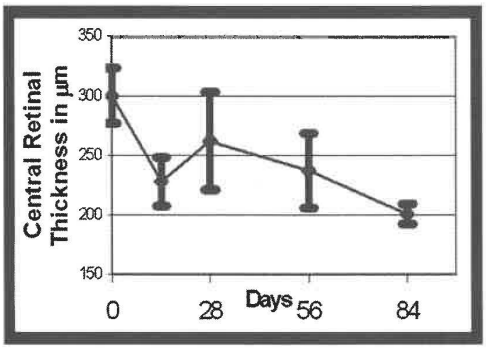

Figure legend: rhuFab V2 is associated with a decrease in central retinal thickness. Figure shows mean values +/- SE from 16 subjects.