Experimental and Clinical Observations of the Intraocular Toxicity of Commercial Corticosteroid Preparations

Tetsuo Hida, M.D., David Chandler, B.S., James E. Arena, R.Ph., and Robert Machemer, M.D.

We tested the vehicles of six different commercially available depot corticosteroids (Celestone Soluspan, Depo-Medrol, Decadron, Decadron L. A., Aristocort, and Kenalog) for possible toxicity when injected intravitreally. When tested on rabbit eyes, the Celestone Soluspan and the Depo-Medrol vehicles caused remarkable retinal degeneration with preretinal membrane formation or cataracts in their standard concentrations. Three other vehicles (Decadron and Decadron L. A.) caused localized retinal degeneration in twice the standard concentration. Thus, toxic effects can be caused by preservatives or inadequate osmolarity of the vehicles alone. The development of proliferative vitreoretinopathy in some cases of injections of intraocular depot corticosteroid can be explained by retinal necrosis and repair processes caused by these vehicles.

PERIOCULAR INJECTION of corticosteroids is a common treatment for a variety of ocular inflammatory disorders. One of the rare but serious complications of this method is perforation of the globe and accidental intraocular injection. Although experimental intravitreal injection of pure triamcinolone acetonide disclosed no damage to the eye,[1] there have been reports of inadvertent injections of commercially available corticosteroid into human eyes resulting in damage to the retina with proliferative vitreoretinopathy.[2] Because some corticosteroids reduce intraocular proliferations,[3,4] we believed that this adverse effect was probably caused by the vehicles rather than the corticosteroid itself. Our purpose was to evaluate the ocular toxicity of vehicles used in commercially available corticosteroid preparations after intravitreal injection, and to demonstrate their potential damaging effects when inadvertently injected into the human eye.

Accepted for publication Dec. 6, 1985.

From the Department of Ophthalmology, Duke University Eye Center, Durham, North Carolina. This study was supported by grant EY02903, IP30EY05722 from the National Eye Institute, by Research to Prevent Blindness, Inc., and by the Helena Rubinstein Foundation.

Reprint requests to Robert Machemer, M.D., Duke University Eye Center, Box 3802, Durham, NC 27710.

Material and Methods

Vehicles—We examined the vehicles of six commercially available corticosteroids used for periocular injections: Celestone Soluspan (betamethasone sodium phosphate), Depo-Medrol (methylprednisolone acetate), Decadron (dexamethasone sodium phosphate), Decadron L.A. (dexamethasone acetate), Aristocort (triamcinolone diacetate), and Kenalog (triamcinolone acetonide).

In Group 1 (regular strength), the vehicles were prepared using the concentrations described in the manufacturers' specifications (Table 1). The osmolarity of the vehicles was adjusted by substituting a sodium chloride equivalent to compensate for the absence of the soluble or partially soluble corticosteroids. The pH of each vehicle was within the range specified by the manufacturer.

In Group 2 (double strength), the concentrations of the vehicles were doubled. We used osmolarity calculations and sodium chloride equivalents to approximate the osmolality of the commercial preparations determined by using a freezing-point depression osmometer. An exception occurred in the formation of the Decadron double-strength vehicle which became more hyperosmotic than the commercial preparation because of the doubled concentration of sodium citrate. The concentration of methylparaben in this vehicle was increased by only 66%, the extent of its aqueous solubility. Measurement of the osmolality for each

©AMERICAN JOURNAL OF OPHTHALMOLOGY 101:190–195, FEBRUARY, 1986

FORMYCON-1058

TABLE 1
VEHICLE INGREDIENTS*

INGREDIENTS	CELESTONE SOLUSPAN	DEPO-MEDROL (40 MG/ML)	DECADRON (24 MG/ML)	DECADRON L.A.	ARISTOCORT	KENALOG
Preservatives (mg/ml)						
Benzalkonium chloride	0.2	—	—	—	—	—
Myristyl gamma-picolinium chloride	—	0.195	—	—	—	—
Benzyl alcohol	—	—	—	9.0	9.0	9.0
EDTA	0.1	—	0.5	0.5	—	—
Sodium bisulfite	—	—	1.0	1.0	—	—
Methylparaben	—	—	1.5	—	—	—
Propylparaben	—	—	0.2	—	—	—
Suspending agents (mg/ml)						
Sodium carboxymethylcellulose	—	—	—	5.0	—	7.5
Polyethylene glycol	—	20.0	—	—	30.0	—
Polysorbate 80	—	—	—	0.75	2.0	0.4
Buffering agents (mg/ml)						
Diabasic sodium phosphate	7.1	—	—	—	—	—
Monobasic sodium phosphate	3.4	—	—	—	—	—
Others (mg/ml)						
Creatinine	—	—	8.0	5.0	—	—
Sodium citrate	—	—	10.0	—	—	—
Sodium chloride	—	8.7	—	6.67	8.5	—
pH	6.8 to 7.2	3.5 to 7.0	7.0 to 8.5	5.0 to 7.5	6.0	5.0 to 7.5
Osmolality (mOsm/kg)	175	318	361	372	404	320

*Based on the manufacturers' package inserts.

double-strength vehicle confirmed the osmolality within a range of +1.6% to −4% of commercial preparations. Each double-strength vehicle had a pH that fell within United States Pharmacopeial and manufacturers' specifications (range, 6.0 to 7.0).

Group 1—Pigmented rabbits weighing between 2 and 4 kg each were anesthetized with ketamine (30 mg/kg of body weight) and xylazine (5 mg/kg of body weight) and their pupils were dilated with topical 0.5% phenylephrine and 0.25% tropicamide. After topical anesthesia with 0.5% proparacaine HCl, 0.1 ml of each vehicle was slowly injected into the vitreous through a 30-gauge needle, inserted through the sclera 4 mm posterior to the corneoscleral limbus in the superior temporal quadrant. The needle tip was positioned just below and as close as possible to the optic disk under indirect ophthalmoscopic control. We used the fellow eye of each animal as a control, injecting 0.1 ml of balanced salt solution (BSS) in the same manner.

Indirect ophthalmoscopic and slit-lamp examinations were done preoperatively, immediately after injection, and on days 1, 2, 4, 7, and 14. Fundus photographs were taken before and at the end of the experiments, and at each examination if abnormalities were found. Photographs of the lens were also taken in cases of abnormal findings.

We tested each vehicle a maximum of four times. If a vehicle showed no toxicity in four trials, we classified it as nontoxic. If a vehicle showed toxic effects in two eyes, we classified it as toxic and did no further trials.

Group 2—Each vehicle proved to be nontoxic in Group 1 was injected in the same manner but at twice the standard concentration.

To test the effect of hyperosmolarity of the vehicle on the eye, we injected a sodium chloride solution with an osmolality close to those of the Aristocort and Decadron double-strength vehicles (411 mOsm/kg) into two eyes in the same manner.

All eyes were monitored for 14 days; in selected cases, the animals were killed on day 14 by an overdose of pentobarbital. The eyes were enucleated, fixed in 10% formalin, and prepared for histologic examination.

Results

We used a total of 39 rabbits in this study. No mechanical damage from the the injection was observed in any of the eyes. None of the control eyes showed abnormalities during the examination period.

Group 1—Decadron, Decadron L.A., Aristocort, and Kenalog vehicles caused no clinically detectable abnormality after injection.

The Celestone Soluspan vehicle produced remarkable damage to the lens and the retina in each of two trials. Only two hours after injection, posterior retinal edema with dilatation of retinal vessels and intraretinal and preretinal hemorrhages were detected. The posterior capsule of the lens was already opaque at this time. The next day, there was a mild anterior chamber reaction and we observed an increased posterior subcapsular cataract. Retinal edema progressed on day 2, but began to regress on day 4 with the appearance of depigmented areas. On day 7, retinal edema was no longer detected, but the depigmentations had progressed. On day 14, a large retinal break was observed near the medullary wing. In one eye, the medullary wing was elevated and distorted at day 14 (Fig. 1). The cataracts progressed during this period, extending to the posterior cortex and nearly obscuring the view of the fundus with the indirect ophthalmoscope (Fig. 2).

The Depo-Medrol vehicle caused a posterior subcapsular cataract that appeared one to two hours after injection and progressed slowly during the examination period. No clinically detectable retinal damage was seen after each of two trials. Although the toxicity of the Depo-Medrol vehicle was obvious, we also tested its double-strength vehicle in Group 2 to determine the effect on the retina.



Fig. 1 (Hida and associates). Posterior retina under dissecting microscope 14 days after injection of the Celestone Soluspan vehicle. Medullary wing is distorted and a large necrotic retinal break is present (arrow).

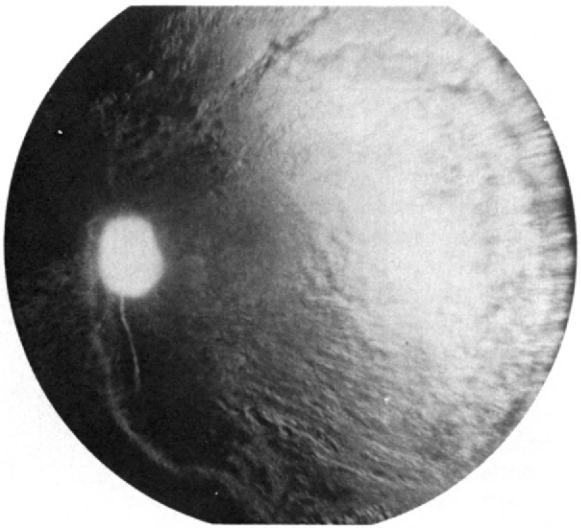

Fig. 2 (Hida and associates). Posterior subcapsular cataract (retroillumination) of the rabbit eye 14 days after injection of the Celestone Soluspan vehicle.

Measurement of osmolality of the commercial corticosteroid preparations showed that all preparations were slightly hyperosmotic except Celestone Soluspan which was considerably hypoosmotic (Table 1).

Group 2—We found no effect on the retina and lens with Aristocort and Kenalog. The Depo-Medrol double-strength vehicle, however, caused remarkable retinal damage in addition to the cataract after each of two injections. The Decadron and Decadron L.A. vehicles were tried in four eyes and produced retinal changes in two eyes. No cataract was detected. In all of these eyes, localized retinal edema was observed close to the optic disk or to one of the medullary wings inferiorly on the day after injection. This edema progressed on day 2 and began to regress on day 4, leaving depigmentation. In two eyes retinal edema involved the medullary wing with dilatation of the vessels and intraretinal or preretinal hemorrhages. Control eyes showed no clinically detectable damage (Table 2).

Two eyes injected with the hyperosmotic sodium chloride solution showed small localized serous retinal detachments one hour after in-

TABLE 2
SUMMARY OF CLINICAL DATA

PREPARATIONS	NO OF EYES INJECTED	NO. WITH CLINICALLY DETECTABLE DAMAGE	NO. WITH RETINAL DAMAGE	NO. WITH CATARACT
Celestone Soluspan	2	2	2 (+++)	2 (++)
Depo-Medrol				
Regular-strength	2	2	0	2 (+)
Double-strength	2	2	2 (++)	2 (++)
Decadron				
Regular-strength	4	0	0	0
Double-strength	4	2	2 (++)	0
Decadron L.A.				
Regular-strength	4	0	0	0
Double-strength	4	2	2 (++)	0
Aristocort				
Regular-strength	4	0	0	0
Double-strength	4	0	0	0
Kenalog				
Regular-strength	4	0	0	0
Double-strength	4	0	0	0
BSS (controls)	38	0	0	0
Saline (411 mOsm/kg)	2	2	2 (+)	0

jection. On the next day, the detachments disappeared, leaving mild retinal edema resulting ultimately in mild depigmentation on day 14.

Histologic sections of the eyes at day 14 after injection of the Celestone Soluspan vehicle showed remarkable damage to the retina. The outer segments and outer nuclear layer had disappeared in the posterior retina, and localized loss of the entire retinal layer was observed close to the medullary wing. In one eye the medullary wing was elevated and folded with a thin membrane of fibroblasts covering the vessels of the wing (Fig. 3). All the other examined eyes in Group 1 showed no histologic changes in the retina.

In all of the sections of the eyes with clinical retinal changes after the injection of double-strength vehicles, we consistently found localized loss of outer segments and, in some eyes, the outer nuclear layer also disappeared. Focal necrosis was found in the nerve fiber layer of the medullary wing in one eye with the Decadron L.A. vehicle and close to the wing in another eye with the Depo-Medrol vehicle. In another eye with the Depo-Medrol vehicle, there was a large area of loss of the entire retinal layer. No histologic damage occurred in eyes without clinically detectable changes after the injections or in the eyes with hyperosmotic saline. The control eyes had normal retinas.

Case Report

A 67-year-old man received an inadvertent intraocular injection of Depo-Medrol after an uncomplicated extracapsular cataract extraction with posterior chamber lens implantation. A vitrectomy was immediately performed and most of the corticosteroid was removed. Eighteen days later, the patient had a visual acuity of

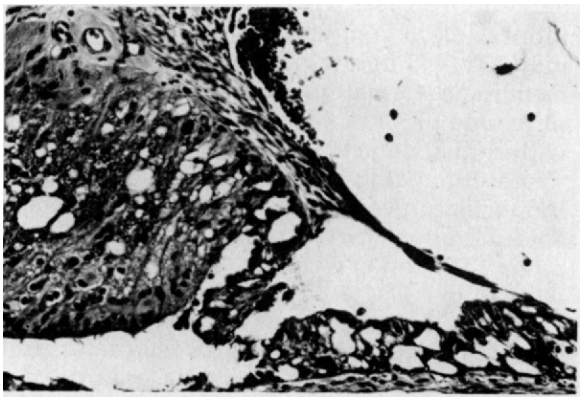

Fig. 3 (Hida and associates). Histologic section of rabbit eye 14 days after injection of the Celestone Soluspan vehicle. Note distorted degenerative medullary wing with preretinal membrane and atrophic retina (hematoxylin and eosin, ×220).

counting fingers temporally. The attached retina showed diffuse thickening and opacification, especially in the macular region. A total retinal detachment developed, with starfold formation thoughout the posterior pole. Atrophic holes could be seen inferior temporally to the fovea and a horseshoe tear was found near the equator at the 9 o'clock meridian. When we examined the patient six weeks after the initial event, his visual acuity was hand movements at 1 foot. There was a well-positioned posterior chamber lens. The retina was detached in a narrow funnel with heavy preretinal membrane formation everywhere. Some blood was found in the inferior vitreous cavity.

We performed a pars plana vitrectomy. It was extremely difficult to peel any membranes, especially on the posterior retina, usually the easiest place to do this. The macular area was atrophic and we found several holes in this area with vessels crossing the holes. A silicone oil tamponade was attempted but failed to flatten the retina.

Discussion

Periocular injection of corticosteroids is an appropriate treatment for various ocular inflammatory disorders and has the advantage of placing high concentrations of corticosteroid locally. The risk of perforation of the globe at injection is probably higher than reported.[2,5-8]

Schlaegel and Wilson[2] reported six cases of accidental intraocular injection of corticosteroid. In two cases vision was lost because of retinal detachment with proliferative vitreoretinopathy and in one case because of preretinal membrane formation and chorioretinal atrophy. One of us (R.M.) examined two patients with retinal detachment in whom proliferative vitreoretinopathy developed after inadvertent intraocular injection of corticosteroid. Remarkable preretinal membranes and unusual thinning of the retina were observed at the time of vitrectomy.

In this study, four of the six vehicles for commercially available corticosteroids (Celestone Soluspan, Depo-Medrol, Decadron, and Decadron L.A.) showed obvious or potential toxicity to the retina after intravitreal injection. The Celestone Soluspan vehicle was the most toxic and caused necrotic retinal degeneration and even some preretinal membrane formation in its standard concentration. The Depo-Medrol vehicle was toxic to the lens but retinal damage was caused only by the double-strength vehicle. Although the toxicity of the Depo-Medrol vehicle was less severe than that of the Celestone Soluspan vehicle, this corticosteroid is commonly used in ophthalmology. The Decadron and Decadron L.A. vehicles did not damage the retina in standard concentration, but double-strength vehicles caused the same localized posterior retinal degeneration. These retinal changes were observed both clinically and histologically in one-half the eyes injected with these vehicles, but the other one-half showed no abnormality. Normal vitreous may protect the rapid dispersion of the injected material and retinal changes probably resulted before they were diluted when the vehicle was injected close to the posterior retina. These toxic effects would be further enhanced with a subretinal injection.

The toxic elements in these vehicles are probably their preservatives. Benzalkonium chloride (Celestone Soluspan) and myristyl gamma-picolinium chloride (Depo-Medrol) are cationic surface-active disinfectants of quaternary ammonium compounds. Benzalkonium chloride is often used in ophthalmic preparations. Previous reports have demonstrated its toxicity to the cornea,[9] and one report showed that it is damaging to the corneal endothelium in vitro at much lower concentrations than are present in ophthalmic solutions.[10] Benzyl alcohol is a preservative contained in Decadron L.A., Aristocort, and Kenalog at the same concentration. Of these three, only the Decadron L.A. double-strength vehicle caused retinal damage in this experiment. Although no ocular toxicity has been proved, intravenous use of solutions containing benzyl alcohol are known to have caused a fetal toxic syndrome in premature infants[11,12] and, therefore, we believe that Aristocort and Kenalog are also potentially toxic.

Parabens are the preservatives used in the Decadron vehicles, and all vehicles except Celestone Soluspan contain suspending agents. The potential toxicity of these agents is not clear.

EDTA, a known calcium chelating agent, is contained in the Celestone Soluspan, Decadron, and Decadron L.A. vehicles. This agent also has a detergent-like action,[13] and may be toxic or enhance the toxic effects of other preservatives by increasing tissue permeability.[14]

Commercial preparations of Decadron, Decadron L.A., and Aristocort were hyperosmotic

and Celstone Solupan was remarkably hypoosmotic. Prepared double-strength vehicles of Decadron and Aristocort were also hyperosmotic and osmometer measurements showed their osmolality to be 414 mOsm/kg and 410 mOsm/kg. Intravitreal injection of a hyperosmotic solution was proved to cause retinal detachment in rabbit eyes, and the minimum osmolality needed to cause retinal detachment was 500 mOsm/kg.[15] Small localized serous retinal detachments were indeed detected after the injection of sodium chloride solution with an osmolality of 411 mOsm/kg, but this change was much less than the ones observed with the actual vehicles. Thus, the hyperosmolality of the vehicle may exaggerate the toxic effect, but it should not be the only cause of retinal damage after the Decadron double-strength vehicle injection. The hypoosmolality of Celestone Soluspan (175 mOsm/kg) may be another factor in the apparant intraocular toxicity of this preparation.

These experiments suggest an explanation for the seeming paradoxic effect of intraocularly injected depot corticosteroids in human eyes. Although the corticosteroid itself should reduce or even prevent intraocular proliferation,[3,4] development of a pattern resembling proliferative vitreoretinopathy occurred. We suspect that the vehicles cause retinal necrosis with resulting reparative glial proliferation. This explains the extreme adhesiveness of the preretinal tissue during attempts to peel these membranes from the retina and also the thinness of and the retinal holes in the retina, corresponding to the experimental findings after Celestone Soluspan injection. Other eyes have survived such injections. In these cases, the injection may have occurred more in the central vitreous cavity and the vehicles in the corticosteroid were probably diluted by the intraocular fluids before they could damage the retina.

Experimental intravitreal injections of slowly dissolving corticosteroids have shown significant inhibition of intraocular proliferation[3,4] and reduction of the inflammation from endophthalmitis.[16] If we want to make use of these desirable preparations and avoid potential disasters in their periocular application, the manufacturer should try to find appropriate vehicles to make these drugs safer. At present, we are compelled to alert ophthalmologists and manufacturers to the potential toxicity of vehicles in the intraocular use of these depot corticosteroids.

References

1. McCuen, B. W., II, Bessler, M., Tano, Y., Chandler, D., and Machemer, R.: The lack of toxicity of intravitreal triamcinolone acetonide. Am. J. Ophthalmol. 91:785, 1981.
2. Schlaegel, T. F., Jr., and Wilson, F. M.: Accidental intraocular injection of depot corticosteroids. Trans. Am. Acad. Ophthalmol. Otolaryngol. 78:847, 1974.
3. Tano, Y., Sugita, G., Abrams, G., and Machemer, R.: Inhibition of intraocular proliferations with intravitreal corticosteroids. Am. J. Ophthalmol. 89:131, 1980.
4. Tano, Y., Chandler, D., and Machemer, R: Treatment of intraocular proliferation with intravitreal injection of triamcinolone acetonide. Am. J. Ophthalmol. 90:810, 1980.
5. Giles, C. L.: Bulbar perforation during periocular injection of corticosteroids. Am. J. Ophthalmol. 77:438, 1974.
6. McLean, E. B.: Inadvertent injection of corticosteroid into the choroidal vasculature. Am. J. Ophthalmol. 80:835, 1975.
7. O'Connor, G. R.: Periocular corticosteroid injections. Use and abuses. Eye Ear Nose Throat Monthly 55:83, 1976.
8. Zinn, K. M.: Iatrogenic intraocular injection of depot corticosteroid and its surgical removal using the pars plana approach. Ophthalmology 88:13, 1981.
9. Burstein, N. L.: Corneal cytotoxicity of topically applied drugs, vehicles and preservatives. Surv. Ophthalmol. 25:15, 1980.
10. Green, K., Hull, D. S., Vaughn, E. D., Malizia, A. A., Jr., and Bowman, K.: Rabbit endothelial response to ophthalmic preservatives. Arch. Ophthalmol. 95:2218, 1977.
11. Gershanik, J. J., Boecler, B., George, W., Sola, A., Leitner, M., and Kapadia, C.: The grasping syndrome. Benzyl alcohol (BA) poisoning? Clin. Res. 29:895A, 1981.
12. Brown, W.J., Buist, N.R.M., Cory Gipson, H.T., Huston, R. K., and Kennaway, N. G.: Fetal benzyl alcohol poisoning in a neonatal intensive care unit. Lancet 1:1250, 1982.
13. Mullen, W., Shepherd, W., and Labovitz, J.: Ophthalmic preservatives and vehicles. Surv. Ophthalmol. 17:469, 1973.
14. Grass, G. M., Wood, R. W., and Robinson, J. R.: Effects of calcium chelating agents on corneal permeability. Invest. Ophthalmol. Vis. Sci. 26:110, 1985.
15. Marmor, M. F.: Retinal detachment from hyperosmotic intravitreal injection. Invest. Ophthalmol. Vis Sci. 18:1237, 1979.
16. Grahman, R.O., and Peyman, G. A.: Intravitreal injection of dexamethasone. Treatment of experimentally induced endophthalmitis. Arch. Ophthalmol. 92:149, 1974.