Downloaded from http://journals.lww.com/retinajournal by BhDMf5ePHKav1zEoum1tQfN4a+kJLhEZgbsIHo4XMi0hCywCX1AWnYQp/IlQrHD3i3D0OdRyi7TvSFl4Cf3VC4/OAVpDDa8KKGKV0Ymy+78= on 09/03/2024

INTRAVITREAL TRIAMCINOLONE ACETONIDE IN EXUDATIVE AGE-RELATED MACULAR DEGENERATION

RONALD P. DANIS, MD, THOMAS A. CIULLA, MD,
LINDA M. PRATT, RN, WAYNE ANLIKER, MD

Purpose: To examine the effects of intravitreal injection of 4.0 mg triamcinolone acetonide on the visual and clinical course of exudative age-related macular degeneration.

Methods: A randomized clinical trial of a single injection of triamcinolone acetonide into the vitreous cavity of experimental eyes at baseline versus observation of untreated subjects was performed in 27 patients followed up for 6 months. Inclusion criteria included exudative age-related macular degeneration with subfoveal or occult choroidal neovascularization, and visual acuity between 20/40 and 20/400. Examination, acuity assessment, fundus photography, and fluorescein angiography were performed at baseline and at 3 and 6 months after enrollment. LogMAR visual acuity was compared between groups by a repeated measures analysis of variance model. Masked assessment of photographic studies was performed and groups were compared with Fisher's exact test.

Results: Visual acuity was significantly better in the treated group compared with control subjects at 3 and 6 months ($P < 0.005$). Fundus photography and angiography were more likely to show stability or improvement at 3 and 6 months in the treated group ($P = 0.05$). Intraocular pressure elevation was seen in 25% of treated patients, but was controlled with topical medications. Progression of cataract was more frequently seen in the treated group.

Conclusions: Intravitreal triamcinolone acetonide may provide short-term improvement in visual acuity and fundus findings in exudative macular degeneration. These findings must be considered preliminary and should be followed by multicenter, masked, placebo-controlled trials with long-term follow-up.

RETINA 20:244–250, 2000

Exudative age-related macular degeneration (ARMD) is a highly prevalent and devastating cause of severe vision loss. Unfortunately, argon or krypton laser photocoagulation, of proven benefit in multicenter, randomized clinical trials,[1] is helpful in a small proportion of cases (5–14%) who present with entirely well-delineated lesions less than 2 disk areas in size. Most patients present with poorly delineated (occult) or subfoveal neovascularization that is unsuitable for laser photocoagulation. A more recent option of at least short-term benefit in patients with exudative ARMD who have lesions featuring primarily classic subfoveal neovascularization is photodynamic therapy,[2] which greatly increases the proportion of lesions amenable to treatment. It is clear that this therapy is a relatively expensive option and its role in the manage-

From the Department of Ophthalmology, Indiana University School of Medicine, Indianapolis.

Supported in part by an unrestricted grant from Research to Prevent Blindness, Inc., New York, New York. T.A.C. is a recipient of a Career Development Award from Research to Prevent Blindness, Inc.

Presented in part at the 1999 annual meeting of the Association for Research in Vision and Ophthalmology; May 10, 1999; Fort Lauderdale, Florida.

The authors have no proprietary interest.

Reprint requests: Ronald P. Danis, MD, Indiana University Medical Center, 702 Rotary Circle, Indianapolis, IN 46202.

1 FORMYCON-1060

Table 1. Subject Characteristics

Subject No.	Age, yr	Sex	logMAR Baseline	logMAR 3 mo	logMAR 6 mo	Cataract Progression	IOP Meds
Control							
1	57	M	0.3	0.2	0.3	No	No
2	68	M	0.8	0.7	0.9	No	No
3	69	F	0.6	0.9	1.0	1+ to 1.5+	No
4	62	F	0.6	1.8	1.8	No	No
5	73	F	0.4	0.4	0.7	No	No
6	70	F	0.4	0.2	0.3	1.5+ to 2+	No
7	86	M	0.4	1.1	1.1	IOL	No
8	73	M	0.7	1.1	1.3	IOL	No
9	75	M	0.8	2.1	2.4	No	No
10	74	M	1.1	1.1	1.1	No	No
11	79	M	1.1	1.1	0.8	No	No
Treated							
1	69	F	0.5	0.4	0.4	IOL	No
2	76	F	0.7	0.4	0.4	IOL	No
3	72	F	0.7	0.8	0.9	2+ to 2.5+	No
4	85	F	0.9	0.9	1.1	IOL	Yes
5	49	M	1.0	1.0	1.0	No	Yes
6	96	M	1.0	1.4	1.4	IOL	No
7	75	M	1.0	0.8	0.7	No	No
8	69	M	0.3	0.2	0.5	2+ to 2.5+	No
9	71	F	0.3	0.2	0.1	2+ to 2.5+	Yes
10	70	M	0.4	0.4	0.1	IOL	No
11	87	F	0.5	1.1	0.8	APH	No
12	86	F	1.3	1.3	1.3	IOL	No
13	78	F	1.1	1.0	1.2	IOL	No
14	81	F	1.3	0.9	0.6	No	Yes
15	64	F	0.7	0.1	1.0	1+ to 2+	No
16	76	F	0.5	0.2	0.1	No	No

Cataract progression, worsening of cataract at any time during follow-up, numeric score 1+ (clear) to 4+ (very dense); IOP meds, topical ocular antihypertensive agents added for intraocular pressure greater than 25 mmHg; IOL, intraocular lens implant after previous cataract extraction; APH, aphakic after previous cataract extraction.

ment of exudative ARMD is being clarified with further study.

Triamcinolone acetonide (TAAC) is a potent, relatively insoluble steroid that has been used for treatment of ocular inflammation by peribulbar or sub-Tenon's injection for decades.[3] The toxicity and pharmacokinetics of intravitreal TAAC injection have been investigated in animal studies.[4–6] Many corticosteroids, including TAAC, have been shown to be effective inhibitors of neovascularization in animal models,[7–9] and as a class are among the most potent antiangiogenic agents known.[10] The mechanism of action of steroid angioinhibition has been characterized as due to an effect on vascular endothelial cell extracellular matrix turnover[10] as well as inhibition of inflammatory cells, which invariably participate in a neovascular response.[11,12]

Penfold et al[13] and Challa et al[14] reported a small, uncontrolled clinical trial of TAAC in exudative ARMD in which intravitreal TAAC injection appeared to be well-tolerated, with a favorable effect on the course of the disease over an 18-month period. In the current study, we randomly assigned patients with exudative ARMD unsuitable for laser therapy to either intravitreal TAAC or observation and monitored the eyes clinically and photographically over a 6-month period.

Patients and Methods

Thirty patients with visual symptoms of 6 months or less duration and a diagnosis of exudative ARMD were randomly assigned by lottery to treatment or observation. Patients had baseline visual acuity (VA) between 20/40 and 20/400 (logMAR 0.3–1.3) measured on a front-lit Bailey-Lovie chart at 10 feet with 125 foot-candles of illumination, lack of significant media opacity, and signs of exudative ARMD (such as subretinal fluid, subretinal hemorrhage, or retinal pigment epithelium detachment associated with confirmatory leakage consistent with choroidal neovascularization on fluorescein angiography). The choroidal

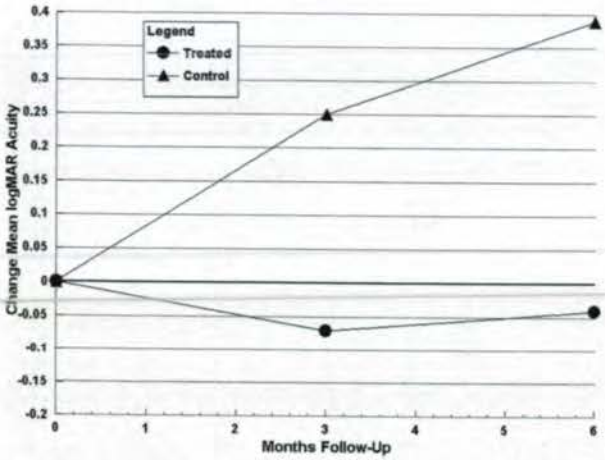

Fig. 1. Mean change from baseline logMAR acuity over the 6-month study duration.

neovascular membranes were all subfoveal and were not amenable to laser photocoagulation either because of occult components or because the patient refused treatment. Patients with a history of glaucoma or ocular hypertension, applanation tension greater than 22 on baseline examination, or glaucomatous optic nerve cupping were excluded. At each follow-up visit, VA was assessed by technicians not associated with the study. Lens grading was performed according to the procedures of the Age-Related Eye Disease Study, and fundus examination, photography, and fluorescein angiography were also performed. The procedures and protocol were approved by the Indiana University–Purdue University, Indianapolis Institutional Review Board and informed consent was obtained.

Patients randomly assigned to treatment were given several drops of topical proparacaine, followed by a drop of 5% betadine. Each patient was reclined slightly in the examining chair and asked to gaze upward. Stabilizing the lids with the nondominant hand, the injection was performed using a 30-gauge needle on a 1-mL syringe. The injection consisted of 0.1 mL of a commercially available suspension of TAAC (Kenalog 40 mg/mL, Schering-Plough; Kenilworth, NJ) and the needle penetrated through the 6 o'clock pars plana (approximately 4 mm from the limbus). The needle was introduced only 2 to 3 mm into the eye in an effort to keep the suspension in the inferior vitreous region, out of the visual axis. Because the needle shaft penetrated a short distance into the eye, it was not visualized during injection. After slow injection (3 or 4 seconds), the fundus was visualized by slit-lamp biomicroscopy until retinal circulation was reestablished. Patients who received injections were asked to return for weekly assessment of intraocular pressure (IOP) for at least the first 4 weeks after injection and were treated with topical antiglaucoma medications if the IOP became elevated over 25 mmHg.

Sixteen patients were randomly assigned to treatment and 14 to observation. All patients were asked to return at 3-month intervals for complete ocular examination, VA assessment, and fluorescein angiography. Acuity was expressed at each visit as logMAR. Of the 14 patients assigned to observation, 3 failed to appear for the 3-month visit and were excluded from analysis. Difference from baseline logMAR value was calculated for each subject and these differences were analyzed via a repeated measurements analysis of variance model.

Independent masked analysis of fundus photographs and fluorescein angiograms obtained at each visit were performed by two of the authors (T.A.C. and R.P.D.). Fundus photographs and angiograms were presented in chronological order, and Macular Photocoagulation Study rings as overlays were used to estimate the borders of lesions and possible changes. Cases were judged to be improved, worse, or stable at each visit relative to baseline. Studies were improved if there was decreased hemorrhage and subretinal fluid exudation and no worsening or an improvement (decrease) in fluorescein leakage with a total neovascular lesion area no larger than at baseline. Stable lesions were those with continuing evolution of the exudative process without remarkable increase in neovascular lesion size. For example, studies showing replacement of subretinal fluid and hemorrhage with subretinal fibrosis were considered stable if the area of the neovascular lesion was unchanged. The lesion was considered worse if the lesion increased in size, whether exudative signs were present or not. Lesion size was estimated from both fundus photographs and fluorescein angiograms for each visit, and an increase in extent of the lesion by more than 250 μm in any

Table 2. Masked Assessment of Fundus Photographs and Fluorescein Angiograms at Each Study Visit

	3 mo				6 mo			
Group	Improved	Stable	Worse	Total	Improved	Stable	Worse	Total
Treated	9	5	2	16	4	7	5	16
Control	1	4	5	10	1	2	7	10

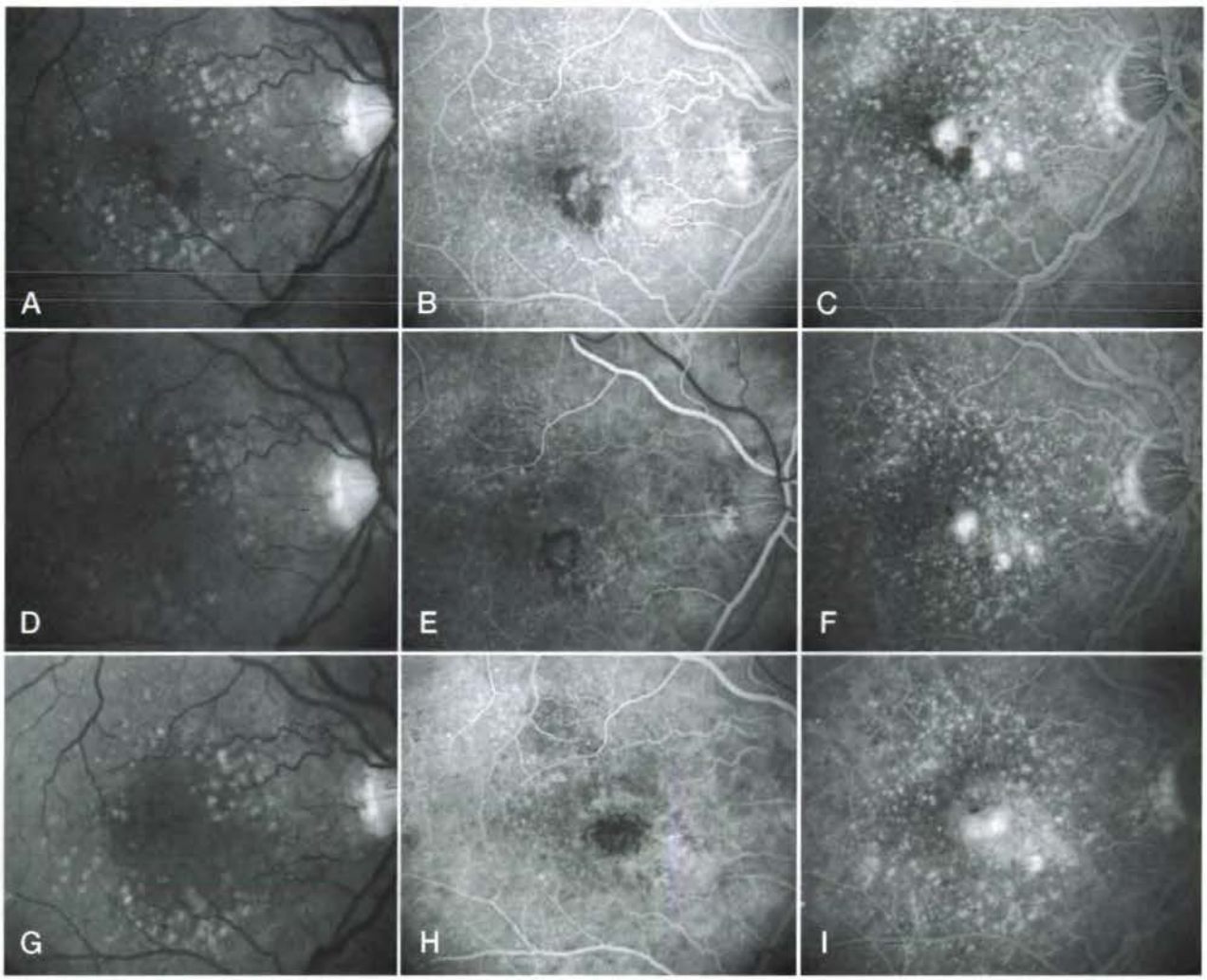

Fig. 2. Fluorescein angiography of treated Patient 1. **A–C**, Red-free image, early and late phase fluorescein angiography frames. At baseline, visual acuity (VA) was logMAR 0.5 (20/60 Snellen equivalent), and a subfoveal choroidal neovascular membrane with associated subretinal blood was noted. The patient declined laser photocoagulation. **D–F**, Three months after injection, VA logMAR 0.4 (20/50) and the angiogram and fundus photos were judged to be improved, due to stability in the size of the lesion and less subretinal blood (also, less subretinal fluid was seen on stereo fundus photography). **G–I**, Six months after injection, VA remained logMAR 0.4 (20/50), but the angiogram was graded as worse due to the slightly increased size of the neovascular membrane compared with the baseline study.

dimension was considered significant. Differences in interpretation were then resolved between the observers by direct discussion. The proportion of visits in which imaging showed macular lesions to be improved or stable versus worse were compared in each group by Fisher's exact test.

Results

The baseline age, sex, and VA of patients are presented in Table 1. Patients receiving injections reported minimal discomfort with the procedure, occasional transient dimming of vision (due to elevated IOP immediately after injection and temporary compromise of retinal circulation), and onset of floaters due to the suspension in the vitreous. No patient required paracentesis to restore retinal circulation within 10 minutes. No patient remarked that the floaters were objectionable or significantly interfered with vision. Four of seven phakic treated patients developed progressive lens opacity and four treated patients required topical ocular antihypertensive therapy for IOP elevation (Table 1). No patient had an IOP measurement over 32 mmHg and IOP was controlled (to <25 mmHg) using one or two ocular antihypertensive topical agents, which were eventually discontinued in all patients. No other complications of treatment were documented.

Baseline acuities were similar between groups (mean logMAR score 0.72 in controls and 0.76 in

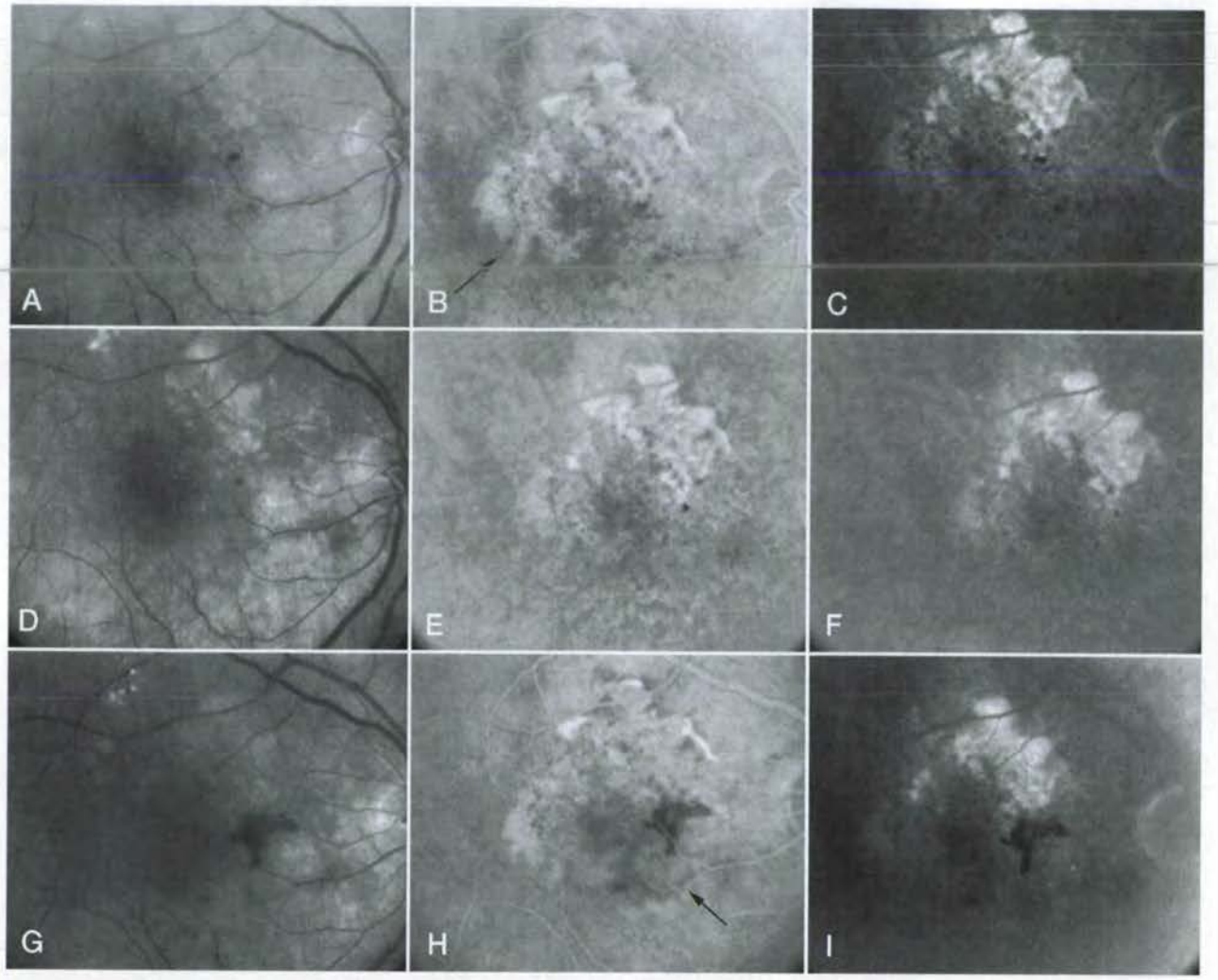

Fig. 3. Fluorescein angiography of treated Patient 9. **A–C**, At baseline, visual acuity was logMAR 0.3 (20/40 Snellen equivalent), and angiography demonstrates a choroidal neovascular membrane with a subfoveal occult component (arrow) and a fleck of subretinal hemorrhage. **D–F**, At 3 months, the acuity was logMAR 0.2 (20/32) and the angiogram was judged to be improved because of stability of the neovascular membrane and less subretinal blood. The stereo fundus photographs also showed less subretinal fluid. **G–I**, At 6 months, acuity was logMAR 0.1 (20/20) but the angiogram was worse due to increased leakage and probable extension of the occult neovascularization in the inferonasal area (arrow).

treated, approximately 20/100 Snellen equivalent). The overall trend for better acuity in the treatment group compared with the control group was significant ($P < 0.005$). At 6 months, the mean acuity was 0.39 logMAR units worse than baseline in the control group, and had improved 0.04 units in the treatment group (Figure 1). Relative to baseline, treated patients had improved mean acuities at 3 and 6 months, but this was not statistically significant. Conversely, the control patients had worse vision compared with baseline at 3 and 6 months ($P < 0.05$). Because few patients were available for analysis after 6 months, late results (at 9 and 12 months) could not be adequately compared between groups.

Assessment of fundus photography and fluorescein angiography is summarized in Table 2. One patient in the control group had ungradable photographs and angiograms at 3 months and was excluded from analysis. At the 3-month visit, more subjects were rated stable or improved in the treated than in the observation group (87.5% versus 50%, $P = 0.05$). At the 6-month visit, the proportion of treated patients with stable or improved lesions was still greater, although the proportion had declined (69% versus 29%, $P = 0.05$). Despite improved acuities, some patients manifested a worsened angiographic exudative ARMD appearance (Figures 2–4).

Discussion

This single-center pilot study demonstrated the potential short-term benefit on VA in exudative ARMD

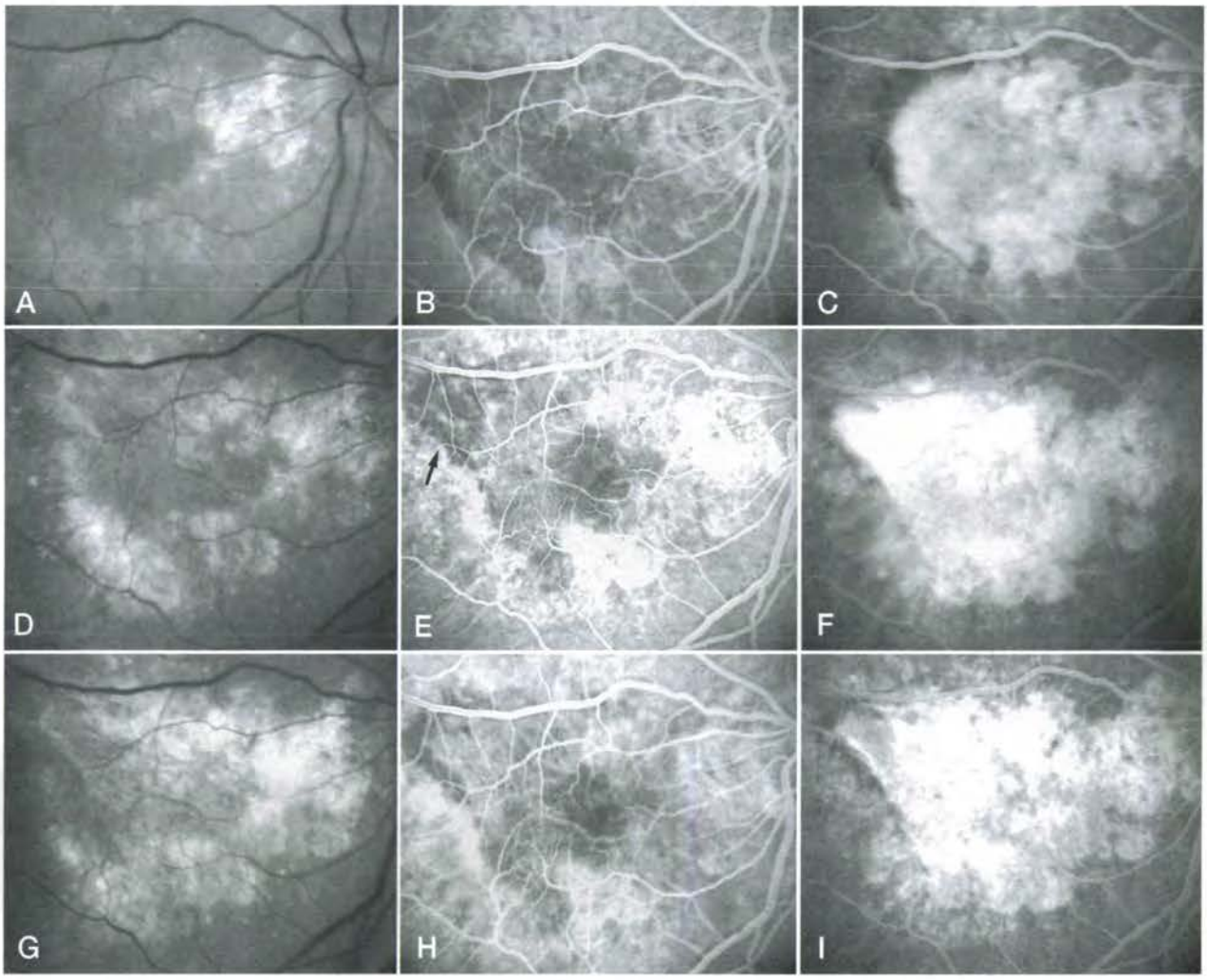

Fig. 4. Fluorescein angiogram of treated Patient 14. **A–C**, At baseline, a large subfoveal choroidal neovascular membrane occupies the central macula and acuity measured logMAR 1.3 (12/200 Snellen equivalent). **D–F**. At 3 months, the angiogram was judged worse due to extension of the neovascularization superotemporally (arrow) but visual acuity had improved to logMAR 0.9 (20/160). Subretinal fluid appeared to have decreased on stereo fundus photography. **G–I**, At 6 months, the acuity had improved to logMAR 0.6 (20/80) but the angiogram was still evaluated as worse than baseline.

of a single 4-mg intravitreal injection of TAAC. In the first 6 months after injection, mean acuity in the treatment group was not significantly different from baseline. This result is in stark contrast to the observation group, which inexorably worsened over this time. Several caveats must be entertained in the consideration of these results. The lack of masked assessment of acuity may bias results, although acuity was measured by a technician unrelated to the project. It was not considered humane or ethical to subject the control group to sham control intravitreal injection because of the obvious stress and risks involved, thereby allowing for possible placebo effect in the treated group. Also, this study would benefit from objective quantitative analysis of fluorescein angiography and fundus photography. However, there is no established method for quantifying the severity of exudative lesions from such studies; hence, masked semiquantitative assessment of these studies was employed.

Finally, the proportion of patients with angiograms demonstrating worsening of the signs of exudative ARMD in the treatment group increased between 3 months and 6 months, raising the possibility that this treatment (a single injection) may have little or no long-term effect on the natural history of the disease. We believe there is a short-term beneficial effect on VA deterioration in these patients due to reduced exudation from the neovascular membrane with less subretinal fluid. There is probably a temporary cessation in the growth of the neovascular membrane in some patients. However, continued growth of the neo-

vascular membranes in patients with early improved VA (Figures 2–4) would portend a likely eventual deterioration of benefits. The study by Challa et al[14] appears to demonstrate a sustained benefit from a single injection over the 18-month follow-up period. This result needs to be clarified with further long-term study and also raises the possibility that periodic reinjection may be helpful in maintaining visual function.

The only other published study to examine intravitreal TAAC in the treatment of exudative ARMD was not a randomized trial.[13,14] The incidence of complications from one or more TAAC injections was similarly low in that study of 30 eyes: only 4 required treatment for elevated IOP and only 6 patients exhibited progressive lens opacity. The authors concluded that the course of vision loss in this cohort was more benign than would be expected from natural history, because 3 of 10 patients with acuity of 3/60 or worse had improved acuity of at least 5 lines and 55% with acuity better than 3/60 at baseline remained stable over long-term follow-up of 18 months. We also noted several patients with marked improvement in acuity; treated Patients 2, 7, 10, 14, 15, and 16 had a 0.3 log unit or more improvement in acuity, versus none in the control group (Table 1), and 9 of the remaining 11 patients in the treatment group remained within 0.2 log units of baseline during the 6-month period, versus 5 of 11 in the control group.

We employed the same dose of TAAC as the previous study, both because this is a convenient aliquot to inject from commercial preparations and because the prior study did not demonstrate significant toxicity from this dose. More sophisticated steroid derivatives with antiangiogenic but little or no glucomineralocorticoid activity might conceivably avoid the lens opacities and IOP elevations noted with intravitreal injection of TAAC at this dose, which is well below the maximal tolerance of the retina, based on animal work.[4–6] The principal preservatives in the preparation used were small amounts of benzyl alcohol and polysorbate 80. No clinical data could be found on intraocular toxicity of these agents in the Medline and Toxlit databases of the National Library of Medicine; however, these agents are widely used in injectable and systemic pharmaceuticals and have extremely low local and systemic toxicity. A 0.4-mg dose of TAAC in the rabbit vitreous produces detectable vitreous levels of drug up to 3 weeks after injection,[5] but the duration of detectable drug levels from a 4-mg injection into the human vitreous cavity is unknown.

Future clinical studies of intravitreal TAAC for neovascular complications should be in the context of multicenter trials with masked acuity assessment and long-term follow-up. It is possible that this drug may have a beneficial role as an adjunctive agent combined with laser photocoagulation, photodynamic therapy, or another angiostatic treatment. Protocols involving periodic reinjection might be evaluated if the beneficial effects on VA are not sustained.

Key words: choroidal neovascularization, macular degeneration, angiogenesis inhibition, triamcinolone acetonide.

References

1. Macular Photocoagulation Study Group. Argon laser photocoagulation for neovascular maculopathy: three-year results from randomized clinical trials. Arch Ophthalmol 1986;104:694–701.
2. TAP Study Group. Photodynamic therapy of subfoveal choroidal neovascularization in age-related macular degeneration with verteporfin. Arch Ophthalmol 1999;117:1329–1345.
3. Schlaegel TF. Ocular Histoplasmosis. New York: Grune & Stratton, 1977.
4. Schindler RH, Chandler D, Thresher R, Machemer R. The clearance of intravitreal triamcinolone acetonide. Am J Ophthalmol 1982;93:415–417.
5. Scholes GN, O'Brien WJ, Abrams GW, Kubicek MF. Clearance of triamcinolone from vitreous. Arch Ophthalmol 1985; 103:1567–1569.
6. McCuen BWD, Bessler M, Tano Y, Chandler D, Machemer R. The lack of toxicity of intravitreally administered triamcinolone acetonide. Am J Ophthalmol 1981;91:785–788.
7. Danis RP, Bingaman DP, Yang Y, Ladd L. Inhibition of preretinal and optic nerve head neovascularization in pigs by intravitreal triamcinolone acetonide. Ophthalmology 1996;103:2099–2104.
8. Tano Y, Chandler D, Machemer R. Treatment of intraocular proliferation with intravitreal injection of triamcinolone acetonide. Am J Ophthalmol 1980;90:810–816.
9. Antoszyk AN, Gottlieb JL, Machemer R, Hatchell D. The effects of intravitreal triamcinolone acetonide on experimental pre-retinal neovascularization. Graefes Arch Clin Exp Ophthalmol 1993;231:34–40.
10. Folkman J, Ingber D. Angiostatic steroids. Ann Surg 1987; 206:374–382.
11. Proia A, Hirakata A, McInnes J, Scroggs M, Parikh I. The effect of angiostatic steroids and B-cyclodextrin tetradecasulfate on corneal neovascularization in the rat. Exp Eye Res 1993;57:693–698.
12. Oh H, Takagi H, Takagi T, et al. The potential angiogenic role of macrophages in the formation of choroidal neovascular membranes. Invest Ophthalmol Vis Sci 1999;40:1891–1898.
13. Penfold P, Gyory J, Hunyor A, Billson F. Exudative macular degeneration and intravitreal triamcinolone: a pilot study. Aust NZ J Ophthalmol 1995;23:293–298.
14. Challa JK, Gillies MC, Penfold PL, Gyory JF, Hunyor AB, Billson FA. Exudative macular degeneration and intravitreal triamcinolone: 18-month follow up. Aust NZ J Ophthalmol 1998;26:277–281.