Check for updates

Clinical and Experimental Ophthalmology (2001) **29**, 2–6

Original Article

Safety and efficacy of intravitreal triamcinolone for cystoid macular oedema in uveitis

Stephanie Young FRACO, Genevieve Larkin FRCS, Michael Branley FRACO and Susan Lightman PhD FRCOphth
Department of Clinical Ophthalmology, Institute of Ophthalmology, Moorfields Eye Hospital, London, UK

Abstract

Purpose: To report the safety and efficacy of intravitreal triamcinolone in the treatment of inflammatory cystoid macular oedema (CMO) in six patients who were resistant to other forms of therapy.

Methods: An open-label unmasked prospective non-randomized pilot study of six patients with idiopathic uveitis and visually significant macular oedema, resistant to periocular and/or systemic corticosteroid treatment, was carried out. Baseline examination and investigations were performed, including fundus fluorescein angiography, and the patients were given a single intravitreal injection of triamcinolone (4 mg/0.1 mL). The primary outcome measure was angiographic resolution of CMO. Patients were reviewed at intervals of 2–4 weeks for 12 months.

Results: A single intravitreal injection of triamcinolone induced clinical and angiographic resolution of inflammatory macular oedema in all patients for varying periods of time up to 6 months. Five patients experienced increased intraocular pressure to 30 mmHg or greater which required treatment. Two patients developed posterior subcapsular cataract.

Conclusion: One injection of intravitreal triamcinolone was an effective short-term treatment for resistant CMO in uveitis. As with steroids given by other routes, raised intraocular pressure and cataract may occur. As it was so effective in these eyes with resistant CMO, a larger study is warranted to evaluate this form of therapy.

Key words: macular oedema, steroids, triamcinolone, uveitis.

Introduction

Chronic cystoid macular oedema (CMO) is an important cause of visual loss in uveitis[1] and it may be resistant to treatment. Corticosteroids given either periocularly or systemically are the mainstay of treatment, together with other immunosuppressive agents such as cyclosporin where steroids alone are not effective.[2] When conventional treatment fails, vitrectomy may occasionally be of help in the younger patient,[3] but otherwise the condition is essentially untreatable. Intravitreal triamcinolone may be effective in the management of exudative macular degeneration in the older patient and result in the flattening of the detachment.[4] We therefore decided to use it in patients with chronic uveitis and CMO in whom other conventional modes of therapy had failed. In the present study, we report an open-label unmasked non-randomized prospective pilot study of the safety and efficacy of intravitreal triamcinolone given for inflammatory CMO in quiet eyes in six patients who were resistant to other forms of therapy.

Methods

Patients

Patients were recruited from a single institution for treatment without randomization. All had the experimental nature of the study explained to them and gave informed consent. The study had the approval of the Ethics Committee of Moorfields Eye Hospital and patients were recruited from the uveitis clinic (by author S Lightman).

The inclusion criteria were chronic uveitis and visually significant CMO of 6 or more months' duration which was resistant to systemic and/or periocular corticosteroid treatment and additional treatment with cyclosporin where possible. In all patients the best corrected visual acuity was 6/18 or less. Patients were excluded if they had received orbital steroid depots (depomedrone) within the previous 3 months or if their systemic maintenance medication was altered within 3 months preceding or following the injection.

Six patients were recruited with visually significant CMO. All had idiopathic uveitis (intermediate or posterior) without known systemic associations and with no significant findings on investigation. In all patients, the CMO was

■ *Correspondence:* Professor Susan Lightman, Department of Clinical Ophthalmology, Institute of Ophthalmology, Moorfields Eye Hospital, City Road, London EC1V 2PD, UK. Email: s.lightman@ucl.ac.uk

FORMYCON-1061

Table 1. Patient characteristics

Patient	Age (years)	Diagnosis	Duration of unresponsive CMO (months)	Periocular injections	Oral steroid course	Other treatment	Postinjection follow up (months)
1	48	Intermediate uveitis	6	× 2	5 years	Cyclosporin A	20
2	57	Idiopathic posterior uveitis	6	× 2	6 weeks	Nil	18
3	25	Intermediate uveitis	9	× 2	Refused	Nil	18
4	23	Intermediate uveitis	12	× 2	4 years	Cyclosporin A Mycophenylate	16
5	28	Intermediate uveitis	48	× 2	5 months	Cyclosporin A	15
6	38	Intermediate uveitis	7	× 3	2 years	Cyclosporin A	15

Table 2. Effect of intravitreal triamcinolone on visual acuity, intraocular pressure and cystoid macular oedema

Patient	Parameter	Baseline	1 month	3 months	6 months	12 months
1	VA	6/18	6/9	6/12	6/18	6/18
	IOP (mmHg)	9	16	18	14	14
	CMO	+	–	+	+	+
2	VA	6/18	6/9	6/9	6/12	6/18
	IOP (mmHg)	15	25	30	17*	16
	CMO	+	–	–	+	+
3	VA	6/18	6/9	6/9	6/6	6/36
	IOP (mmHg)	16	32	26†	24†	20
	CMO	+	–	–	–	?
4	VA	6/24	6/9	6/9	6/18	6/24
	IOP (mmHg)	10	22	34	20‡	13
	CMO	+	+	–	+	+
5	VA	6/24	6/18	6/12	6/24	6/24
	IOP (mmHg)	8	20	30‡	17	18
	CMO	+	+	–	+	+
6	VA	<6/60	6/12	6/9	6/18	6/60
	IOP (mmHg)	14	28	36§	12	14
	CMO	+	–	–	–	?

VA, visual acuity (Snellen); IOP, intraocular pressure; CMO, cystoid macular oedema.

*Using dorzolamide t.i.d.; †using dorzolamide and brimonidine tartrate b.i.d.; ‡using levobunolol hydrochloride b.i.d.; §using dorzolamide t.i.d., brimonidine tartrate b.i.d. and latanoprost nocte. +, CMO present; –, CMO absent; ?, inadequate view.

unresponsive to treatment with periocular corticosteroids and they had experienced no pressure rise after this type of treatment. Five had taken oral steroids (four in combination with another immunosuppressive agent) and had either no response (one patient) or had become resistant to therapy (four patients). None had previous steroid-induced ocular hypertension or cataract.

Procedure

Baseline clinical examination was performed, including best-corrected Snellen visual acuity (VA), biomicroscopy and standard fundus fluorescein angiography.

Each patient received a single intravitreal injection of triamcinolone acetate of 4 mg/0.1 mL (Kenalog; Bristol–Myers Squibb, Hounslow, Middlesex, UK) after topical amethocaine 1%, topical povidone-iodine 5% and mercury weight decompression. Injections were given via 30 gauge needles through the inferotemporal pars plana, 4 mm from the limbus. Intraocular pressure was checked following the injection and topical chloramphenicol was given for 1 week.

Patients were seen at 1 week and then at intervals of 2–4 weeks for 12 months. Fluorescein angiography was repeated at 1, 3 and 6 months. The primary outcome was angiographic resolution of CMO.

Results

The results are outlined in Tables 1 and 2. The procedure did not cause significant discomfort or any complications.

Clinical and angiographic resolution of CMO occurred in all cases. The median corrected VA prior to injection was 6/24. The postinjection median VA was 6/12 at 1 month and 6/9 at 3 months. Relapse of CMO occurred in one patient at 3 months (as demonstrated by angiography) and was present in four of the six patients by 6 months (also demonstrated by angiography). Secondary ocular hypertension in

14429071, 2001, 1, Downloaded from https://onlinelibrary.wiley.com/doi/10.1046/j.1442-9071.2001.00360.x by Vanderbilt University, Wiley Online Library on [03/09/2024]. See the Terms and Conditions (https://onlinelibrary.wiley.com/terms-and-conditions) on Wiley Online Library for rules of use; OA articles are governed by the applicable Creative Commons License

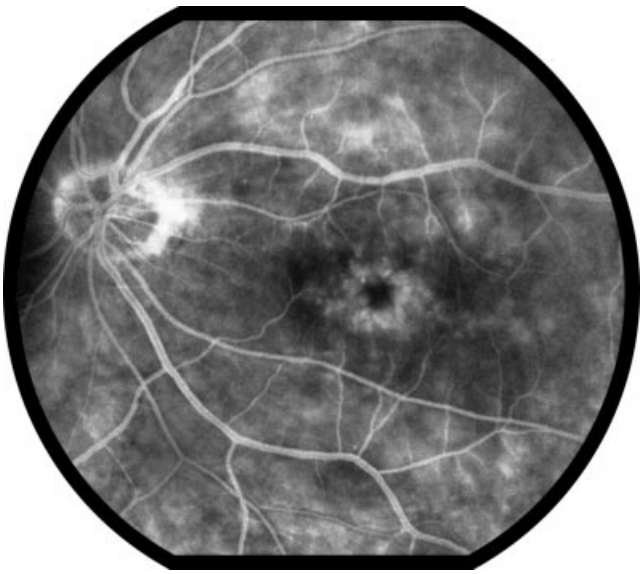

Figure 1. Fluorescein angiogram confirming cystoid macular oedema in case study 1.

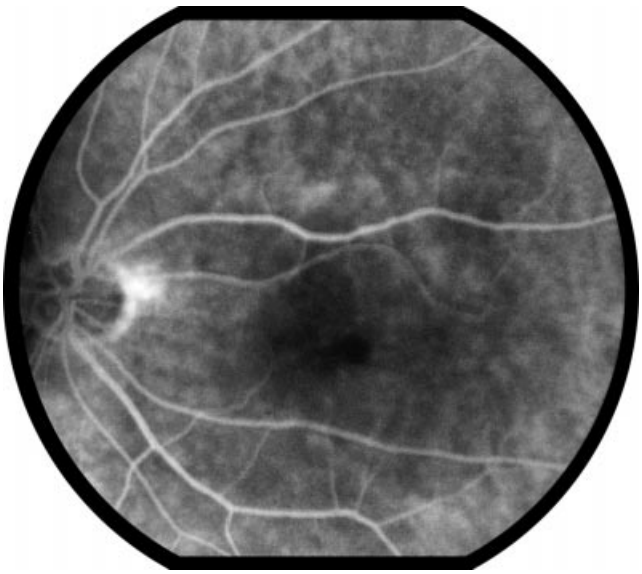

Figure 2. Fluorescein angiogram showing resolution of cystoid macular oedema after intravitreal injection of triamcinolone in case study 1.

the presence of open angles occurred in five of six patients (Table 2). These patients were treated when their intraocular pressure (IOP) reached 30 mmHg or more at a median time of 10 weeks postinjection (range 4–12 weeks). Patient 5 had a history of asthma, which contraindicated treatment with topical beta-blockers, and of renal calculi, which excluded acetazolamide. When his IOP was not controlled on maximal topical therapy, he required a trabeculectomy. One other patient required topical therapy for 10 weeks while three others ceased treatment as their IOP returned to baseline between 6 and 8 months after injection. No patients suffered glaucomatous field loss on automated visual field testing.

Patients 3 and 6 developed posterior subcapsular cataracts which were symptomatic 6 months following the injection and required surgery. Patient 6 had undergone trabeculectomy which would also contribute to cataract formation.

Case study 1

A 23-year-old white man was referred with a 4-year history of bilateral floaters and reduced VA. He had no relevant past medical history and presented to his local ophthalmologist with intermediate uveitis and CMO. No abnormalities were found on investigation. Visual acuity at that time was 6/24 bilaterally and he was treated with oral prednisolone commencing at 60 mg/day. Visual acuity improved to 6/12 and the steroid was gradually reduced to a base level of 12.5 mg/day, with resolution of CMO and VA stabilizing at 6/9. Over the next 2 years, exacerbations responded to temporary increases in oral prednisolone, although other immunosuppressive agents were required to minimize the maintenance dose. Initially, cyclosporin A was added (5 mg/kg per day reducing to 2 mg/kg per day) and later mycophenolate mofetil (1 g b.i.d.). He had intermittent left CMO managed with two additional orbital floor injections and two sub-Tenon's injections of depomedrone. He was referred when he failed to respond to increased systemic prednisolone and two further periorbital injections of depomedrone given 3 months apart.

Examination showed corrected VA to be 6/12 in the right eye and 6/24 in the left eye, and the intraocular pressures were 12 mmHg. The anterior segments were quiet bilaterally with few cells present in the vitreous. Cystoid macular oedema was present bilaterally but more marked in the left eye and was confirmed with fluorescein angiography (Fig. 1). No other features of disease activity were present. Intraocular triamcinolone was given to the worse left eye as described above. Over the next 4 weeks he had clinical and angiographic resolution of CMO in the left eye (Fig. 2) and VA improved to 6/12 remaining at this level for 4 months before falling to 6/18 at 6 months with return of CMO. At the 3 month review, IOP increased to 34 mmHg necessitating topical treatment with levobunolol hydrochloride, which was given for another 4 months. Twelve months following the injection his left VA was 6/24 with CMO and normal IOP on no topical medication. There was no change in automated perimetry compared with baseline.

Case study 2

A 38-year-old white man presented in February 1997 with a 6-week history of reduced left vision (VA 6/24), intermediate uveitis, optic disc oedema and macular oedema. His past medical history included asthma for which he used salbutamol and beclomethasone inhalers. Investigations including bronchoscopy and bronchiolar biopsy were negative and he was treated with two periorbital and one sub-Tenon's injection of corticosteroid without effect before

14429071, 2001, 1, Downloaded from https://onlinelibrary.wiley.com/doi/10.1046/j.1442-9071.2001.00360.x by Vanderbilt University, Wiley Online Library on [03/09/2024]. See the Terms and Conditions (https://onlinelibrary.wiley.com/terms-and-conditions) on Wiley Online Library for rules of use; OA articles are governed by the applicable Creative Commons License

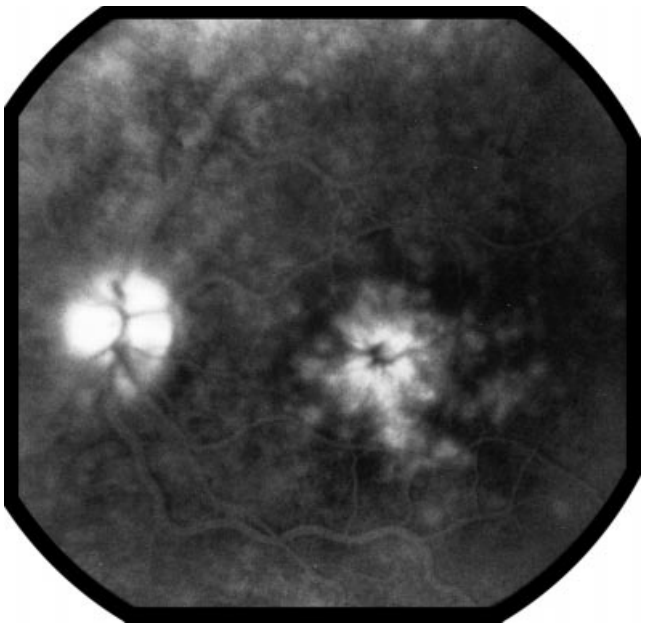

Figure 3. Fluorescein angiogram confirming cystoid macular oedema in case study 2.

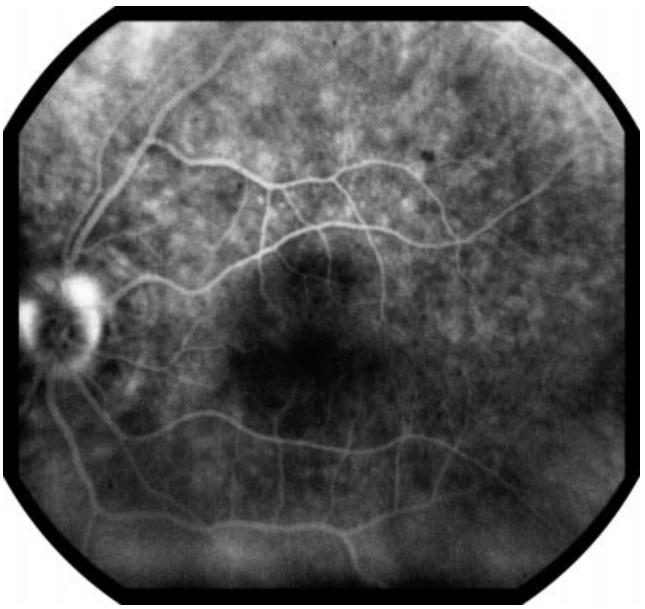

Figure 4. Fluorescein angiogram showing resolution of cystoid macular oedema after intravitreal injection of triamcinolone in case study 2.

responding to oral prednisolone. Over the following 2 years he required cyclosporin A in order to control inflammation on low oral doses of steroid but relapses became more frequent and did not respond to additional periocular steroid. Visual acuity in the left eye was less than 6/60 (right eye 6/6), the eye was quiet and CMO was confirmed on angiography (Fig. 3).

Informed consent was given for intravitreal triamcinolone. One month later the CMO had resolved completely (Fig. 4) and vision improved to 6/9 but he developed ocular hypertension (28 mmHg) which was treated with dorzolamide, brimonidine tartrate and latanoprost. His medical history of severe asthma contraindicated use of topical beta-blockers and of renal calculi excluded acetazolamide. When the pressure climbed to 50 mmHg 4 months after the injection he required trabeculectomy. Six months following the injection he had no CMO on fluorescein angiography. His vision, however, had deteriorated to 6/18 due to posterior subcapsular cataract (in part likely to be related to the trabeculectomy) although his IOP was normal without treatment. Automated perimetry did not show a glaucomatous defect. By 12 months postinjection the visual acuity had fallen to 6/60 and fundus examination was limited by posterior subcapsular cataract requiring surgery.

Discussion

Macular oedema is a major cause of severe visual impairment in ocular inflammatory disease.[1] It accounts for poor vision not only during the active phase of various types of uveitis but over prolonged periods may cause permanent macular damage.[5] It is often responsive to corticosteroids, either systemically or via the orbital floor[6] or sub-Tenon's route,[7] although additional immunosuppression may be necessary.[8] Inflammatory macular oedema has also been treated with acetazolamide,[9–11] macular grid photocoagulation[12] and pars plana vitrectomy[3] but the results have not been encouraging. Long-term management is frequently a difficult balance of efficacy and safety and macular oedema may become resistant to treatment.

Local treatment is particularly attractive in patients who have isolated ocular disease, especially unilateral, as it has the potential to avoid unwanted systemic side-effects. Intravitreal injection has become an acceptable method of delivering antibiotic agents in severe ocular infections.[13,14] Dexamethasone has also been used in this setting but its effect is thought to be short-lived[15] while triamcinolone, which has a longer duration of action, was well tolerated when used to treat exudative macular degeneration.[4]

In the six patients studied, intravitreal triamcinolone (4 mg/0.1 mL) was an effective treatment for inflammatory macular oedema with clinical and angiographic resolution evident in all patients by 6 weeks (range 2–6 weeks). Improvement in visual acuity occurred with at least two Snellen lines gained. Two patients had no CMO at 6 months. In the four whose macular oedema recurred, median duration of effect was 8 weeks (range 6–10 weeks). Intravitreal triamcinolone induced ocular hypertension in five of the six patients (increases of 15–22 mmHg above baseline) and represents a serious potential risk. Although no patient suffered glaucomatous visual field loss, one patient was intolerant to beta-blockers and acetazolamide necessitating filtration surgery. In a report by Challa *et al.* secondary ocular hypertension was observed in only one of 26 eyes (24 patients) in an older group of patients treated with a single dose of intravitreal triamcinolone (4 mg/0.1 mL)

14429071, 2001, 1, Downloaded from https://onlinelibrary.wiley.com/doi/10.1046/j.1442-9071.2001.00360.x by Vanderbilt University, Wiley Online Library on [03/09/2024]. See the Terms and Conditions (https://onlinelibrary.wiley.com/terms-and-conditions) on Wiley Online Library for rules of use; OA articles are governed by the applicable Creative Commons License

for exudative macular detachment, although three patients had elevated intraocular pressure following a second injection.[16] In another report, of 113 patients given intravitreal triamcinolone for exudative macular degeneration, 42% developed a rise in IOP of 2–4 mmHg, 32% had a rise in IOP of >5 mmHg and a further 11% had a rise in IOP of >10 mmHg.[17] A history of steroid response and likely intolerance to beta-blockers should be considered contraindications to intravitreal triamcinolone. The greater incidence of IOP rise in the present study may reflect compromised drainage angles secondary to the chronic inflammatory process.

Two of the six patients developed posterior subcapsular cataract 6 months following intravitreal triamcinolone, although one of these had undergone previous trabeculectomy which is also associated with cataract formation. Progression of nuclear sclerotic cataract was reported in 22% of an older group following a single injection and three of four patients who received two injections within 4 months.[16] A second injection of triamcinolone given 8 months after the first appears to produce no more adverse events than a single injection (Gillies MC, 1999, pers. comm.).

Intravitreal triamcinolone was effective treatment for inflammatory macular oedema in six patients who failed to respond to conventional therapy; however, its use may induce ocular hypertension and cataract. The number of patients in the present study is small but the effects seen on CMO and visual acuity are very encouraging. However, the effects on IOP and hastening of cataract formation may limit its usefulness in this younger population as compared to its usefulness in older patients with age-related macular degeneration. Newer steroid preparations may have less effect on the IOP while still clearing CMO, making them more suitable for either repeated injections or insertion into slow-release devices.[18]

References

1. Rothova A, Suttorp-van Schulten MS, Frits Treffers W, Kijlstra A. Causes and frequency of blindness in patients with intraocular inflammatory disease. *Br. J. Ophthalmol.* 1996; **80**: 332–6.
2. McCluskey PJ, Towler HM, Lightman S. Management of chronic uveitis. *BMJ* 2000; **320**: 555–8.
3. Dugel PU, Rao NA, Ozler S, Ligget PE, Smith RE. Pars plana vitrectomy for intraocular inflammation-related cystoid macular edema unresponsive to corticosteroids. *Ophthalmology* 1992; **99**: 1535–41.
4. Penfold PL, Gyory JF, Hunyor AB, Billson FA. Exudative macular degeneration and intravitreal triamcinolone. *Aust. NZ J. Ophthalmol.* 1995; **23**: 293–8.
5. Smith RE, Godfrey WA, Kimura SJ. Complications of chronic cyclitis. *Am. J. Ophthalmol.* 1976; **82**: 277–82.
6. Riordan-Eva P, Lightman S. Orbital floor steroid injections in the treatment of posterior uveitis. *Eye* 1994; **8**: 66–70.
7. Tanner V, Kanski JJ, Frith PA. Posterior sub-Tenon's triamcinolone injections in the treatment of uveitis. *Eye* 1998; **12**: 679–85.
8. Lightman S. Use of steroids and immunosuppressive drugs in the management of uveitis. *Lancet* 1991; **338**: 1501–504.
9. Cox SN, Hay E, Bird AC. Treatment of chronic macular edema with acetozolamide. *Arch. Ophthalmol.* 1988; **106**: 1190–95.
10. Faber MD, Lam S, Tessler HH, Jennings TJ, Cross A, Ruskin MM. Reduction of macular oedema by acetozolamide in patients with chronic iridocyclitis: a randomised prospective crossover study. *Br. J. Ophthalmol.* 1994; **78**: 4–7.
11. Whitcup SM, Csaky KG, Podgor MJ, Chew EY, Perry CH, Nussenblatt RB. A randomized, masked, cross-over trial of acetazolamide for cystoid macular edema in patients with uveitis. *Ophthalmology* 1996; **103**: 1054–63.
12. Suttorp-Schulten MSA, Feron E, Postema F, Kijlstra A, Rothova A. Macular grid photocoagulation in uveitis. *Br. J. Ophthalmol.* 1995; **79**: 821–4.
13. Baum J, Peyman G, Barza M. Intravitreal administration of antibiotic in the treatment of bacterial endophthalmitis. *Surv. Ophthalmol.* 1982; **26**: 204–6.
14. Young SH, Morlet N, Coroneo MT. Prevention of intraocular pressure rise following intravitreal injection. *Br. J. Ophthalmol.* 1993; **77**: 572–3.
15. Peyman P, Herbst R. Bacterial endophthalmitis: treatment with intraocular gentamycin and dexamethasone. *Arch. Ophthalmol.* 1974; **91**: 416–18.
16. Challa JK, Gillies MC, Penfold PL, Gyorp JF, Hunyor AB, Billson FA. Exudative macular degeneration and intravitreal triamcinolone: 18 month follow-up. *Aust. NZ J. Ophthalmol.* 1998; **26**: 277–81.
17. Wingate RJB, Beaumont PE. Intravitreal triamcinolone and elevated intraocular pressure. *Aust. NZ J. Ophthalmol.* 1999; **27**: 431–2.
18. Yang CS, Khawly JA, Hainsworth DP *et al.* An intravitreal sustained-release triamcinolone and 5-fluorouracil codrug in the treatment of experimental proliferative vitreoretinopathy. *Arch. Ophthalmol.* 1998; **116**: 69–77.

14429071, 2001, 1, Downloaded from https://onlinelibrary.wiley.com/doi/10.1046/j.1442-9071.2001.00360.x by Vanderbilt University, Wiley Online Library on [03/09/2024]. See the Terms and Conditions (https://onlinelibrary.wiley.com/terms-and-conditions) on Wiley Online Library for rules of use; OA articles are governed by the applicable Creative Commons License