Safety and Efficacy of Dispase and Plasmin in Pharmacologic Vitreolysis

Fenghua Wang, Zhiliang Wang, Xiaodong Sun, Fang Wang, Xun Xu, and Xi Zhang

Purpose. To evaluate the safety and efficacy of dispase and plasmin when inducing posterior vitreous detachment (PVD) by intravitreous injection in rabbit eyes.

Methods. Forty-eight young pigmented rabbits were randomized into six groups. Groups 1 and 5 received 0.025 U dispase in test eyes; group 2, 0.1 U dispase; groups 3 and 6, 1 U plasmin; and group 4, 4 U plasmin. All groups received PBS in control eyes. Groups 5 and 6 were euthanatized 15 minutes after surgery for ocular histologic examination. The remaining groups (groups 1–4) received indirect ophthalmoscope and biomicroscopy 15 and 30 minutes; 1, 2, and 8 hours; and 1, 3, and 7 days after surgery. Ultrasonography and electroretinogram were performed 1 hour and 1 and 7 days after surgery. The eyes then were examined by scanning and transmission electron microscopy.

Results. Partial or complete PVDs were observed in the eyes that received dispase and plasmin, confirmed by the results of scanning electron microscopy. Light microscopy showed inflammation in both dispase- and plasmin-treated eyes of groups 5 and 6. However, whereas in plasmin-treated eyes the ERG and cell ultrastructure showed no significant changes, in dispase-treated eyes, the amplitudes of ERG showed a significant reduction from baseline and ultrastructural damage to the retina was detected by transmission electron microscopy. Cell damage, preretinal hemorrhage, and cataract were also observed in these eyes. No changes were observed in the control eyes.

Conclusions. Intravitreal injection of dispase at 0.025 U or more can induce PVD, but it is not safe. Plasmin (1–4 U) is safer, except for the potential risk of inducing intraocular inflammation. (*Invest Ophthalmol Vis Sci.* 2004;45:3286–3290) DOI:10.1167/iovs.04-0026

The vitreous–retinal interface plays an important role in many vitreoretinal disorders, including retinal detachment, diabetic retinopathy, retinal vein occlusion, and macular hole.[1,2] Despite major advances in vitreoretinal surgical techniques over the past 30 years, relief of vitreoretinal traction remains the most critical and perhaps the most difficult step in the surgical management of such diseases. To solve this problem, several kinds of enzymes have been investigated to separate the posterior vitreous cortex (PVC) from the inner limiting lamina (ILL)—a process also known as pharmacologic vitreolysis.[3–6]

These substances, including hyaluronidase, chondroitinase, tissue plasminogen activator, plasmin, and dispase, have been shown to induce vitreolysis in porcine, rabbit, and human eyes. Although a large number of studies concerning pharmacologic vitreolysis have been performed, very little has been reported about side effects in most of the studies.[7–10]

Our preliminary investigation on enzyme vitrectomy made us believe that the side effects or complications associated with the use of these substances should be carefully evaluated before they are used in human eyes. Some of them may induce more invasive results in the eye than surgical procedures.[11]

To obtain more information about the safety of these substances, in our experiment, dispase and plasmin were injected into rabbit eyes by intravitreous injection. Their safety was carefully evaluated by a series of morphology and functional examinations in current research.

Materials and Methods

Enzyme and Animal Preparation

Dispase and plasmin powders (Calbiochem, La Jolla, CA) were prepared in calcium and magnesium-free phosphate-buffered saline (PBS), diluted to the final concentrations, dispase 0.5 U/mL and 2 U/mL and plasmin 20 U/mL and 80 U/mL, and stored at −20°C for future use.

Forty-eight 2-month-old male pigmented rabbits were treated in accordance with the ARVO Statement for the Use of Animals in Ophthalmic and Vision Research. All rabbits were randomly placed in six groups. Each group consisted of eight rabbits that received 0.05 mL dispase or plasmin in one eye (test eye) and 0.05 mL PBS in the other (control eye). The concentrations of dispase and plasmin in test eyes were: group 1, dispase 0.025 U/0.05 mL; group 2, dispase 0.1 U/0.05 mL; group 3, plasmin 1 U/0.05 mL; group 4, plasmin 4 U/0.05 mL; group 5, dispase 0.025 U/0.05 mL; group 6, plasmin 1 U/0.05 mL

All rabbits were initially examined with binocular indirect ophthalmoscopy, biomicroscopy, B-ultrasonography (BVI, Clermont-Ferrand, France) and electroretinography to exclude any eye abnormalities.

Injection and Observation

Independent and masked experienced operators performed the complete processes of injection and observation. Each study eye received a 0.05-mL solution through a 30-gauge needle into the midvitreous through the pars plana.

Then, binocular indirect ophthalmoscopy and biomicroscopy examinations were performed immediately in all groups to look for possible surgical complications. Next, groups 1 to 4 were observed for 15 and 30 minutes; 1, 2, and 8 hours; and 1, 3, and 7 days after the injection. Their eyes were also examined with B-ultrasonography.

Electroretinography

Scotopic electroretinography (ERG) was obtained at baseline and 1 hour, 1 day, and 7 days after the injection. Rabbits were pupil dilated by 0.5% tropicamide phenylephrine eye drops and dark adapted for 30 minutes. Full-field ERGs were recorded from both eyes with a commercial system (UTAS-E2000; LKC Technologies, Gaithersburg, MD). Averages of 10 responses were calculated and the a- and b-wave amplitudes were recorded.

From the Department of Ophthalmology, Shanghai First People's Hospital, Shanghai, People's Republic of China.

Submitted for publication January 12, 2004; revised March 13, 2004; accepted March 29, 2004.

Disclosure: **F. Wang**, None; **Z. Wang**, None; **X. Sun**, None; **W. Fang**, None; **X. Xu**, None; **X. Zhang**, None

The publication costs of this article were defrayed in part by page charge payment. This article must therefore be marked "*advertisement*" in accordance with 18 U.S.C. §1734 solely to indicate this fact.

Corresponding author: Xi Zhang, 85 Wu-Jin Road Shanghai, 200080, People's Republic of China; 021110288@fudan.edu.cn.

Investigative Ophthalmology & Visual Science, September 2004, Vol. 45, No. 9
Copyright © Association for Research in Vision and Ophthalmology

Downloaded from iovs.arvojournals.org on 09/03/2024

Table 1. Incidence of Partial and Complete PVD in Groups 1–4

	Partial	Complete	Total
Dispase 0.025 U	5 (62.5)	3 (37.5)	8 (100)
Dispase 0.1 U	1 (12.5)	7 (87.5)	8 (100)
Plasmin 1 U	5 (62.5)	1 (12.5)	6 (75.0)
Plasmin 4 U	2 (25.0)	6 (75.0)	8 (100)

Data are the number of eyes with PVD, with the percentage of total eyes in each group in parentheses.

Histologic Evaluation

To investigate the short-term effects of dispase and plasmin on intraocular tissues, groups 5 and 6 were euthanatized at 15 minutes. The eyes were fixed for light microscopic examination of the retina and lens. The eyes were fixed with 2% paraformaldehyde for 24 hours and then embedded in paraffin. Horizontal sections (5-μm-thick) were made through the optic nerve head and stained with hematoxylin and eosin.

On day 7, rabbits in groups 1 to 4 were euthanatized, and the eyes were examined by scanning and transmission electron microscopy to investigate the ultrastructure of the retina and vitreoretinal interface. After enucleation, the eyes underwent immediate sharp razor penetration near the pars plana to ensure rapid penetration of fixative, and then remained immersed in 4% glutaraldehyde (0.1 M phosphate buffer and pH 7.4) for 24 hours at 4°C. To avoid artificially mechanical posterior vitreous detachment (PVD), the vitreous was dissected with a sharp razor. Carefully separated from the anterior segment of the globe, the posterior segment was oriented and opened into four parts. Two parts were dehydrated, dried, sputter-coated in gold, and photographed (S-520 scanning microscope; Hitachi, Tokyo, Japan). The specimens for transmission electron microscopy were separated from the posterior pole retina and photographed by electron microscope (JEM-1200EX; JEOL, Tokyo, Japan).

Data Analysis

Statistical analyses were performed on computer (SPSS for windows, ver. 10.0; SPSS Inc., Chicago, IL).

Results

Incidence of PVD

PVD was clinically classified according to the method of Oliveira et al.[12] Scanning electron microscopy (SEM) was performed to determine the degree of any vitreous detachment (Table 1). There was no PVD observed in the control eyes.

Clinical Observation

No abnormalities were found in all preinjection eyes and in postinjection control eyes. Observations in postinjection ophthalmoscopy and biomicroscopy of test eyes are presented in Table 2.

Table 2. Incidence of Postinjection Changes in Test Eyes

	Enzyme/ Dose	Tyndall (+)	Cataract	Haze	Hemorrhage
Group 1	D 0.025 U	1	0	8	5
Group 2	D 0.1 U	1	3	8	8
Group 3	P 1 U	2	0	8	0
Group 4	P 4 U	3	0	8	0
Group 5*	D 0.025 U	0	0	8	0
Group 6*	P 1 U	1	0	8	0

n = 8/group. D, dispase; P, plasmin.

* Incidences in Groups 5 and 6 are based on 15 minutes postoperative observation.

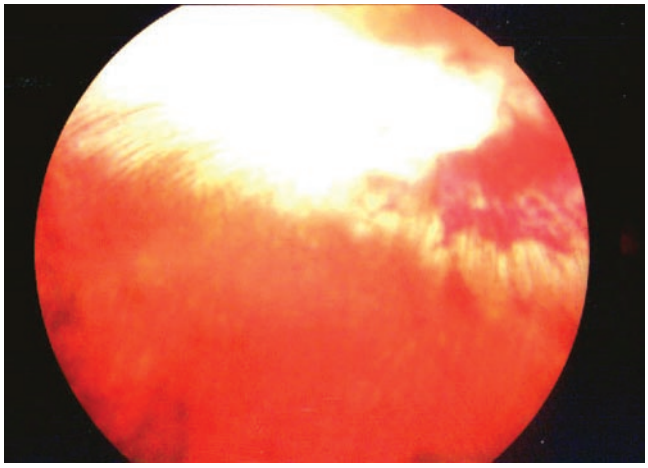

Figure 1. Preretinal hemorrhage. Fundus photograph of a test eye in group 1 that received 0.025 U dispase. This photograph was taken 2 hours after injection. Note the preretinal hemorrhage near the optic disc.

In the dispase group, we observed preretinal hemorrhage as early as 30 minutes after injection (group 2, dispase 0.1 U) and 2 hours after injection (group 1, dispase 0.025 U). The bleeding peaked after 8 hours, mainly distributing blood near the optic disc (Fig. 1). After 24 hours, the hemorrhage area reduced gradually. On the seventh day, bleeding was still observed in five test eyes of group 2. Cataract appeared on the third day after surgery in three of the eyes that received dispase 0.1 U.

In the plasmin group, anterior chamber flare and vitreous exudation were observed as early as 10 minutes after injection. Without using any additional drug, inflammation spontaneously lessened and cleared in 24 (group 3, plasmin 1 U) and in 72 hours (group 4, plasmin 4 U).

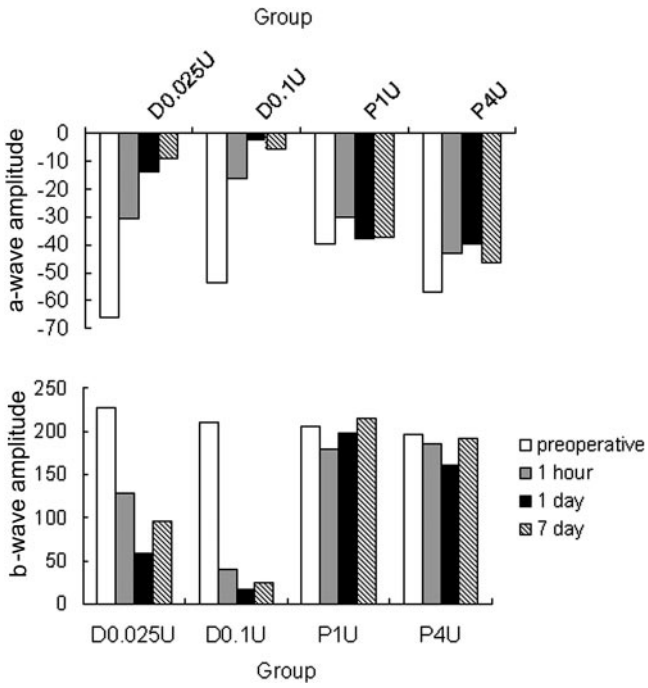

Figure 2. The mean value of the ERG a- and b-waves before and after the injection. D, dispase; P, plasmin.

Downloaded from iovs.arvojournals.org on 09/03/2024

Table 3. Results in Plasmin Treated Eyes

	a-Wave before Injection	a-Wave after Injection			b-Wave before Injection	b-Wave after Injection		
		1 h	1 d	7 d		1 h	1 d	7 d
Plasmin 1 U								
mean	−39.56	−30.24	−37.59	−37.13	206.08	179.96	198.21	214.21
t		−1.669	−0.603	−0.636		1.452	−1.076	−0.625
P		0.139	0.565	0.545		0.190	0.317	0.552
Plasmin 4 U								
mean	−56.78	−43.22	−39.71	−46.27	196.11	185.14	160.21	191.31
t		−0.973	−1.460	−1.189		0.660	1.739	0.233
P		0.363	0.188	0.273		0.530	0.126	0.822

B-Ultrasonography

Mild to moderate vitreous opacities were observed in dispase- and plasmin-treated eyes. Vitreous hemorrhage was detected in three dispase-treated eyes (group 2) at 1 hour after injection, and the incidence increased to six eyes in the same group on the second day.

Electroretinography

In control eyes, no statistically significant difference was found between the pre- and postinjection mean a- and b-wave amplitudes.

Figure 2 shows the ERG findings for the test eyes before and after injection. For the test eyes receiving 0.025 or 0.1 U dispase, ERG data analyses showed significant reductions of the mean a- and b-wave amplitudes (both $P < 0.01$) from baseline. The ERG a- and b-waves in 0.1 U dispase-treated eyes were nearly unrecordable after injection, indicating a significant toxic effect. The ERG reading of the eyes in the plasmin 1- and 4-U groups had no significant changes from the baseline ($P > 0.01$, Table 3).

Light Microscopy

In light micrographs, the posterior capsule of the lens was intact in all eyes. The control eyes had a structure similar to that of normal eyes. There were distinct cellular layers and a continuous ILL covering the inner surface of the retina.

Light microscopy of the test eyes showed abnormal retinal morphology and cellular anatomy in group 5 (dispase 0.025 U). Inflammatory cells and some red blood cells gathered in the posterior vitreous cavity in all eight eyes (Fig. 3A). The ILL was discontinuous in four eyes. Some retinal ganglion cells showed a severely damaged structure (Fig. 3B). We also found a few inflammatory cells in the posterior vitreous cavity in the plasmin-treated eyes, but the cellular layers of the retina were clearly demarcated, and the ILL was presented as a continuous membranous structure. There were no abnormalities compared with control eyes (Fig. 3C).

Scanning Electron Microscopy

In SEM photographs of PVD eyes, the inner limiting membrane was covered by only a few remnants of cortical vitreous at the posterior pole (group 3) and at the equator (groups 1, 2, and 4). At the vitreous base, there was no vitreoretinal separation except for four eyes that received 0.1 U dispase. There was a direct correlation between the concentration of plasmin and the degree of vitreoretinal separation. Eyes that received 1 U plasmin had much more residual collagen fibrils than those that received 4 U plasmin. In all control eyes the vitreous cortex was completely attached to the retina (Fig. 4).

Transmission Electron Microscopy

The morphology of the ILL and the cellular anatomy of the retina were not affected in plasmin- and PBS-treated eyes, but the inner layer cells, especially the ganglion and bipolar cells, changed considerably in dispase-treated eyes (Fig. 5).

Discussion

Dispase, also called neutral protease, hydrolyzes several proteins, including type IV collagen and fibronectin, which are present at the vitreoretinal interface and support attachment of the vitreous cortex to the ILL. Plasmin has been used in small clinical studies and is viewed as a promising enzyme as the adjunct in vitrectomy.[13,14] It readily degrades the glycoprotein component laminin (LN) and fibronectin (FN) at an enzyme-to-substrate ratio of 1:100. Therefore plasmin can act on the vitreoretinal interface by degrading FN and LN and facilitate separation of vitreous fibers from the ILL.[15,16]

In this study, we investigated the safety and efficacy of dispase and plasmin in pharmacologic vitreolysis in rabbit eyes. We chose rabbit for our investigation, because rabbit has ocular pharmacokinetics similar to those in humans and is a good model for preclinical studies.[17] It is also the most widely used model in similar researches. The study results showed complete or partial vitreoretinal separation mainly based on the scanning electron microscopy, which is generally regarded as a reliable method to evaluate PVD.[18–20]

Dispase appeared toxic to the retina at the different doses and time courses used in this study. Intravitreously injected, dispase can cause preretinal hemorrhage and vitreous inflammation in 15 minutes. Longer exposure (7 days) to a higher dose of dispase (0.1 U) can induce irreversible lens injury, as well as irreversible retinal functional and morphologic damage.

We found that our results showing dispase's efficacy are different from those reported by Jorge et al.[21] They tested dispase at doses of 0.05 to 2.5 U and concluded that it would not induce PVD in rabbit and human eyes. We agree with their results regarding dispase-related hemorrhage, which is also consistent with the previously reported results of most investigators,[8,22] except Oliveira et al.[12] They used 50 μg dispase combined with vitrectomy in porcine eyes and concluded that it was safe. This concentration is comparable to 0.025 U dispase in rabbit eyes, which was the lowest effective concentration in our experiments.

We believe that cataracts formed because dispase acted on the type IV collagen in the posterior capsular. It also acted on the extravascular matrix, and then caused preretinal hemorrhage. Because dispase is usually obtained from *Bacillus polymyxa* and contains endotoxin, it may not be optimal for application in the eyes.

Downloaded from iovs.arvojournals.org on 09/03/2024

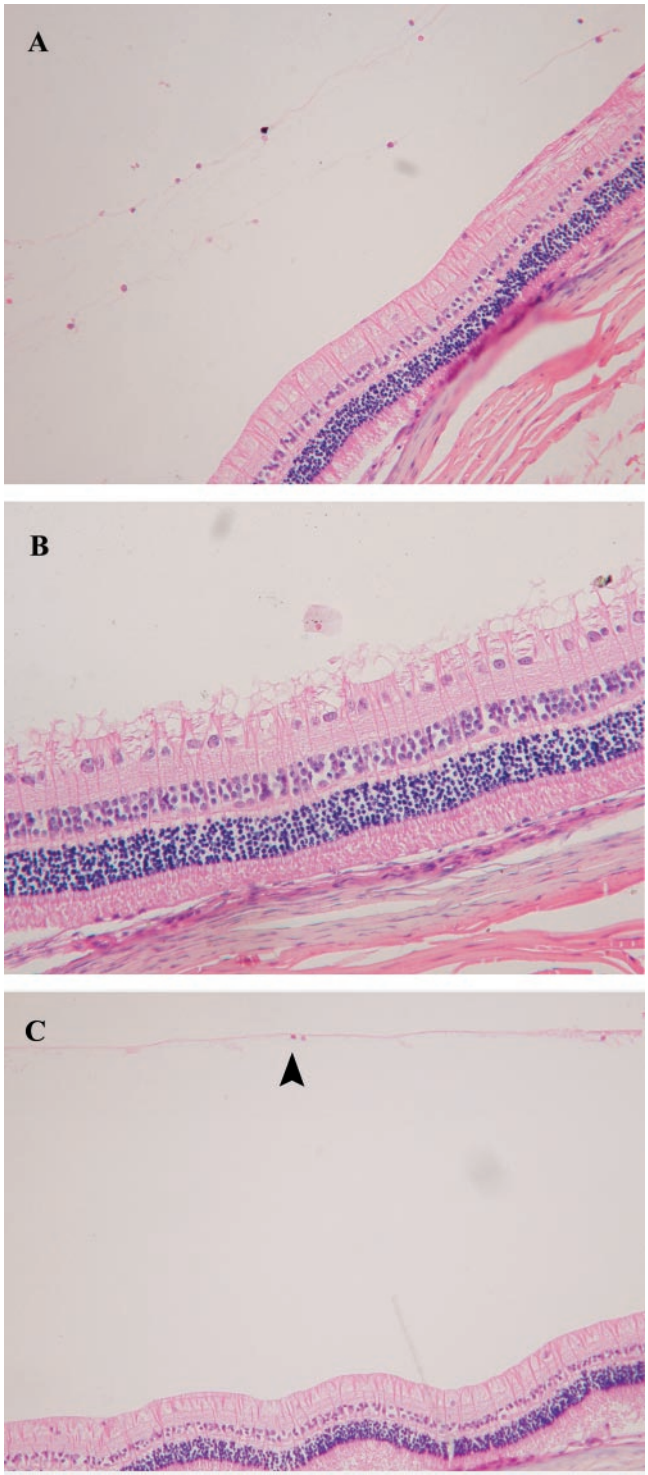

FIGURE 3. Light micrograph of dispase-treated and plasmin-treated eye. (**A**) Light micrograph of a group-5 test eye (0.025 U dispase). Inflammatory cells and red blood cells were present in the posterior vitreous cavity. (**B**) Light micrograph of another group-5 test eye (0.025 U dispase). A damaged inner layer retinal cells and discontinuous ILL are shown. (**C**) Light micrograph of a group-6 test eye (1 U plasmin). The retinal cells were normal. A few inflammatory cells (*arrow*) were present in the posterior vitreous cavity. Magnification: (**A**, **C**) ×40; (**B**) ×200.

Compared with the dominant toxic effect of dispase, plasmin's side effects were mild. After injection of 1 or 4 U plasmin, the eyes demonstrated reversible anterior chamber and vitreous aseptic inflammation. During the observed inflammation phase, gentle reductions in a- and b-wave amplitudes were noted at 1 hour and 1 day after injection (Fig. 4), but the reductions were not significantly different (Table 3). From the results of ERG examination and electron microscopy, it appears that 1 and 4 U plasmin did not further injure function and structure of retina.

The gathering of inflammatory cells indicated the immune response to foreign protein, especially from different species. Using autologous plasmin and microplasmin may lessen the immune response to foreign protein.[13,14,20] However, plasmin is not a natural component of vitreous because of the existence of the blood–eye barrier. It may induce autoimmune responses and hence exert an unexpected effect in human eyes. This type of inflammation cannot be lessened, even by using autologous plasmin. Therefore, the response should be carefully considered when using plasmin in human clinical trials.

In summary, PVD was successfully induced by intravitreous dispase and plasmin injections. Dispase at 0.025 U or more caused injuries to the lens and retina. Plasmin at 1 and 4 U was safer, except for reversible anterior chamber and vitreous inflammation.

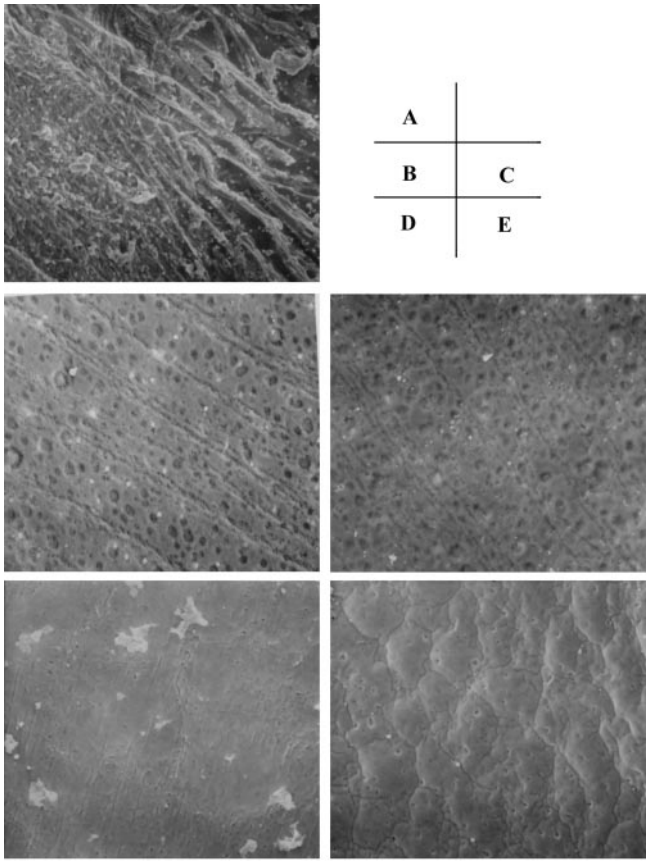

FIGURE 4. Scanning electron photomicrographs of the inner retina surface. (**A**) In a control eye (PBS) with no PVD, vitreous cortex fiber remained on the retinal surface. (**B–E**) In test eyes with complete or partial PVD, there was less vitreous cortex left on the retinal surface. (**B**) Group 1 (dispase 0.025 U), complete PVD. (**C**) Group 2 (dispase 0.1 U), complete PVD. (**D**) Group 3 (plasmin 1 U), partial PVD, with some cortex residue on the retinal surface. (**E**) Group 4 (plasmin 4 U), complete PVD. Magnification, ×200.

Downloaded from iovs.arvojournals.org on 09/03/2024

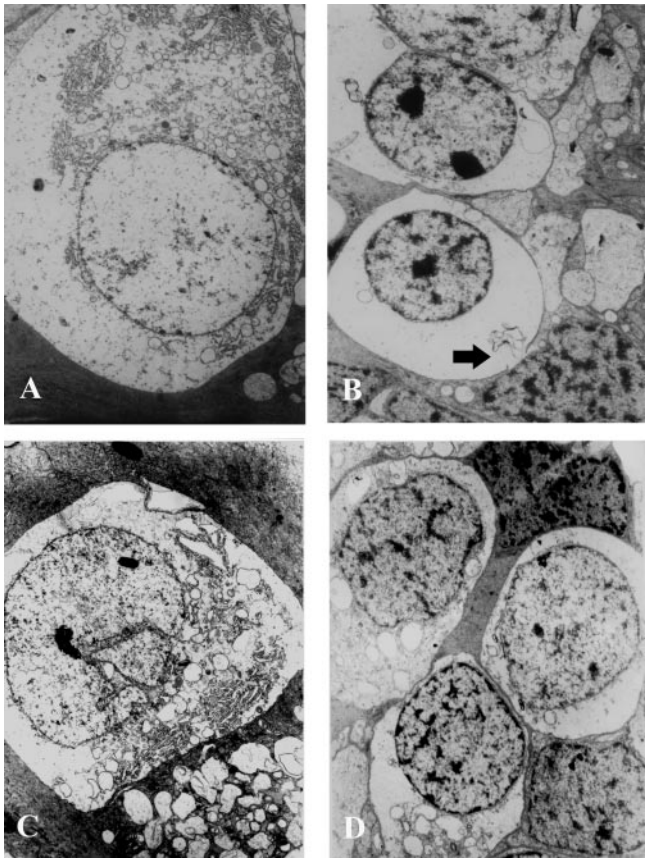

FIGURE 5. Transmission electron photomicrographs of retinal cells in the test eyes. (**A**, **B**) Eye that received 0.1 U dispase. (**A**) Edematous retinal ganglion cell. (**B**) Bipolar cells with damage to the cell membrane (*arrow*). (**C**, **D**) Eye that received 4 U plasmin. (**C**) A retinal ganglion cell was normal. (**D**) Bipolar cells were mildly edematous, but the cell membrane was still intact. Magnification, ×25,000.

Acknowledgments

The authors thank Chen Rongjia, Yu Zhang, Zou Haidong, Zhu Ping, Zhu Qi, and Gu Qing for excellent technical assistance throughout the project.

References

1. Sebag J. Classifying posterior vitreous detachment: a new way to look at the invisible. *Br J Ophthalmol*. 1997;81:521.
2. Kakehashi A, Kado M, Akiba J, et al. Variations of posterior vitreous detachment. *Br J Ophthalmol*. 1997;81:527–532.
3. Hesse L. Using enzymes in the posterior eye segment: current status and future possibilities. *Ophthalmologe*. 2001;98:1176–1180.
4. Robert B. Anticipation for enzymatic vitreolysis (editorial). *Br J Ophthalmol*. 2001;85:1–2.
5. Sebag J. Pharmacologic vitreolysis. *Retina*. 1998;18:1–3.
6. Sebag J. Is pharmacologic vitreolysis brewing? *Retina*. 2002;22:1–3.
7. Verstraeten TC, Chapman C, Hartzer M, et al. Pharmacologic induction of posterior vitreous detachment in the rabbit. *Arch Ophthalmol*. 1993;111:849–854.
8. Tezel TH, Del Priore LV, Kaplan HJ. Posterior vitreous detachment with dispase. *Retina*. 1998;18:7–15.
9. Harooni M, McMillan T, Refojo M. Efficacy and safety of enzymatic posterior vitreous detachment by intravitreal injection of hyaluronidase. *Retina*. 1998;18:16–22.
10. Unal M, Peyman GA. The efficacy of plasminogen-urokinase combination in inducing posterior vitreous detachment. *Retina*. 2000;20:69–75.
11. Fenghua W, Xi Z, Xiaodong S. Efficacy and safety of dispase in inducing posterior vitreous detachment of rabbit eyes [in Chinese]. *Chin Ophthalmic Res.* 2003;21:121–125.
12. Oliveira LB, Tatebayashi M, Mahmoud TH, et al. Dispase facilitates posterior vitreous detachment during vitrectomy in young pigs. *Retina*. 2001;21:324–331.
13. Williams JG, Trese MT, Williams GA, et al. Autologous plasmin enzyme in the surgical management of diabetic retinopathy. *Ophthalmology*. 2001;108:1902–1905.
14. Trese MT, Williams GA, Hartzer MK. A new approach to stage 3 macular holes. *Ophthalmology*. 2000;107:1607–1611.
15. Liotta LA, Goldfarb RH, Brundage R, et al. Effect of plasminogen activator, plasmin, and thrombin on glycoprotein and collagenous components of basement membrane. *Cancer Res*. 1981;41:4629–4636.
16. Li X, Shi X, Fan J. Posterior vitreous detachment with plasmin in the isolated human eye. *Graefes Arch Clin Exp Ophthalmol*. 2002;240:56–62.
17. Pearson PA, Jaffe GJ, Martin DF, et al. Evaluation of a delivery system providing long-term release of cyclosporine. *Arch Ophthalmol*. 1996;114:311–317.
18. Gandorfer A, Putz E, Welge-Lussen U, et al. Ultrastructure of the vitreoretinal interface following plasmin assisted vitrectomy. *Br J Ophthalmol*. 2001;85:6–10.
19. Gandorfer A, Priglinger S, Schebitz K, et al. Vitreoretinal morphology of plasmin-treated human eyes. *Am J Ophthalmol*. 2002;133:156–159.
20. Gandorfer A, Rohleder M, Sethi C, et al. Posterior vitreous detachment induced by microplasmin. *Invest Ophthalmol Vis Sci*. 2004;45:641–647.
21. Jorge R, Oyamaguchi EK, Cardillo JA, et al. Intravitreal injection of dispase causes retinal hemorrhages in rabbit and human eyes. *Curr Eye Res*. 2003;26:107–112.
22. Frenzel EM, Neely KA, Walsh AW, et al. A new model of proliferative vitreoretinopathy. *Invest Ophthalmol Vis Sci*. 1998;39:2157–2164.

Downloaded from iovs.arvojournals.org on 09/03/2024