Posterior Vitreous Detachment Induced by Microplasmin

Arnd Gandorfer,[1,2,3] *Matthias Rohleder,*[1,2,3] *Charanjit Sethi,*[2] *Dominik Eckle,*[1] *Ulrich Welge-Lüssen,*[1] *Anselm Kampik,*[1] *Philip Luthert,*[3] *and David Charteris*[2]

Purpose. To demonstrate the efficacy of microplasmin in inducing posterior vitreous detachment (PVD) and to evaluate the human and the feline retina after treatment.

Methods. Thirteen human donor eyes were injected with 62.5, 125, or 188 μg microplasmin. The 13 fellow eyes received balanced salt solution. Four of the microplasmin-treated eyes received an additional intravitreal gas injection. After incubation at 37°C for 30 minutes, all globes were placed in 4% paraformaldehyde. Retinal specimens were processed for scanning (SEM) and transmission (TEM) electron microscopy. Five feline eyes were injected with 14.5- or 25-μg microplasmin. Animals were killed after 1 day, 3 days, or 3 weeks, and retinal specimens were evaluated by electron and confocal microscopy.

Results. In all control eyes, SEM demonstrated the cortical vitreous covering the inner limiting membrane (ILM). Intravitreal injection of 125 or 188 μg microplasmin resulted in complete PVD. After treatment with 62.5 μg microplasmin, SEM revealed collagen fibrils covering the ILM. Additional gas injection did not change the dose necessary for PVD. In vivo in cats, 25 μg microplasmin resulted in complete PVD after 3 days. After 3 weeks, there was complete PVD with both doses of microplasmin. The retina and the ILM were well preserved in all eyes.

Conclusions. Both after death and in vivo, microplasmin induces a dose-dependent cleavage between the vitreous cortex and the ILM without morphologic alterations of the retina. In the feline eye, there is no cellular response of retinal glial cells or neurons. (*Invest Ophthalmol Vis Sci.* 2004;45:641–647) DOI:10.1167/iovs.03-0930

Current concepts of the pathogenesis of macular disease are based on the premise that traction at the vitreoretinal interface is a major component of retinal dysfunction.[1] This traction is thought to be mediated by the vitreous cortex and by fibrocellular proliferation at the vitreoretinal interface, and therefore complete removal of the cortical hyaloid is often a principal goal of vitreoretinal surgery.[2]

Removal of the cortical vitreous by mechanical means, however, does not result in complete vitreoretinal separation.[3] Cortical vitreous fibrils of varying extent are left behind on the inner limiting membrane (ILM) when the hyaloid is detached by suction applied by the vitrectomy probe.[4,5] Incomplete vitreoretinal separation, a clinical entity called vitreoschisis, which has been described particularly in diabetic eyes,[6] has been proposed as a major cause of disease progression and treatment failure.[7–9] Moreover, there is experimental evidence from adult primates that mechanical separation of the hyaloid from the retina is not only insufficient to provide complete vitreoretinal separation but frequently causes damage to the macula and the optic disc, including breaks and separation of the ILM from the retina and avulsion of nerve fibers and ganglion cells.[3]

Currently, removal of the ILM is considered the most efficient technique to eliminate vitreomacular traction. Peeling of the ILM, however, involves direct intervention on the macula by mechanical means, and although ILM peeling (without the use of indocyanine green) is generally regarded as a safe and feasible surgical maneuver, it remains challenging for the surgeon, and potentially can result in macular damage.[10,11] Therefore, the desire for complete vitreoretinal separation and the potential risk of aggressive ILM peeling suggests the need for pharmacologic vitreous separation to minimize mechanical trauma to the retina.

Plasmin is a serine protease that mediates the fibrinolytic process and modulates the extracellular matrix.[12] It hydrolyzes a variety of glycoproteins, including laminin and fibronectin, both of which are present at the vitreoretinal interface and are thought to play a key role in vitreoretinal attachment.[12–14] Plasmin does not degrade collagen type IV, a major component of basement membranes and the ILM.[12] Therefore, plasmin holds theoretical promise to induce posterior vitreous detachment (PVD) without damaging the ILM and the retina.

The efficacy of plasmin in inducing PVD has been demonstrated in several studies.[4,15–19] Previous work of our group showed a dose- and time-dependent cleavage between the vitreous and the retina in porcine eyes.[15] In contrast to earlier reports, no mechanical approach such as vitrectomy or additional gas injection was necessary to induce PVD.[17,18] Plasmin alone was sufficient to achieve complete separation at the vitreoretinal junction at the posterior pole and at the equator in a dose-dependent manner.[15] Reproducing the experimental setting in donor eyes confirmed the cleaving effect of plasmin in human eyes.[16] A third study demonstrated the potential benefit of plasmin as an adjunct to vitrectomy.[4] In contrast to conventionally vitrectomized eyes, which revealed remnants of cortical vitreous in the form of collagen fibrils covering the retina, the combination of an intravitreal injection of plasmin followed by vitrectomy 30 minutes later resulted in a bare ILM, consistent with complete PVD.[4]

Plasmin, however, has as yet not been available or approved for intravitreal application in humans. Therefore, plasminogen, the inactive precursor of plasmin has been proposed for intra-

From the [1]Department of Ophthalmology, University Eye Hospital, Ludwig-Maximilians-University, Munich, Germany; the [2]Vitreoretinal Research Unit, Moorfields Eye Hospital, United Kingdom; the [3]Department of Pathology, Institute of Ophthalmology, London, United Kingdom.

Supported by the Friedrich-Baur Fund and the Schneider Fund and ThromboGenics Ltd., Dublin, Ireland.

Submitted for publication August 25, 2003; revised October 29, 2003; accepted October 31, 2003.

Disclosure: **A. Gandorfer**, ThromboGenics Ltd. (F, C); **M. Rohleder**, None; **C. Sethi**, None; **D. Eckle**, None; **U. Welge-Lüssen**, None; **A. Kampik**, ThromboGenics Ltd. (F, C); **P. Luthert**, None; **D. Charteris**, None

The publication costs of this article were defrayed in part by page charge payment. This article must therefore be marked "*advertisement*" in accordance with 18 U.S.C. §1734 solely to indicate this fact.

Corresponding author: Arnd Gandorfer, Department of Ophthalmology, University Eye Hospital, Ludwig-Maximilians-University, Mathildenstrasse 8, 80336 Munich, Germany; arnd.gandorfer@ak-i.med.uni-muenchen.de.

Copyright © Association for Research in Vision and Ophthalmology

Downloaded from iovs.arvojournals.org on 08/24/2024

vitreal injection, necessarily followed by an additional administration of a plasminogen activator, such as streptokinase or urokinase.[20] To overcome the administration of heterologous plasminogen, Hesse et al.[21] induced a breakdown of the blood–retinal barrier by cryotherapy, thereby releasing autologous plasminogen. Additional administration of tissue plasminogen activator resulted in an intravitreal generation of autologous plasmin which induced PVD.[21] All these studies were performed in rabbit eyes.[17,20,21]

Recombinant microplasmin (ThromboGenics Ltd., Dublin, Ireland) is currently under clinical development for systemic administration in patients with thromboembolic disease. Microplasmin consists of the catalytic domain of plasmin and shares the same catalytic properties as human plasmin.[22] The molecular mass of microplasmin (28 kDa) is lower than the molecular mass of human plasmin (88 kDa), thus, in theory, enabling the molecule to penetrate epiretinal tissue more effectively than plasmin obtained from pooled plasma or autologous plasmin.

We investigated the cleaving effect of microplasmin at the vitreoretinal interface in both human tissue and in vivo in the cat. In the postmortem experiment, human donor eyes were exposed to different doses of microplasmin. In addition, some eyes were treated by gas injection. Transmission and scanning electron microscopy were performed in all eyes to investigate the efficacy of microplasmin in producing complete vitreoretinal separation. In a feline model, the pharmacology and toxicity of microplasmin were assessed by scanning and transmission electron microscopy and by laser confocal microscopy.

Methods

Human Eyes

Twenty-six human globes with no known eye disease were obtained from the local eye bank (Munich, Germany), having been removed from 13 donors within 19 hours of death. The donors' ages ranged from 34 to 69 years. Donor eyes were obtained and used according to the provisions of the Declaration of Helsinki for research involving human tissue. After the cornea was harvested with a 14-mm diameter trephine, the globes were incubated in a moist chamber at 37°C for 15 minutes. Microplasmin (0.2 mL) was injected into the vitreous cavity of 13 eyes. The fellow eyes received an injection of physiologic saline solution (BSS Plus; Alcon Laboratories, Fort Worth, TX) and served as the control. Nine eyes were treated with an intravitreal injection of microplasmin only. Because it had been reported previously that plasmin induces PVD in combination with vitrectomy or gas injection only,[17,18] 0.6 mL of sulfurhexafluoride (SF_6) was administered additionally in four eyes, and the globes were fixed with the posterior pole in an upright position. For details of doses and treatment see Table 1. After treatment, all eyes were incubated at 37°C for 30 minutes. The globes were then placed in 4% paraformaldehyde, and 0.1 mL of fixative was also injected into the vitreous cavity to stop enzymatic action within the eye.

Table 1. Dose and Treatment in Human Donor Eyes

Number of Eyes	Dose of Microplasmin (μg)	Treatment
2	62.5	Intravitreal injection
5	125.0	Intravitreal injection
2	188.0	Intravitreal injection
2	62.5	Intravitreal injection and gas tamponade (0.6 mL SF_6)
2	125.0	Intravitreal injection and gas tamponade (0.6 mL SF_6)

Feline Model

All procedures were approved by the Secretary of State (Home Office, Animal Procedures Section, UK) and adhered to the ARVO Statement for the Use of Animals in Ophthalmic and Vision Research. Five adult domestic cats aged between 12 and 23 months were anesthetized with an intramuscular injection of 0.5 mL ketamine (Ketaset; Park-Davis, Eastleigh, UK) and 0.3 mL medetomide (Dormitor; Pfizer, Sandwich, UK), and received an intravitreal injection of 14.5 (n = 2) or 25 μg (n = 3) microplasmin. The cats injected with 14.5 μg microplasmin were subsequently killed at 3 and 21 days whereas the cats injected with 25 μg microplasmin were subsequently killed at 1 day, 3 days, and 21 days.

Tissue Processing

Electron Microscopy. All eyes were hemisected along the pars plana, and the anterior segment was discarded. A corneal trephine of 12.5-mm diameter was slowly moved through the vitreous and the posterior pole was punched out. Retinal specimens for scanning and transmission electron microscopy were then obtained from the posterior pole with a corneal trephine of 4-mm diameter.

Retinal discs for scanning electron microscopy were postfixed in osmium tetroxide 2% (Dalton's fixative), dehydrated in ethanol, dried to the critical point, sputter coated in gold, and photographed by electron microscope (ISM-35 CF; JEOL, Tokyo, Japan).

Specimens for transmission electron microscopy were postfixed in Dalton's fixative, dehydrated, and embedded in Epon. Semithin sections were stained with 2% toluidine blue. Ultrathin sections were stained for contrast with uranyl acetate and lead citrate and analyzed by electron microscope (EM 9; Carl Zeiss Meditec, Jena, Germany).

Electron microscopic photographs were evaluated independently by two observers. Each observer evaluated the degree of vitreoretinal separation by deciding whether a continuous or discontinuous network of collagen fibrils covered the ILM, or whether single or sparse collagen fibrils were present at the ILM, or whether the ILM was devoid of any collagen fibrils.[15]

Confocal Microscopy. After rinsing in phosphate-buffered saline (PBS), the specimens were orientated in 5% agarose (Sigma-Aldrich; St. Louis, MO) in PBS. Sections (100-μm-thick) were cut with a vibratome (Technical Products International; Polysciences, Warrington, PA) and incubated in normal donkey serum (1:20; Dianova, Hamburg, Germany) in PBS containing 0.5% bovine serum albumin (BSA; Fisher Scientific, Pittsburgh, PA), 0.1% Triton X-100 (Roche Diagnostics, Mannheim, Germany), and 0.1% sodium azide (Sigma-Aldrich) overnight at 4°C on a rotator (PBS, BSA, Triton, and azide mixture referred to as PBTA). After removal of blocking serum, primary antibodies were added in six sets of pairs: anti-glial fibrillary acidic protein (GFAP; 1:500; Dako, Hamburg, Germany) with anti-collagen IV (1:50; Dako); anti-vimentin (1:50; Dako) with anti-fibronectin (1:400; Dako); anti-synaptophysin (1:50; Dako) with anti-neurofilament (1:25; Dako); anti-laminin (1:25; Dako) with anti-CD 68 (1:50; Dako); anti-red/green opsin (1:100; Santa Cruz Biotechnology, Santa Cruz, CA) with anti-rhodopsin (1:200; Santa Cruz Biotechnology); anti-blue opsin (1:100; Santa Cruz Biotech) with anti-rhodopsin (1:200; Santa Cruz Biotech). For selection and specificity of antibodies used see Table 2.

After overnight incubation at 4°C on a rotator, sections were rinsed in PBTA and incubated again overnight at 4°C with the secondary antibody. Donkey anti-mouse and donkey anti-rabbit secondary antibodies were used for each combination of primary antibodies, conjugated to Cy2 or Cy3 (Dianova, Hamburg, Germany). All secondary antibodies were used at a dilution of 1:100, and all the antibodies were diluted in PBTA. The sections were then rinsed, mounted in N-propyl gallate in glycerol and viewed on a laser scanning confocal microscope (model LSM 510; Carl Zeiss Meditec).

Downloaded from iovs.arvojournals.org on 08/24/2024

Table 2. Selection and Specifity of Antibodies Used

Antibody	Specificity
Anti-glial fibrillary acidic protein (GFAP); anti-vimentin	Intermediate filament proteins of Müller cells
Anti-neurofilament	Neurofilaments in ganglion cells and in horizontal cells
Anti-synaptophysin	Synaptic vesicles in plexiform layers
Anti-red/green opsin; anti-blue opsin	Cones
Anti-rhodopsin	Rods
Anti-fibronectin	Fibronectin
Anti-laminin	Laminin
Anti-collagen IV	Collagen type IV
Anti-CD68	Macrophages

Results

Human Eyes

Scanning Electron Microscopy. *Intravitreal Injection of Microplasmin.* After treatment with 62.5 μg microplasmin, scanning electron microscopy revealed a discontinuous network of collagen fibrils covering the ILM (Fig. 1A). Microplasmin at 125 μg resulted in complete vitreoretinal separation with an almost bare ILM covered by only sparse collagen fibrils (Fig. 1B); 188 μg resulted in similar ultrastructure of the vitreoretinal interface, and the amount of collagen fibrils left on the ILM (Fig. 1C).

Intravitreal Injection of Microplasmin and Gas. There were remnants of cortical vitreous covering the ILM in eyes which received 62.5 μg microplasmin and gas (Fig. 1D; Table 3). Intravitreal injection of 125 μg microplasmin followed by gas tamponade resulted in a complete vitreoretinal separation consistent with a bare ILM (Fig. 1E). All control eyes showed a dense network of collagen fibrils covering the ILM (Fig. 1F).

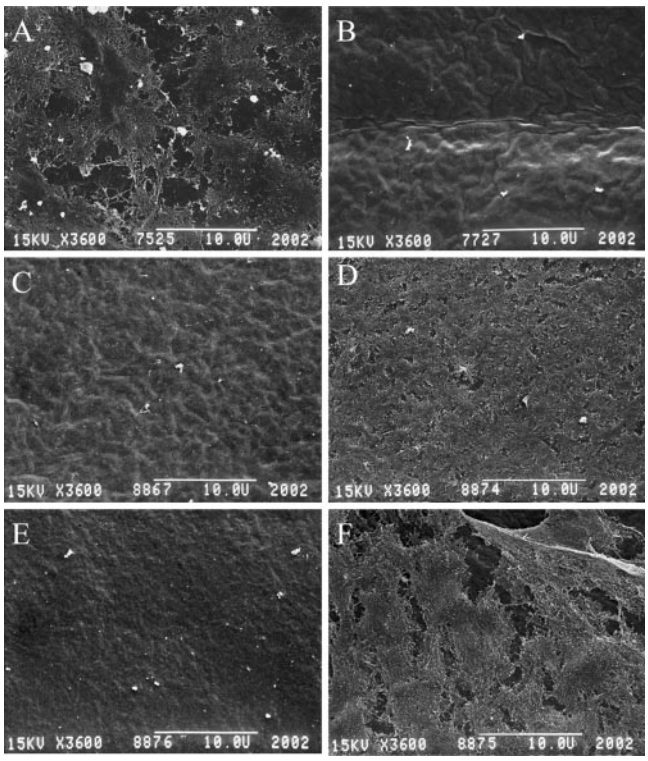

Figure 1. Scanning electron micrographs of the vitreoretinal interface in human donor eyes. (**A**) Intravitreal injection of 62.5 μg of microplasmin resulted in remnants of collagen fibrils covering the ILM. Microplasmin at (**B**) 125 and (**C**) 188 μg produced complete PVD and a bare ILM. (**D**) Compression of collagen fibrils toward the ILM in an eye treated with 62.5 μg microplasmin and gas. (**E**) Complete PVD after treatment with 125 μg microplasmin and gas. (**F**) Dense network of collagen fibrils in a control eye. Magnification: ×3600.

Transmission Electron Microscopy. The intraretinal morphology of all microplasmin-treated eyes was unchanged compared with control eyes. The ultrastructure of the ILM was well preserved (Fig. 2A), and there was no difference between the microplasmin-treated eyes and the control (Fig. 2B).

Feline Eyes

Scanning Electron Microscopy. One day after intravitreal injection of 25 μg microplasmin, sparse collagen fibrils covered the ILM (Fig. 3A). Three days after treatment, 25 μg microplasmin resulted in complete vitreoretinal separation (Fig. 3B). There were no remnants of collagen fibrils left at the vitreoretinal interface. The eye that received 14.5 μg microplasmin revealed sparse collagen fibrils covering the ILM 3 days after the injection (Fig. 3C). Twenty-one days after treatment, both 14.5 μg (Fig. 3D) and 25 μg microplasmin (Fig. 3E) resulted in a bare ILM. All fellow control eyes had a dense network of collagen fibrils covering the retina (Fig. 3F; Table 4).

Light and Transmission Electron Microscopy. Regarding the cytoarchitecture of the retina, no difference was observed between microplasmin-treated eyes and control eyes (Figs. 4A, 4B). The ultrastructure of the inner retina (Figs. 4C, 4D) and of the ILM (Figs. 4E, 4F) was normal.

Laser Confocal Microscopy. In microplasmin-treated eyes and in control eyes, the end-foot portion of Müller cells was clearly labeled by anti-GFAP (Figs. 5A, 5B) and anti-vimentin (Fig. 5C, 5D). There was no extended staining of Müller cell processes beyond the inner nuclear layer. No significant staining was observed with anti-collagen IV and anti-fibronectin, which may relate to species specificity (data are not shown). The ILM was stained by anti-laminin. Few macrophages were present in both treated eyes and control eyes. The ganglion cell axons and dendrites, the horizontal cells, and the inner and outer plexiform layer were clearly labeled by anti-neurofilament and anti-synaptophysin (Figs. 5E, 5F). The photoreceptor layer was labeled by anti-neurofilament. With respect to any of the antibodies used, there was no difference between microplasmin-treated eyes and control eyes at any time point of the study.

Discussion

The present study demonstrates the efficacy of microplasmin in separating the posterior hyaloid from the ILM. Both in human donor eyes and in vivo feline eyes, complete vitreoretinal separation was induced in a dose- and time-dependent fashion without morphologic damage to the retina.

Downloaded from iovs.arvojournals.org on 08/24/2024

Table 3. Degree of Residual Cortical Vitreous in Human Donor Eyes

Dose of Microplasmin (μg)	Treatment	Degree of Residual Cortical Vitreous	
		Treated Eyes	Control Eyes
62.5	Intravitreal injection	++	+++
125	Intravitreal injection	−	+++
188	Intravitreal injection	−	+++
62.5	Intravitreal injection and gas tamponade	++	+++
125	Intravitreal injection and gas tamponade	−	+++

+++, Continuous network of collagen fibrils; ++, discontinuous network of collagen fibrils; +, sparse collagen fibrils; −, no collagen fibrils, bare ILM.

In human donor eyes, intravitreal injection of 125 μg microplasmin was sufficient to induce complete PVD with bare ILM. In terms of enzymatic action, 125 μg microplasmin is the dose equivalent to 2 U plasmin (Sigma-Aldrich) which causes complete vitreoretinal separation in porcine eyes and in human donor eyes.[15,16] Microplasmin (62.5 μg, which is equivalent to 1 U of Sigma-Aldrich plasmin) left collagen fibrils adherent to the ILM, and 188 μg microplasmin had an effect similar to that of 125 μg microplasmin. Therefore, for the short-term effect of microplasmin, 125 μg appears to be the optimal dose necessary to cleave the vitreoretinal junction within 30 minutes.

As in previous studies, no additional surgical technique was necessary to separate the hyaloid from the ILM.[15,16] However, because it had been reported previously that plasmin is effective only in combination with intravitreal gas injection or vitrectomy,[17,18] we investigated the additional effect of an intravitreal gas injection. The application of a gas bubble into the vitreous of a microplasmin-treated eye did not affect the dose needed to cleave the vitreoretinal junction. It has been shown that an intravitreal gas injection does not separate the vitreous cortex from the retina but compresses the collagen fibrils of the vitreous gel toward the retina.[23] Therefore, in this postmortem model, there appeared to be no benefit of an additional intravitreal gas injection over the administration of microplasmin alone.

To assess the cleaving effect of microplasmin at the vitreoretinal interface in vivo, we administered two different doses into the vitreous cavity of five adult cats. First, we used 25 μg microplasmin which is one fifth of the dose found sufficient to induce complete PVD within 30 minutes in human donor eyes. Twenty-five micrograms microplasmin is equivalent to 0.4 U Sigma plasmin, and 0.4 U autologous plasmin has been applied clinically to the vitreous cavity of human eyes with macular holes and diabetic retinopathy.[24,25] Second, we adjusted this dose to the smaller vitreous volume of the feline eye (60% of the vitreous volume of the human eye),[26–28] 14.5 μg microplasmin in the feline eye is equivalent to 25 μg microplasmin in the human eye.

Three days after an intravitreal application of 25 μg microplasmin in the feline eye, there was complete vitreoretinal separation, whereas 1 day after treatment with the same dose, some collagen fibrils were still present at the vitreoretinal

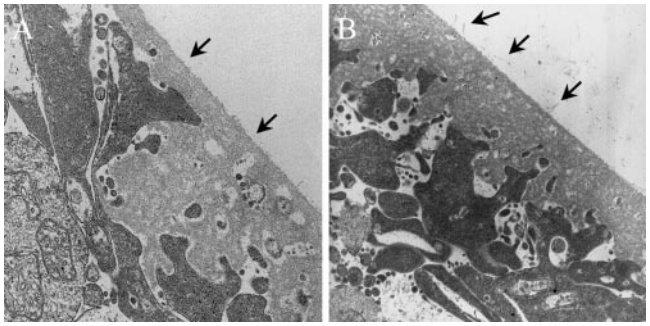

Figure 2. Transmission electron micrographs of the ILM in human donor eyes. (**A**) Microplasmin-treated eye showing the absence of collagen fibrils (*arrows*) on the ILM. (**B**) Control eye showing the continued presence of fibrils (*arrows*). Magnification: (**A**) ×13,600; (**B**) ×6,800.

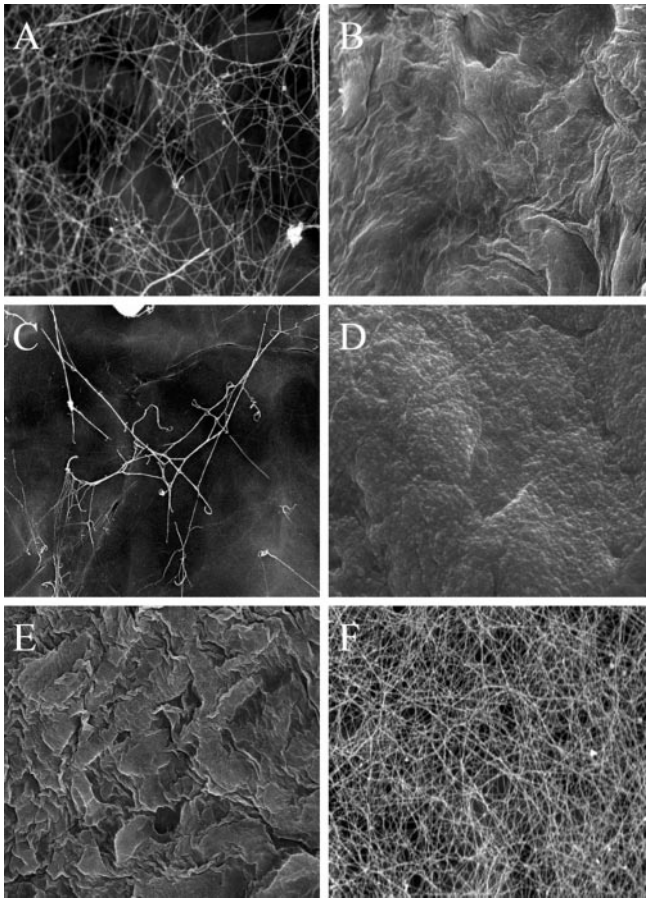

Figure 3. Scanning electron micrographs of the vitreoretinal interface in feline eyes. (**A**) Intravitreal injection of 25 μg microplasmin left remnants of collagen fibrils on the ILM 1 day after treatment. (**B**) Three days after treatment, 25 μg of microplasmin resulted in complete PVD. (**C**) Remnants of collagen fibrils 3 days after treatment with 14.5 μg microplasmin. (**D**, **E**) Bare ILM 3 weeks after injection of (**D**) 14.5 and (**E**) 25 μg of microplasmin. (**F**) Control eye showing a dense attached cortical vitreous. Magnification: ×3600.

Downloaded from iovs.arvojournals.org on 08/24/2024

Table 4. Degree of Residual Cortical Vitreous in Feline Eyes

Dose of Microplasmin (μg)	Duration of Treatment (days)	Degree of Residual Cortical Vitreous	
		Treated Eyes	Control Eyes
14.5	3	+	+++
14.5	21	−	+++
25	1	+	+++
25	3	−	+++
25	21	−	+++

+++, Continuous network of collagen fibrils; ++, discontinuous network of collagen fibrils; +, sparse collagen fibrils; −, no collagen fibrils, bare ILM.

interface. This suggests that the effect of microplasmin continues beyond 24 hours.

As formal in vivo vitreous pharmacokinetic experiments have not been performed, the metabolism of microplasmin in the vitreous cannot be determined at this time. However, given the immediate inactivation of plasmin and microplasmin in the blood by its natural antagonist α-2-antiplasmin, the reasons for an ongoing effect of microplasmin in the vitreous deserve consideration.

First, there may be saturation of α-2-antiplasmin. Recent studies of our group revealed very low levels of α-2-antiplasmin in the vitreous of eyes with macular holes, and a correlation of α-2-antiplasmin levels with breakdown of the blood–retinal barrier (Ulrich JN, unpublished data, 2003). Assuming that an intravitreal injection represents only a slight perturbation of the blood–retinal barrier in the feline eye, low levels of α-2-antiplasmin may be saturated and the enzymatic activity of microplasmin may last longer. However, the mechanism of inactivation of both microplasmin and plasmin in the vitreous is not known, and it is not possible to determine whether a differential effect can be expected in inactivation by use of the truncated molecule microplasmin. Further pharmacokinetic

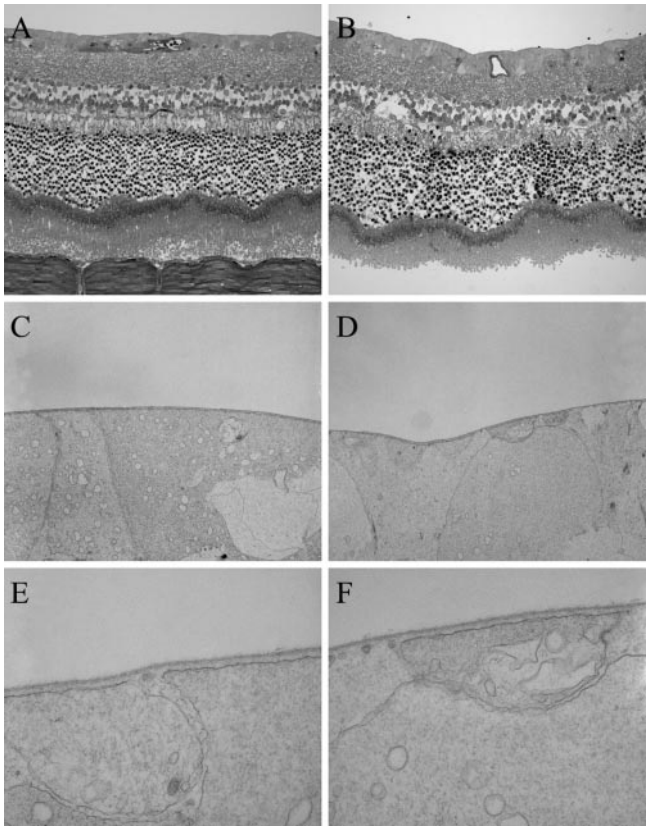

Figure 4. Light microscopy of semithin sections of feline eyes showed normal cytoarchitecture of the retina in microplasmin-treated eyes (**A**) and in control eyes (**B**). Transmission electron microscopy (**C–F**) revealed a well-preserved inner retina and ILM in microplasmin-treated eyes (**C**, **E**) and in control eyes (**D**, **F**). Magnification: (**A**, **B**) ×250; (**C**, **D**) ×6,000; (**E**, **F**) ×30,000.

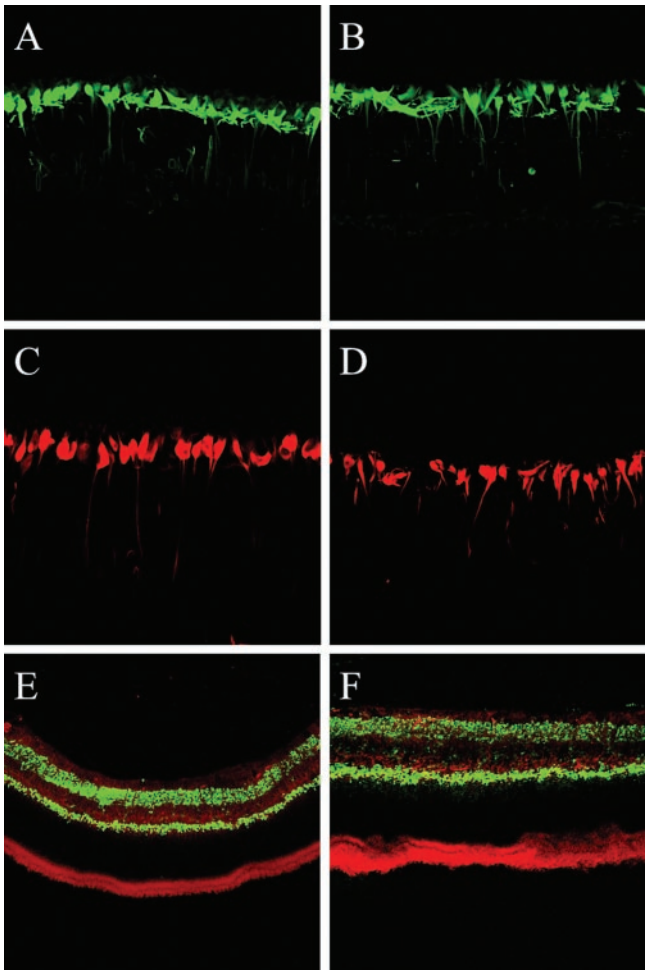

Figure 5. Confocal laser scanning microscopy with probes to GFAP (**A**, **B**, *green*) and vimentin (**C**, **D**, *red*). There was no difference between microplasmin-treated eyes (**A**, **C**) and control eyes (**B**, **D**). (**E**, **F**) Double-label immunohistochemistry with probes to synaptophysin (*green*) and neurofilament (*red*) shows no difference between a microplasmin-treated eye (**E**) and a control eye (**F**). Magnification: (**A–C**) ×400; (**D**) ×250; (**E**, **F**) ×160.

Downloaded from iovs.arvojournals.org on 08/24/2024

and toxicologic assessments in an in vivo setting are warranted before proceeding to clinical evaluation of this agent.

Second, ongoing downstream pathways may remain active after microplasmin has been inactivated. Secondary pathways may include activation of collagenases or matrix metalloproteinases (MMPs) and induction of an inflammatory response. Both activation of collagenases and manipulation of MMP-2 and -9 have been reported to be caused by plasmin.[29–31] From the present study, we cannot determine whether or to what extent secondary pathways may have contributed to the cleaving effect of microplasmin. We have demonstrated, however, that during a period of 3 weeks, activation of collagenases or MMPs did not alter the ultrastructure of the retina. The cytoarchitecture of the retina of microplasmin-treated eyes was unchanged compared with control eyes. In addition, we did not observe any signs of an inflammatory reaction after microplasmin injection. Electron microscopy and laser confocal microscopy did not show any evidence of inflammatory cellular infiltration of the retina.

In ultrastructural terms, there was no difference in the retinal anatomy between microplasmin-treated eyes and control eyes. The ILM and the retina were well preserved in all specimens. There is little previous work on the vitreoretinal relationship in feline eyes. However, our observation that all control eyes had an attached hyaloid makes it likely that PVD had not occurred spontaneously in the animals in our series. To what extent the age of the cat accounts for the presence or absence of PVD is unknown. The time- and dose-dependent fashion of vitreoretinal separation observed in human and feline eyes and the absence of PVD in our control animals suggest a similar physiological adhesion at the vitreoretinal junction of cats and humans. The feline model appears therefore to be an expensive but worthwhile technique to assess pharmacologically induced alterations at the vitreoretinal interface.

One more reason to use this model to assess the safety of pharmacologically induced PVD is that the feline retina has been extensively studied by anatomists and physiologists. Like the human retina outside the fovea, the feline retina is rod dominated, and it has an intraretinal circulation.[32] This is in contrast to the rabbit retina, which has no intraretinal vessels. The rabbit inner retina is perfused by vasculature that lies on its vitreal surface, and this limits the value of experimental studies primarily focused on the vitreoretinal interface in the rabbit.

For years, the feline model has provided high-quality data on the cellular responses of the retina to detachment (Sethi CS, et al. *IOVS* 2001;42:ARVO Abstract 2401).[33–40] Comparative studies of human tissue in parallel with the feline model demonstrate the validity of the feline eye in predicting cellular responses in the human eye (Charteris DG, et al. *IOVS* 2001; 42:ARVO Abstract 3530; Sethi CS, et al. *IOVS* 2001;42:ARVO Abstract 1805).

In the feline model, retinal detachment produces a significant proliferation of Müller cells and a massive upregulation of intermediate filament proteins in their cytoplasm, such as glial fibrillary acidic protein (GFAP) and vimentin.[33,34,41] This Müller cell response is widely known as gliosis and is supposed to play a key role in the complex cellular responses of the retina to detachment.[33,34,36,37,42] In the normal retina, Müller cells appear quiescent and express very small amounts of GFAP and vimentin.[32] However, even vitrectomy without inducing retinal detachment has been shown to cause upregulation of GFAP.[43] Recent work by our group demonstrated marked upregulation of intermediate filament proteins after attempted peeling of the ILM in feline eyes (Gandorfer A, unpublished data, 2003). These data point out the high reactivity of Müller cells to any form of surgical trauma.

In the present study, we did not observe any change in Müller cell reactivity after induction of PVD by microplasmin. Moreover, there was no difference between treated eyes and control eyes with respect to any antibody applied. The staining patterns of all retinal layers was generally unremarkable. We cannot rule out that cellular responses that could not be demonstrated by the antibodies used occurred after microplasmin treatment. However, the quiescent state of Müller cells at any time point of the study in association with the unchanged ultrastructure and immunoreactivity of the retina provides experimental evidence pointing to the safety of microplasmin in inducing PVD.

In conclusion, microplasmin is effective in inducing PVD and appears to be safe for the ocular ultrastructure. The major advantage of microplasmin compared with mechanical ILM peeling for complete vitreoretinal separation lies in the unchanged reactivity of retinal glial cells and neurons. Compared with autologous plasmin, microplasmin ensures the application of a pure substance at a defined dose. In theory and in practice, microplasmin holds the promise to cleave the vitreoretinal junction selectively without damaging the retina. Further studies are now needed to examine the long-term effect of microplasmin on both morphology and retinal function before clinical work can be undertaken with this preparation.

Acknowledgments

The authors thank Peter Munroe (Institute of Ophthalmology, London, UK) and Jürgen Werner (University Eye Hospital, Munich, Germany) for excellent technical assistance.

References

1. Morris R, Witherspoon CD. In: Kriegelstein G, ed. *Retinology Today.* Munich, Germany: Verlag für Medizin und Naturwissenschaftler; 2000:83–8.
2. Gandorfer A, Rohleder M, Kampik A. Epiretinal pathology of vitreomacular traction syndrome. *Br J Ophthalmol.* 2002;86:902–909.
3. Russell SR, Hageman GS. Optic disc, foveal, and extrafoveal damage due to surgical separation of the vitreous. *Arch Ophthalmol.* 2001;119:1653–1658.
4. Gandorfer A, Ulbig M, Kampik A. Plasmin-assisted vitrectomy eliminates cortical vitreous remnants. *Eye.* 2002;16:95–97.
5. Le Mer Y, Kroll P, Chofflet J, Hesse L. Systematic search of the posterior vitreous cortex during vitrectomy: technique, complications and results (in French). *J Fr Ophtalmol.* 1994;17:459–464.
6. Schwartz SD, Alexander R, Hiscott P, Gregor ZJ. Recognition of vitreoschisis in proliferative diabetic retinopathy: a useful landmark in vitrectomy for diabetic traction retinal detachment (see comments). *Ophthalmology.* 1996;103:323–328.
7. Sebag J. Diabetic vitreopathy. *Ophthalmology.* 1996;103:205–206.
8. Faulborn J, Bowald S. Microproliferations in proliferative diabetic retinopathy and their relationship to the vitreous: corresponding light and electron microscopic studies. *Graefes Arch Clin Exp Ophthalmol.* 1985;223:130–138.
9. Faulborn J, Dunker S, Bowald S. Diabetic vitreopathy: findings using the celloidin embedding technique. *Ophthalmologica.* 1998;212:369–376.
10. Gandorfer A, Haritoglou C, Gandorfer A, Kampik A. Retinal damage from indocyanine green in experimental macular surgery. *Invest Ophthalmol Vis Sci.* 2003;44:2722–2729.
11. Haritoglou C, Gass CA, Schaumberger M, Gandorfer A, Ulbig MW, Kampik A. Long-term follow-up after macular hole surgery with internal limiting membrane peeling. *Am J Ophthalmol.* 2002;134: 661–666.
12. Liotta LA, Goldfarb RH, Brundage R, Siegal GP, Terranova V, Garbisa S. Effect of plasminogen activator (urokinase), plasmin, and thrombin on glycoprotein and collagenous components of basement membrane. *Cancer Res.* 1981;41:4629–4636.

Downloaded from iovs.arvojournals.org on 08/24/2024

13. Kohno T, Sorgente N, Ishibashi T, Goodnight R, Ryan SJ. Immunofluorescent studies of fibronectin and laminin in the human eye. *Invest Ophthalmol Vis Sci*. 1987;28:506–514.
14. Russell SR, Shepherd JD, Hageman GS. Distribution of glycoconjugates in the human retinal internal limiting membrane. *Invest Ophthalmol Vis Sci*. 1991;32:1986–1995.
15. Gandorfer A, Putz E, Welge-Lussen U, Gruterich M, Ulbig M, Kampik A. Ultrastructure of the vitreoretinal interface following plasmin assisted vitrectomy. *Br J Ophthalmol*. 2001;85:6–10.
16. Gandorfer A, Priglinger S, Schebitz K, et al. Vitreoretinal morphology of plasmin-treated human eyes. *Am J Ophthalmol*. 2002;133:156–159.
17. Hikichi T, Yanagiya N, Kado M, Akiba J, Yoshida A. Posterior vitreous detachment induced by injection of plasmin and sulfur hexafluoride in the rabbit vitreous. *Retina*. 1999;19:55–58.
18. Verstraeten TC, Chapman C, Hartzer M, Winkler BS, Trese MT, Williams GA. Pharmacologic induction of posterior vitreous detachment in the rabbit. *Arch Ophthalmol*. 1993;111:849–854.
19. Li X, Shi X, Fan J. Posterior vitreous detachment with plasmin in the isolated human eye. *Graefes Arch Clin Exp Ophthalmol*. 2002;240:56–62.
20. Unal M, Peyman GA. The efficacy of plasminogen-urokinase combination in inducing posterior vitreous detachment. *Retina*. 2000;20:69–75.
21. Hesse L, Nebeling B, Schroeder B, Heller G, Kroll P. Induction of posterior vitreous detachment in rabbits by intravitreal injection of tissue plasminogen activator following cryopexy. *Exp Eye Res*. 2000;70:31–39.
22. Shi GY, Wu HL. Isolation and characterization of microplasminogen: a low molecular weight form of plasminogen. *J Biol Chem*. 1988;263:17071–17075.
23. Lincoff H, Kreissig I, Jakobiec F, Iwamoto T, Vitolo J, Shapiro R. Gas vitrectomy in a primate model. *Graefes Arch Clin Exp Ophthalmol*. 1986;224:215–217.
24. Trese MT, Williams GA, Hartzer MK. A new approach to stage 3 macular holes. *Ophthalmology*. 2000;107:1607–1611.
25. Williams JG, Trese MT, Williams GA, Hartzer MK. Autologous plasmin enzyme in the surgical management of diabetic retinopathy. *Ophthalmology*. 2001;108:1902–1905.
26. Bron AJ, Tripathi BJ. *Wolff's Anatomy of the Eye and Orbit.* 8th ed. London: Chapman; 1997.
27. Gelatt KN. *Veterinary Ophthalmology.* 2nd ed. Philadelphia: Lea & Feabiger; 1991.
28. Sebag J. *The Vitreous. Structure*, *Function*, *Pathobiology.* New York: Springer Verlag; 1989.
29. Baramova EN, Bajou K, Remacle A, et al. Involvement of PA/plasmin system in the processing of pro-MMP-9 and in the second step of pro-MMP-2 activation. *FEBS Lett*. 1997;405:157–162.
30. Mainardi CL, Dixit SN, Kang AH. Degradation of type IV (basement membrane) collagen by a proteinase isolated from human polymorphonuclear leukocyte granules. *J Biol Chem*. 1980;255:5435–5441.
31. Ramos-DeSimone N, Hahn-Dantona E, Sipley J, Nagase H, French DL, Quigley JP. Activation of matrix metalloproteinase-9 (MMP-9) via a converging plasmin/stromelysin-1 cascade enhances tumor cell invasion. *J Biol Chem*. 1999;274:13066–13076.
32. Lewis GP, Charteris DG, Sethi CS, Fisher SK. Animal models of retinal detachment and reattachment: identifying cellular events that may affect visual recovery. *Eye*. 2002;16:375–387.
33. Fisher SK, Erickson PA, Lewis GP, Anderson DH. Intraretinal proliferation induced by retinal detachment. *Invest Ophthalmol Vis Sci*. 1991;32:1739–1748.
34. Lewis GP, Erickson PA, Guerin CJ, Anderson DH, Fisher SK. Changes in the expression of specific Müller cell proteins during long-term retinal detachment. *Exp Eye Res*. 1989;49:93–111.
35. Lewis GP, Erickson PA, Anderson DH, Fisher SK. Opsin distribution and protein incorporation in photoreceptors after experimental retinal detachment. *Exp Eye Res*. 1991;53:629–640.
36. Lewis GP, Guerin CJ, Anderson DH, Matsumoto B, Fisher SK. Rapid changes in the expression of glial cell proteins caused by experimental retinal detachment. *Am J Ophthalmol*. 1994;118:368–376.
37. Lewis GP, Matsumoto B, Fisher SK. Changes in the organization and expression of cytoskeletal proteins during retinal degeneration induced by retinal detachment. *Invest Ophthalmol Vis Sci*. 1995;36:2404–2416.
38. Lewis GP, Linberg KA, Fisher SK. Neurite outgrowth from bipolar and horizontal cells after experimental retinal detachment. *Invest Ophthalmol Vis Sci*. 1998;39:424–434.
39. Lewis GP, Linberg KA, Geller SF, Guerin CJ, Fisher SK. Effects of the neurotrophin brain-derived neurotrophic factor in an experimental model of retinal detachment. *Invest Ophthalmol Vis Sci*. 1999;40:1530–1544.
40. Lewis GP, Fisher SK. Müller cell outgrowth after retinal detachment: association with cone photoreceptors. *Invest Ophthalmol Vis Sci*. 2000;41:1542–1545.
41. Geller SF, Lewis GP, Anderson DH, Fisher SK. Use of the MIB-1 antibody for detecting proliferating cells in the retina. *Invest Ophthalmol Vis Sci*. 1995;36:737–744.
42. Charteris DG, Sethi CS, Lewis GP, Fisher SK. Proliferative vitreoretinopathy: developments in adjunctive treatment and retinal pathology. *Eye*. 2002;16:369–374.
43. Yoshida A, Ishiguro S, Tamai M. Expression of glial fibrillic acidic protein in rabbit Müller cells after lensectomy-vitrectomy. *Invest Ophthalmol Vis Sci*. 1993;34:3154–3160.

Downloaded from iovs.arvojournals.org on 08/24/2024